This is a digital copy of a book that was preserved for generations on library shelves before it was carefully scanned by Google as part of a project to make the world's books discoverable online.

It has survived long enough for the copyright to expire and the book to enter the public domain. A public domain book is one that was never subject to copyright or whose legal copyright term has expired. Whether a book is in the public domain may vary country to country. Public domain books are our gateways to the past, representing a wealth of history, culture and knowledge that's often difficult to discover.

Marks, notations and other marginalia present in the original volume will appear in this file - a reminder of this book's long journey from the publisher to a library and finally to you.

Usage guidelines

Google is proud to partner with libraries to digitize public domain materials and make them widely accessible. Public domain books belong to the public and we are merely their custodians. Nevertheless, this work is expensive, so in order to keep providing this resource, we have taken steps to prevent abuse by commercial parties, including placing technical restrictions on automated querying.

We also ask that you:

+ *Make non-commercial use of the files* We designed Google Book Search for use by individuals, and we request that you use these files for personal, non-commercial purposes.
+ *Refrain from automated querying* Do not send automated queries of any sort to Google's system: If you are conducting research on machine translation, optical character recognition or other areas where access to a large amount of text is helpful, please contact us. We encourage the use of public domain materials for these purposes and may be able to help.
+ *Maintain attribution* The Google "watermark" you see on each file is essential for informing people about this project and helping them find additional materials through Google Book Search. Please do not remove it.
+ *Keep it legal* Whatever your use, remember that you are responsible for ensuring that what you are doing is legal. Do not assume that just because we believe a book is in the public domain for users in the United States, that the work is also in the public domain for users in other countries. Whether a book is still in copyright varies from country to country, and we can't offer guidance on whether any specific use of any specific book is allowed. Please do not assume that a book's appearance in Google Book Search means it can be used in any manner anywhere in the world. Copyright infringement liability can be quite severe.

About Google Book Search

Google's mission is to organize the world's information and to make it universally accessible and useful. Google Book Search helps readers discover the world's books while helping authors and publishers reach new audiences. You can search through the full text of this book on the web at `http://books.google.com/`

LANE MEDICAL LIBRARY STANFORD

LANE

MEDICAL LIBRARY

Dr. S.O. Beasley

Shadworth O Beasley M.D.

A TEXT-BOOK

OF

SURGICAL ANATOMY

BY

WILLIAM FRANCIS CAMPBELL, M. D.

BROOKLYN—NEW YORK

PROFESSOR OF ANATOMY, LONG ISLAND COLLEGE HOSPITAL; ATTENDING SURGEON TO THE METHODIST EPISCOPAL, SWEDISH, AND BUSHWICK HOSPITALS; CONSULTING SURGEON TO THE JAMAICA HOSPITAL

WITH 319 ORIGINAL ILLUSTRATIONS

PHILADELPHIA AND LONDON

W. B. SAUNDERS COMPANY

1908

Copyright, 1908, by W. B. Saunders Company

PRINTED IN AMERICA

PRESS OF
W. B. SAUNDERS COMPANY
PHILADELPHIA

5 13
9 05

TO
MY MOTHER

THE IDEAL TEACHER
WHOSE FAITH NEVER FALTERED
WHOSE PATIENCE NEVER FAILED

THIS BOOK IS
DEDICATED

50162

PREFACE

ANATOMIC facts are dry only as they are isolated. Translated into their clinical values they are clothed with living interest.

No teacher can impart, or student assimilate, all the details of anatomy. The facts must be sifted, their comparative values fixed, and the reason for their acquisition demonstrated by directing attention to the practical problems with which they are associated.

A fact that can be utilized is a fact that will survive. No attempt, therefore, has been made to present all the anatomic data. Those facts only have been selected which have a practical bearing, and those structures and regions emphasized which have a peculiar interest for the surgeon.

Surgery is anatomy practically applied, and the "anatomic mind" is as essential to a surgeon as the "aseptic conscience." The single purpose of this book is to aid the student and practitioner in mastering the essentials of practical anatomy. Due acknowledgment of the various sources from which the material has been gleaned is made in the bibliography appended. The facts themselves are the products of many minds and the accumulation of many years. Only the manner of their presentation and the attempt to estimate their clinical values can be credited the author.

Grateful appreciation is due Dr. P. Chalmers Jameson for his criticisms and suggestions in the chapter on the Eye; Dr. Frederick Tilney for a like service in the chapters on the Brain and Spinal Cord; and Dr. B. Joseph for his aid in preparing the index and reading the proof. The illustrations, for the most part, are the work of Mr. F. A. Deck, whose efficient co-operation has materially enhanced the value of the text.

BROOKLYN, NEW YORK,
FEBRUARY 1, 1908.

WILLIAM FRANCIS CAMPBELL.

CONTENTS

PART I

THE HEAD AND NECK

CHAPTER I

PAGES

SURFACE ANATOMY 17–24

CHAPTER II

THE SCALP 25–32

Its structure—Arteries of the scalp and their peculiarities—Treatment of hemorrhage of the scalp—Veins, nerves, and lymphatics of the scalp—The temporal region—Collections of blood or pus—Tumors of the scalp.

CHAPTER III

THE BONY VAULT OF THE CRANIUM 33–39

Its structure—Fractures of the skull and their complications.

CHAPTER IV

THE CRANIAL CONTENTS 40–58

The membranes of the brain and their structure—The dura mater—The middle meningeal artery—Epidural hemorrhage and its treatment—The sinuses and their surgical considerations—The arachnoid—The subarachnoid space—The cerebrospinal fluid—The pia mater—The arteries of the brain—Craniocerebral topography—Wounds of the brain—Trephining.

CHAPTER V

THE EAR 59–69

The external ear and its clinical considerations—Membrana tympani and its clinical considerations—The tympanum—The Eustachian tube—The mastoid process, its relations and clinical considerations.

CHAPTER VI

PAGES

THE FACE 70–94

Its blood supply and clinical considerations—Its nerves and its affections—The parotid region and its contents—Stenson's duct—Affections of the parotid region—The buccal region, its contents and affections—The superior maxillary region and its clinical considerations—The inferior maxillary region—The temporomaxillary articulation and its affections—The pterygomaxillary fossa—The inferior dental nerve—The lingual nerve.

CHAPTER VII

THE ORBITAL REGION 95–111

The orbital cavity, its structure—The orbital aponeurosis—The muscles of the orbit and their action—The orbital vessels and nerves—The eyeball, its structure and clinical considerations—The eyelids, their structure—The conjunctiva and its affections—The lacrimal apparatus and its surgical considerations.

CHAPTER VIII

THE NOSE AND NASAL CAVITIES 111–123

The structure of the nose—Fracture of the nasal bones—Arteries and nerves of the nose—The nasal cavities, their structure, blood supply, and clinical considerations—Accessory sinuses of the nose, and their clinical considerations.

CHAPTER IX

THE MOUTH, TONGUE, AND PHARYNX 124–147

The mouth—The lips—Hare-lip—The gums and their affections—The teeth, their structure and affections—The tongue, its structure and affections—Excision of the tongue—The palate, its divisions and structure—Cleft palate—The tonsils, their structure, blood supply, and affections—The pharynx, its structure and affections.

CHAPTER X

THE NECK 148–206

General considerations—Regions of the neck—The submaxillary region and its affections—The lingual triangle—The sternomastoid or carotid region—The sternomastoid muscle and its affections—The common carotid artery and its relations—The retrocarotid gland—Ligation of the common carotid—The internal and external carotid arteries and their surgical considerations—The internal jugular vein—Farabeuf's triangle—The cervical sympathetic and its surgical considerations—The outer region of the neck—The occipital triangle—The supraclavicular triangle, its contents and surgical considerations—The infrahyoid region—The larynx, its structure and surgical considerations—The trachea, its structure and surgical considerations—The thyroid gland, its structure, affections, and surgical considerations—The parathyroid glands and their clinical considerations—The esophagus, its structure, relations, and surgical considerations—The deep cervical fascia and its divisions—The lymphatics of the neck and their surgical considerations.

PART II

THE THORAX

CHAPTER XI

PAGES

SURFACE ANATOMY 204–206

CHAPTER XII

THE THORAX AND ITS CONTENTS 207–232

Contour of the thorax and deviations from the normal—The sternum, general considerations and fracture—The ribs, general considerations and fracture—Empyema—The intercostal spaces, arteries, nerves, and neuralgia—Internal mammary artery—The mammary region and its contents—The female breast, its general considerations, structure, and affections—The thoracic cavity—The diaphragm—The pleura—The pleural sinus—Pleurisy—Thoracentesis—Pneumothorax—The lungs, their anatomic considerations, blood, nerve, and lymph supply—Pulmonary embolism—Emphysema—Wounds of the lung—The mediastinum—The pericardium—The superficial cardiac triangle—Relation of the heart to the chest wall—The precardial region—Wounds of the heart—The aorta, its divisions and relations—The lymphatics of the mediastinum—The thymus—Mediastinal abscess and tumors.

PART III

THE UPPER EXTREMITY

CHAPTER XIII

SURFACE ANATOMY 233–239

CHAPTER XIV

THE SHOULDER 240–277

Clavicular region—The clavicle and its affections—The infraclavicular fossa—The subclavius muscle—The clavipectoral fascia—The scapular region—The supraspinous fossa—The infraspinous fossa—The subscapular fossa—Protection to the shoulder-joint—The quadrangular space—The triangular space—Fractures of the scapula—The scapulohumeral region—The deltoid muscle—The biceps muscle—Affections of the shoulder-joint, their clinical and surgical considerations—The axilla, its contents, affections, and surgical considerations—The axillary artery and its surgical considerations—The axillary lymph-glands and their surgical considerations—The brachial plexus, its branches, their general and surgical considerations—Erb's paralysis.

CHAPTER XV

PAGES

THE ARM, ITS REGION AND MUSCLES 278–283

The brachial artery, its location, branches, and clinical considerations—The median nerve—The triceps muscle—Fracture of the shaft of the humerus and its effects.

CHAPTER XVI

THE REGION OF THE ELBOW, ITS BOUNDARIES AND STRUCTURES... 284–296

Phlebotomy—The brachial artery—The biceps tendon—The arterial circle at the elbow-joint—The elbow-joint, its structure, landmarks, and surgical considerations—Fractures in vicinity of the elbow-joint.

CHAPTER XVII

THE FOREARM, ITS MUSCLES, NERVES, AND ARTERIES AND THEIR SURGICAL CONSIDERATIONS 297–304

Bones of the forearm—Fractures of the forearm and their clinical considerations.

CHAPTER XVIII

THE WRIST 305–315

Structures in the wrist—Wounds of the anterior portion of the wrist—General considerations of the posterior surface of the wrist—The ligamentous and tendinous structures of the wrist, their general and clinical considerations—The bones of the wrist and the joint structures into which they enter the triangular fibrocartilage—Colles' fracture, its general and surgical considerations—Fracture of the scaphoid—Affections of the wrist—Excision of the wrist.

CHAPTER XIX

THE HAND 316–330

Palm of the hand—Thenar eminence—Hypothenar eminence—The hollow of the hand—The deep palmar fascia—Dupuytren's contraction—The superficial palmar arch—The flexor tendons in the palm—The great palmar bursa and its surgical considerations—Compound palmar ganglion—Infections of the palm—The deep palmar arch—The palmar interossei—The dorsal surface of the hand—The metacarpal bones, their anatomic and surgical considerations—The fingers, their anatomic and surgical considerations—Tumors of the hand—Lymphatics of the upper extremity.

PART IV

THE ABDOMEN AND PELVIS

CHAPTER XX

SURFACE ANATOMY 331–335

CHAPTER XXI

PAGES

THE ABDOMEN AND ITS CONTENTS 336–460

General consideration of the abdomen and its anterior wall —The abdominal muscles, their anatomic, clinical, and surgical considerations—The aponeurosis of the external oblique and its divisions—The internal abdominal ring—The subperitoneal connective tissue and its characteristics —Arteries, veins, lymphatics, and nerves of the abdominal wall—Clinical considerations of the nerve supply of the abdominal wall—Congenital defects of the abdomen—Injuries and abscess of the abdominal wall—The umbilical region, its contents and their affections—Umbilical hernia—The inguinal region, its anatomic and surgical importance—The peritoneal fossæ—Inguinal hernia, its causes, varieties, structure, and treatment—Inguino-femoral region and its structures—Femoral hernia, its anatomic and surgical considerations—The posterior abdominal wall—The iliac fascia—The psoas and iliacus muscles—Psoitis—Psoas abscess—The lumbar region—Lumbar puncture—The muscles of the lumbar region—The triangle of Petit—The lumbar fascia—The erector spinæ muscles—The quadratus lumborum—Lumbago—The abdominal cavity, its boundaries and structures—The peritoneum, its structure and divisions—The great omentum, its structure and functions—The lesser omentum—The gastrosplenic omentum—The mesentery, its structure and affections—Intestinal localization—The lesser peritoneal cavity—The peritoneum, vessels, nerves, and lymphatics—Clinical considerations of the peritoneum —The stomach, its location, structure, clinical and surgical considerations—The small intestines, their divisions, structure, clinical, and surgical considerations—The cecum, its location, types, and abnormalities of position—The ileocecal valve—Intussusception, its causes and structure—The vermiform appendix, its varieties, structure, and location—The mesappendix—The appendiculo-ovarian ligament—The blood-vessels, lymphatics, and nerves of the appendix—The pericecal fossæ—Variations in the position of the appendix—Clinical and surgical considerations of the appendix—The colon, its location, structure, and divisions—Capacity of the colon, surgical considerations of the colon—The liver, its location, structure, affections, and clinical considerations—The gall-tract; its divisions, their anatomic considerations, affections, clinical and surgical considerations—The spleen, its location, structure, abnormalities, clinical, and surgical considerations—The pancreas, its function, structure, abnormalities, and surgical considerations—The kidneys, their location and structure—Movable kidney—Structures at the hilum of the kidney—Brödel's white line—Abnormalities, clinical and surgical considerations of the kidney—The ureters, their course, structure, relations, abnormalities, clinical and surgical considerations—The suprarenal glands, their location, structure, and affections—Vessels, nerves, and lymphatics of the abdomen, their clinical and surgical significance—Shock.

CHAPTER XXII

THE PELVIS AND ITS CONTENTS 46

Its divisions, diameters of its inlet and outlet, and its position —The pelvic axis—Sacro-iliac joint—Sacrocoxalgia—The symphysis pubis and symphyseotomy—Fractures of the pelvis—Pelvic deformities—The pelvic diaphragm—The levator ani muscle—The pelvic fascia, its attachments and divisions—Pelvic cellular tissue, and its characteristics—The pelvic viscera—The rectum, its relations, divisions, and structure—The anal canal—Vessels, nerves, and lymphatics of the rectum—Fistula in ano—Hemorrhoids—Fissure of the anus—Excision of the rectum—Imperforate anus—The bladder, its relations and divisions—The vesical trigone—Vessels, nerves, and lymphatics of the bladder—The female bladder—Clinical considerations of the bladder —The prostate, its relations, structure, and vascular and nerve supply—Clinical considerations of the prostate—The seminal vesicles and ducts, vas deferens and ejaculatory ducts and their clinical considerations—The uterus, its divisions, position, and relations—Its means of fixation —The cul-de-sac of Douglas—The cervix and its divisions —Atresia of the cervix—Cavity and structure of the uterus—Vessels, nerves, and lymphatics of the uterus—Malformations of the uterus—Clinical considerations of the uterus—The broad ligaments, their attachments, contents, and relations—Clinical considerations of the broad ligaments—The round ligaments and their course—Their clinical considerations—The uterosacral ligaments—The ovaries, their functions, size, shape, location, and structure—The parovarium—Clinical considerations of the ovaries—Parovarian cysts—Access to ovaries—The Fallopian tubes, their appearance, course, structure, and clinical considerations—The vagina, its course, relation, and structure—The female urethra, its direction, relations, structure, and clinical considerations.

CHAPTER XXIII

THE MALE PERINEUM AND ITS ADNEXA 51

The rectal triangle, its contents, and ischiorectal abscess—The urogenital triangle—The male urethra, its location, course, divisions, structure, and characteristics—Stricture of the urethra—Catheterization—Contents of the urogenital triangle—The triangular ligament—The compressor urethræ—Perineal section—The penis, its structure and affections—The fascia penis—Clinical considerations of the penis—The scrotal region—The scrotum, its structure, reflexes, and lymphatics—Epithelioma of the scrotum—The cremasteric reflex—The testicles and epididymis, their function and structure—Inversion of the testicle—The tunica vaginalis—The spermatic cord—The vas deferens—The spermatic artery—The spermatic veins —The lymphatics, nerves, and clinical considerations of the spermatic cord—Undescended testicle—Ectopia testis —Hydrocele, its varieties—Varicocele—Affections of the testicles and epididymis.

CHAPTER XXIV

PAGES

THE FEMALE PERINEUM AND ITS ADNEXA..... 544–547

Vaginorectal triangle—The female external genitals—The labia majora—The labia minora—The clitoris—The hymen—The vaginal bulbs—The vulvovaginal glands.

PART V

THE SPINE

CHAPTER XXV

THE SPINAL COLUMN AND ITS CONTENTS..... 548–561

General considerations of the spinal column—The intervertebral fibrocartilage—Movements of the spine—The physiologic movements of the spine—Kyphosis—Lordosis—Scoliosis, general characteristics of the vertebræ—The atypical vertebræ—The spinal canal, its length and structure—The spinal cord, its membranes, structures, and conduction paths—The spinal nerves—Clinical considerations of the spinal column and cord.

PART VI

THE LOWER EXTREMITY

CHAPTER XXVI

SURFACE ANATOMY..... 562–567

CHAPTER XXVII

THE REGION OF THE HIP, ITS GENERAL CONSIDERATIONS, MUSCLES, BURSÆ, VESSELS, NERVES, AND LYMPHATICS..... 568–592

The infragluteal triangle—The great sciatic nerve, its affections and surgical considerations—The groin, its lymphatics and their affections—The fascia lata—The saphenous opening—Scarpa's triangle and its contents—Affections of the femoral vein—Psoas abscess—The psoas bursa—Tumors of the groin—The obturator or adductor region, its foramen, artery, nerve, gland, and hernia—The hip-joint, its structure and parts—Fracture of the neck of the femur—Dislocation of the hip and its reduction—Tubercular hip disease and its symptomatology.

CHAPTER XXVIII

PAGES

THE THIGH, ITS STRUCTURES..... 593–596

The femoral artery—Hunter's canal—Ligation and anomalies of the femoral artery—The great sacrosciatic nerve—Fracture of the femur.

CHAPTER XXIX

REGION OF THE KNEE, THE STRUCTURES IN ITS FORMATION..... 597–614

The circumpatellar anastomosis—Nerves of the knee-joint—The popliteal space, its contents, boundaries, and clinical and surgical considerations—Popliteal aneurysm—The knee-joint and its structures—Genu valgum and its treatment—genu varum—The patella—The ligamentum patellæ—Fracture and dislocation of the patella—The synovial membrane of the knee and its affections—Fixation of the knee—Ankylosis—Fractures about the knee-joint—Dislocations of the knee—Excision of the knee-joint.

CHAPTER XXX

THE LEG, ITS STRUCTURES, THEIR ANATOMIC AND CLINICAL CONSIDERATIONS..... 615–620

Varicose veins—The bones of the leg, their fractures and other affections.

CHAPTER XXXI

THE ANKLE AND FOOT, THE STRUCTURES ENTERING IN ITS FORMATION..... 621–642

The tendo Achillis—Talipes equinus—Equinovarus—Tenotomy of the tendo Achillis—The retrocalcaneal bursa—The posterior tibial artery—The tibiotarsal joint—Pott's fracture—The foot and its structures—The plantar surface—The plantar fascia—The plantar arteries—The bones of the foot and their affections—The mediotarsal joint—The tarsometatarsal joint—Fractures and dislocations of the ankle—Amputations of the foot—The toes and their affections—Nerve supply of the lower extremity.

INDEX..... 643

SURGICAL ANATOMY

PART I

THE HEAD AND NECK

CHAPTER I

SURFACE ANATOMY

THE anatomy that may be studied upon the living subject, the many anatomic facts which the student may demonstrate upon his own person, such as the bony prominences, the course of the vessels and nerves, the various anatomic landmarks, etc., should emphasize the importance of a thorough mastery of these obvious facts before proceeding to a study of the deeper structures.

Note and practically demonstrate the following points (Fig. 1):

The **external occipital protuberance** (inion) may be felt as a prominent tubercle at the back of the head just above the line of junction of the neck and scalp. Opposite this point, on the inner surface of the skull, is situated the *torcular Herophili* into which flow six sinuses.

The **glabella,** a point above the root of the nose between the superciliary ridges. A line drawn from the glabella and passing directly over the vertex of the skull indicates—

(*a*) *The course of the superior longitudinal sinus.*

(*b*) *The longitudinal fissure* separating the cerebral hemispheres.

The **mastoid process,** the bony prominence behind the ear, its base above on a line with the roof of the external auditory meatus, its tip pointing toward the angle of the jaw. Draw a line from the external occipital protuberance to the base of the

mastoid process; this line represents the course of the horizontal portion of the lateral sinus. A line from the base to the tip of the mastoid represents the course of the sigmoid portion of this sinus.

The **lambda** may be felt as a depression in the median line about 2½ inches above the external occipital protuberance. It corresponds to the position of the *posterior fontanel*, the junction of the sagittal and lambdoidal sutures. On each side of the lambda may be felt the *parietal eminences*.

The **bregma** corresponds to the position of the *anterior fontanel*—the junction of the coronal and sagittal sutures. It

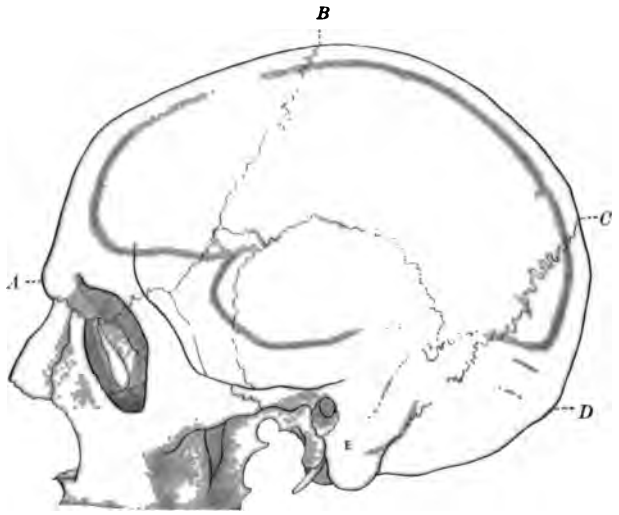

FIG. 1.—SURFACE MARKINGS OF THE HEAD.
A, The glabella; *B*, the bregma; *C*, the lambda; *D*, the external occipital protuberance; *E*, the mastoid process.

cannot be demonstrated upon the adult skull, but it is located at the center of a line passing across the vertex of the skull from one external auditory meatus to the other.

The **supra-orbital ridges,** the prominent bony ridges above the margin of the orbit. Note that they are broad internally and become less distinct as they arch outward. Behind these ridges are situated the *frontal sinuses* (Fig. 2). At the outer extremity of the ridge is a prominent angle, the *external angular process*.

The **supra-orbital notch** may be felt along the supra-orbital margin at the junction of its inner and middle thirds. Through

this notch is transmitted the supra-orbital nerve and artery. Press upon the notch and note the intense pain.

Raise the eyebrows and move the scalp back and forth and demonstrate the action of the *occipitofrontalis muscle.* Palpate the *zygoma* throughout its entire extent. Note that at its root, in front of the ear, it is crossed by the *temporal artery,* the pulsations of which can be plainly felt—a convenient point to get the pulse, especially during anesthesia, when the radial pulse is not accessible.

Above the zygoma palpate the *temporal muscle,* lodged in the temporal fossa. Bring the jaws tightly together and feel the contraction of the muscle.

FIG. 2.—SURFACE MARKINGS OF THE FACE.
A, Supra-orbital notch; *B*, infra-orbital notch; *C*, mental foramen; *D*, alar cartilages; *E*, frontal sinus; *F*, nasal bones; *G*, lateral cartilages of nose; *H*, antrum of Highmore.

Trace the *temporal ridge* which outlines the temporal fossa from the external angular process over the side of the skull to the base of the mastoid process.

Examine the external ear and demonstrate the **pinna** or **auricle;** it applies to the expanded portion of the external ear and includes all the external parts except the external auditory canal or meatus (Fig. 3).

The **helix,** the rim of the auricle.

The **anthelix,** the curved prominence in front and parallel with the helix.

The **concha,** the deep hollow in front of the anthelix and surrounding the entrance to the meatus.

The **tragus,** the small pointed eminence in front of the meatus.

The **antitragus,** separated from the tragus by a deep notch—the incisura intertragica—a small prominence on the lower rim of the concha.

The **lobule,** the dependent noncartilaginous portion. In some ears the lobule does not hang freely, but is adherent anteriorly.

Demonstrate on the face—

The **infra-orbital notch** (see Fig. 2), along the infra-orbital margin at the junction of its inner and middle thirds. It

FIG. 3.—SURFACE MARKINGS OF THE EAR.
A, The helix; *B*, the anthelix; *C*, the concha; *D*, the tragus; *E*, the antitragus; *F*, the lobule.

transmits the infra-orbital nerve and artery. Make pressure upon the notch and note the intense pain.

The **masseter muscle,** below the zygoma and extending to the angle of the jaw. Bring the muscle out prominently by pressing the jaws firmly together.

Stenson's duct, which can be felt like a whip-cord crossing the masseter muscle about a finger's-breadth below the zygoma.

The **condyle of the jaw,** just in front of the ear and at the root of the zygoma. Note that it glides forward when the mouth is opened.

The **facial artery,** as it crosses the lower jaw in front of the

masseter muscle. Its pulsations can be distinctly felt; it is a convenient point for the anesthetist to get the pulse when the radial pulse is not accessible.

The **mental foramen** in the body of the lower jaw, midway between its upper and lower borders, opposite the interval between the bicuspid teeth. It transmits the mental nerve and vessels. Pressure over this point produces intense pain.

The **nasal bones** forming the solid upper half of the nose, the cartilaginous portion below forming the movable half.

The **nasal spine** of the superior maxilla which can be felt between the two nostrils.

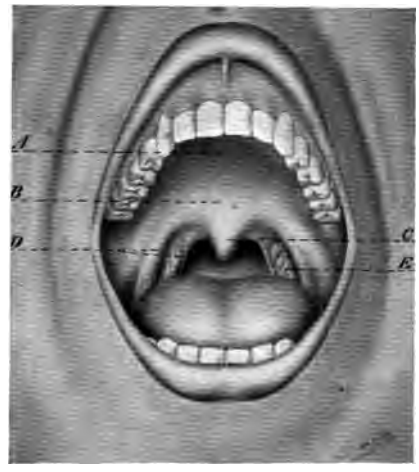

FIG. 4.—SURFACE MARKINGS SHOWN WITHIN THE MOUTH.
A, Hard palate; *B*, soft palate; *C*, uvula; *D*, pillars of fauces; *E*, tonsils.

The **cartilaginous septum** forming a partition between the nasal fossæ.

The **outer wall of the superior maxillæ** on each side the nose, behind which is the **antrum of Highmore**.

Lightly compress the upper and lower lips between the thumb and finger and note the pulsations of the *coronary arteries*.

Before a looking-glass open the mouth wide and demonstrate (Fig. 4) the **hard palate** forming the anterior half of the roof of the mouth, the **soft palate** behind forming the posterior half.

The **uvula,** the central dependence of the soft palate.

The **pillars of the fauces,** anterior and posterior, two folds

of mucous membrane arching downward on each side from the base of the uvula to the base of the tongue.

The **tonsils** lodged in the sulcus between the anterior and posterior pillars of the fauces.

The **epiglottis** may be seen behind the center of the root of the tongue when it is pulled well forward.

The **circumvallate papillæ** at the posterior part of the tongue, arranged in the form of the letter V with the apex directed backward.

Turn the tip of the tongue upward and note the prominent **ranine veins** on its under surface (Fig. 5).

FIG. 5.—SURFACE MARKINGS OF THE UNDER SURFACE OF THE TONGUE.
A, Ranine veins; *B*, frenum; *C*, submaxillary glands; *D*, orifice of Wharton's duct.

The **frenum,** a fold of mucous membrane extending from the under surface of the tongue to the mouth.

The **sublingual glands,** beneath the mucous membrane of the floor of the mouth on each side of the frenum, forming an oblong ridge.

The **orifice of Wharton's duct** opening on the summit of a small papilla at the side of the frenum.

Demonstrate in the neck the following points:

The **principle structures** in the middle line of the neck can be easily palpated. Beginning from above (Fig. 6)—

The **hyoid bone** can be felt beneath the lower jaw; the body in the center and the great cornua on the sides.

The **thyroid cartilage**—"Adam's apple"—forms the most prominent landmark in the middle line of the neck.

The **cricothyroid membrane,** beneath the lower border of the thyroid cartilage and forming a slight depression between it and the cricoid cartilage below.

Through this membrane a rapid "tracheotomy" may be performed in case of emergency.

The **cricoid cartilage** below marks the beginning of the esophagus, as well as the trachea.

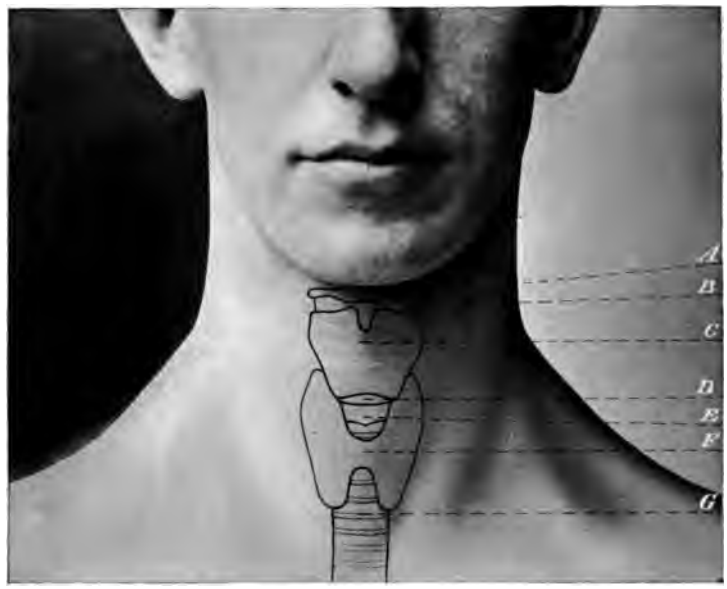

FIG. 6.—SURFACE MARKINGS OF THE ANTERIOR PART OF THE NECK.
A, Hyoid bone; *B*, thyrohyoid membrane; *C*, thyroid cartilage; *D*, cricothyroid membrane; *E*, cricoid cartilage; *F*, thyroid isthmus; *G*, trachea.

The **trachea,** below the cricoid, and palpable as far as the sternal notch.

On the side of the neck palpate—

The **sternomastoid muscle,** extending diagonally across the neck from the mastoid process to the sternum—the most important landmark of the neck. The anterior border corresponds to the course of the great vessels. At a point opposite the upper border of the thyroid cartilage the common carotid bifurcates into the internal and external carotids.

The **"carotid tubercle,"** the prominent tubercle on the

transverse process of the sixth cervical vertebra may be palpated opposite the cricoid cartilage.

Practice compression of the carotid artery against the "carotid" tubercle.

Behind the sternomastoid palpate the **cords of the brachial plexus,** making them prominent by pulling down the arm and drawing the head to the opposite side.

The **subclavian artery** may be demonstrated by standing behind a living subject and inserting the thumb at the junction of the sternomastoid and clavicle. By pressing downward and inward the pulsations may be felt and the artery compressed against the first rib.

CHAPTER II

THE SCALP

THE **scalp** consists of the soft parts covering the bony vault of the cranium. It extends from the superior curved line of the occipital bone, behind, to the superciliary ridges in front; on the sides to the temporal ridges. It may be divided into five layers, although the scalp proper is formed by the union of the first three (Fig. 7).

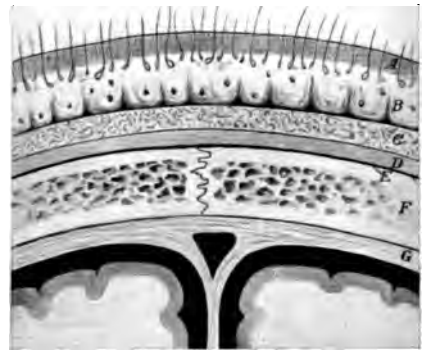

FIG. 7.—SECTION SHOWING LAYERS OF SCALP AND STRUCTURES BENEATH.
A, The skin; *B*, the superficial fascia; *C*, the occipitofrontalis; *D*, subaponeurotic layer; *E*, pericranium; *F*, bone; *G*, dura mater.

1. The **skin** is the thickest in the body. It is intimately connected with the occipitofrontalis muscle and aponeurosis by means of the superficial fascia, hence it moves with the muscle. It is rich in sebaceous glands. The excretory ducts of these glands frequently become occluded and give rise to *sebaceous cysts* (wens). These cysts may grow to a considerable size. *They form the most common tumor of the scalp.* They are situated superficial to the occipitofrontalis aponeurosis, and their removal should be accomplished without invading the dangerous area of the scalp.

2. The **superficial fascia** is a fibrofatty layer, very dense, and capable of resisting pressure. Above, it is intimately con-

nected with the skin; below, with the occipitofrontalis aponeurosis. Behind, it is continuous with the superficial fascia of the neck; in front, with the superficial fascia of the face; hence, the readiness with which erysipelas of the scalp extends to these parts.

It contains (*a*) the principal vessels and nerves of the scalp. There are two peculiarities about the arteries of the scalp: first, they are subcutaneous instead of subaponeurotic; second, they lie in channels in the dense fibrous layer to which they are adherent. Hence, in wounds of the scalp hemorrhage is profuse because the artery can neither contract nor retract. It is very difficult to clamp the bleeding vessel. A suture ligature is the best means of controlling the hemorrhage. (*b*) The hair-bulbs which have such a firm attachment in the fascia that the weight of the body may be lifted by grasping the hair. Many instances are recorded where the hair, being caught in the wheels of a machine, the scalp was torn from the skull, the hair-roots remaining intact.

3. The **occipitofrontalis** is the broad musculo-aponeurotic layer which covers the vertex of the skull from occiput to brow. It consists of two flat muscular bellies (occipital and frontal) and an intervening aponeurosis. The *occipital portion*, about 1½ inches in length, arises from the superior curved line of the occipital bone and the mastoid process of the temporal bone. The fibers ascend in a parallel direction to terminate in the aponeurosis.

The *frontal portion* arises from the supra-orbital margin and the external angular process of the orbit. The fibers arch upward over the forehead and meet the aponeurosis at the coronal suture.

The frontal portion is supplied by the facial nerve, the occipital portion by the posterior auricular branch of the facial. Because of its intimate connection with the skin through the superficial fascia, the integument participates in the movements of the occipitofrontalis muscle. Laterally, the aponeurosis is continuous with the temporal fascia below the temporal ridge.

4. The **subaponeurotic layer** consists of loose areolar tissue. Its laxity explains the mobility of the scalp. It permits extensive flaps to be torn loose. The Indian practice of scalping was a simple procedure, since a portion of the scalp was removed above this loose connective tissue. This layer has been called by Treves the *dangerous area of the scalp*, because suppuration within the layer spreads widely. It may undermine the entire

scalp and form beneath it a bed of pus. To provide proper drainage for a phlegmon of this layer, incision should be made above the superior curved line of the occipital, above the eyebrow, or above the zygoma. *Wounds of the scalp* do not gape unless the occipitofrontalis muscle or aponeurosis be involved. Wounds transverse to the direction of the muscle present the greatest amount of gaping.

5. The **pericranium** (external periosteum) is loosely attached to the bone except at the sutures where the union is intimate. The pericranium differs from periosteum in that necrosis of bone follows extensive removal of periosteum, while the pericranium may be removed and the bone survive because of the nutrition it receives through the dura mater; hence, the cranial bones are independent of the pericranium.

Neither the pericranium nor dura mater has the power of reproducing bone as does the periosteum; therefore, in loss of bone in the skull due to operation or necrosis, new bone does not form and the gap is filled in only by connective tissue. The pericranium dips down between the sutures and is continuous with the external layer of dura mater. Thus it forms the *intersutural membrane*. Hence, the products of inflammation beneath the pericranium are confined to one bone. Inflammation of the pericranium may extend to and involve the dura mater through the intersutural membrane.

The **arteries of the scalp** are arranged in pairs. Two anterior—the frontal and supra-orbital; two lateral—the anterior and posterior temporals; two posterior—the posterior auricular and occipital.

The *frontal* is the terminal branch of the ophthalmic. It leaves the orbit at the inner angle and ascends on the forehead, anastomosing with the supra-orbital and the frontal of the opposite side. In the operation of rhinoplasty, where the flap is taken from the forehead to form a new nose, the integrity of this artery assures the vitality of the flap.

The *supra-orbital*, a branch of the ophthalmic, exits through the supra-orbital notch in company with the nerve of the same name. It passes vertically up and anastomoses with the frontal and anterior temporal. In resecting the supra-orbital nerve the artery gives the surgeon little trouble, because of its small size.

The *temporal*, one of the branches of the external carotid, exits from the parotid at the interspace between the condyle of the jaw and the external auditory meatus. It is accompanied

by the auriculotemporal nerve. Two inches above the zygoma it divides into an *anterior* and *posterior*. The anterior anastomoses with the supra-orbital; the posterior anastomoses with the posterior, auricular, and occipital.

The earliest evidence of arterial degeneration is seen in this artery, especially the anterior branch. It is the most frequently wounded of all the arteries of the scalp. Cirsoid aneurysm more frequently affects the superficial temporal than any other artery of the body. The superficial temporal is always a convenient vessel for the anesthetist to feel the pulse, more especially when the radial is not handy.

The *posterior auricular*, a branch of the external carotid. It passes over the mastoid process and divides into an anterior and posterior branch. The anterior anastomoses with the posterior temporal, the posterior with the occipital.

The *occipital*, a branch of the external carotid and a vessel of some volume. It pierces the trapezius muscle at its attachment to the superior curved line at a point midway between the external occipital protuberance and the mastoid process. It anastomoses with (*a*) the posterior temporal; (*b*) the posterior auricular; (*c*) the occipital of the opposite side. All the arteries of the scalp go from base to apex and form a complete anastomosis. An extremely active circulation results.

Peculiarities of Arteries of the Scalp.—(*a*) They are subcutaneous instead of subaponeurotic; hence, they are more superficial than arteries of the same caliber in other parts of the body. (*b*) They are lodged in channels in the subcutaneous fibrous tissue and are adherent to the walls of these channels; hence, they do not retract after being cut, or diminish in caliber; on this account wounds of the scalp, even when small, are followed by profuse hemorrhage.

Treatment of Hemorrhage from the Scalp.—Because of the fibrous character of the tissue in which the arteries lie, clamp and ligature are unsatisfactory. It is difficult to seize the bleeding point with a clamp, and it is almost impossible to prevent the ligature from slipping off. The two methods of control most satisfactory are (*a*) compression. The vessels lying in channels directly over a plane of bone; this means is always efficacious. In operations on the scalp a tourniquet of rubber tubing applied to the base of the scalp will render the operation almost bloodless. (*b*) Suture ligature. A needle threaded with catgut and passed under the bed of the artery anchors the ligature in place and secures satisfactory control.

Wounds of the Scalp.—While they bleed profusely, they heal rapidly and possess a high vital resistance against infection. According to their depth they may be (*a*) supra-aponeurotic in which there is no tendency for the edges of the wound to separate and, if small, needs neither suture nor drainage, and (*b*) sub-aponeurotic, in which the edges have a tendency to separate, the more so if the wound be transverse to the direction of the aponeurosis. Drainage should always be employed, because the "dangerous area" is exposed.

Because of the vascularity of the scalp, large flaps may be torn loose without danger of gangrene, and healing usually ensues when the flap is replaced.

The **veins of the scalp** are of three classes:

(1) *Superficial*, usually accompany the corresponding arteries in the superficial fascia.

(2) *Diploic*, traverse the diploe (the spongy osseous tissue between the two tables of the skull) (see Fig. 9). They possess only an internal covering, find their greatest development in the aged, and communicate with the venous sinuses internally and the superficial veins externally, by means of the emissary veins.

(3) *Emissary*, pass through foramina in the skull and establish communication between the veins of the scalp and the sinuses of the brain.

The two most important are—

1. A vein which passes through the parietal foramen to reach the superior longitudinal sinus.

2. A vein which traverses the mastoid foramen to reach the lateral sinus. The application of leeches behind the ear thus abstracts blood directly from the intracranial circulation.

Other smaller veins traverse the various foramina and the scalp also possesses minute veins communicating with the diploe. There is, therefore, a complete venous anastomosis between the veins of the scalp, the veins of the diploe, and the sinuses of the brain. Hence, infections of the scalp may in this way be carried to the brain and meninges.

All infections of the scalp are dangerous, because of the direct communication between the extra- and intracranial venous circulation (Fig. 8). If there were no emissary veins, injuries and diseases of the scalp would lose half their seriousness (Treves).

Nerves of the Scalp.—The sensory nerves are of interest because they are frequently the seat of neuralgias. They are the branches of the trifacial and the cervical plexus. The following are the most important:

1. *Supra-orbital nerve,* a branch of the frontal from the ophthalmic division of the fifth, passes through the supra-orbital notch in company with the artery, ascends on the forehead and terminates in cutaneous and pericranial branches. In supra-orbital neuralgias this nerve has been resected at its point of exit from the orbit (at junction of inner and middle thirds of upper margin of orbit).

FIG. 8.—ANASTOMOSIS BETWEEN THE EXTRA- AND INTRAVENOUS CIRCULATION.

2. *Supratrochlear,* a branch of the frontal from the ophthalmic. It passes inward above the pulley of the superior oblique, curves up on the forehead 1 cm. from the median line, supplies the skin of lower part of forehead on either side of the median line, and the skin of the upper lid.

3. *The auriculotemporal nerve,* a branch of the inferior maxillary division of the fifth. It ascends with the temporal artery between the external ear and the condyle of the jaw. It supplies the integument of the temporal region, the skin lining the meatus, and that covering the helix and tragus. In resection of this nerve, the superficial temporal artery is the guide alongside of which the nerve lies. It is found in front of the tragus at the base of the zygoma.

4. *The great occipital nerve,* the internal branch of the second cervical. It pierces the trapezius near its attachment to the cranium in company with the occipital artery. It supplies the integument of the scalp as far forward as the vertex. This nerve is sometimes the seat of cervical neuralgia. In resection the occipital artery is the guide to its exposure.

The **lymphatics** form three distinct groups:

(*a*) *Frontal* empty into the parotid ganglia. Some join the lymphatics of the face end in the submaxillary glands.

(*b*) *Parietal,* more voluminous than the preceding, empty into the mastoid ganglia.

(*c*) *Occipital,* pass directly back and empty into the sub-

occipital ganglia. Some may reach the ganglia under the sternomastoid and sometimes the submaxillary group.

The scalp in the temporal region differs from that already described by the interposition of the temporal fascia and the temporal muscle.

The **temporal fascia** is a shining, white, fan-shaped fascia, to whose under surface are attached the superficial fibers of the temporal muscle. Above, it is attached to the entire extent of the temporal ridge; below, it divides into two layers, the outer layer being attached to the external border and the inner to the internal border of the zygomatic arch.

Between the two layers is a small quantity of fat, the orbital branch of the temporal artery, and a filament from the superior maxillary nerve (Gray). *Because of the density of this fascia abscesses beneath rarely point to the surface, but burrow into the pterygoid and maxillary regions, appearing in the mouth or neck.*

The **temporal muscle** is a broad, triangular muscle occupying the temporal fossa. It is inserted into the bony wall of the temporal fossa and the under surface of the temporal fascia. The fibers converge to a tendon which is inserted into the apex and inner surface of the coronoid process of the inferior maxillary bone as far as the last molar tooth.

The inferior portion of the muscle is covered by a mass of fat, which diminishes with disease, and causes the deep depressions above the zygomatic arch seen in people with wasting diseases. The pericranium of the temporal fossa is much thinner and more intimately adherent to the bone than over the vertex. Hence, in this region we do not get subperiosteal collections of blood and pus.

Collections of Blood or Pus in the Scalp.—They may be (*a*) *subcutaneous;* they then are limited, and result from a bruise or superficial infection and are ordinarily of little moment.

The subcutaneous collections of blood may be the source of an error in diagnosis. The center softens and the circumference becomes prominent and hard, simulating a bony edge with a soft depression in the center, hence the condition is not infrequently mistaken for depressed fracture.

(*b*) *Subaponeurotic* ("Dangerous Area").—The blood infiltrates with great facility between the aponeurosis and pericranium. If the bleeding is not arrested the soft parts are completely denuded from the vault of the cranium. Subaponeurotic abscess is rare. Pus, like blood, spreads in all directions, the damage is considerable, and the condition

demands prompt incision, thorough drainage, and immobilization of the scalp.

(c) *Subperiosteal* collections are limited to one bone because of the intersutural membrane.

The *caput succedaneum* of the newborn is a subperiosteal hematoma caused by pressure during the passage of the fetus. Subperiosteal collections of pus may extend and involve the dura mater through the intersutural membrane.

Tumors of the Scalp.—All tumors above the aponeurosis are freely movable. All immovable growths are below the aponeurosis. *The most frequent tumor of the scalp is the sebaceous cyst or wen.* They may attain a large size and are frequently multiple. Situated in the skin, they are freely movable and may be excised without opening the aponeurosis.

Papillomas are frequent outgrowths from the skin of this region.

Lipomas are rare; when present they originate in the superficial fascia and are usually found in the occipital region.

Dermoid cysts are situated beneath the aponeurosis in a shallow trough of bone and are not movable. They occupy favorite sites, such as the glabella, the outer wall of the orbit, the temporoparietal region, and the mastoid region. They are congenital, of slow growth, and usually appear after puberty. If the bony floor be entirely absorbed the cyst will then receive the pulsations from the dura mater upon which it lies.

Aneurysm of the scalp may be the result of traumatism (punctured wounds) affecting the branches of the external carotid, principally, the temporal.

Cirsoid aneurysm has a predilection for the scalp. It is most frequently seen in the superficial temporal arteries. The artery lengthens, dilates, and becomes very tortuous. There sometimes appear *blood tumors* which are connected with the intracranial circulation through congenital defects in the cranium. They communicate either with the sinuses or the diploic veins. They are reducible, receive faint pulsation from the brain, disappear when the patient stands, and appear when lying down. If they are present in the median line they are probably connected with the superior longitudinal sinus.

Carcinoma may originate in the sebaceous glands and hair-follicles, and resembles rodent ulcer in its characteristics.

Sarcoma of the scalp is rare, and is usually secondary to sarcoma of the periosteum, diploe, or dura.

CHAPTER III

THE BONY VAULT OF THE CRANIUM

THE cranium is a hollow sphere composed of eight bones: the frontal, ethmoid, sphenoid, occipital, two parietal and two temporal. Besides, we have the *Wormian* bones, usually occupying the superior and posterior angle of the parietal which sometimes being movable, may easily be mistaken for fragments of a fractured bone.

The *epipteric bone* is a Wormian bone which is situated between the anterior inferior angle of the parietal bone and the great wing of the sphenoid. Situated in the "fracture area," it may be mistaken for a fragment of the tip of the sphenoid wing.

The bones of the cranium differ in thickness in different locations and in different subjects. They are thickest at the occipital protuberance, the mastoid process, the inferior portion of the frontal. Thinnest at the occipital fossæ, the temporal fossae, and at points corresponding to the sinuses and the bony grooves which lodge arteries. In applying the trephine and in fracture of the skull it is important to keep these points in mind.

The cranial bones are united by means of sutures, principally of the dentate form, the serrated borders dovetailing with each other. The squamous type of suture is formed by the overlapping of bones over another, as seen in the squamous portion of the temporal overlapping the parietal. Between the sutures the pericranium dips down and forms the intersutural membrane.

At birth the cranial bones are not united. They gradually grow together and practically form one bone. This union begins at the fourteenth year and is completed about the fortieth.

When union takes place too early, due to the arrest of development of the brain, a condition of *microcephalus* is produced. Lannelongue has proposed to relieve this condition by excising strips of bone on each side of the vertex of the skull (craniotomy) to allow the brain to expand. The results do not

justify this procedure, nor is it founded on scientific facts, since the undeveloped brain is the *cause* and not the *result* of the microcephalic skull.

The cranium is elastic because of the number of bones of which it is composed and the cushion of intersutural membrane between them. Its elasticity diminishes as age increases. Fracture of the skull in children is rare; in the aged it is frequent. Treves has compared the skull of an infant to that of an old man as a cranium of tin would be to a cranium of earthenware. A blow that would dent the one would crack the other.

Structure of Cranial Bones.—They are composed of two bony tables with an intermediary spongy tissue between, the *diploe*, in which ramify the diploic veins (Fig. 9).

The *outer table* is formed of compact bone of a certain thickness and is very elastic.

FIG. 9.—SHOWING THE TABLES OF THE SKULL.

The *inner table*, formed of compact bone, is thinner and whiter. Its surface is irregular, being grooved for the lodgment of the meningeal vessels. It is very brittle and possesses no elasticity.

The elasticity of the outer table, the brittleness of the inner table, and the intervening diploe explains the peculiar results following blows on the skull which will receive further attention when we consider fractures of the skull.

Peculiarities in the Nutrition of the Cranial Bones.—The pericranium forms an external periosteum, the dura mater an internal periosteum, and between the two tables ramify the diploic veins.

The pericranium is loosely attached to the bones at the vault of the cranium. If it be stripped from the bone necrosis does not follow, nor does necrosis follow if the bone be deprived of dura mater.

Neither the pericranium nor the dura mater have the power of forming new bone. When a portion of bone is removed the gap is not filled by new bone; the cicatrix of the skin adheres to the dura and closes the opening.

Necrosis of the vault of the skull is quite common. The outer table having less nutrition than the inner table is more frequently affected. Necrosis may give rise to thrombophlebitis and pyemia of the intracranial circulation, or to meningitis.

FRACTURES OF THE SKULL

The skull in children is not easily fractured. The bones are elastic, ossification is incomplete—a blow that would fracture the adult skull will simply indent the skull of a child.

Predisposition to fracture of the skull increases with age. After the fortieth year ossification is complete and the cranium may be considered one bone.

There are, however, certain features of architecture and mechanism which act as a protection and render fracture of the skull less frequent.

The anatomical reasons given by Treves are:

1. The density and mobility of the scalp.
2. The dome-like arrangement of the vault.
3. The number of bones that compose the head causes the violence to be broken up among many segments.
4. The sutures interrupt the continuity of any given force.
5. The intersutural membrane acts as a linear buffer.
6. The mobility of the head.
7. The elasticity of the bones themselves.

In fracture of the skull the broken bone, per se, is of little moment; it is the injury to the soft parts within the skull that gives to this lesion sequelæ of special gravity.

Linear fracture is frequently unrecognized, produces no symptoms, and repair proceeds without interruption. When the fragments are depressed and, as is usual, associated with a wound of the scalp, pressure effects are produced by the fragments themselves, or by a blood-clot from the lacerated arteries or veins. The brain tissue itself may be irreparably damaged, and the entrance of micro-organisms may later give rise to cerebral abscess.

Fractures of the vault are produced by direct violence. The elasticity of the outer table, the brittleness of the inner table, and the intervening diploe explain the peculiar results following blows on the vault of the skull.

We can never form an exact idea of the extent of a fracture from the condition of the outer table.

There may be a fracture of the inner table without the integrity of the outer table being destroyed (Fig. 10).

There may be a simple fissure of the outer table and a multiple fracture of the inner table.

There may be a fracture of the outer table depressed into the diploe, with the inner table intact (Fig. 11).

FIG. 10.—FRACTURE OF THE INNER TABLE WITH OUTER TABLE INTACT.

Both tables may be fractured and depressed (Fig. 12).

Fractures of the Base of the Skull and the Relations of the Structures Involved.—On the inner surface of the base of the skull are three fossæ: the anterior, middle, and posterior, arranged like three steps, the anterior being the highest, the middle next, and the posterior the lowest.

FIG. 11.—FRACTURE OF THE OUTER TABLE WITH THE INNER TABLE INTACT.

The **anterior fossa** lodges the frontal lobes, which rest directly upon the thin orbital plates. The olfactory bulbs lie upon the cribriform plate of the ethmoid, sending filaments to the nasal cavity.

Fractures of the anterior fossa may occur indirectly by extension from blows on the forehead (85 per cent. of basic fractures originate in the vault—Scudder), or directly by foreign bodies being thrust through the thin orbital plates, or through the cribriform plate of the ethmoid by way of the

nose. Fractures of the anterior fossa may be followed by subconjunctival ecchymosis; blood and cerebrospinal fluid may flow from the nose. Pressure on the olfactory nerve may cause loss of smell; pressure on the optic nerve blindness on the affected side.

The **middle fossa** lodges the temporal lobe. The relation of the brain to the mastoid antrum, separated only by a thin plate of bone—the tegmen tympani—explains the frequency of abscess of the temporal lobes resulting from middle-ear disease.

The posterior border of the lesser wing of the sphenoid corresponds to the fissure of Sylvius.

The **cavernous sinus** is lodged in a groove on each side of the sella turcica. The internal carotid artery, the third,

FIG. 12.—BOTH TABLES FRACTURED AND DEPRESSED.

fourth, ophthalmic division of the fifth, and sixth nerves are within the walls of the sinus.

Traumatism or fracture of the base in this region may be the cause of a communication between the artery and the sinus resulting in an arteriovenous aneurysm which, because of its situation, produces a *pulsating exophthalmos.*

The **Gasserian ganglion** is lodged in an osteofibrous space (the cave of Meckel) near the apex of the petrous portion of the temporal bone. On its upper surface is the dura mater, intimately adherent. From it is given off its three large branches: the *ophthalmic*, passing through the sphenoidal fissure, the *superior maxillary* through the foramen rotundum, and the *inferior maxillary* through the foramen ovale. The first and second divisions are purely sensory, the third is joined by a motor root outside the cranium, and is both motor and sensory. The Gasserian ganglion is removed for intractable facial neuralgia (see pp. 77 and 78).

Fractures of the Middle Fossa.—The middle fossa is the most common place for fracture of the base occurring indirectly from extension of fractures of the parietal region of the skull or by blows on the chin causing a violent impact of the condyle of the jaw against the glenoid cavity. In fractures by extension the petrous portion of the temporal bone is frequently involved, giving rise to injury of the *facial* and *auditory* nerves. Twenty-five per cent. of all fractures of the base involve these nerves.

The arachnoid surrounding the nerves may be torn and the internal ear so injured as to allow cerebrospinal fluid and blood to flow from the ear.

The fractures may involve the body of the sphenoid and blood find its way into the pharynx. The nerves which may be involved by traumatism or pressure in the middle fossa are:

The Motor Oculi.—Followed by ptosis, slight exophthalmos, dilated pupil, and external strabismus. The eyeball cannot be moved upward, downward, or inward. The eye deviates outward, accommodation is paralyzed.

The Trochlear.—Eyeball cannot be turned downward. The eyeball is deviated upward and slightly inward. Patient complains of double vision.

The Trifacial.—Loss of sensation in the face and cornea. Loss of the power of mastication. Paralysis of the masseter, pterygoid, and temporal muscles.

The Abducens.—The eyeball cannot be turned outward, there is internal strabismus and diplopia.

When the petrous portion of the temporal bone is fractured there is likely to be an involvement of facial and auditory nerves.

The Facial.—Followed by complete paralysis of the muscles of expression, the soft palate, and orbicular muscles of the mouth and eye. The face is smooth and expressionless on the affected side. the eyelid cannot be closed. If the patient attempts to smile or whistle the face is drawn over to the sound side. If he tries to swallow fluids, they dribble from the mouth on the affected side.

The Auditory.—Deafness on the affected side.

The **posterior fossa** lodges the cerebellum.

In the center is the foramen magnum, transmitting the lower portion of the medulla, the spinal accessory nerves, and the vertebral arteries.

Above and passing downward and forward are the deep grooves which lodge the *lateral sinuses* and terminate in the jugular foramen.

Fractures of the posterior fossa may be caused by falls upon the buttock, knees, or feet, the violence causing an impaction of the spinal column against the condyles of the occipital bone; or it may result from extension of fractures of the occipital region of the skull. Extravasation of blood takes place beneath the deep fascia and ecchymotic spots may be seen along the course of the posterior auricular artery and over the tip of the mastoid process.

The nerves which may be involved are the glossopharyngeal, pneumogastric, spinal accessory, and hypoglossal, giving rise to bulbar symptoms, indistinct articulation, atrophy of the tongue, difficulty in swallowing, paralysis of the sternomastoid and trapezius (Eisendrath).

Craniotabes is a condition found in rickety children and tertiary syphilis. It consists of a softening of circumscribed areas of bone in the cranium. These areas when pressed upon by the finger, feel like wet parchment.

The cranial bones are also affected by syphilitic and tubercular diseases. Osteoma and sarcoma are sometimes found in these bones.

The tumors which arise from lack of development of the cranial bones will be discussed under Tumors of the Brain.

CHAPTER IV

THE CRANIAL CONTENTS

THE soft parts of the cranial cavity consist of—

(*a*) The envelopes or membranes.

(*b*) The cerebrospinal fluid.

(*c*) The brain.

The membranes of the brain are three:

1. The dura mater—the membrane of protection.
2. The arachnoid—the membrane of adjustment.
3. The pia mater—the membrane of nutrition.

The **dura mater** is the thickest and most external of the three membranes of the brain. It forms a fibrous covering for the brain and has a fourfold function.

1. *It forms the internal periosteum of the skull.* Through this means the bones of the skull receive a large part of their nourishment, and for this reason necrosis does not follow when the bones are denuded of pericranium.

FIG. 13.—COMPRESSION OF THE BRAIN CAUSED BY COLLECTION OF BLOOD OR PUS BETWEEN THE BONE AND THE DURA MATER.

The external surface of the dura mater is adherent to the bones of the cranium, but not to the same extent in all parts. It is loosely attached to the vault of the cranium, except along the sutures and around the foramina; hence collections of blood or pus may form between the bone and the dura and cause compression (Fig. 13).

It is intimately attached to the base of the skull, especially at the bony prominences; hence collections of blood and pus

between the skull and the dura rarely, if ever, occur at the base.

The *Pacchionian bodies* are small projections, usually in clusters, found on the surface of the dura mater in the neighborhood of the superior longitudinal sinus. They cause depressions on the inner surface of the skull bone. At times they become so large as to cause pressure enough to give rise to focal epilepsy. Deaver has trephined to relieve this condition. While they appear to originate in the dura, they are really villous processes of the arachnoid which push the dura mater before them. They serve as channels for the passage of the cerebrospinal fluid into the venous sinuses of the dura mater and in this way relieve intracranial pressure from excess of cerebrospinal fluid.

FIG. 14.—THE RELATIONS OF THE MIDDLE MENINGEAL ARTERY TO THE SKULL.

The **middle meningeal artery** is the most frequent source of epidural hemorrhage, and its relation to the dura is of great surgical importance (Fig. 14). It is a branch of the internal maxillary and enters the cranium through the foramen spinosum. At the anterior inferior angle of the parietal bone it divides into two branches, anterior (the larger) and posterior.

The artery lies between the skull and the dura. It is lodged in bony grooves and is adherent to the dura. Fracture of this portion of the skull is apt to be accompanied by rupture of the artery, and the subsequent effusion of blood between the dura and the skull forms a clot that compresses the brain. This pressure over the motor tract will be followed by symptoms of paralysis.

Epidural hemorrhage has for its seat of election the lateral

regions of the cranium, because (*a*) the principal branches of the middle meningeal artery are in the temporal region; (*b*) the dura mater is loosely attached at this point; (*c*) fractures are most frequent at this point because of the thinness of the bone.

The two causes of epidural hemorrhage are contusion and fracture. A contusion may produce a tearing of the dura mater and rupture of the artery and the rupture of the artery may occur on the opposite side from the trauma. A hemorrhage occurring in this way is known as *hemorrhage contre-coup.*

The symptoms of compression from epidural hemorrhage *do not appear immediately,* as in depressed fracture. They appear after a few hours, since an interval of time must elapse before a clot is formed sufficiently large to produce pressure symptoms.

Diagnosis of the cause of compression may be made by observing the interval of time which elapses between the traumatism and the appearance of compression symptoms. *If the symptoms appear immediately, depressed bone is the cause. If they appear a few hours after, hemorrhage is the cause. If they appear a few weeks after, abscess is the cause.*

The *treatment of epidural hemorrhage* is to trephine for removal of clot and arrest of hemorrhage. The point of election for placing the trephine in suspected hemorrhage from the middle meningeal is a point two fingers'-breadth above the midpoint of the zygoma.

2. The dura mater forms three partitions for the support of the lobes of the brain and to prevent the lobes compressing each other in the different positions of the head.

(*a*) The **falx cerebri** is a sickle-shaped process of dura mater which forms a vertical partition between the two hemispheres of the brain. Its narrowest part in front is attached to the crista galli of the ethmoid bone, behind it joins the tentorium at a right angle. Its upper convex margin is attached to the inner surface of the skull in the median line as far back as the internal occipital protuberance. In this margin is contained the *superior longitudinal sinus.* Its lower margin is free and concave and contains the *inferior longitudinal sinus.* At the line of junction of the falx cerebri and the tentorium runs the straight sinus (Fig. 15).

(*b*) The **tentorium** is a horizontal partition of dura mater which forms a tent-like roof, crescentic in form, covering the upper surface of the cerebellum and supporting the occipital

lobes of the brain. Its convex margin, behind, is attached to the inner surfaces of the occipital bone, represented by a line drawn from the external occipital protuberance to the external auditory meatus. In this border, on each side, is enclosed the lateral sinus. Its upper surface joins at a right angle the posterior margin of the falx cerebri.

In front it is attached to the upper margin of the petrous portion of the temporal bone and encloses, on each side, the superior petrosal sinus. It is continued forward and attached

FIG. 15.—THE FALX CEREBRI AND TENTORIUM, AND THE RELATION OF THE SINUSES.

to the anterior and posterior clinoid processes of the sphenoid bone.

(*c*) The **falx cerebelli** is a vertical partition of dura mater which separates the two lobes of the cerebellum. Its posterior margin is attached to the crest on the inner surface of the occipital bone.

3. **Sinuses.**—*The dura mater forms the sinuses or venous canals which return the blood from the head.* One of the peculiarities of the cerebral circulation is the formation within the dura mater of these triangular spaces in which circulates the venous blood. These canals are formed by splitting the dura mater into two layers (Fig. 16). They are adherent for the most part to the walls of the cranium. When cut they remain open. They have no valves, but present irregular partitions.

The sinuses receive tributary veins from the dura mater, from the pericranium, and from the diploe; hence, there is an active communication between the intra- and extracranial circulation. All the blood from the sinuses finally flows into the internal jugular vein.

The sinuses are situated superiorly and posteriorly and are in relation with the bones of the cranium. The arterial trunks are situated anteriorly and inferiorly, and are in contact with the brain substance.

There are fifteen of these sinuses, which may be divided into two groups: (1) the five single sinuses; (2) the five pairs.

The former are: superior longitudinal, inferior longitudinal, circular, transverse, and straight. The latter are: lateral,

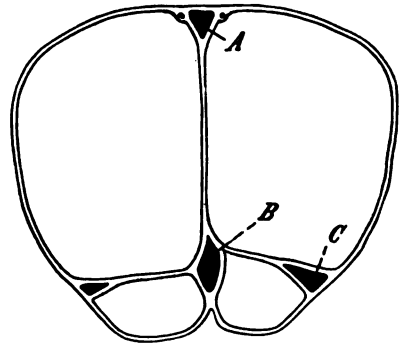

FIG. 16.—SHOWING THE SPLITTING OF THE DURA MATER TO FORM THE WALLS OF THE SINUSES.
A, Superior longitudinal sinus; *B*, straight sinus; *C*, lateral sinus.

superior petrosal, inferior petrosal, cavernous, and occipital (Fig. 17). The sinuses of special interest to the surgeon are the superior longitudinal, the lateral, and the cavernous.

The **superior longitudinal sinus** runs along the attached border of the falx cerebri. It begins at the foramen cecum, through which it receives a vein from the nasal fossa, courses from before backward, grooving the middle of the frontal bone and the adjacent edges of the parietals, and, descending on the occipital, it terminates in the torcular Herophili, opposite the internal occipital protuberance.

The torcular Herophili is the dilated extremity of the superior longitudinal sinus, into which empty the lateral, straight, and occipital sinuses.

In its course the sinus receives the superior cerebral veins and a pericranial branch through the parietal foramen.

The **course of the sinus** is marked on the scalp by a straight line drawn from the root of the nose, over the median line of the vertex, to the external occipital protuberance.

FIG. 17.—SCHEME SHOWING THE SINUSES AND THEIR ANASTOMOSES WITH THE EXTRA-CRANIAL VENOUS CIRCULATION. (After Macewen.)

A, Superior longitudinal sinus; *B*, lateral sinus; *C*, inferior longitudinal sinus; *D*, cavernous sinus; *E*, superior petrosal sinus; *F*, inferior petrosal sinus; *G*, occipital sinus; *H*, subclavian vein; *I*, internal jugular vein; *J*, external jugular vein; *K*, facial vein; *L*, supra-orbital vein; *M*, posterior external jugular vein; *N*, vertebral vein.

Surgical Considerations.—In applying the trephine to the skull it is necessary to avoid the line which marks the course of the sinus.

Compound fractures of the skull in the median line may involve the sinus and give rise to abundant hemorrhage. The best means of controlling this hemorrhage is by the use of iodoform gauze packing. If the rent in the sinus be small it may be sutured.

Infections of the scalp may be carried into the sinus by means of the parietal emissary veins. Septic processes in the nose may be carried by the nasal vein, which has direct communication with its point of origin.

Headache due to cerebral congestion may be relieved by

epistaxis or by leeching the nose, because of the nasal communication with this sinus.

The **lateral sinuses** are the largest of the cranial sinuses and through them all the venous blood from the brain is returned to the jugular veins.

In describing the course of the lateral sinuses we may divide it into two portions: a *horizontal* and *sigmoid* (see Fig. 17). The *horizontal portion* commences at the internal occipital protuberance and takes a horizontal course, running along the attached border of the tentorium cerebelli in a groove of the occipital and posterior inferior angle of the parietal, as far as the mastoid portion of the temporal bone.

The Sigmoid Portion.—On reaching the mastoid portion of the temporal, the sinus leaves the tentorium and makes a bend forming the "knee" of the sinus. Its direction is then downward, inward, and forward. It grooves the mastoid and ends

FIG. 18.—LINES ON THE SURFACE OF THE SKULL REPRESENTING THE COURSE OF THE LATERAL SINUS.

at the jugular foramen in the internal jugular vein. The S-shaped portion of the sinus which grooves the mastoid is sometimes referred to as the *sigmoid sinus.*

The two lateral sinuses are not of equal size. The right is usually large and receives the blood from the superior longitudinal sinus, while the left is smaller and empties the straight sinus.

The **course of the lateral sinus** is indicated on the scalp: the horizontal portion by a line drawn from the external occipital protuberance to the base of the mastoid process and the sigmoid portion by a line from the base of the mastoid to its tip (Fig. 18).

The lateral sinus in its course receives various tributaries:

(*a*) The superior petrosal sinus joins it at the bend of the "knee."

(*b*) The inferior petrosal at its termination in the jugular vein.

(*c*) The mastoid vein and—

(*d*) The posterior condyloid vein form a communication with the pericranium.

(*e*) The inferior cerebral, the inferior cerebellar, some diploic veins, and, frequently, veins from the internal ear also join the sinus.

Surgical Considerations.—*Leeching.*—The proper place to apply a leech in meningitis is behind the ear; thus, blood is directly abstracted from the lateral sinus through the mastoid vein. Another, but less favorable site, is the inner canthus of the eye, where blood may be abstracted from the cavernous sinus by the anastomosis between the angular and ophthalmic veins.

Septic thrombosis of lateral sinus may follow middle-ear disease. The sigmoid is the portion most frequently involved. If, in mastoid disease, the antrum has been opened and drained without satisfactory results, the sigmoid portion of the lateral sinus should be opened and the infected clot removed. The internal jugular vein should be ligated to prevent the dissemination of the infected clot.

Trephining the Lateral Sinus.—This is done for septic thrombosis following middle-ear disease, and the sigmoid portion of the sinus is the part exposed. This condition being a complication of mastoid disease, the mastoid is usually opened first and the sinus subsequently exposed by removing the intervening bone.

Before removing the clot from the sinus the internal jugular vein should be ligated to prevent the dissemination of septic emboli. For primary exposure of the sigmoid sinus the following landmarks are useful. Draw a line vertically bisecting the mastoid from base to tip. Make the opening on this line between the parallels of the roof and floor of the external auditory meatus.

It is well to remember that the two lateral sinuses are not of equal size. The right is usually larger. The right sigmoid groove is deeper and reaches further forward; hence, in right-sided otitis media intracranial lesions are more frequent because the sigmoid portion of the right lateral sinus is nearer the middle ear.

Relation of the Sinus to the Mastoid Antrum.—The mastoid antrum lies a little above and *behind* the external auditory meatus, in a space represented by the suprameatal triangle (Fig. 19). *Behind* the mastoid antrum lies the bend

of the sigmoid part of the lateral sinus. Macewen gives the following guide: In the adult a vertical line, drawn ½ inch behind the posterior bony wall of the external auditory meatus and between the levels of the roof and the floor, will, in the majority of cases, indicate the position of the anterior convexity of the sigmoid portion of the lateral sinus.

Trephining Mastoid Cells.—A number of landmarks have been proposed in opening the mastoid, of which two seem the most practical:

(*a*) Trephine through the suprameatal triangle.

(*b*) Deaver proposes to draw a horizontal line through the roof of the external auditory meatus and a vertical line through the posterior wall. Place the trephine in the angle.

Whatever landmarks may be selected, there is one invariable rule to follow, viz.: *Hug the posterior wall of the bony meatus.* Whatever the operative procedure, the work will be facilitated

FIG. 19.—WHITE DOTTED LINE SHOWS SUPRAMEATAL TRIANGLE.

by making such an incision as will expose the entire mastoid process rather than attempt to work through the time-honored vertical incision behind the ear.

The **cavernous sinus** is so called because of the interlacing filaments within. The sinuses are situated on each side of the sella turcica. They are triangular in shape and extend from the sphenoidal fissure to the apex of the petrous bone. In front they receive the ophthalmic vein, behind they empty into the petrosal sinuses. On the sides they communicate with each other through the circular sinus. Within, but separated from the blood current by the lining membrane, which is continuous with the outer coat of the veins, are the third, fourth, and ophthalmic division of the fifth nerves on the outer wall, the internal carotid artery with the sixth nerve on the inner wall.

Surgical Considerations.—The cavernous sinus is more rarely affected by thrombosis than the other large sinuses.

When infection takes place it is frequently accompanied by basilar meningitis. The possible sources of infection are from inflammation in the orbital cavity, infections of the face, erysipelas, etc., through the ophthalmic vein; ulcerations of the tonsil and pharynx through the pterygoid plexus; and inflammations in the maxillary, frontal, ethmoidal, and sphenoidal sinuses. A case of thrombosis is reported from an alveolar periostitis following the extraction of a wisdom tooth.

While at the onset one sinus only is affected, the inflammation usually spreads through the circular sinus to the sinus of the opposite side. The cavernous sinus is separated from the sphenoidal sinus by a thin bony wall. A wound of the cavernous sinus which involves this partition may be followed by fatal hemorrhage from the nose. An arteriovenous aneurysm may be formed between the cavernous sinus and the internal carotid artery, giving rise to exophthalmos and a pulsating tumor of the orbit. Such a condition may be caused by traumatism (bullet or stab wound, or fracture of the base) or by a diseased condition of the coats of the artery. It is well to keep in mind, however, that pulsating tumor of the orbit may also be caused by an aneurysm of the orbital artery.

4. The dura mater forms a sheath for the nerves as they leave the skull.

The **arachnoid** (the membrane of adjustment) is a delicate serous membrane separating the fibrous dura mater from the vascular pia mater. It forms a loose investment for the brain and is continued down over the cord. It does not dip into the fissures and sulci except into the great longitudinal fissure. It is prolonged upon the nerves as a sheath.

Subarachnoid space is the interval between the arachnoid and pia mater in which circulates the cerebrospinal fluid. This space is very insignificant on the convexity of the skull, but very extensive at the base of the skull, beneath the cerebellum, medulla, pons, and as far forward as the optic nerves. Hence, as Hilton has observed, the most important parts of the brain do not rest upon bone, but upon the subarachnoid fluid which practically serves the purpose of a "water-bed."

The anterior third is the only part of the brain resting directly upon bone, *i. e.*, the orbital plates of the frontal bone. The posterior two-thirds of the brain does not lie directly upon bone, but upon the cerebrospinal fluid.

Cerebrospinal fluid circulating between the arachnoid and pia mater completely envelops the cerebrospinal axis,

surrounds the brain and spinal cord, penetrates the ventricular cavities, and plays an important rôle in the physiology and pathology of the brain and cord.

It is a clear, limpid fluid, very rich in chlorid of sodium. It contains a very small quantity of albumin, which distinguishes it from blood-serum. Its quantity varies (being about 60 gm.), but it is quickly reproduced.

It is secreted chiefly in the lateral ventricles. It passes from the lateral ventricles to the third ventricle, through the foramen of Munro, from the third to the fourth ventricle through the aqueduct of Sylvius, from the fourth ventricle through the foramina of Magendie, Key, and Retzius, to the subarachnoid space of the brain and spinal cord (Deaver).

The cerebrospinal fluid finds an outlet from the subarachnoid space—

(*a*) By way of the Pacchionian bodies—the villous prolongations of arachnoid which communicate with the sinuses of the dura mater.

(*b*) The prolongations of arachnoid along the cranial and spinal nerves communicating with the lymphatics.

The cerebrospinal fluid thus not only forms a water-bed in which the brain rests, but an *adjustable "water-bed."*

The function of the cerebrospinal fluid is twofold:

(1) *Protection.*—The most important parts of the brain are protected from the concussion which might be transmitted through the bones of the skull.

(2) *Adjustment.*—The brain will not tolerate the slightest compression, yet this delicate structure is lodged in an immovable bony case. There is an increase in brain volume whenever congestion is present. When the heart systole sends the blood throughout the brain, when at each expiration the veins are filled, how then does the brain escape compression? Only through the medium of a movable body in the cranium which can be displaced and can adjust itself to the slightest change in the brain—the cerebrospinal fluid. At each beat of the heart and each act of respiration this function of adjustment is being performed, the ebb and flow of the cerebrospinal fluid conforming to the quiescence or activity of the brain.

Surgical Considerations.—After fracture of the base of the skull cerebrospinal fluid may be seen flowing from the ears or nose and lead to diagnosis of the site of fracture. When from the nose the anterior fossa is involved, when from the ears the middle fossa.

Tubercular and inflammatory deposits may lead to closure of the foramen of Magendie and the excessive accumulation of fluid within the ventricle produce a condition known as *internal hydrocephalus.*

The sudden withdrawal of a large amount of cerebrospinal fluid causes a derangement of intracranial pressure and disturbance of cerebral function.

The **pia mater** is the membrane of nutrition. It forms a very thin, delicate curtain, immediately contiguous to the brain substance. It is essentially vascular and invests the brain intimately, sending processes into all its fissures and convolutions, to their entire depth. This membrane has been likened to a grape arbor; the vessels running over and through it, to a grape vine.

Arteries of the Brain.—Four great arterial trunks carry the blood to the brain—two vertebrals and two internal carotids. Their chief characteristic is the tortuous course which they take before arriving at the brain. These various bends in the course of the arteries are evidently for the purpose of lessening the shock of the heart's systole.

The **vertebral artery,** slightly sinuous as it ascends through the foramina in the transverse processes of the cervical vertebræ, describes two curves, a vertical and a horizontal curve. It finally unites with the vessel of the opposite side at the lower border of the pons Varolii to form the basilar artery.

The **internal carotid** rises vertically to the base of the cranium, where it makes a very pronounced bend. It takes a tortuous course through the carotid canal; in the cavernous portion it forms a curve like the letter S; it finally pierces the dura mater on the inner side of the anterior clinoid process, passes between the second and third nerves, and reaches the anterior perforated space at the inner extremity of the fissure of Sylvius, where it divides into two terminal branches, the anterior and middle cerebral.

The Circle of Willis.—The vertebral and internal carotid arteries form at the base of the brain a remarkable anastomosis known as the circle of Willis, which equalizes the flow of blood in the brain and permits ligature of the common carotid without degeneration of the brain following. No cerebral disturbance has followed the ligation of both common carotids, providing sufficient interval has elapsed between the two operations. When accident has occurred it has been observed after the first operation.

The circle of Willis (Fig. 20) is heptagonal in outline and is formed by the two anterior cerebrals in front, branches of the internal carotid, connected by the anterior communicating. The two posterior cerebrals behind, branches of the basilar, connected by the posterior communicating, with the internal carotids. The anterior, the middle, and the posterior cerebral arteries, forming three great trunks, inosculate freely in the pia mater and supply the brain.

The smaller cerebral arteries neither give nor receive anastomotic branches, but form a terminal circulation. Hence, when one of these arteries becomes obstructed by an embolus there is a complete loss of function of the part and softening of a limited area of the cortical area involved.

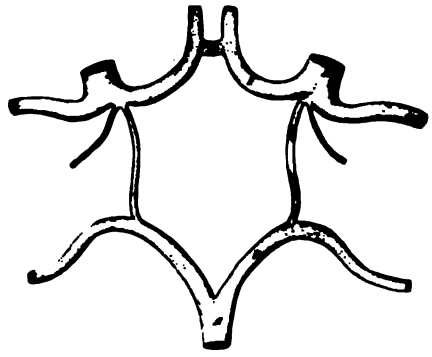

FIG. 20.—DIAGRAM OF THE CIRCLE OF WILLIS.
A, Basilar artery; *B*, posterior cerebral; *C*, posterior communicating; *D*, internal carotid; *F*, anterior cerebral; *G*, anterior communicating.

Charcot's "Artery of Cerebral Hemorrhage."—The lenticulostriate branch of the middle cerebral supplies the lenticular and caudate nuclei and is the most common seat of cerebral hemorrhage. Charcot found this artery so frequently ruptured in apoplexy that he termed it the "artery of cerebral hemorrhage."

Craniocerebral Topography.—In certain areas of the brain are located centers which preside over movements of the opposite side of the body. They are called motor areas or motor centers. These motor centers have a definite relation to the skull and when they are affected by compression from hemorrhage, fracture, or foreign body we can locate the point on the skull which corresponds to the affected center in the brain and by trephining relieve the symptoms.

Certain points, lines, and measurements have been definitely established to guide the surgeon in opening the brain cavity. The projection on the skull of the areas of the brain which are of practical surgical import is termed *craniocerebral topography.*

The centers in the brain whose functions are accurately known are (*a*) the motor area, (*b*) speech area, (*c*) visual area, (*d*) auditory area, (*e*) smell and taste area, and (*f*) general sensory area.

The **motor area** *comprises the region immediately anterior to the fissure of Rolando,* viz.: half of the ascending frontal convolution and the portion of the paracentral lobule lying anterior to the fissure of Rolando. If we divide this area into three parts we have three distinct motor centers corresponding to three distinct regions of the body. The *upper third* corresponds to the lower extremity, the *middle third* to the upper extremity, and the *lower third* to the face and tongue.

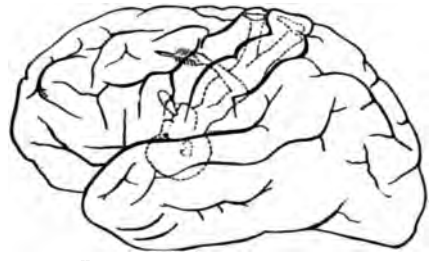

FIG. 21.—INVERTED FIGURE SHOWS THE RELATION OF THE MOTOR AREAS.

Remember that the *motor areas are inverted* on the surface of the brain. The *lower extremity* is at the *top* of the *fissure,* the *arm* at the *middle,* and the *face* at the *bottom* (Fig. 21).

If these areas be stimulated there will be definite movements, on the opposite side of the body, of the leg, arm, or face. If they be compressed or destroyed, there will be corresponding paralysis of the parts. This area is supplied by the middle cerebral artery, which is really a continuation of the internal carotid, so that emboli from the heart finding their way into the carotids are apt to find lodgment in the middle cerebral and cause a paralysis of the opposite side of the body.

The **speech center** is located in the Sylvian operculum on the left side in right-handed people and on the right side in left-handed people (Fig. 22). It is usually on the left side, since "we are generally left-brained, just as we are right-handed." This region is known as "Broca's region," and disease thereof

will cause *aphasia* or loss of power of speech. Aphasia may be of two kinds—motor and sensory. In the motor variety there is loss of the power to co-ordinate the muscles of articulation, in the sensory variety there is loss of memory for words, called *amnesia*. In the former the patient knows the words perfectly and can write them, but is unable to pronounce them. This condition may be produced by a plugging of the middle cerebral artery, by cerebral softening, hemorrhage, or pressure of tumor.

The **visual area** is located in the superior and inferior lip of the cuneate lobe situated respectively above and below the calcarine fissure.

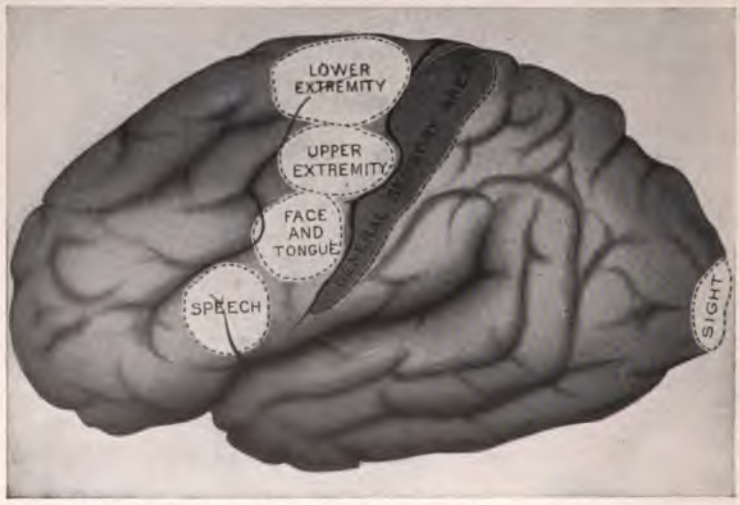

FIG. 22.—LOCALIZATION OF VARIOUS CENTERS ON THE OUTER SURFACES OF THE BRAIN.
Note the motor centers *in front* of the fissure of Rolando.

The **auditory area** is located in the transverse gyri of Heschl—two or three convolutions which course inward and somewhat forward on the superior surface of the temporal lobe.

The **smell and taste area** is located in the anterior extremity of the hippocampal convolution.

The **general sensory area** is located in an area immediately posterior to the fissure of Rolando (see Fig. 22).

It will thus be seen that there is a large portion of the brain whose function is not definitely known. This is especially seen in that part of the frontal lobe which lies in front of the

coronal suture. It has been called the "*silent region.*" If a lesion be present here it does not give rise to any localizing symptoms. Depressed bone, hemorrhage, abscess, tumor, or foreign body give rise to no paralyses. This region probably presides over the higher mental faculties, and injury to the part results in mental irritability and dulness of intellect.

Relations of the Brain to the Skull.—The lower level of the cerebrum (Fig. 23) is represented in front by a line drawn horizontally across the forehead, through the glabella; on the side by a line drawn from the external angular process of the frontal bone to the external auditory meatus; posteriorly

FIG. 23.—RELATION OF THE BRAIN TO THE SKULL. (Modified after Krönlein.)

1, 1, Reid's base-line; 2, 2, superior horizontal line; 3, 3, anterior vertical line passing from middle of zygomatic arch perpendicular to base-line; 4, 4, middle vertical line passing through pre-auricular fossa; 5, 5, posterior perpendicular line passing through the posterior border of the mastoid process; 3, 6, line of fissure of Rolando; 3, 7, line of fissure of Sylvius.

by a line from the external auditory meatus to the inion. The cerebellum is situated below the posterior part of the line.

The **longitudinal fissure** corresponds to a line drawn from the glabella directly over the vertex of the skull to the inion.

The **fissure of Sylvius,** situated at the front and side of the base of the brain, consists of a vertical and horizontal limb. The vertical limb runs up 1 inch into the frontal lobe. The horizontal limb passes backward and upward for about 2½ inches, separating the temporal lobe below from the frontal and parietal above. Within the beginning of the horizontal limb is the *island of Reil,* in which region, on the left, the motor

centers for speech were formerly thought to reside. It has been demonstrated, however, that this region has nothing in common with the cortical areas presiding over speech production. At most it is but a link between the hearing and speech centers (A. W. Campbell). This fissure lodges the lesser wing of the sphenoid and the middle cerebral artery. To indicate the position of the fissure of Sylvius on the skull draw a line from a point 1¼ inches behind the external angular process of the frontal bone to a point ¾ inch below the most prominent part of the parietal eminence. The first ¾ inch represents the main fissure, the remainder of the line the horizontal limb (Deaver).

The **fissure of Rolando** begins above, near the middle of the longitudinal fissure, runs obliquely downward and forward, nearly to the anterior extremity of the fissure of Sylvius. It separates the frontal from the parietal lobe. The cortical areas bounding this fissure anteriorly contain the motor centers, which preside over movements on the opposite side of the body of the upper and lower extremity and face. To represent the fissure of Rolando on the skull draw two lines perpendicular to Reid's base-line (see Fig. 23) (a line drawn through the lowest part of the infra-orbital margin and the middle of the external auditory meatus).

The two perpendicular lines terminate at the line representing the great longitudinal fissure. The anterior line passes through the pre-auricular fossa; the posterior passes along the posterior border of the mastoid process. From the point of intersection of the posterior perpendicular line with the great longitudinal fissure to the point of intersection of the anterior perpendicular line with that of the horizontal limb of the fissure of Sylvius, draw a third line, which represents the fissure of Rolando (Deaver). The above method is somewhat complicated for practical purposes, and, bearing in mind that any guide given for the location of this fissure is only approximately correct, the simplest and most practical method is the following: With the scalp completely shaved draw the following points with an analine pencil.

Upper limit of Rolandic fissure—a point ½ inch behind the center of a line drawn from the glabella to the inion.

Lower limit of Rolandic fissure—a point 3⅜ inches below the beginning of a line drawn from the upper limit of the fissure to the center of the zygomatic arch.

RULE.—*The fissure of Rolando is represented by the first* 3⅜

inches of a line drawn from a point ½ inch behind the center of a line from the glabella to inion to center of the zygomatic arch.

Three-quarters inch anteriorly and running parallel with the fissure, is the ascending frontal convolution which forms the motor area.

Parieto-occipital Fissure.—If the line representing the fissure of Sylvius be extended back to the longitudinal fissure the parieto-occipital fissure will be represented by the last inch of this line, or it is 3⅜ inches above the external occipital protuberance.

Clinical Considerations.—In dealing with injuries of the brain it is well to recall the apt simile of Treves, viz.: that it is a mass of soft tissue that may be damaged by shaking as gelatin may be shaken in a case.

Concussion of the brain cannot be anatomically defined. It is a condition which follows violent blows on the head, presenting well-defined symptoms without a recognized anatomic lesion. The jarring or shaking of the brain causes the cells to undergo some modification which we do not know. It is the first step in a process which, intensified, would lead to contusion or laceration of the brain.

Contusion of the brain is like contusion in other tissues. It may occur with or without fracture. It is important to remember that frequently there is contusion of the brain by *contrecoup*. In a case reported by Tillaux an area of contusion was found directly opposite the point where the blow was struck.

Compression of the brain is manifested by well-marked symptoms and may be due to pressure from depressed bone, blood-clot, abscess, tumor, or foreign body.

Wounds of the Brain.—The brain is very tolerant of wounds and foreign bodies, so long as there is no inflammatory process set up.

The two signs of penetration of the brain cavity are:

(1) Escape of cerebrospinal fluid.

(2) Escape of brain substance.

Wounds of the brain may give no special symptoms, and frequently the autopsy reveals what was not suspected during life.

Trephining.—In applying the trephine to the skull three important points should be kept in mind:

1. The varying thickness of the bone in the same skull and in different individuals.

2. The skull is thickest at the occipital protuberance, the mastoid process, and the lower part of the frontal bone. It is thinnest in the temporal fossæ and the occipital fossæ.

3. Wherever the sinuses and meningeal vessels groove the bone, it is thinned out. The lines of the superior longitudinal and lateral sinus should be avoided in placing the trephine, unless they are intended to be opened.

Where to Place the Trephine.—For *brain tumors, abscess, blood-clot,* and *focal epilepsy* the point is determined by the localizing symptoms.

For *foreign bodies*—at the wound of entrance. If the bullet or foreign substance is not recovered, we at least establish drainage.

For *middle meningeal hemorrhage*—at a point two fingers'-breadths above the midpoint of the zygoma.

FIG. 24.—SHADED PORTION ON SURFACE OF THE BRAIN INDICATING THE POSITION OF THE LATERAL VENTRICLE WITHIN.

The **lateral ventricle** (Fig. 24) may be tapped by various routes, as suggested by different operators. The technic recommended by Keen is as follows: The skull is opened by the trephine at a point 1¼ inches behind the center of the external auditory meatus and the same distance above Reid's base-line. The ventricle is opened by carrying a grooved director obliquely forward and upward toward a point 2½ inches above the opposite external auditory meatus. The grooved director reaches the ventricle at a depth of about 2¼ inches.

CHAPTER V

THE EAR

The **external ear** (Fig. 25) consists of the auricle, or pinna, and the auditory meatus.

The **auricle** is a fibrocartilaginous appendage, irregular in form, composed of many folds and fossæ and solidly attached to the sides of the cranium at the entrance of the auditory canal. It presents a variety of forms, may be congenitally

FIG. 25.—THE EXTERNAL EAR.

absent, or supernumerary auricles may be situated on the cheek or side of the neck. The prominent rim of the auricle is the *helix*. The groove at its inner border is the *fossa of the helix*. The curved prominence in front of the helix is the *anthelix*, which, as it ascends, bifurcates and forms the *crura*, which encloses a depression—the *fossa of the anthelix*. In front of the anthelix is the deepest part of the auricle, the

concha, and in front of the concha and extending backward over the meatus is the *tragus*. Behind the tragus and separated by the incisura intertragica is the *antitragus*, below which is the fibrous *lobule*. On the inner margin of the helix, at the junction of its upper and middle third, is a small tubercle—the *tubercle of Darwin*.

The skin of the auricle is thin and very adherent to the cartilage; it passes into the meatus, where it becomes thinner and finally blends with the periosteum.

In abscess and hematoma the auricle may be the seat of great swelling and pain. In *chronic gout* small hard nodules

FIG. 26.—EXTERNAL AUDITORY MEATUS AND TYMPANIC CAVITY.

(*tophi*) are found in the subcutaneous tissue at the border of the helix. They are deposits of urate of soda, and are sometimes so numerous as to cause deformity.

The **external auditory meatus** extends from the concha to the membrana tympani. It is an osseocartilaginous, slightly S-shaped canal 1½ inches long, measured from the bottom of the concha. Its direction is obliquely inward and forward (Fig. 26). Its greatest vertical diameter is at its external opening, its greatest transverse diameter is at the tympanic end. Its narrowest part is at the junction of the osseous and cartilaginous portions, about ⅓ inch from the external opening.

The meatus is lined with fine skin, firmly attached to the

cartilaginous and osseous portions of the canal and forming the outer layer of the membrana tympani. The subcutaneous tissue of the cartilaginous portion contains sebaceous glands and *ceruminous* glands, which secrete the ear wax, the ducts opening on the surface of the skin.

The Relation of the Meatus.—The upper wall is in relation with the middle cerebral fossa, from which it is separated by a layer of bone, frequently very thin; hence, abscess of the external ear occupying this position may be followed by meningitis. The anterior wall is directly behind the temporo-maxillary articulation. A blow on the chin may be transmitted to the condyle of the jaw and a fracture of the anterior wall of the meatus result. Inflammatory processes are associated with pain during mastication.

The lower wall is in relation with the parotid region and abscesses of the wall or of the gland may reciprocally travel from one structure to the other.

The posterior wall is in immediate relation with the mastoid cells and, since the cartilage is deficient at this point, there is little to prevent inflammatory processes extending from one part to the other.

Blood Supply.—The auricle and meatus are richly supplied with blood, principally from the temporal and posterior auricular arteries and veins; hence, wounds of these parts heal rapidly. The exposed position of the auricle, however, renders it liable to gangrene from frost-bite.

Nerve Supply.—The upper and anterior part of the auricle and the external meatus derive their nerve supply from the auriculotemporal branch of the inferior maxillary division of the fifth nerve. The posterior and anterior parts of the pendulous portion of the ear are supplied by the great auricular branch of the pneumogastric (Arnold's nerve), which sends a branch to the back of the concha and to the lower and back part of the meatus.

Pain in the ear is of great diagnostic significance, and its exact localization will often suggest the nerve paths along which will be found its cause.

Take such well-known examples as the association of toothache and earache—the same nerve which supplies the auditory canal and the anterior portion of the ear supplies the teeth. The same may be said of earache and stiffness of the jaw; lesions of the anterior third of the tongue and pain in the auditory canal (cancer of the tongue).

The reflex phenomena associated with Arnold's nerve are of great anatomic interest. Any irritation of this nerve, such as the introduction of an ear speculum or a plug of wax, may cause the patient to cough. Treves cites a case of Arnold's where severe chronic vomiting was cured by extracting from each ear of a child a bean which had been introduced in play. Sneezing and yawning have likewise been traced to irritation within the meatus.

Clinical Considerations.—(*a*) In using the ear speculum to inspect the meatus and the membrana tympani it should be borne in mind that the curve of the canal can be straightened out by drawing the auricle upward, backward, and outward.

FIG. 27.—THE APPEARANCE OF THE OUTER SURFACE OF THE TYMPANIC MEMBRANE. (After Deaver.)

(*b*) The canal in children is short, due to the deficiency of the osseous portion; the speculum should, therefore, be introduced with care and not pushed too far in.

(*c*) The narrowest portion of the canal is at the junction of the cartilaginous and osseous portion; hence, foreign bodies are apt to be wedged in at this point.

(*d*) In the floor of the meatus are the fissures of Santorini, filled with fibrous tissue, and through these a parotid abscess may break through into the meatus (Treves).

The **membrana tympani** (the drumhead) is a thin membranous partition which separates the external auditory meatus from the tympanic cavity (Fig. 27). It is firmly attached to a ring of bone except at the upper portion, where the ring is incom-

plete and forms the *notch of Rivini.* The portion of the membrane covering this deficiency is lax and thin, and is known as *Shrapnell's membrane.* The membrana tympani is very obliquely placed, forming an angle of forty-five degrees with the floor of the meatus. Its outer surface is concave. Its depressed center is known as the *umbo* and represents the point where the handle of the malleus is attached. Its outer surface is covered with modified skin, its middle layer is fibrous, and its inner surface is covered with mucous membrane.

When seen through an ear speculum the membrana tympani presents the following characteristics:

(*a*) The *umbo,* at the center of the concavity of the membrane where the handle of the malleus is attached.

(*b*) The rest of the handle, seen through the membrane, running upward and forward to the periphery.

(*c*) The cone of reflected light, with its apex at the umbo extending downward and forward to the periphery. This luminous triangle undergoes certain modifications in diseases of the ear.

The chorda tympani nerve passes across the upper portion of the membrane.

The blood supply of the membrane is from the tympanic branches of the internal maxillary and the internal carotid arteries. The nerve supply is the auriculotemporal to the external surface and branches from the tympanic plexus to the inner surface.

Perforation of the membrana tympani may occur as the result of traumatism, from sneezing, coughing, a box on the ear, or it may result from the escape of pus in otitis media. *Traumatic perforations heal rapidly, those associated with otitis media seldom close* (Deaver).

Paracentesis of the membrane is performed for the evacuation of pus in otitis media or to allow the sound waves direct access through a membrane which has become thickened and incapable of transmitting vibrations to the labyrinth. Since the important parts of the membrane occupy the supraumbilical portion, paracentesis of the membrane should always be performed in the subumbilical segment.

The **tympanum** or middle-ear (see Fig. 26) is a small cavity situated between the external and the internal ear. It contains the ossicles (the malleus, incus, and stapes), a chain of movable bones which transmits sound vibrations from the membrana tympani to the fenestra ovalis of the internal ear. It is bounded

externally by the tympanic membrane, internally by the bony labyrinth of the internal ear. The roof is formed by a thin plate of bone which separates it from the middle cranial fossa; the floor is formed by a similar plate of bone separating it from the jugular fossa. The anterior wall is narrow and receives two tubes: the upper is the canal which lodges the tensor tympani muscle, the lower is the Eustachian tube (see Fig. 26).

The **aqueductus Fallopii,** which lodges the facial nerve, is marked by a rounded ridge of bone passing anteroposteriorly and situated at the junction of the inner wall and the roof of the tympanum. A very thin plate of bone separates the nerve from the cavity of the middle ear. Suppurative processes may destroy this bony lamina and produce facial paralysis. The tympanum is lined with mucous membrane which is directly continuous with the mucous membrane of the Eustachian tube and the mastoid antrum.

The **Eustachian tube** is an osseocartilaginous canal which connects the tympanic cavity with the nasopharynx. It is about 1½ inches long; its direction is inward, downward, and forward. Like the external auditory meatus, it consists of an osseous and cartilaginous portion, which are respectively ½ and 1 inch long. The narrowest part of the tube is at the junction of the bony and cartilaginous portions. The cartilaginous part ends in a trumpet-shaped expansion at the pharyngeal orifice, from the lower aspect of which the tensor and levator palati muscles arise.

During deglutition these muscles contract, open the tube, and allow air to enter the tympanic cavity.

Inflation of the middle ear may be accomplished by (*a*) *Valsalva's method.* The patient closes the mouth and nose and forcibly blows out the cheeks and thus drives the air through the Eustachian tube. A sense of pressure is felt in the ears and the hearing is dulled because of the distention of the membrana tympani.

(*b*) *Politzer's Method.*—The nozzle of a Politzer air-bag is inserted into the nostril and the nose closed. While the patient swallows a mouthful of water the rubber bag is forcibly compressed and the air forced into the tympanum.

The Eustachian tube is lined with mucous membrane continuous with that of the middle ear; hence, inflammatory processes of the nasopharynx may secondarily involve the middle ear. Enlarged tonsils or hypertrophied adenoid tissue may obstruct the tube and cause deafness.

The **mastoid process,** as a distinct process, does not exist at birth; it is rudimentary. The *mastoid antrum,* however, is almost as large at birth as in the adult, and is covered by a thin layer of bone through which pus often makes its way to the surface.

The **mastoid cells** develop with the mastoid process, and at puberty nearly the entire process is occupied by the mastoid cells which communicate directly or indirectly with the antrum. They contain air and are lined with mucous membrane which is continuous with that of the antrum.

The cells at the apex are small and contain marrow. The pneumatic cells are not confined to the mastoid process, they occasionally extend into the posterior root of the zygoma, the parietal bone above, the occipital bone behind, and the region of the jugular process below (Taylor).

The **mastoid antrum** is the largest and most important cavity in the mastoid process. It is situated in the upper

FIG. 28.—THE SURFACE RELATIONS OF THE MASTOID ANTRUM.

and anterior portion of the process, just behind the tympanum, at a point corresponding to the posterior and superior wall of the external meatus (Fig. 28). It is about the size of a pea, and is lined with mucous membrane which is continuous with that of the tympanum and mastoid cells. It opens in front into the tympanum, the opening being on a higher level than the floor of the antrum; hence, the difficulty of draining this cavity through the external ear.

Relations of the Antrum.—The roof (tegmen antri) is formed of a thin plate of bone (1 mm.) which separates the antrum from the cranial cavity. It is on a level with the lower border of the posterior root of the zygoma and is perforated by small veins which empty into the superior petrosal sinus. The floor of the antrum is in relation with the mastoid cells and on a lower level than the orifice of communication with the tympanum.

The outer wall of the antrum is separated from the skin by a compact layer of bone which varies in thickness according to age. In infancy it is very thin, so that suppurative processes may spontaneously find their way to the surface. As the mastoid process develops, the depth of the antrum from the surface increases, the average depth, according to Deaver, being ½ to ¾ inch.

The inner wall of the antrum lies at an average depth of ¾ inch from the base-line of Macewen's suprameatal triangle. The facial canal lies on the inner side of the passageway between the tympanum and antrum. In children the wall of the canal is thin; hence, in children facial paralysis is much more likely to follow otitis media than in adults.

The anterior wall of the antrum separates it from the bony portion of the external auditory meatus.

The posterior wall of the antrum separates it from the sigmoid sinus. It is perforated by numerous foramina, through which small veins pass into the sigmoid sinus.

Macewen's suprameatal triangle is formed by the posterior root of the zygoma above, the posterior margin of the

FIG. 29.—MACEWEN'S SUPRAMEATAL TRIANGLE.

osseous part of the external auditory meatus in front, and a base-line from the root of the zygoma to the posterior margin of the bony meatus behind (Fig. 29). If the orifice of the external osseous meatus be bisected horizontally, the upper half would be on a level with the mastoid antrum. If this segment be again bisected vertically its posterior half would correspond to the junction of the antrum and middle ear (Macewen).

The suprameatal triangle is of prime importance in the surgery of the mastoid antrum. It is through this area only that the antrum can be opened with safety.

Clinical Considerations.—The tympanum or middle ear is a region of great clinical importance. Its relation to important structures and the various paths through which infection may travel renders a knowledge of its surgical anatomy indispensable in the application of proper surgical relief. The tympanum is in direct communication with the nasopharynx through the Eustachian tube; hence, in inflammatory conditions of the throat or nose—diphtheria, scarlet fever, tonsillitis, postnasal adenoids, etc.—the infection may extend into the middle ear and produce changes in the structures which seriously impair the hearing, or a suppurative condition may be inaugurated (suppurative otitis media) which will lead to grave consequences.

In abscess of the tympanum, if not evacuated by surgical intervention, the membrane may rupture spontaneously and the pus be discharged through the external meatus. There is, however, a tendency to chronicity in these abscesses because of defective drainage, due to the fact that—

(*a*) The Eustachian tube may be closed by its swollen mucous membrane.

(*b*) The floor of the tympanum is below the level of the external auditory meatus.

(*c*) The opening into the antrum leads into a closed cavity which drains off the overflow and itself becomes infected.

The *paths of infection and its results are*—

(*a*) Through the roof of the tympanum, causing meningitis and intracranial abscess.

(*b*) Through the tympanic floor, involving the internal jugular vein and causing fatal hemorrhage or septic thrombophlebitis of the vein.

(*c*) Caries of the anterior wall, followed by ulceration into the carotid artery and fatal hemorrhage.

(*d*) Caries of the Fallopian canal and permanent facial paralysis.

(*e*) Disorganization of the internal ear and permanent deafness.

(*f*) Infection of the mastoid antrum and cells (mastoiditis).

Mastoid Disease.—The mastoid antrum and its surrounding cells are lined with mucous membrane and communicate with the middle ear. It is frequently the site of inflammatory processes which constitute one of the most important sequelæ of middle-ear disease. When the mastoid antrum becomes infected drainage should be provided by prompt surgical

intervention, otherwise the inflammation may spread into the surrounding structures and fatal results ensue.

It may extend upward by carious absorption of the bony roof and produce meningitis and temporosphenoidal abscess, or the minute veins which pass through the bone may carry the infection to the superior petrosal sinus and septic thrombosis of the sinus result.

It may extend downward into the adjacent mastoid cells, necrosing the mastoid process, burrowing beneath the sternomastoid muscle, and result in a deep abscess of the neck.

It may extend outward, burrowing its way to the surface. This is very apt to occur in children through the mastosquamosal suture, which is not usually closed by ossification till the age of puberty (Allport).

It may extend backward, infecting the sigmoid sinus, or the infection, being disseminated by the minute veins which traverse the bony partition, thrombophlebitis of the sinus results. Extension of the infection through the internal jugular may lead to general pyemia, or it may travel along the cerebellar veins and give rise to cerebellar abscess.

It may extend inward and involve the labyrinth, giving rise to permanent deafness, or involve the Fallopian canal and paralysis of the facial nerve result.

Mastoiditis of Bezoldt is an infection of the cell in the tip of the mastoid. It may remain for a long time unrecognized; it may erode the thin cortical bone and become extra-mastoid by following the course of the occipital artery to the base of the neck, or escape beneath the digastric fascia to the subhyoid region.

Rules for Opening the Mastoid Antrum.—1. Remember that it lies within the boundaries of the suprameatal triangle.

2. In approaching the antrum hug the posterior wall of the external meatus and follow its general direction.

3. Do not extend the opening too far upward or the middle cranial fossa may be opened.

4. Do not direct the opening backward; the sigmoid sinus may be wounded. The knee of the sigmoid sinus is generally on a level with the upper part of the external osseous meatus and, according to Macewen, the distance from the external osseous meatus varies from 2 to 3 mm. The right sigmoid groove is generally wider and is situated further forward than the left.

5. Do not penetrate deeper than ¾ inch, or the Fallopian canal containing the facial nerve may be injured.

6. If, with the above precautions, the antrum cannot be found, adopt the suggestion of Whiting and pass a probe with its point bent sharply into a hook between the fibrocartilaginous canal and the posterior wall of the bony meatus, into the tympanum, and hook the tip beneath the tympanic ring in the superior posterior quadrant. The probe will traverse the opening between the tympanum and antrum and may be held in position as a guide.

CHAPTER VI

THE FACE

THE skin of the face is thin, mobile, vascular, and abundantly supplied with sweat and sebaceous glands. These glands, when inflamed, give rise to acne, especially about the alæ of the nose and angle of the mouth, and are frequently the site of sebaceous cysts. The subcutaneous cellular tissue is lax and contains more or less fat, except in the eyelids and over the bridge of the nose. The laxity of the cellular tissue favors the spread of inflammatory processes, which are usually accompanied by great swelling of the face. In general dropsy the face becomes "puffy," the edema first appearing in the loose tissue of the lower eyelid. Because of its mobility and vascularity, the skin of the face is specially qualified for plastic operations.

The skin of the face is frequently the site of epitheliomata which have a special predilection for the eyelid, angle of the eye, cheek, and alæ of the nose. They possess certain characteristics which are worth noting:

(*a*) They progress very slowly.

(*b*) They do not affect the general health, even after many years and numerous operations.

(*c*) They rarely invade the lymphatics.

The subcutaneous tissues of the face contain a quantity of fat, yet the face is rarely the site of lipomas.

The **facial muscles** are situated in the subcutaneous tissue and may be divided into three groups: those of the eyebrows and eyelids, those of the nose, and those of the mouth—palpebral, nasal, and oral (Deaver).

The functions of the facial muscles are twofold:

1. To open and close the orifices.
2. To give expression to the features.

The important part which these muscles play is well demonstrated in facial paralysis (page 74).

Blood Supply.—The principal artery of the face is the **facial,** a branch of the external carotid. It reaches the facial

region by crossing the lower jaw at the anterior inferior angle of the masseter muscle, where its pulsations can be plainly felt. From this point it takes a tortuous course to the angle of the mouth, thence to the side of the nose, and terminates in the angular artery at the inner canthus of the eye, where it anastomoses with the nasal branch of the ophthalmic artery (Fig. 30). The principal branches of the facial are the inferior labial, the superior and inferior coronary, and the lateral nasal branches.

The **facial vein** takes an almost straight course from the inner canthus of the eye to the anterior inferior angle of the

FIG. 30.—SURFACE MARKINGS OF THE FACE.
A, Facial artery; *B*, facial vein; *C*, Stenson's duct; *D*, Facial nerve.

masseter muscle (Fig. 30). At its beginning it communicates through the ophthalmic vein with the cavernous sinus, at the middle of its course it communicates through the deep facial vein with the pterygoid venous plexus, and through it with the cavernous sinus. It terminates in the internal jugular vein.

Clinical Considerations.—There is a very free anastomosis between the arteries of the face: (*a*) The two facial arteries anastomose through their branches; (*b*) the branches of the internal maxillary communicate with the facial branches; (*c*) the external and internal carotid communicate through the anastomosis between the facial and ophthalmic arteries. Thus it

will be observed that the tissues of the face are very vascular; hence—

(*a*) Wounds of the face bleed freely and heal rapidly; the vital resistance of the tissues is high.

(*b*) Extensive plastic operations on the face are possible and are utilized in correcting deformities, congenital or acquired.

(*c*) *Nevi* and blood tumors (birth-marks) are frequently found on the face, especially the lips. They appear as a superficial discoloration of the skin, either of a pink or bluish hue, and consist of an abnormal collection of arterioles situated in the subcutaneous tissue.

(*d*) The pulsations of the facial artery, so easily felt as it crosses the lower jaw in front of the masseter muscle, are of importance to the anesthetist when the radial pulse cannot be conveniently felt.

The facial vein, possessing no valves, communicating with the cavernous sinus and the internal jugular vein, plays an important rôle in septic processes of the face; hence, infections of the face are dangerous because of the possibility of thrombosis of the cavernous sinus and septic meningitis.

The treatment of facial nevi by the injection method has been followed by sudden death, due to pulmonary embolism through the great vein of the neck.

Nerves.—The facial nerve is the motor nerve of the face and supplies all the muscles of expression. It consists of an intracranial, a temporal, and a facial portion. It begins its facial course just below the lobe of the ear, between the mastoid process and the angle of the jaw (see Parotid Region). It divides within the parotid gland and its branches spread over the face in the shape of a fan, extending from the temporal region above to the submaxillary region below (Fig. 31). It forms communications with various branches of the fifth nerve. The general horizontal direction of the branches of the facial nerve suggests the advantage of horizontal incisions in the face.

Facial paralysis (Bell's palsy) may be due to pressure within the cranium from hemorrhage, abscess, or tumor; to involvement of the Fallopian canal from fracture or middle-ear disease; to tumors or abscess of the parotid gland; to division of the nerve during operation, or to exposure of the face to cold.

In paralysis of the facial nerve all the muscles of expression are paralyzed and the face assumes a characteristic appearance (Fig. 32). The wrinkles and furrows of the skin on the par-

alyzed side are smoothed out, and the patient cannot close his eye; the cornea is thus exposed and corneal ulcer is apt to follow. To prevent this the lids should be approximated by adhesive strips. The mouth is pulled over to the sound side by the unopposed muscles, saliva dribbles from the mouth, and the patient cannot pucker the mouth for whistling, because

FIG. 31 —BRANCHES OF THE FACIAL NERVE SPREAD OVER THE FACE IN THE SHAPE OF A FAN.

of paralysis of the orbicularis oris. The impaired buccinator allows the cheek to puff out in deep expiration and food lodges between the teeth and the cheek. Paralysis of the muscles of the middle ear may cause loud noises to distress the patient. If the chorda tympani nerve is involved there is a loss of the sense of taste in the anterior two-thirds of the tongue on the affected side. If the paralysis of the facial nerve is of central

origin the muscles of the eyebrow and eyelids are not affected, probably due to the existence of certain commissural fibers.

When facial paralysis is due to division of the nerve during operation, the lesion may be remedied by immediate or subsequent anastomosis of the distal end of the divided nerve with the spinal accessory or hypoglossal nerves. The many successful cases which have followed this operation are sufficient to establish its value and importance in rectifying this unfortunate accident.

FIG. 32.—APPEARANCE OF FACE IN FACIAL PARALYSIS.

The **sensory nerve** of the face is the fifth of the trifacial. As its name indicates, it supplies the skin of the face in three situations: the supra-orbital, infra-orbital, and mental regions. The fifth nerve expands into the Gasserian ganglion, which lies upon the apex of the petrous portion of the temporal bone, from which emanate the three sensory divisions: the ophthalmic, superior maxillary, and inferior maxillary.

The branches of these three divisions appear upon the face through three foramina: the supra-orbital, infra-orbital, and mental foramina.

Location of the Foramina.—The *supra-orbital foramen* is at the junction of the inner and middle third of the upper margin of the orbit (Fig. 33). A straight line drawn downward from this point so as to cross the gap between the two bicuspid teeth will cross both the infra-orbital and mental foramina (Treves) (Fig. 34).

FIG. 33.—*A*, SUPRA-ORBITAL FORAMEN; *B*, INFRA-ORBITAL FORAMEN; *C*, MENTAL FORAMEN.

FIG. 34.—LINE OF SUPRA-ORBITAL, INFRA-ORBITAL, AND MENTAL FORAMINA.

The *infra-orbital foramen* corresponds to a point about ½ inch below the junction of the inner and middle thirds of the lower margin of the orbit (see Fig. 33).

The *mental foramen* is situated in the lower jaw opposite the second bicuspid tooth, midway between the alveolus and the lower border of the jaw (see Fig. 33). In old age it is nearer the alveolus.

Areas of the Face Supplied by the Trifacial (Fig. 35).—The *supra-orbital nerve* emerges from the supra-orbital foramen, supplies the upper eyelid, the forehead, and scalp as far back as the vertex.

The *infra-orbital nerve* leaves the infra-orbital foramen and supplies the lower eyelid, the integument on the side of the

FIG. 35.—AREAS OF THE FACE SUPPLIED BY THE TRIFACIAL NERVE.

nose, and the integument and mucous membrane of the upper lip.

The *mental branch* of the inferior dental nerve emerges from the mental foramen and supplies the integument of the chin and the skin and mucous membrane of the lower lip.

Trifacial neuralgia, manifested by acute pain in the parts supplied by branches of the fifth nerve, may be caused by carious teeth, disease of the maxillary or frontal sinuses, or some irritation within the cranium.

In cases of intractable facial neuralgia, where all possible sources of peripheral irritation have been removed without

relief, it may be necessary to resect the nerves as they leave their bony canals, or if this procedure fails, relief can only be obtained by excision of the Gasserian ganglion. Resection of the nerves as they leave their bony canals is a simple procedure, since they are easily located beneath the superficial structures. In infra-orbital neuralgia the whole nerve, with Meckel's ganglion, has been removed, and the results have justified this radical procedure.

The **Gasserian ganglion** occupies an osteofibrous space (Meckel's cave) on the superior surface of the petrous portion of the temporal bone near its apex (Fig. 36). It lies between the endosteal and meningeal layers of the dura mater. When

FIG. 36.—THE GASSERIAN GANGLION.
A, Gasserian ganglion; *B*, ophthalmic division; *C*, superior maxillary division; *D*, inferior maxillary division.

removing the ganglion the outer layer of dura mater must be incised.

From the anterior border of the ganglion proceed its three large branches: the ophthalmic, the superior maxillary, and the inferior maxillary. The first two of these are solely nerves of sensation, the inferior maxillary, however, is joined outside the cranium by the motor root of the trifacial and is, therefore, a mixed nerve.

The ophthalmic nerve enters the orbit through the sphenoidal fissure and supplies the orbital contents.

The superior maxillary nerve leaves the skull through the foramen rotundum. The inferior maxillary makes its exit through the foramen ovale.

The Gasserian ganglion is removed by making an osteoplastic flap in the temporal region just above the zygoma, to reach the middle fossa of the skull. The dura is separated from the bone and the brain retracted to give a view of the deeper structures. When the foramen spinosum and middle meningeal artery are reached the artery should be ligated. Immediately in front of the foramen spinosum is the foramen ovale, transmitting the inferior maxillary, and ¾ inch anterior to the foramen ovale is the foramen rotundum, transmitting the superior maxillary. After the superior and inferior maxillary nerves have been demonstrated and divided at their respective foramina they should be traced backward to the

FIG. 37.—THE PAROTID GLAND.

Gasserian ganglion, lodged in Meckel's space between the two layers of dura mater. The outer layer of dura mater having been incised, the ganglion can be removed.

The **lymphatics of the face** run downward and terminate in the submaxillary and superficial cervical glands. The lymphatics from the outer part of the eyelids and cheek go to the parotid gland.

The **parotid region** is occupied by the parotid gland, which lies in a groove between the ramus of the jaw and the anterior border of the sternomastoid muscle (Fig. 37).

The *boundaries* of the region are, above, the external auditory canal and the temporomaxillary articulation; below, a line passing from the angle of the jaw to the anterior border

of the sternomastoid muscle; in front, the posterior border of the ramus of the jaw; behind, the anterior border of the sternomastoid muscle.

The above limitations merely outline the superficial part of the region; the parotid gland really occupies a compartment the shape of a triangular pyramid, with the skin as its base and the styloid process its apex.

The *fibrous capsule of the parotid* is formed from the deep cervical fascia, which is continuous behind with the sheath of the sternomastoid and in front with the masseteric aponeurosis. The parotid capsule plays an important rôle in the pathology of the gland, since the gland is not entirely enclosed by its capsule. The capsule is *strongest externally, behind and below.* It is *weakest in front* at the posterior border of the jaw. It is *deficient internally*, near the styloid process, where a portion of the gland is in direct relationship with the lateral wall of the pharynx. *It is incomplete above* where it is in direct contact with the external auditory meatus and the posterior portion of the capsule of the temporomaxillary articulation. Hence, collections of pus within the gland spread in the direction of least resistance—forward toward the cheek, upward toward the external auditory meatus and the temporomaxillary joint, inward toward the pharynx. Conversely, suppurative processes in the external auditory meatus, the middle ear, the temporomaxillary joint, or a retropharyngeal abscess may point in the parotid region.

Contents of the parotid compartment are the parotid gland, the external carotid artery, the external jugular vein, lymphatic ganglia, and the facial and temporo-auricular nerves.

The **parotid gland** is the largest of the salivary glands. It fills the parotid space and sends a process over the masseter muscle known as the *facial process.* In the upper portion of this process is the accessory parotid gland (*socia parotidis*), which has a duct of its own which opens into Stenson's duct. The vessels and nerves adhere intimately to the gland and it is impossible to dissect them out without removing portions of the gland. Hence, the difficulties presented in extirpating the diseased parotid are very great and cannot be accomplished without destruction of the facial nerve. In malignant disease of the parotid operation is only justifiable when the morbid process can be removed in its entirety. When we consider the situation of the parotid and its pharyngeal prolongation, the difficulties of a total extirpation are almost insurmountable.

Tillaux observes that extirpation of these tumors is useless unless complete, and when complete it is fatal.

Mumps (epidemic parotitis) is an inflammation of the fibrous framework of the gland accompanied by swelling of the gland without suppuration. It is accompanied by swelling and tenderness in other glands, notably the testicles, ovaries, and mammary glands. It must not be confounded with acute parotitis, which is an inflammation of the glandular tissue itself, and occurs as a complication of infectious diseases, typhoid, pneumonia, the eruptive fevers, and usually terminates in suppuration.

The **vessels** of the parotid region are: the **external carotid artery,** which crosses obliquely behind the ramus of the jaw and enters the parotid gland, the upper two-thirds of which it traverses. It approaches more and more the superficial surface to the border of the condyle of the jaw, where it divides into its terminal branches, the *superficial temporal* and the *internal maxillary*. Thus, the external carotid artery traverses the parotid gland in an oblique direction from within, out and anteroposteriorly.

The **temporomaxillary vein,** formed by the confluence of the superficial temporal and the internal maxillary vein, descends in the substance of the parotid gland external to the artery. It sends a branch to join the facial vein and another through the deep part of the gland to join the internal jugular and finally is joined by the posterior auricular vein and becomes the external jugular.

The vessels form a rich vascular plexus intimately connected with the gland. They are situated within a narrow space difficult of access. The parotid gland is separated from the internal carotid, the internal jugular vein, the pneumogastric, the glossopharyngeal, and hypoglossal nerves only by a thin layer of fascia. Hence, wounds of the parotid region are often grave because of the difficulty in controlling hemorrhage. As a rule, both ends of the vessel should be ligated within the wound. If the ends of the bleeding vessels cannot be found then the external carotid should be tied. If this procedure fails the internal carotid must also be ligated.

The **nerves** of the parotid region are: (*a*) the **auriculo-temporal nerve,** a sensory branch of the inferior maxillary division of the fifth, which forms an anastomosis with the facial and the otic ganglion. It emerges from the upper border of the parotid and crosses the root of the zygoma between the

external ear and the condyle of the jaw, dividing into its temporal branches. This nerve is sometimes resected in persistent neuralgia and is easily found as it crosses the zygoma, lying between the ear and the temporal artery.

(*b*) The **facial nerve,** after leaving the stylomastoid foramen, enters the parotid gland at a point corresponding to the base of the lobule of the ear and runs forward in the substance of the gland, crossing the external carotid artery. After a course of 2 cm. in the gland it divides into two branches, the *temporofacial* (ascending) and the *cervicofacial* (descending). These terminal divisions break up within the gland and form a plexus, the *pes anserinus* (goose's foot). The branches finally emerge at the anterior border of the parotid and radiate over the side of the face in a fan-like manner. During its course anastomoses are formed with the auriculotemporal and the great auricular nerves.

The *position of the facial nerve* is indicated by a line drawn from the base of the lobule of the ear downward and forward across the face for about 1 inch (Deaver) (see Fig. 30). The facial nerve does not adhere very closely to the glandular tissue and small benign growths, such as adenoma and chondroma may be removed without injuring it. It is quite evident, however, that the removal of the parotid is necessarily followed by facial paralysis.

Stenson's duct begins at the anterior border of the parotid gland and crosses the masseter muscle about a finger's-breadth below the zygoma. At the anterior border of the muscle it bends abruptly inward and pierces the substance of the buccinator, running obliquely forward between the buccinator muscle and the mucous membrane of the mouth, into which it opens by a small orifice opposite the second molar tooth of the upper jaw. The course of the duct may be represented by a line drawn from the lower margin of the concha to a point midway between the ala of the nose and the margin of the upper jaw (see Fig. 30). Stenson's duct may be divided into a masseteric and buccal portion nearly equal in length. The masseteric portion of the duct can be easily felt as a rounded cord rolling beneath the skin when the masseter muscle is contracted. It is situated about a finger's-breadth below the zygoma, the transverse facial artery being above and some branches of the facial nerve below.

At the anterior border of the masseter muscle the duct bends at nearly a right angle; hence, the difficulty in passing a probe.

In passing a probe slight traction should be made on the cheek to straighten out the canal and the opening of the duct sought on the summit of a papilla opposite the second molar tooth. There is no valve at its outlet, but the obliquity of the opening prevents fluids passing in the reverse direction.

Incisions in the parotid region should always be in a horizontal direction, parallel to the course of its two important structures, the facial nerve and Stenson's duct.

Fistulæ of the parotid and its duct usually occur as the result of wounds of the gland or its duct during operation. Fistulæ of the gland itself heal spontaneously. Fistulæ of the masseteric portion of the canal are very difficult to cure, since the position of the duct makes it difficult to turn the course of the saliva into the mouth. Anastomosis of the divided ends gives the most satisfactory results. Fistulæ of the buccal portion are cured by making a new buccal orifice and turning the proximal portion of the duct into the mouth.

The **parotid lymph-glands** are placed some superficially; others are imbedded in the gland itself. They drain the lateral portions of the scalp, the outer portions of the eyelids, the cheek, the root of the nose, and the outer part of the ear. Vessels from the parotid lymph-glands empty into the superficial and deep cervical glands. The *subparotid glands* between the parotid and the pharynx drain the nasal fossæ, the nasopharynx, and the Eustachian tube. These lymphatic glands play an important rôle in the pathology of the parotid region and may give rise to tumors which are obscure and difficult to diagnose, such as lymphadenoma and lymphosarcoma.

Tumors of the Parotid.—Chondroma is found more frequently in connection with the salivary glands than any other benign tumor (Senn), the parotid being more frequently affected than the submaxillary gland. The mixed tumors are characteristic of this region, such as chondrosarcoma, myxosarcoma, and myxadenoma. Tumors of the parotid press upon and destroy the nerves and may cause anesthesia of the skin supplied by the auriculotemporal nerve, or paralysis of the muscles supplied by the facial. Large tumors of the parotid may press upon the pharynx and cause dysphagia. Tillaux cites the case of a gaseous tumor of the parotid gland which disappeared on pressure and was reproduced when the patient made a sudden and forcible expiration with the mouth closed. The tumor was connected with Stenson's duct, the internal extremity of which was open and dilated.

The **masseter** and **internal pterygoid muscles** are alike in form and function (Figs. 38 and 39). They have been likened to the two bellies of the digastric muscle and should be studied together. They are thick quadrilateral muscles placed, respectively, on the outer and inner surfaces of the ramus of the jaw. They are inserted into the lower portion of the ramus, descending to the angle of the jaw, where they meet at the lower border and are united by periosteum. They are supplied by the inferior maxillary nerve and by their combined action they raise the lower jaw against the upper with great force. In resections of the jaw the periosteum should be peeled off so

FIG. 38.—MASSETER MUSCLE.

as to preserve the continuity of the two muscles and thus retain a thick groove of periosteum, which will contribute very efficiently to repair.

The muscles of mastication are most frequently involved in the spasmodic contractions of *trismus* or *lockjaw*. This condition may be produced by irritation of the inferior maxillary nerve, as in caries of the lower teeth, or it may be associated with the eruption of the lower wisdom tooth. In tetanus, tonic contraction of these muscles appears among the first symptoms.

The relations, in this region, of the parotid gland, Stenson's duct, the transverse facial artery, and the branches of the facial nerve have already been noted. These structures are all sub-

aponeurotic and, in opening a subcutaneous abscess they would not be invaded.

The **buccinator muscle** is a thin quadrilateral muscle arising from the alveolar processes of the upper and lower jaws, its fibers converge toward the angle of the mouth and are continuous with the orbicularis oris. It forms a sort of support for the buccal mucosa. It is supplied by the facial nerve and its function is to compress the cheeks so that during mastication the food is pushed beneath the molar teeth. Hence, in paral-

FIG. 39.—INTERNAL PTERYGOID MUSCLE.

ysis of the facial nerve the food constantly collects between the cheek and the teeth and must be dislodged by the finger.

The **buccal nerve,** a branch of the inferior maxillary, is a nerve of sensation supplying the integument and mucous membrane covering the buccinator muscle and anastomosing with the facial nerve. Neuralgias of this nerve are common and are diagnosed by the site and direction of the pain, following a line extending from the ear to the middle of the cheek. Tillaux observes that they give three painful points:

(*a*) In front of the lobule of the ear.

(*b*) Near the anterior border of the masseter muscle.

(*c*) In the middle portion of the cheek.

The buccinator muscle is pierced by Stenson's duct opposite the second molar tooth of the upper jaw (see Stenson's duct).

The **molar glands** are situated between the buccinator muscle and its fascia, lying directly on the muscle behind Stenson's duct, opposite the last molars. Cysts and adenoma of the cheek have their origin in these glands.

The **fatty ball of Bichat** is a lobulated mass of fat which occupies the space between the masseter and the external surface of the buccinator. It is well developed in infants and does not disappear in the adult even in advanced stages of emaciation. It has been termed by Ranke the "sucking pad," because of the support it affords the cheek of the infant in nursing the breast.

Lipomas of the cheek may be either subcutaneous or subaponeurotic. The latter are never submucous since they always lie on the external surface of the buccinator. They may, however, owing to the thinness of the buccinator and the position of the aponeurosis, present in the mouth rather than the skin, and may be removed by way of the mouth through the buccal mucous membrane.

Collections of pus in the cheek may be supra- or subaponeurotic. When they are supra-aponeurotic they invade the subcutaneous tissue and make their appearance beneath the skin. When they are subaponeurotic they may invade the temporal and zygomatic fossæ and present in the cheek between the buccinator muscle and its aponeurosis.

The **superior maxillary region** is composed of the two superior maxillæ which unite in the median line and form the greater part of the framework of the face. The superior maxilla has been compared to a shell of bone enveloping the maxillary sinus or antrum of Highmore (see pages 120 and 121). It forms part of the floor of the orbit, the roof of the mouth, the external wall of the nasal fossa, and the anterior wall of the spheno-maxillary fossa. Owing to the fact that it is well protected by its outlying processes, the nose, the malar bones, and the zygomatic arches, *fractures of the superior maxilla are not common.* This fracture may be due to direct violence or it may be indirectly transmitted through a blow on the chin or by a blow on the head when the chin is fixed. Gunshot wounds of the face or a kick in the face by a horse may be mentioned among the causes.

Scudder observes that fracture of the superior maxilla occurs

so frequently from a bicycle injury that it may be properly called the bicycle accident.

The infra-orbital nerve may be involved, causing anesthesia or neuralgia of the parts. The lacrimal sac is sometimes torn and the lacrimal duct obstructed.

In treating these fractures remember that the vitality of this bone is very great and observe the dictum of Malgaigne, to *leave undisturbed every fragment that is not absolutely and entirely detached.* The periosteum of the superior maxilla does not form new bone; hence, necrosis of bone or removal of fragments always leaves a permanent gap.

Excision of the superior maxilla is practised in case of malignant disease and temporary osteoplastic resection is sometimes done as a preliminary in gaining access to nasopharyngeal tumors.

The cutaneous incision divides the upper lip in the median line and is carried around the ala of the nose, along the side of the nose to the inner canthus of the eye. The incision is continued in a horizontal direction about ¼ inch below the infra-orbital margin to a point over the most prominent part of the malar bone.

The flap is dissected up and turned outward. The advantage of this incision is the thorough exposure of the parts which are to be excised, the main vessels of the flap are not disturbed, and no important branches of the facial nerve are divided. The angular artery and vein and the infra-orbital artery and nerve are severed, but the hemorrhage is easily controlled. The superior maxilla is readily removed after dividing its bony connections at four points (Fig. 40).

(*a*) *Externally,* with the malar bone.

(*b*) *Internally,* with the nasal process.

(*c*) *In the median line,* through the alveolar process and hard palate.

(*d*) *Behind,* with the pterygoid process.

The infra-orbital nerve is divided in front of Meckel's ganglion. No large vessels are, however, severed in this operation.

The **inferior maxilla,** because of its horseshoe shape, its great elasticity, and mobility is protected from fracture to a comparative extent. Nevertheless, it is more frequently fractured than any other bone of the face. It is usually broken by direct violence. The symphysis is rarely broken, because of its great strength. The ramus is protected by muscular pads. The most common site of fracture is at its weakest point—a

little in front of the masseter muscle, where it is weakened by the mental foramen and the deep socket of the canine tooth.

As a rule, there is little displacement, but when the bones are broken obliquely there is a tendency of the fragments to override, the anterior fragment being drawn downward and backward by the depressor muscles of the jaw, the posterior fragment being drawn upward and outward by the elevator muscles. The existence of displacement is seen in the difference in the level of the teeth. Fractures of the lower jaw are usually

FIG. 40.—FOUR POINTS OF BONY CONNECTION OF SUPERIOR MAXILLA.

compounded by laceration of the gums and are thus subject to infection.

When the fragments are accurately approximated and firmly retained infection seldom occurs, and solidification is rapid. When the fragments, however, have a tendency to override, suppuration is invited and abscesses may form about the jaw or in the neck, portions of the jaw exfoliate and the process extend over a long period before a permanent cure can be obtained.

The old method of treatment by locking the lower jaw against the upper has been replaced by the use of the interdental splint, which insures accurate approximation and satisfactory retention.

The **temporomaxillary articulation** is a hinge-joint modified to allow a gliding movement. It is formed above by

the anterior part of the glenoid cavity (the part in front of the fissure of Glaser) and the eminentia articularis; below by the condyle of the lower jaw. These two bony surfaces are convex and the articulation is only made possible by the interposition of a biconcave *interarticular fibrocartilage* which articulates above with the glenoid cavity and below with the condyle of the jaw; hence, *this articulation is composed of two distinct joints,* one between the condyle of the jaw and the interarticular fibrocartilage, which allows the hinge-like movement, and the other between the fibrocartilage and the glenoid cavity, which permits the movement of a gliding character (Fig. 41).

FIG. 41.—TEMPOROMAXILLARY ARTICULATION. Showing interarticular fibrocartilage.

The surfaces of the interarticular fibrocartilage are separated from their respective bony articulations by two distinct synovial cavities. The margins of the cartilage are connected with the capsular ligament, and in addition it receives part of the insertion of the external pterygoid muscle. Hence, the cartilage follows closely the normal movements of the condyle from the glenoid fossa to the eminentia articularis.

The **capsular ligament** is very thin and loose, the weakest point being in front. It passes from the circumference of the glenoid cavity to the upper margin of the articular disk, and from the lower margin of the articular disk to the neck of the condyle of the jaw. Thus it will again be seen how the two distinct joints are formed in this articulation.

The **external lateral ligament** is an accessory band of the capsular ligament. It is short and strong, and descends from the tubercle at the root of the zygoma downward and backward to the neck of the condyle of the jaw (Fig. 42). It forms a powerful obstacle to backward displacement of the jaw. This is the only ligament which affords material support to the joint, and, as Tillaux has observed, *the true internal lateral ligament of one side is the external lateral ligament of the opposite side.*

FIG. 42.—EXTERNAL LATERAL LIGAMENT, NORMAL; MOUTH CLOSED.

The **internal lateral** or **sphenomaxillary ligament** contributes no support to the joint. It is a long, thin band extending from the spine of the sphenoid to the margin of the dental foramen. It is separated from the neck of the jaw by an interval through which pass the internal maxillary artery and the inferior dental vessels and nerve.

The **stylomaxillary ligament** is a thickened band of cervical fascia extending from the apex of the styloid process to the angle of the jaw. It separates the parotid and submaxillary glands.

Note the fact that the glenoid fossa is separated from the bony meatus and the middle ear only by a thin plate of bone. Hence, blows upon the chin would produce serious damage to three delicate structures, were it not for the external lateral ligament which resists backward movements of the condyle. Note also that diseases of the middle ear may extend into the articulation or from the articulation into the ear.

Dislocation of the Lower Jaw.—A study of the bony relations of the temporomaxillary joint demonstrates that simple dislocation can occur only in one direction, namely, forward. Dislocations in other directions are complicated by fracture of the jaw or of the walls of the glenoid fossa. Dislocation of the jaw forward may be unilateral or bilateral. It is usually bilateral.

It occurs when the mouth is wide open (Fig. 43). The external lateral ligament being relaxed and the external pterygoid muscles vigorously contracting, the condyle of the jaw with the fibrocartilage is drawn over the eminentia articu-

FIG. 43.—EXTERNAL LATERAL LIGAMENT; MOUTH OPEN.

laris into the zygomatic fossa (Fig. 44). Conditions favorable to this dislocation obtain during the act of yawning, vomiting, the manipulations of the dentist, or it may be produced by a blow upon the chin when the mouth is wide open.

Treatment.—The obstacle to the reduction of this dislocation, as observed by Stimson, is the external lateral ligament. When the mouth is closed the external lateral ligament slants obliquely downward and backward (see Fig. 42). When the mouth is opened, the axis of the ligament is vertical (see Fig. 43). When the mouth is opened beyond its normal limits, the ligament relaxes and the condyle passes forward beyond the eminentia articularis. Then, by the contraction of the muscles of mastication, the ligament is made tense and the condyle is fixed in its new position (see Fig. 44). Hence, in reducing

dislocations of the jaw, the tension of the external lateral ligament must be relieved before reduction can be accomplished.

Thus it will be seen that the chin must first be depressed, *i. e.*, open the mouth wider to relax the ligament, then press the condyle backward into place. This maneuver is accomplished by placing the thumbs, well protected, in the mouth and making pressure against the anterior border of the rami while the hand depresses the symphysis.

Arthritis of the temporomaxillary joint may be secondary to inflammatory processes in the parotid gland, the middle ear, and the external auditory meatus, or may originate in the joint itself. The serious consequence of such a process is a resultant

FIG. 44.—EXTERNAL LATERAL LIGAMENT; JAW DISLOCATED.

ankylosis which obviously forms a formidable obstacle to nutrition, talking, respiration, and proper cleanliness of the mouth.

Fixation of the jaw may be due to (1) intra-articular causes:

(*a*) Bony ankylosis after destructive changes in the joint.

(*b*) Ankylosis due to adhesions following inflammatory processes.

(2) Extra-articular causes:

(*a*) Spasmodic contraction of the muscles of mastication due to some reflex irritation, as the eruption of a wisdom tooth or the toxemia of tetanus (lockjaw).

(*b*) Intrabuccal cicatrices following extensive ulcerations of the mouth.

Tumors of the lower jaw are (*a*) those connected with the teeth, odontomes (tumors composed of dental tissue), dentigerous cysts, which may attain a large size, and (*b*) fibroma, osteoma, enchondroma, sarcoma, and epithelioma. In malignant disease of the lower jaw the wisdom of early and extensive excision of the jaw is emphasized by the many and important neighboring structures which may be invaded.

Necrosis of the jaw may be the result of carious teeth or an osteomyelitis following the exanthemata. A peculiar form of necrosis of the maxillary bones sometimes develops in those employed in match factories—*phosphorus necrosis.* It begins in the form of a periostitis and terminates in necrosis. Circumscribed areas of necrosed bone form sequestra and may be easily removed. In extensive necrosis it may be necessary to resect the entire bone. If the periosteum be preserved, reproduction of the bone may take place.

The **pterygomaxillary fossa** is an irregular-shaped cavity situated between the face and the cranium. It is bounded externally by the zygomatic arch and ramus of lower jaw, internally by the external pterygoid plate; anteriorly, by the zygomatic surface of the superior maxilla; posteriorly, by the posterior border of the external pterygoid plate. Above, it communicates with the temporal fossa and at its upper and inner part are two fissures, the *sphenomaxillary* and the *pterygomaxillary fissures.*

The **sphenomaxillary fissure** is horizontal and opens into the outer and back part of the orbit. It transmits the superior maxillary nerve and its orbital branch, the infra-orbital vessels, and the ascending branches of Meckel's ganglion.

The **pterygomaxillary fissure** is vertical and forms a right angle with the preceding fissure. It communicates with the sphenomaxillary fossa and transmits the internal maxillary artery.

Contents of the pterygomaxillary fossa—all the muscles of mastication excepting the masseter, the internal maxillary artery, vein, and their branches, and the inferior maxillary nerve. The fossa is filled with a mass of fatty tissue which is continuous with that of the temporal fossa and the buccal fat of the cheek. The external pterygoid muscle occupies the greater part of the fossa.

The entire fossa is traversed from without, and in nearly a horizontal direction by the *internal maxillary artery,* which begins immediately behind the neck of the condyle of the jaw,

and, passing inward upon the outer surface of the external pterygoid muscle, reaches the sphenomaxillary fossa, giving off in its course branches to supply the deep structures of the face.

Internal to the external pterygoid muscle are the lingual, inferior dental, the auriculotemporal, and the deep temporal nerves, which traverse the space in a vertical direction. At the lower border of the external pterygoid the chorda tympani nerve joins the lingual.

The special interest attached to this fossa is its communications with neighboring regions, viz.:

(*a*) Above, with the temporal fossa.

(*b*) Below and externally, with the buccal cavity.

(*c*) In front, with the orbital cavity by the sphenomaxillary fissure.

(*d*) With the nasal fossa through the sphenopalatine foramen.

(*e*) With the cranial cavity, through the sphenoidal fissure.

(*f*) Behind it is continuous with the parotid region.

Hence, it is obvious that suppurative processes starting in this fossa may find their way into the adjacent regions or *vice versa*, and malignant growths easily spread from one region to the other.

Penetrating wounds of the fossa are dangerous because of the resulting hemorrhage. When the usual means of hemostasis is ineffectual it will be necessary to ligate the external carotid.

The **pterygoid venous plexus** is a plexus of considerable size situated between the pterygoid muscles, receiving tributary branches from the nose, orbit, face, and temporal region, and communicating with the cavernous sinus. Hence, in cellulitis of the regions drained by this plexus infective thrombosis may reach the pterygoid plexus and the cavernous sinus, and meningeal complications ensue.

The **inferior dental nerve** passes downward with the inferior dental artery beneath the external pterygoid muscle, then between the internal lateral ligament and the ramus of the jaw to the dental foramen. It passes along the dental canal in the inferior maxilla, supplying branches to the teeth. Opposite the mental foramen it divides into a mental and incisor branch, the former emerging through the mental foramen to supply the skin and mucous membrane of the lower lip and chin (Fig. 45).

This nerve is frequently the site of severe neuralgias which necessitate its resection.

Exposure of the inferior dental nerve is practical in three situations:

(*a*) *Before entering the dental canal.* Within the mouth the nerve can be located at the dental foramen which occupies a central position on the inner surface of the ramus of the jaw.

The *guide to the dental foramen* is the *lingula* (spine of Spix), a prominent sharp spine immediately in front of the foramen to which is attached the internal lateral ligament of the lower jaw. After incising the mucous membrane along the inner side of the anterior border of the ramus of the jaw and separating the fibers of the internal pterygoid muscle the sharp spine of the lingula can be easily recognized, at the base of which lies the dental foramen where the nerve can be readily exposed.

(*b*) *Within the dental canal* the nerve may be exposed by making an incision through the cheek and reflecting upward the fibers of the masseter muscle. The outer table of the

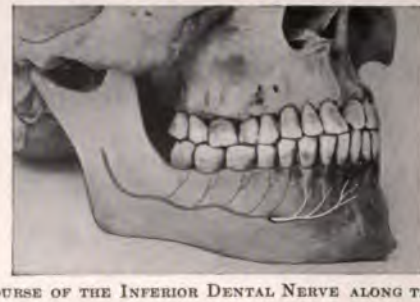

FIG. 45.—THE COURSE OF THE INFERIOR DENTAL NERVE ALONG THE DENTAL CANAL.

ramus is removed by trephining and the nerve removed from the portion of the canal exposed.

(*c*) *At the mental foramen,* by everting the lower lip and incising the mucous membrane down to the bone opposite the interval between the bicuspid teeth.

The **lingual nerve** passes between the internal pterygoid muscle and the ramus of the jaw, and becomes superficial as it reaches the floor of the mouth behind the last molar tooth and in front of the pterygomaxillary ligament.

Resection of the nerve is often necessary for the relief of intense pain associated with cancer of the tongue. It may be exposed by making an incision midway between the tongue and the prominent alveolar ridge of the last molar tooth. DaCosta advises that the knife enter ¾ inch behind and below the last molar tooth and be carried down to the bone for simple division of the nerve.

CHAPTER VII

THE ORBIT

THE orbits are the bony cavities situated between the anterior portion of the cranium and the face, and separated by the nasal fossa. They contain the globe of the eye and its appendages. The importance of this region from an anatomic and surgical standpoint is apparent. The orbital cavity is closed in front by the eyelids, which are separated from the globe of the eye by the folds of the conjunctiva. The eyeball occupies the anterior part of the orbit. The posterior portion is filled with fat, fascia, muscles, vessels, and nerves belonging to the eye. The anterior and posterior portions are separated from each other by the capsule of Tenon, a membranous sac which envelops the posterior portion of the eyeball and forms a socket in which it plays, just as the head of a bone moves in its articular cavity.

The **orbital cavity** is in the form of a quadrilateral pyramid, the base being in front and the summit behind. The largest circumference of the orbit is about 1 cm. back of the rim. The anteroposterior axes of the two cavities are not parallel; they are oblique and tend to converge posteriorly. The depth of the cavity is from 4 to 5 cm. Note here that the shape of the bony orbit being that of a quadrilateral destined to contain a spheric body—the eyeball—there are formed at the four bony angles triangular spaces which offer convenient points for exploration, either digitally or by the use of instruments (Fig. 46).

The bony walls of the orbit are very thin and are lined with periosteum which is continuous through the optic foramen with the dura mater. Anteriorly it blends with the pericranium. It is important to note that the four walls are in immediate relation with four fossæ. *Above, the anterior cerebral fossa; below, the maxillary sinus; internally, the nasal fossa; externally, the temporal fossa.* Here, therefore, is a cavity separated from four important fossæ by a thin bony wall. Foreign bodies thrust into the orbital cavity may not only injure its contents, but invade the adjoining cavities. Just

so may tumors of any one of these fossæ encroach upon the central cavity. Note, also, that the orbital cavity is circumscribed by bone except in front, where it is closed only by soft parts, the eyelids; obviously, therefore, tumors developing in the orbit will push the eyeball forward toward the point of least resistance and produce a condition of exophthalmos.

The *superior* or *cranial wall* forms the roof of the orbit and part of the floor of the anterior cerebral fossa. It is composed of the frontal bone and the lesser wing of the sphenoid. It is extremely thin and brittle, except at the base of the orbit. Its fragile character must be borne in mind when extirpating tumors of the orbit. Foreign bodies thrust into the orbit

FIG. 46.—QUADRILATERAL FORM OF BONY ORBIT.
The globe of the eye, forming within it four triangular spaces.

and entering this surface penetrate the base of the brain. It is the most frequent site of indirect fracture of the base of the skull.

The *inferior* or *maxillary wall* forms the floor of the orbit and the roof of the maxillary sinus. It is composed of the superior maxilla, the malar, and palate bones.

The inferior wall is very thin and easily destroyed by tumors which may either invade the maxillary sinus or, originating in the sinus, protrude into the orbit.

The *internal* or *nasal wall* is formed by the nasal process of the maxilla, the internal angular process of the frontal, the lacrimal, the os planum of the ethmoid, and a small portion of the body of the sphenoid. It lies very nearly in a sagittal plane and is in relation with the ethmoid cells and the nasal fossa. The wall separating the ethmoid cells is of paper

thinness; hence, in inflammation of the ethmoid cells pain is manifest on the inner orbital wall and the infection may invade the orbital cavity and produce an orbital cellulitis or abscess, with great pain and proptosis.

Slight traumatism may fracture the inner wall and *emphysema of the eyelids* result from the air in the nasal fossæ being forced into the cellular tissue of the orbit and eyelids.

The *external* or *temporal wall* is very oblique. It is formed by the malar, the external angular process of the frontal, and the great wing of the sphenoid. In an enucleation of the eye it is well to follow this wall in severing the optic nerve. Tumors of the orbit may destroy this wall and, penetrating the temporal fossa, present beneath the temporal aponeurosis.

The four angles of the orbit present some points of surgical interest. The superior internal angle is in close relation with the frontal sinus. It lodges the pulley of the superior oblique. The superior external angle is the site of the fossa which lodges the lacrimal gland. The inferior internal angle marks the superior border of the nasal orifice and the inferior external angle is the point at which the superior maxilla is detached from the malar in performing resection of the former.

The **sphenomaxillary fissure** occupies the infero-external border of the orbit. Through this fissure a means of communication is established between the orbit and the temporal, zygomatic, and sphenomaxillary fossæ. It transmits the superior maxillary nerve and its orbital branch, the infra-orbital vessels, and ascending branches from Meckel's ganglion. The periosteum which covers the fissure usually forms an effective barrier against the dissemination of pus. Tumors, however, may arise in the orbit and invade these fossæ, or *vice versa*.

The *summit of the orbit* does not correspond to the optic foramen, which occupies the superior wall, but to the **sphenoidal fissure** at its widest part. Through this fissure the orbit communicates with the cranial cavity and transmits the third, fourth, ophthalmic division of the fifth and sixth nerves, the orbital branch of the middle meningeal artery, a recurrent branch from the lacrimal to the dura mater, and the ophthalmic vein.

The **soft parts in the orbit** are contained in two separate and distinct compartments, separated by a reduplication of the orbital aponeurosis or capsule of Tenon. The anterior compartment is occupied by the eyeball, the posterior by the vessels, nerves, muscles, and orbital fat.

The **orbital aponeurosis** is the connective-tissue skeleton which holds the structures in the orbit in suspension (Fig. 47). It extends from the optic foramen forward to the circumference of the orbit, with the periosteum of which it blends. In its transit forward it sends out prolongations which ensheath nearly every structure contained in the bony orbit. The principal parts of this aponeurosis are—

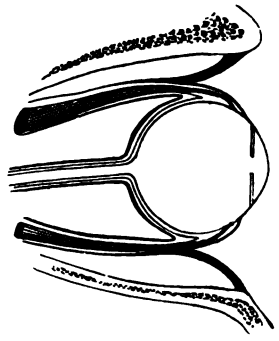

FIG. 47.—ORBITAL APONEUROSIS AND TENON'S CAPSULE (diagrammatic).

(*a*) Tenon's capsule, forming a socket for the eyeball.

(*b*) The sheaths of the muscles.

(*c*) The check ligaments, which act as an important factor in assisting and restraining the action of the muscles. Note that the orbital fascia acts as an obstructive agent in preventing the exit of pus from the orbit, and explains the tension and pain associated with *postorbital abscess*.

The **capsule of Tenon** is a reduplication of the orbital aponeurosis surrounding the posterior two-thirds of the eyeball (Fig. 48); behind it surrounds the optic nerve and is merged into its sheath.

FIG. 48.—TENON'S CAPSULE FORMING A SOCKET FOR THE EYEBALL.

Anteriorly, it is concave and in contact with the outer surface of the sclera; posteriorly, it is convex and in relation with the orbital fat.

The Function of Tenon's Capsule.—(*a*) It provides a practical joint cavity in which the eyeball moves like the head of a bone.

(*b*) It forms a partition which divides the orbital cavity into an anterior and posterior compartment.

(*c*) It permits an enucleation of the eye without opening the posterior compartment and thus lessens the danger of meningeal infection.

The **posterior compartment of the orbit** contains fat, the muscles of the eye, the ophthalmic artery and vein, and the nerves of the orbit.

The **muscles of the orbit** are the levator palpebræ superioris, the four recti, and the superior and inferior oblique.

The levator palpebræ superioris raises the upper eyelid and directly opposes the action of the orbicularis palpebrarum.

The **four recti muscles** (superior, inferior, internal, and external) arise around the circumference of the optic foramen from a common tendinous ring, the lower and inner portion of which is known as the *ligament of Zinn.* They run forward into the anterior compartment, receiving an investment from the orbital aponeurosis, and are inserted into the sclerotic coat of the eye in the following manner, so as to form the arc of a spiral, the internal rectus being inserted 5 mm. from the corneoscleral junction, the inferior 6 mm., the external 7 mm., and the superior 8 mm. (Fig. 49).

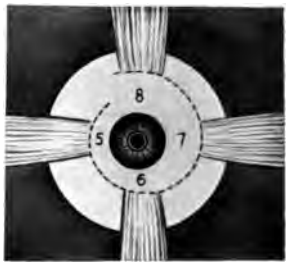

FIG. 49.—THE INSERTION OF THE RECTI MUSCLES FORM THE ARC OF A SPIRAL.

Action.—The recti muscles acting singly will turn the globe of the eye upward or downward, inward or outward. Since, however, the superior and inferior recti do not pass directly, but obliquely forward, they turn the eye slightly inward as well; this, however, is somewhat counterbalanced by the action of the oblique muscles.

The external rectus of one eye acts in association with the internal rectus of the other, as in turning both eyes to the same side. Both internal recti, however, act together in the production of convergence or in turning both eyes inward. The superior, inferior, and internal recti are supplied by the third nerve, the external is supplied by the sixth nerve.

The **superior oblique** arises a little above the upper margin of the optic foramen, traverses the upper and inner side to the inner angle of the orbit, where, as a rounded tendon, it passes through a fibrous cartilaginous ring or pulley which is lined

with synovial membrane, the *trochlear*, and then turns at an angle and passes back beneath the superior rectus to be inserted into the outer and posterior part of the globe of the eye, between the superior and external recti muscles. It is supplied by the fourth nerve. Its action is to roll the eyeball inward, and, because of its insertion into the posterior portion of the globe, to draw the cornea downward and slightly abduct it (Fig. 50).

The **inferior oblique** arises from the front of the orbit just external to the lacrimal sac, passes outward and backward under the inferior rectus muscle, then upward between the external rectus and the globe, to be inserted into the sclerotic at the

FIG. 50.—INSERTION OF THE OBLIQUE MUSCLES BETWEEN THE SUPERIOR AND EXTERNAL RECTI MUSCLES.

back of the eye, posterior to the equator of the eyeball between the superior and external recti. It is supplied by the third nerve and its action is to roll the eyeball outward and draw the cornea upward and slightly abduct it.

Action of the Orbital Muscles.—The eyeball possesses for the most part only the movement of rotation. When we speak of the eye moving up or down, in or out, we do not mean that the eyeball has changed its relative position, but that the cornea is turned in different directions, or that the eyeball has been rotated around one of its axes.

The recti muscles and the oblique muscles are as groups antagonistic, the one (recti) tending to retract, the other

oblique drawing the eye forward. They do not, however, act as isolated groups, since the eye is but slightly advanced or retracted by muscular action. The muscles act together to maintain the eye in position and cause it to move only about a center of rotation. Hence, the paralysis of a single muscle causes a certain amount of derangement of all the others.

The **ophthalmic artery,** coming from the internal carotid, enters the orbit through the optic foramen in company with and external to the optic nerve. It goes to the inner angle of the orbit, where it terminates by anastomosing with the facial. In extirpating the eye or tumors of the orbit the several small branches are easily controlled.

Branches of the ophthalmic artery supply the eyeball through the short ciliary arteries, the two long ciliary arteries, and the anterior ciliary arteries. The vessels of the conjunctiva are derived from the lacrimal and two palpebral arteries. The retina is supplied through the *arteria centralis retinæ,* which does not anastomose with the choroidal vessels; hence, when the central artery of the retina is plugged by embolism, sudden blindness follows.

The **ophthalmic vein** anastomoses with the angular vein of the facial and passes through the sphenoidal fissure to the cavernous sinus. *Thus is established an intra- and extracranial anastomosis through which infections, especially of the face, may be carried within the cranium.* Anthrax or erysipelas of the face may be followed by grave cerebral lesions from a phlebitis of the facial vein extending into the cavernous sinus. The number of vessels in the orbit explains the vascular tumors which are found there, such as arteriovenous aneurysm between the internal carotid artery and the cavernous sinus, aneurysm of the ophthalmic artery, cirsoid aneurysm, or dilatation of the ophthalmic vein. These vascular tumors are frequently the result of traumatism and give rise to pulsating tumors of the orbit.

The **nerves of the orbit** are the optic, the third, fourth, ophthalmic division of the fifth, sixth, and sympathetic. The motor nerves of the orbit are the third (motor oculi), the fourth (trochlear) and the sixth (abducens).

The **optic nerve** passes through the optic foramen to the eyeball, where it perforates the sclera posteriorly, to be expanded in the retina. The sheath of the nerve is derived from the dura mater and the arachnoid, and thus establish a communication with the subdural and subarachnoid spaces.

Note that the two points at which the nerve is constricted are at the optic foramen—just sufficient to admit its caliber—and at its entrance through the sclera (Fig. 51).

This explains how inflammatory conditions affecting the nerve, or pressure within the cranial cavity exerted through the spaces about the nerve, produce a condition of strangulation causing a neuritis which is manifest by a condition of *choked disk*.

The **motor oculi nerve** supplies all the muscles of the orbit except the superior oblique and external rectus. Through

FIG. 51.—OPTIC NERVE.
A, Note the two points of constriction.

the ciliary ganglion it supplies the sphincter muscle of the iris and the ciliary muscle (the muscle of visual accommodation). Hence, when it is paralyzed from disease, tumor, fracture of the orbit, or penetrating wounds, we may have—

(*a*) Ptosis, drooping of the upper eyelid (paralysis of the levator palpebræ).

(*b*) External strabismus (unopposed action of the external rectus) and inability to turn the eyeball up or down.

(*c*) Dilatation of the pupil (paralysis of the sphincter of the pupil).

(*d*) Loss of accommodation (paralysis of the ciliary muscle).

(*e*) Slight prominence of the eyeball (unopposed action of the superior oblique and general lack of muscular tonicity).

The **trochlear nerve** supplies the superior oblique muscle. Paralysis of the nerve causes inability to roll the eye inward.

The **abducent nerve** supplies the external rectus muscle. When paralyzed there is deviation of the cornea inward, producing convergent squint. This nerve is frequently injured in fractures of the base of the skull.

The **sensory nerves** are derived from the ophthalmic division of the fifth nerve, which divides, just before entering the orbit, into three branches: the lacrimal, frontal, and nasal.

The **lacrimal nerve** passes to the external wall of the orbit and is distributed to the lacrimal gland, the conjunctiva, and the integument of the upper eyelid.

The **frontal nerve** divides midway between the apex and base of the orbit into the supratrochlear and the supra-orbital. The supratrochlear leaves the orbit between the supra-orbital foramen and the pulley of the superior oblique, supplies the integument of the lower part of the forehead, and sends filaments to the conjunctiva and skin of the upper lid. The supra-orbital leaves the orbit through the supra-orbital foramen, gives off branches to the upper eyelid, and ascends upon the forehead supplying the integument of the scalp as far back as the vertex and the pericranium over the frontal and parietal bones.

The **nasal nerve** runs along the internal wall of the orbit, passes through the anterior ethmoidal foramen, and passes down by the side of the crista galli into the nose. In its course it gives off branches to the lacrimal gland, the conjunctiva, skin of the upper eyelid, the ciliary muscle, iris, cornea, and the mucous membrane and the skin of the nose.

The **ophthalmic ganglion** is a small ganglion about the size of a pinhead lying in the back part of the orbit on the outer side of the ophthalmic artery. It receives three roots: a motor root from the motor oculi, a sensory root from the nasal branch of the ophthalmic, and a sympathetic root from the cavernous plexus. Its branches of distribution are the short ciliary nerves which pierce the sclerotic and are distributed to the ciliary muscle, iris, and cornea.

By a careful study of this nerve distribution the many reflex sensory and motor phenomena connected with the eye are easily understood. Photophobia or intolerance of light is

associated with inflammatory affections of the eye. The reflex is sent through branches of the fifth to the facial nerve and spasm of the orbicular muscle results.

In deep inflammations of the eyeball pain is referred down the side of the nose, in the forehead, temples, and teeth of the upper jaw associated with lacrimation.

A blow on the nose or inhalation of pungent odors is followed by stimulation of the lacrimal secretions.

The **eyeball** (Fig. 52) is situated in the anterior orbital compartment. It rests behind on the capsule of Tenon, which forms a socket in which it moves with freedom. In front are the posterior surfaces of the eyelids. The orbital fat behind the capsule of Tenon gives the normal eye a certain prominence. In wasting diseases the diminution of the orbital fat causes the eye to have a sunken appearance.

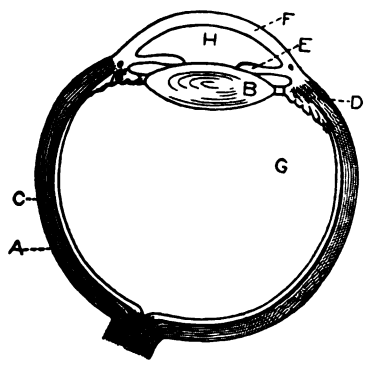

FIG. 52.—STRUCTURES OF THE EYEBALL (diagrammatic).

A, Sclerotic coat; *B*, lens; *C*, choroid; *D*, ciliary body; *E*, iris; *F*, cornea; *G*, vitreous body; *H*, aqueous chamber.

The **sclerotic** forms the tough, fibrous external capsule which encloses five-sixths of the globe and is continuous in front with the cornea. It gives insertion to the muscles which move the eyeball. Posteriorly it is pierced by the optic nerve, to which it contributes a covering, anteriorly by the anterior ciliary arteries and veins. The inelasticity of the sclera explains the severe pain suffered in conditions causing intra-ocular pressure, as in acute glaucoma. It may be wounded by foreign bodies or ruptured by violent pressure applied to the globe. Wounds of the sclera are dangerous only when the deeper structures are involved, such as the ciliary body, the lens, and the vitreous humor.

Note that the weakest point of the sclera is at the point of entrance of the optic nerve, and it is at this point that the results of excessive intra-ocular pressure are most manifest, as in the cupping of the optic disk in glaucoma.

The **cornea** is the transparent portion of the fibrous capsule of the eyeball. It forms the anterior sixth of the globe and is practically the "window of the eyeball." The cornea

contains no blood-vessels, but receives its nutrition from the lymph derived from the blood-vessels of the conjunctiva and the anterior ciliary vessels.

Arcus senilis is the appearance of a white, opaque crescent or circle at the periphery of the cornea. It occurs after middle life and is due to degenerative changes, the result of atheroma. This, however, does not apparently interfere with the healing process after operative procedures in this region.

In inflammation of the cornea (keratitis) and in ulcers, healing is followed by the formation of cicatricial tissue which gives rise to corneal opacities.

The **choroid** is the vascular and pigmentary membrane of the eye. It invests the posterior two-thirds of the globe. Externally it is connected with the sclerotic, internally it is attached to the retina. It is composed of a capillary network of arteries and veins and the connective tissue is filled with pigmented cells (Gray). The choroid is sometimes the seat of melanotic sarcoma which gradually involves and finally destroys the sight, produces violent pains by intra-ocular tension, and may invade the cranial cavity or the maxillary sinus. *It is the most frequent site of pathologic lesions within the eyeball.*

The **ciliary body** consists of the ciliary muscle and the ciliary processes. It is really a continuation of the choroid—joining the choroid with the margin of the iris. It is the "*dangerous area*" *of the eye.* Wounds in this region may involve the iris, choroid, retina, and cornea, and inflammation of the ciliary body in one eye may be followed by sympathetic ophthalmia beginning in the ciliary body of the other eye.

The ciliary muscle is the muscle of accommodation, and acts by pulling on the ciliary processes and the suspensory ligament of the lens, and thus accommodates the eye to different distances. *Deep wounds of this body almost always necessitate enucleation of the globe.*

The **iris** is the colored circular curtain between the cornea and the lens. At its center is an opening, the pupil, which varies in size according to the intensity of the light. It is really a window through which light enters the interior of the eye. When the light is strong the pupil contracts, when it is feeble the pupil dilates. The pigment in the iris determines the color of the individual's eyes. The iris and ciliary body are continuous; hence, inflammations of the iris are apt to extend to the choroid. As a result of iritis adhesions may form either

to the cornea in front (anterior synechia) or to the capsule of the lens (posterior synechia). *This emphasizes the necessity of immediate dilatation of the pupil in iritis with plastic exudate.*

The **Argyll-Robertson pupil** is one which does not contract under the reflex stimulation of light, but retains its contraction for convergence and accommodation. It is due to the abolition of the pupillary reflex and is a symptom of posterior spinal sclerosis.

The **retina** is a delicate membrane forming the inner tunic of the eye. Externally it is in contact with the choroid, internally with the vitreous body. It is essentially the nervous membrane of the eye, and within it are spread out the fibers of the optic nerve. The retina depends entirely upon the central artery for its blood supply, and if an embolus plug the artery, sudden blindness ensues.

The **lens** is a biconvex transparent body enclosed in a capsule and situated behind the pupil and in front of the vitreous body. It is held in position by the zone of Zinn or suspensory ligament of the lens, which is a thickened portion of the capsule extending from the lens to the ciliary body.

The action of the ciliary muscle varies the tension of this ligament and the focal distance of the lens, and thus *accommodation* is accomplished. The lens is the site of *cataract*, a condition characterized by opacities of varying extent caused by traumatism, senile changes, or malnutrition.

The **vitreous body** is a soft, jelly-like substance which fills the cavity of the retina. In front is a small concavity for the reception of the lens. It is enclosed in a delicate transparent membrane, the hyaloid membrane.

The **aqueous chamber** is really a large lymph space between the cornea and the lens. It is divided by the iris into an anterior and posterior chamber, which communicates through the pupil. The external angle of the anterior chamber is called the filtration angle, and it is here that the excess of aqueous humor escapes into the spaces of Fontana and thence through the canal of Schlemm into the anterior ciliary veins, thus reducing intra-ocular tension (Deaver).

Glaucoma is a disease characterized by increased intra-ocular tension, causing hardness of the eyeball, pain, and impairment of vision. It is due to obstruction of the filtering angle whereby the aqueous humor is unable to make its exit through the canal of Schlemm. The excess of fluid in the eyeball causes increased tension.

Enucleation of the eye consists of the removal of the eyeball without opening the capsule of Tenon. The eyelids being separated by a speculum, the ocular conjunctiva is incised around the corneal border and pushed back over the eye. The rectus muscles are hooked up and divided at their insertions. The eyeball is drawn forward and the optic nerve severed with scissors passed along the outer or inner side of the globe. The eye is drawn out of the orbit, all retaining structures are divided, and the conjunctival wound closed by suture.

Tumors acquire a peculiar gravity because of their tendency to compress the optic nerve and the globe of the eye, and finally force it from the orbit and destroy it.

Cysts of the orbit sometimes develop in the pulley of the superior oblique muscle and from the orbital portion of the lacrimal gland.

Lipomas of the orbit, though rare, present a soft, nonreducible, nonpulsating tumor appearing at the circumference of the orbit. Sarcoma and carcinoma may invade the posterior part of the orbit and necessitate an exenteration of the orbital contents.

Orbital emphysema may follow fracture of the nose involving the ethmoid cells and nasal sinuses. The air in the connective tissue may cause protrusion of the eyeball and may spread to the eyelid. The emphysematous collection is increased by blowing the nose.

Foreign bodies may penetrate the orbit and remain *in situ* for many years. Tillaux reports a case of a bullet penetrating the right orbit, passing behind the eyeball without injuring it, and coming out of the left orbit after destroying the eye of that side. Of interest also is Furneaux Jordan's well-known case of a man employed in threshing who became the subject of severe ophthalmia and after several weeks ejected from the lower eyelid some pus, in which was found a grain of wheat.

The **eyelids** are two movable musculomembranous curtains placed in front of the eyeball for purposes of protection and lubrication. The outer surface of the eyelid is covered by skin which is thin and freely movable over the lax subcutaneous tissue. Edematous swellings and extravasations of blood readily form beneath it and are particularly conspicuous. The inner surface is lined with the conjunctival mucous membrane. The interval between the two eyelids is the palpebral fissure. The points at which the two eyelids unite are the *internal* and *external canthi;* at the inner margin of the inner

canthus is a small red elevation known as the *caruncula lacrymalis*. At the free margin of the eyelids are the eyelashes, some modified sweat-glands, and sebaceous glands; and just behind are found the orifices of the ducts of the Meibomian glands. The eyelids are composed of the following layers: skin, tarsal cartilage, and conjunctiva. The margins of the lids are particularly prone to inflammatory changes. Inflammation of the hair-follicles (blepharitis) is a common affection. Chronic inflammatory changes may cause contraction of the conjunctiva and the lid may be curled inward toward the globe and produce a condition of **entropion.**

Ectropion is an eversion of the lid caused either by a defect in the tonicity of the eyelid, seen in the aged, or it is the result of cicatrix following injury. It not only produces deformity, but compromises the eye because of its lack of protection.

The common *stye* is an inflammation of one of the sebaceous glands of the lid.

Meibomian cyst is a retention cyst of the Meibomian glands.

The eyelids are richly supplied with blood from the palpebral and lacrimal branches of the ophthalmic. They are frequently the seat of vascular growths, such as *nevi*.

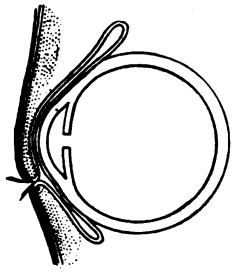

FIG. 53.—REFLECTIONS OF CONJUNCTIVA.
Note formation of superior and inferior sacs.

The **nerves of the eyelids** are the supra-orbital, the supra- and infratrochlear, the lacrimal to the upper lid, and the infra-orbital to the lower lid.

The **lymphatics** of the eyelids empty into the parotid and submaxillary lymph-glands.

The **conjunctiva** is the delicate mucous membrane lining the posterior surface of the eyelids and reflected over the anterior portion of the sclera as far as the cornea, to which it imparts its epithelial lining. This explains corneal invasion of conjunctival diseases by continuity of structure. At the free border of the lids it blends with the integument (Fig. 53).

The palpebral portion lining the lids is thick, vascular, and adherent; the bulbar portion over the eye is much thinner and very loosely attached. Over the cornea it consists only of epithelium and forms the anterior layer of the cornea.

Subconjunctival hemorrhages may occur from violent coughing or vomiting, or they may appear in fracture of the

base of the skull. In these hemorrhages the blood retains the arterial color (Treves). These hemorrhages are readily absorbed and leave no permanent impairment of the eyeball.

The conjunctiva is particularly exposed to inflammatory processes. After wounds or burns adhesions may take place in which the two lids become fused together, or the lid may adhere to the globe.

The **lacrimal apparatus** consists of—

(*a*) The lacrimal gland and its excretory ducts.

(*b*) The lacrimal canals, the lacrimal sac, and the nasal duct (Fig. 54).

The **lacrimal gland** is the organ that secretes the tears. It is almond-shaped and is lodged in a bony depression at the

FIG. 54.—LACRIMAL APPARATUS.

superior and external part of the orbit. It is contained in a fibrous sac which separates it from the surrounding structures and renders enucleation possible without opening the posterior orbital cavity. It must be remembered that in the extirpation of this gland for excessive lacrimation the secretion does not cease, since the conjunctiva itself secretes about half the total quantity. In structure the lacrimal gland resembles a salivary gland and its secretion is conveyed by six to twelve ducts which open at the upper cul-de-sac of the conjunctiva near the external canthus. The tears are thus excreted at the upper and outer portion of the orbit, flow over the eyeball, and by the action of the eyelids are swept toward the inner canthus,

where they are carried to the inferior meatus of the nose by accessory ducts which consist of—

The **lacrimal canals** (Fig. 51), the superior and inferior, surround the lacrimal caruncle at the inner canthus. They begin in two elevated pin-point openings (the *puncta lacrymalia*) and unite in an ampulla which empties into the lacrimal sac.

The **lacrimal sac** (Fig. 54) is the upper dilated portion of the nasal duct which is lodged in a deep groove between the nasal process of the superior maxillary and the lacrimal bone. In front of the sac is the tendo oculi, to which it is attached by a fibrous expansion. Thus, when the orbicularis palpebrarum contracts in closing the eyelids, the tendo oculi is made

FIG. 55.—THE NASAL DUCT.

taut and a vacuum is formed in the sac, so that the tears are sucked through the lacrimal canals into the sac.

The lacrimal sac is situated just below the lower end of the frontal sinus. Infections of the sinus may be transmitted to the sac and produce a dacryocystitis.

The **nasal duct** (Fig. 55) is a direct continuation of the lacrimal sac. It is three-quarters of an inch long and descends in a bony groove formed by the superior maxillary, the lacrimal, and the inferior turbinated bones. It opens into the inferior meatus through a slit-like aperture—the *valve of Hasner*. The direction of the duct is downward, outward, and backward, in a line which, if extended, would strike the first molar tooth of the lower jaw on the corresponding side.

Surgical Considerations.—The lacrimal gland may be the seat of abscess, or cystic, benign, or malignant degeneration. The gland may be readily removed by making an incision just below the eyebrow and the gland with its capsule extirpated without invading the general cavity of the orbit. Any obstruction of the lacrimal tubes from foreign body, injury, or inflammation, or a deviation of the lower punctum as a result of ectropion or entropion may result in a condition of *epiphora* or overflow of tears. The guide to the lacrimal sac is the tendo oculi lying in front of the sac, which can readily be felt or seen when the eyelids are drawn forward.

CHAPTER VIII

THE NOSE AND NASAL CAVITIES

THE nose forms a triangular pyramid with its base behind. It is separated from the face by the nasogenial grooves and from the lips by the nasolabial groove. These grooves are utilized in making incisions in extirpation of the superior maxillary bone.

The skin over the root of the nose and adjacent parts is thin and loose, and can be utilized in plastic operations of the face. Over the alæ it is thick, adherent, and abundantly supplied with sweat and sebaceous glands which stud the surface with their excretory orifices. The sebaceous material coming in contact with the air collects the dust and gives rise to the so-called "blackheads."

The sebaceous glands of the nose are frequently the site of acne. Sometimes a chronic inflammatory process appears, leading to hypertrophy of the skin, capillary network, and subcutaneous fascia, and produces an enlarged red nose which may attain an enormous size (*acne rosacea*).

The skin of the lower part of the nose is also very commonly attacked by lupus, which may successively destroy all the coverings of this region.

The foundation of the nose is formed by the nasal processes of the superior maxillæ, the nasal bones, and the nasal spine of the frontal. The rest of the organ is composed of two lateral cartilages, placed on either side of the nostril, to which they give contour. When these cartilages have been destroyed it is impossible, by any operative measures, to restore the nose to its original form.

Fracture of the nasal bones usually occurs from direct violence. The resulting deformity depends upon the direction of the force. In addition to the ordinary signs of fracture we may get epistaxis and subcutaneous emphysema.

Sometimes the perpendicular plate of the ethmoid is involved in the fracture, in which case there may be a communication with the base of the cranium and cerebrospinal fluid may flow from the nose. Union takes place after these fractures with

greater rapidity than after fracture of any other bone of the body (Treves).

Syphilis and tuberculosis have a predilection for the framework of the nose, frequently destroying the bridge of the nose and giving it a sunken appearance (saddle-nose), which results in a hideous deformity.

Deformities of the nose may be ameliorated by various methods of rhinoplasty, such as taking a flap of skin from the forehead and, with its pedicle twisted, applying it to the root of the nose, or a flap from the forearm may be applied to the nose while the arm is held in position till the flap unites.

The **arteries of the nose** are remarkable for their number and size. The facial supplies branches to the sides of the nose; the superior coronary supplies the septum and alæ, and the ophthalmic sends branches to the root and the dorsum.

The great vascularity of the tissues causes wounds of the nose to heal rapidly and admirably adapts it for plastic operations. The veins follow the course of the arteries. Those at the root empty into the ophthalmic and thence into the cavernous sinus. Inflammations in this region, erysipelas, etc., may, through this communication of the extra- and intracranial circulation, send infected emboli to the brain.

The nose is rich in lymphatics which communicate with the parotid and submaxillary glands.

The **nerves** supplying the skin of the nose are the infratrochlear branch of the nasal to the integument of the root and the terminal branches of the nasal, to the integument of the alæ and tip of nose. The side of the nose is supplied by the second division of the fifth; hence, painful affections about the root of the nose or the nostrils are accompanied by lacrimation, which is explained by the intimate connection between the nasal nerve and the lacrimal gland.

The **nasal cavities** are two intricate fossæ specially adapted for receiving odors and warming the air as it passes to the lungs. They communicate in front with the exterior (*anterior nares*), behind with the pharynx (*posterior nares*). The nostrils form a vestibule which is placed in front of the fossæ.

Relations.—The nasal cavities are situated below the cranium, below and internal to the orbital cavities, above the arch of the palate, and between the maxillary sinuses.

The two cavities represent a triangular pyramid with the apex above and the base below. In the middle is a partition (the septum) extending from the apex to the base and dividing

the pyramid into two parts, corresponding to the two fossæ. The internal surface is smooth and perpendicular, the external surface is irregular and oblique.

The **roof of the nasal cavity** represents the apex of the pyramid. It is very narrow and extremely thin. It is formed by the cribriform plate perforated by foramina through which pass the branches of the olfactory nerve. This portion of the nose is difficult to explore. Sharp instruments may easily penetrate its fragile wall and open the anterior fossa of the skull. Traction on a polypus attached at this point has caused the thin wall to yield and open up a communication with the cranial cavity. Tillaux reports the interesting case of an optician who had a constant dropping of cerebrospinal fluid, amounting to a half pint a day, which appeared after the removal of a polypus attached to the nasal roof. The position of the head influenced the flow. If it was lowered the flow was incessant, if thrown back, it stopped entirely. The patient was observed for a year and the flow continued unabated. Cases of meningocele protruding through the nasal roof have been mistaken for polypus.

The **floor of the nasal cavity** represents the largest part of the fossa and is situated above the level of the anterior nares. Its width is about a half inch. It forms the superior surface of the vault of the palate and slopes gradually from before backward.

The **septum** forms a median vertical partition between the two fossæ. It is composed of the perpendicular plate of the ethmoid, the vomer, and the septal cartilage. It is thin and covered by mucous membrane which is not very adherent. It is subject to deviations, in fact it is rare to find the septum perfectly straight in adults. When the deviation is pronounced, it may obstruct the nostril and may be mistaken for nasal tumor, polypus, etc., and when sufficient to cause obstruction operative means may be employed for its correction.

The **outer wall** is characterized by prominences, depressions, and orifices.

There are three bony prominences which dip down from the outer wall into the nasal cavity—the superior, middle, and inferior *turbinated bones* (Fig. 56). The superior turbinated forms a very slight relief, the middle is more prominent, and the inferior the most voluminous of the three. They all present similar dispositions. They are directed downward and inward and curve outward at their free border.

The superior and middle turbinated bones come from the ethmoid. The inferior is a special bone. The recesses between the turbinal bones and the outer wall are called the meatus and contain the orifices of the accessory sinuses (Fig. 57).

FIG. 56.—SUPERIOR, MIDDLE, AND INFERIOR TURBINATED BONES, SEEN FROM WITHIN OUT.

The **superior meatus,** situated between the middle and superior turbinals, contains the opening into the sphenoidal sinus and the opening of the posterior ethmoidal cells.

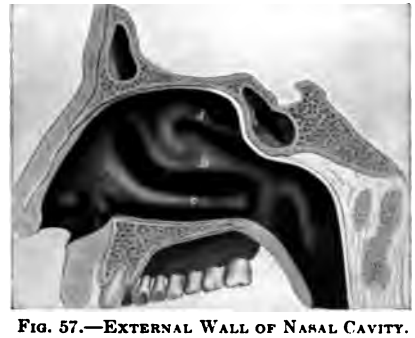

FIG. 57.—EXTERNAL WALL OF NASAL CAVITY.
A, Superior; *B*, middle; and *C*, inferior turbinals.

The **middle meatus,** between the middle and inferior turbinals, presents at its upper and anterior part a deep groove, the *infundibulum* into which opens the communication from the frontal sinus (Fig. 58, *A*). It also contains the openings

from the maxillary sinus (Fig. 58, *B*) and the anterior ethmoidal cells.

The **inferior meatus**, between the inferior turbinal and the floor of the nose, is the largest of the three. It contains the inferior orifice of the nasal duct, about ¾ inch above the nasal floor (Fig. 58, *C*).

In **examining the nasal fossæ** it is well to remember—

(*a*) That the plane of the nostril is below that of the floor of the nares; hence, the head should be carried backward and the nose drawn upward.

(*b*) The greatest diameter of the anterior nares is the vertical diameter. The nasal speculum should, therefore, be opened in a vertical direction.

(*c*) The anterior extremity of the middle turbinal is directed upward, that of the inferior turbinal downward; hence, the middle meatus is very large and open in front. Again, the inferior meatus is but slightly raised above the floor of the nasal fossa, so that in introducing instruments, therefore, it is much easier to get into the middle meatus. In order to get into the inferior meatus it is necessary to keep the point of the instrument well toward the floor of the nasal fossa.

Fig. 58.—Bases of Superior, Middle, and Inferior Turbinated Bones and Relation of the Orifices.

(*d*) The posterior orifices of the nasal fossæ are in the form of an ellipse with the greatest diameter in the vertical direction (2.5 cm.). They are separated by the posterior margin of the vomer and limited externally by the internal pterygoid process.

The shape and size of these apertures are important in tamponing the posterior nares in cases of epistaxis.

The **mucous membrane** of the nose is continuous with all the cavities communicating with it. The superior or olfactory portion is thin and less resistant. It covers the cribriform plate of the ethmoid and contains the terminal endings of the olfactory nerves.

The respiratory portion is thicker and more vascular; it forms a sort of loose cushion covering the parts, and these pads of mucous membrane have been mistaken for polypi.

The mucous membrane is attached to the periosteum by a

deep fibrous layer. Its glands are in clusters, very abundant, and disseminated over the lower and posterior parts of the outer wall and the free border of the turbinated bones.

These glands may become hypertrophied and in cases of coryza give rise to a copious watery secretion. In the ordinary "cold in the head," the obstruction in the nose is due to the swelling of the mucous membrane covering the inferior turbinals. This congestive swelling is accounted for by the rich venous plexus which lies beneath the mucous membrane.

Polypi have a predilection for the nasal fossæ. They may be (*a*) myxomatous, springing from the mucous membrane, usually of the middle or inferior turbinals. They may block the nostrils and obstruct respiration. They may press outward, widen the nose, and project through the anterior or posterior nares.

(*b*) Fibrous or sarcomatous polypi arising from the periosteum of the nasal roof; they grow in all directions, invading the orbit, the cranial cavity, the maxillary sinus, and the pharynx. Obstruction of the nasal duct, causing epiphora, may be an early symptom.

The **blood supply** is derived principally from the internal maxillary, the ophthalmic, and facial arteries.

The veins accompany the arteries and form a rich network beneath the mucous membrane of the middle and inferior turbinals. This is so pronounced over the inferior turbinal that the mucous membrane here is referred to as "the erectile body."

The ethmoidal veins empty into the superior longitudinal sinus, the nasal vein through the ophthalmic into the cavernous sinus. This communication between the extra- and intracranial circulation explains the relief from violent headache after nosebleed; and, again, infectious processes in the nose may thus be carried into the cranium.

Epistaxis.—Bleeding from the nose is a frequent occurrence and may sometimes assume serious proportions. It may be the result of fracture of the base of the skull (anterior fossa) or it may be due to engorged capillaries or to the ulceration of an artery.

Treatment.—Pressure on the upper lip to occlude the artery of the septum or by raising the arms to increase the expansion of the chest and lessen the pressure in the veins. Cold applied to the back of the neck stimulates the vasomotor center. If the bleeding be profuse and prolonged it will be necessary to

plug the anterior and posterior nares with cotton or gauze. In every case the patient should maintain the erect position; the head should not be allowed to hang over a basin, as this attitude compresses the jugular veins and increases the venous engorgement.

The **lymphatics** of the nasal fossæ go to the submaxillary and parotid glands.

The **nerve supply** is the nerves of special sense (olfactory) distributed to the roof and the inner and outer walls near the roof, and branches from the first and second divisions of the fifth. The inhalation of strong irritants causes excessive

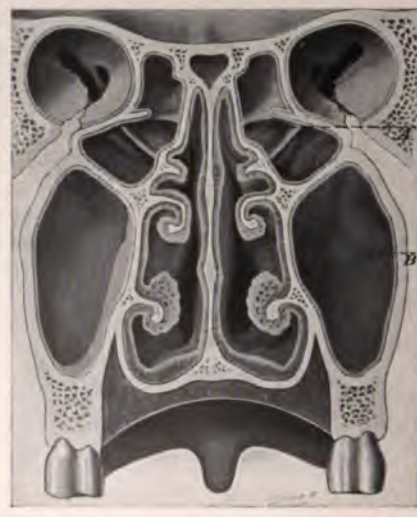

FIG. 59.—RELATION OF THE NASAL FOSSÆ TO THE SINUSES.
A, Ethmoidal cells; *B*, maxillary sinus.

lacrimation because of the nasal nerve communicating with the ophthalmic, and, conversely, strong sunlight on the eyes will produce an attack of sneezing.

The **accessory sinuses of the nose** (Fig. 59) are:

(*a*) The frontal sinuses.
(*b*) The maxillary sinuses (antrum of Highmore).
(*c*) The sphenoidal sinuses.
(*d*) The ethmoidal cells.

The **frontal sinuses** (Fig. 60) are cavities situated in the anterior and lower part of the frontal bone. They are above and external to the nasal cavities and above and internal to the

orbital cavities. They may be considered osseous cells of the diploe considerably enlarged, limited in front by the external table and behind by the internal table.

The frontal sinuses do not exist at birth, but begin to grow at puberty and reach their development by the twentieth year. The two sinuses are separated by a bony septum which thins out as the sinuses grow and sometimes disappears by absorption. The septum also deviates to the right or left, so that one sinus is always larger than its fellow. Bouyer observes that the more developed the frontal sinuses, the less are the sphenoidal, and *vice versa*.

FIG. 60.—FRONTAL SINUS AND SURFACE LOCATION.

The frontal sinuses communicate with the middle meatus of the nose. The outlet is found in the highest part of the infundibulum, lying beneath the middle turbinal.

The lining mucous membrane is continuous with that of the nose and contains some small glands and a few nerve filaments. The dimensions of the frontal sinus, according to Taylor, are: height, 1¼ inches; breadth, 1 inch; depth, ¾ inch.

Fracture over the frontal sinus may be depressed without injuring the cranial contents. These fractures may be associated with emphysema of the surrounding tissues due to the communication with the nose. Living bodies such as larvæ

may lodge within the frontal sinus and give rise to symptoms of great intensity.

Inflammation of the mucous lining of the frontal sinuses may be secondary to inflammation within the nose. When pus forms within these sinuses it may drain into the nasal fossa, or if the communication with the nose is blocked by swelling of the lining membrane it gives rise to grave complications by destroying the internal table and infecting the cranial contents, or it may perforate the wall of the orbit and produce grave symptoms in the eye.

FIG. 61.—ANTRUM OF HIGHMORE AND SURFACE LOCATION.

When pus is diagnosed in the frontal sinus the sinus should be opened by trephining over the inner portion of the supra-orbital margin.

The **maxillary sinus** (antrum of Highmore) (Fig. 61) is a pyramidal cavity in the interior of the superior maxilla. It is bounded above by the inferior wall of the orbit, which is traversed by a canal occupied by the infra-orbital nerve, below by the alveolar arch which carries the molar teeth, in front by the facial surface of the superior maxilla, behind by the zygomatic surface of the superior maxilla, internally by the thin outer wall of the nasal fossa.

The base of the pyramid is directed toward the nose, the apex toward the malar process of the superior maxilla. This

sinus exists from birth, it enlarges at puberty, and continues to grow until adult life, acquiring its maximum development in the aged.

It is lined with mucous membrane continuous with that of the nose. The floor of the antrum is frequently the site of projections formed by the alveolar processes of the molar teeth, especially the first and second. Hence, caries of the molar teeth may be the cause of an infective process in the antrum. The antrum is also easily opened through the alveolar processes of the first and second upper molars.

FIG. 62.—ANTRUM OF HIGHMORE.
White arrow natural drainage; black arrow, surgical drainage.

The orifice of the antrum (sometimes double) opens into the infundibulum of the middle meatus of the nose, *the greater part of the sinus being below the orifice.* Hence, fluids necessarily accumulate in the antrum, the orifice being so situated that it can only drain off the overflow (Fig. 62).

The maxillary sinus is more frequently the site of suppurative processes than any of the other accessory sinuses of the nose, infection taking place—

(*a*) Through the upper molar alveoli.

(*b*) By way of the nose, primarily, or secondarily, by discharges from the frontal sinus flowing into the infundibulum and invading the orifice of the antrum. When pus collects within the antrum there is no natural drainage. The normal opening of the antrum simply carries away the overflow; hence, these processes run a chronic course, and if the normal outlet becomes blocked the accumulation of pus may give rise to severe neuralgia (infra-orbital) or it may invade the orbit, the ethmoid cells, or open externally.

Methods of Opening the Antrum.—(*a*) Through the alveolar processes of the first and second molars (Fig. 62).

(*b*) Through the anterior wall of the antrum, on a level with the canine fossa.

(*c*) From the inferior meatus, through the external wall of the nasal fossa.

The simplest method is to extract the first molar tooth and penetrate the cavity through the alveolar process, directing the drill upward and inward. This opening is well adapted for drainage, since it is located in the most dependent portion of the cavity.

Tumors of the antrum may be either malignant or benign. The malignant tumors grow rapidly, and by pressure upon the walls of the antrum they may advance upward, pushing forward and disorganizing the eyeball; growing downward they involve the palate and loosen the teeth; inward they obstruct the nostril, and backward they invade the pharynx. The treatment of malignant growths of the antrum is excision of the superior maxilla.

The Ethmoidal Sinuses or Cells (see Fig. 61).—The lateral masses of the ethmoid bone contain the anterior and posterior ethmoidal sinuses. The anterior cells open directly into the middle meatus of the nose; the posterior cells open into the superior meatus of the nose. The cells are lined with mucous membrane continuous with that of the nasal cavity.

Like the other accessory sinuses, the ethmoidal cells may be the site of inflammatory processes originating in the cells or they may be secondarily infected from the frontal and maxillary sinuses through the proximity of the orifices in the middle meatus.

Inflammation in the ethmoid cells may extend into the orbit or into the cranial cavity. Taylor observes that a feature of ethmoidal inflammation is the frequency with which it is associated with intranasal polypi.

The **sphenoidal sinuses** are situated in the body of the sphenoid bone which projects below into the superior wall of the nasal fossa. They are two in number, separated by a vertical septum. They do not exist at birth, but appear about the twentieth year. They are lined with mucous membrane continuous with that of the nose, and their orifices are situated behind the posterior extremity of the superior turbinated bone at a higher level than the body of the sinus, the direction of the drainage being similar to that of the maxillary sinus. They may be the site of inflammatory trouble and malignant or benign growths.

The rôle of the sinus is considered purely a mechanical one. They appear at the age of puberty at a time when the face increases in volume, and they provide an increase of surface without augmenting the weight.

CHAPTER IX

THE MOUTH, TONGUE, AND PHARYNX

THE **mouth** is the cavity at the beginning of the alimentary canal in which the food is prepared by mastication and insalivation for further elaboration in the stomach.

It consists of two parts—

(*a*) **The vestibule** (Fig. 63 *A*)—the space in front of the teeth, when the jaws are closed, bounded by the lips, cheek,

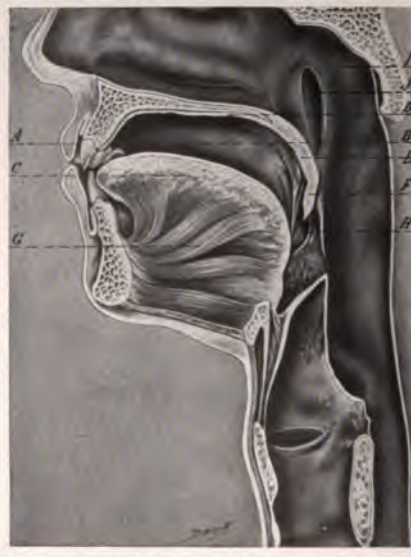

FIG. 63.—VERTICAL SECTION OF MOUTH AND PHARYNX. (After Deaver.)
A, vestibule; *B*, cavity of mouth proper; *C*, tongue; *D*, hard palate; *E*, soft palate; *F*, uvula; *G*, geniohyoglossus muscle; *H*, tonsil; I, nasopharynx; J, orifice of Eustachian tube.

and alveolar arches. About the circumference of this space are formed the superior and inferior cul-de-sacs by the reflection of the mucous membrane of the lips and cheek on the upper and lower alveolar arches.

Alveolar abscesses always appear in the circumference of the vestibule.

Stenson's duct opens in the external wall of the vestibule opposite the second molar tooth of the upper jaw.

The vestibule communicates with the buccal cavity through the space behind the third molar tooth, which space may be utilized in lockjaw for feeding the patient.

The coronoid process of the lower jaw is external to the dental arch and its anterior border may be felt in the vestibule. When dislocated it is specially prominent, and its appreciation is an aid in establishing a diagnosis of unilateral or bilateral dislocation.

(*b*) The **cavity of the mouth proper** (Fig. 63 *B*), situated behind the teeth and limited in front and on the sides by the alveolar arches; the roof is formed by the hard and soft palate; the floor is formed by the tongue and its reflections of mucous membrane to the gum of the lower jaw. It communicates behind with the pharynx through the isthmus of the fauces.

The **lips** are two fleshy folds which circumscribe the mouth and close the buccal cavity in front. At the sides they unite and form the commissures. The internal surface is covered by mucous membrane, the external surface by the integument, and between the two are found the orbicularis muscle, the coronary vessels, nerves, and labial glands.

The skin of the lips is thick and adherent to the subjacent muscular layer. It contains hair-follicles and sebaceous glands and is frequently the site of furuncle, anthrax, and syphilitic ulceration. The lower lip is a favorite site for epithelioma. The lips are exceedingly vascular and nevi occur in this region with great frequency.

The **orbicularis oris** muscle is the sphincter muscle of the mouth continuous at the angles with the buccinator and the muscles of expression. It gives extreme mobility to the mouth. The general direction of its fibers is circular and in vertical incisions it causes separation of the wound edges.

The **labial glands** are situated between the mucous and muscular layer and are embedded in loose connective tissue. Their ducts open upon the mucous membrane. They may be the site of abscess or they may hypertrophy to such an extent as to require excision. When the ducts of the glands become occluded they give rise to mucous cysts of the lips. Congenital fistulæ on the inner surface of the lip originate in cysts of this region.

The **arteries,** the inferior and superior coronary, are branches of the facial and anastomose in the median line.

They are situated between the muscle and the mucous membrane and nearer the free than the attached border of the lips. In vertical incision of the lip hemorrhage from the coronary arteries is easily controlled by slight compression and rarely needs a ligature.

The **veins** accompany the arteries and flow into the facial vein. It will thus be seen that there is a communication between the lips and the intracranial circulation which has an important pathologic bearing in labial abscess and anthrax.

The **lymphatics** are drained by the submental and submaxillary glands and are found enlarged in cancer.

The **nerves** are motor branches from the facial and sensory branches from the infra-orbital nerve to the upper lip, and from the mental to the lower lip.

The lips are very mobile, elastic, and vascular, and permit extensive plastic operations to be performed with success.

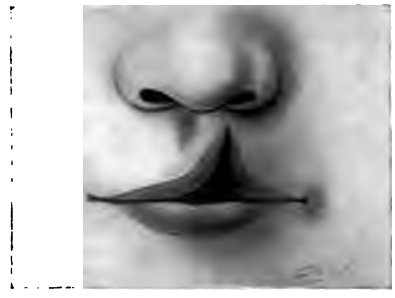

FIG. 64.—HARE-LIP.

Hare-lip is a cleft of the lip due to arrest of development. The lower lip develops from two centers which fuse in the median line and a congenital fissure of the lower lip rarely occurs. The upper lip develops from three centers: a median, represented by the frontonasal process, and the two lateral, corresponding to the superior maxillary processes. When these processes fail to unite on one or both sides of the frontonasal process, there results a unilateral or bilateral (single or double) harelip (Fig. 64). Note, therefore, that hare-lip is a lateral cleft, not a median one. The deformity may consist only of a notch in the upper lip or it may extend up into the nostril and be associated with a cleft palate. It is more common on the left side.

In double hare-lip the median portion of the lip may be

attached with the intermaxillary bone to the projecting nasal septum (persistent fetal type), since the intermaxillary bone, the nasal septum, and the median portion of the lip are developed from the same center.

The intermaxillary bone contains the germs of the incisor teeth; the cleft in hare-lip, therefore, corresponds to the interval between the lateral incisors and the canine teeth.

The treatment of hare-lip by plastic operation is attended with satisfactory results. The projecting intermaxillary bone may be an obstacle to satisfactory union of the soft parts, but *it should not be removed*, since it contains the germs of the incisor teeth and is an indispensable factor in obtaining a satisfactory cosmetic result. If the projecting bone cannot be sufficiently reduced by forcibly crowding it back, a portion of the vomer which prevents reduction may be excised. When there is a cleft palate complicating hare-lip, it is wise to close the labial cleft first, as this procedure has the effect of narrowing the palatal cleft.

The **gums** consist of a fibrous layer of tissue closely surrounding the neck and penetrating the interstices of the teeth, and connected with the alveolar periosteum. It is covered with mucous membrane which, although quite vascular, is paler than the surrounding buccal mucosa and possesses only a slight degree of sensibility.

At the level of the neck of the tooth the periosteum is prolonged into the alveolus and constitutes the alveolar periosteum of the tooth.

When caries attacks a tooth, infection may spread and give rise to a subperiosteal abscess or *gum-boil*. Because of the dense membrane under which the pus forms, intense pain is suffered until the pus is evacuated either spontaneously or by incision. These seemingly slight alveolar infections may be followed by necrosis or a fistulous tract opening on the cheek. In the upper jaw the inflammation may extend into the antrum and produce an empyema.

In *mercurial poisoning* manifested by excessive secretion of saliva (ptyalism) there is a spongy and congested condition of the gums which causes them to ulcerate and bleed easily.

Lead-poisoning manifests itself in the gums by the formation of a blue line of sulphid of lead along their margins, caused by the decomposition of organic material about the teeth.

Epulis is a term applied to a class of tumors which are connected with the gums. It may be a simple hypertrophy of the

fibrous tissue of the gum (fibrous epulis) or it may spring from the periosteum and become sarcomatous (malignant epulis).

Fixation of the Teeth.—1. By means of the alveoli in the jaws which form sockets for the teeth.

2. The alveolar periosteum is continuous with the fibrous layer of the gum which, after closely investing the neck of the tooth, is prolonged into the alveolus between the root and the alveolar wall lining the entire surface of the root, and at the bottom of the alveolus is continuous with the sheath of the vessels and nerves which enter the root.

This periosteal investment is thick in infancy, diminishes in adult life, and becomes imperceptible in the aged.

Re-implantation.—A tooth which has been completely separated from its alveolus may be reinserted and become solidly fixed, but never regains its sensibility.

Transplantation.—Teeth have been successfully transplanted from one patient to another. The apparent difficulties attending this procedure and the resources of modern dentistry render this operation of little practical value.

Pyorrhea alveolaris (Rigg's disease) is a purulent inflammation of the dental periosteum which, unchecked, leads to necrosis of the alveoli and loosening of the teeth.

While the extraction of a tooth is ordinarily a simple procedure, it is well to remember that in exceptional cases hemorrhage is severe, and in hemophiliacs it has been attended with fatal results.

The **teeth** appear at two periods of dentition. The result of the first dentition is the twenty *temporary teeth* (four incisors, two canine, and four molars in each jaw).

The result of the second dentition is the thirty-two *permanent teeth* (four incisors, two canines, four bicuspids, and six molar teeth in each jaw) (Fig. 65).

Remember that—

(*a*) The first of the temporary teeth appear in the seventh month and the first of the permanent teeth in the seventh year.

(*b*) The lower teeth appear before the upper, the median incisors appearing first.

(*c*) The first dentition is complete at the end of two and a half years.

(*d*) In the second dentition the first molars (six-year molars) are the first to appear. The second molars (twelfth-year molars) appear from the twelfth to the fifteenth year and the

third molars (wisdom teeth) appear from the twentieth to the thirtieth year. The eruption of the wisdom teeth is often attended with trismus of the jaw and abscess. Failure of these teeth to erupt may be the cause of cyst of the jaw.

(*e*) The evidence of hereditary syphilis is seen in the permanent teeth, "*Hutchinson teeth.*" Their characteristics are their uneven arrangement and the crescentic notch in the cutting edge, especially marked in the upper central incisors.

FIG. 65.—THE PERMANENT TEETH.
A, Central incisor; *B*, lateral; *C*, canine; *D*, first bicuspid; *E*, second bicuspid; *F*, first molar; *G*, second molar; *H*, third molar.

The **tongue** (Fig. 66) occupies the floor of the mouth, and is composed of a mass of intrinsic and extrinsic muscles covered by mucous membrane. Its function is complex. Not only is it the organ of the special sense of taste, but it assists, by its great mobility, in mastication and deglutition and is an important factor in the production of articulate speech.

There exists between the muscular fibers very little connective tissue and a small quantity of fat, so that abscess of the tongue is rare. When it does occur, it is characterized by a hard and prominent swelling, which may be mistaken for a solid tumor due to the close texture of the tongue and the thickness of the mucosa.

Glossitis (cellulitis of the tongue), although uncommon, sometimes occurs, and the swelling may be so intense as to fill the pharynx and provoke asphyxia.

The tongue is attached to the os hyoides by the hyoglossus muscle, to the styloid process by the styloglossus muscle, and to the lower jaw by the genioglossus muscle and the mucous mem-

brane reflected on the alveolar arches. It is also connected with the epiglottis and soft palate. It will be observed that the tongue is moved about or held in place by its extrinsic muscles; hence, when during anesthesia these muscles become paralyzed, the tongue may fall back and obstruct the breathing by closing the larynx. Such an accident is overcome either by placing the fingers behind the angle of the jaw and pulling it forward so that the genioglossus muscle may pull the tongue away from the pharyngeal air-passage, by grasping the tongue with tongue-forceps and pulling it forward, or by anchoring it with

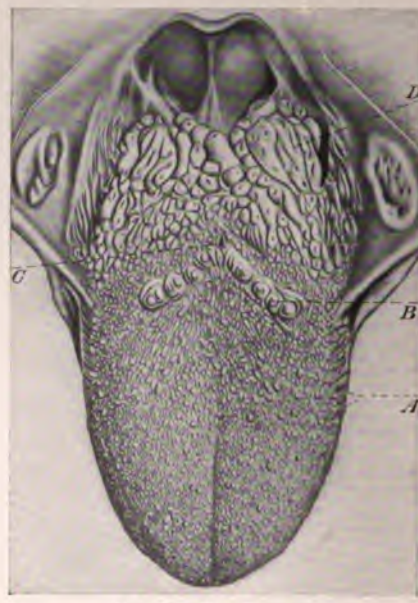

FIG. 66.—THE TONGUE.
A, Papillæ (fungiform); *B*, papillæ (circumvallate); *C*, foramen cecum; *D*, lingua tonsillar tissue.

a silk suture passed through its center. Likewise, in excision of the middle portion of the inferior maxilla, where the genioglossus muscle is divided the tongue may suddenly fall back and cause asphyxia. After the completion of such an operation the patient should be watched for some hours and the tongue anchored by a silk suture as a precautionary measure.

When the tongue is raised from the floor of the mouth there is observed a median fold of mucosa, the *frenum* (Fig. 67), which passes from the inferior surface of the tongue to the body

of the lower jaw. Occasionally this fold of mucosa may extend to the tip or be abnormally short, and thus produce a condition of "*tongue-tie*" which may prevent the infant from properly nursing or later on interfere with articulation. This condition is easily remedied by section of the obstructing band of tissue. On each side of the frenum are the prominent ranine veins (Fig. 67 *D*) which give the mucosa a bluish tinge; and further down on each side, near the dental arch, is an elliptic prominence which marks the site of the *sublingual glands* (Fig. 67 *C*). Its excretory ducts (ducts of Rivinus), eight to twenty, open separately into the mouth upon an elevated crest of mucous

FIG. 67.—THE UNDER SURFACE OF THE TONGUE.
A, Frenum; *B*, Wharton's duct; *C*, sublingual gland; *D*, ranine vein; *E*, lingual nerve.

membrane situated on either side of the frenum, posterior to Wharton's duct.

Wharton's duct occupies the floor of the mouth, passing between the sublingual gland and the genioglossus muscle, and opens on the summit of a prominent papilla at the side of the frenum (Fig. 67 *B*). The duct is about 5 cm. in length and runs straight until it reaches its termination, where it is bent like a crochet needle (Tillaux). The buccal orifice is narrow and very contractile; it is possible, however, to catheterize the duct with a fine stylet. In this region the lingual nerve at first lies external to Wharton's duct, then, looping beneath it passes to the tip of the tongue.

It will be noted that while Wharton's duct occupies the floor

of the mouth, its gland, the submaxillary, occupies the suprahyoid region of the neck; hence, salivary calculi in the canal will present under the mucosa of the floor of the mouth; salivary calculi of the gland present below the jaw.

Beneath these important structures in the floor of the mouth will be found the genioglossus and the geniohyoid muscles, and supporting all these structures like a hammock are the mylohyoid muscles, swung from the mylohyoid ridges of the lower jaw and the body of the hyoid bone, the muscular fibers of the two sides joining in a median fibrous raphe. Thus, there is formed a muscular diaphragm which separates the structures of the floor of the mouth, from those of the neck.

Ranula is a term which has been loosely applied to all cysts in the floor of the mouth; but, as Sutton observes, cysts in this situation may be of various kinds and the name ranula should be restricted to cysts which originate in connection with the ducts of the salivary glands. Tillaux contends that a cystic dilatation of Wharton's duct from impacted calculus never occurs, since the walls are not distensible and the tension and pain would be so intense as to preclude a slow-forming cystic tumor.

Ranula is probably a retention cyst of one of the sublingual ducts. It usually presents a prominence in the sublingual region and may interfere with speech and deglutition. Its cure is affected only by dissecting out the lining membrane and suturing the edges of the cyst to the surrounding mucosa.

The **mucous membrane of the tongue** on the under surface is thin and smooth, and resembles the mucosa lining the rest of the buccal cavity.

The dorsal surface of the tongue is covered by mucous membrane which is distinctively characteristic.

The anterior two-thirds (papillary portion) is covered with a membrane which bristles with papillæ. In the center is the median raphe, which marks the septum between the muscles of the two sides and which terminates behind at the *foramen cecum* (see Fig. 66 *C*), the orifice of the obliterated thyroglossal duct. The largest of the *papillæ* are the *circumvallate*, about ten in number, arranged in the form of a V, the apex of which is directed backward toward the foramen cecum. These papillæ contain the taste-buds (see Fig. 66 *B*).

The posterior third (pharyngeal portion) contains no papillæ, but presents numerous prominences and depressions due to the submucous lymphoid tissue. This lymphoid tissue is known as the *lingual tonsil* (see Fig. 66 *D*). These lymphoid

follicles are nipple-like, with an umbilicated center which leads to a funnel-shaped cavity analogous to the crypts of the pharyngeal tonsil.

The lingual tonsil when hypertrophied is a frequent source of irritation, and may become sufficiently enlarged to interfere with respiration by depressing the epiglottis.

The tongue is rich in glandular tissue situated between the mucosa and the muscles. The *glands of Blandin or Nuhn,* situated on the inferior surface, near the tip of the tongue, and the *glands of Weber,* situated posteriorly on the lateral border, secrete mucus. Occlusion of their ducts may give rise to retention cyst (Fig. 68).

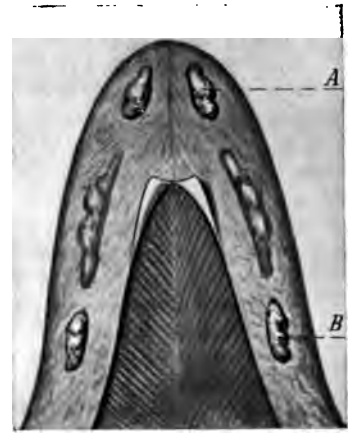

FIG. 68.—THE INTRINSIC GLANDS OF THE TONGUE.
A, Gland of Nuhn; *B*, gland of Weber.

In the region of the taste-buds are the *serous glands* (glands of v. Ebner), which secrete abundantly at the moment of gustation.

Diagnostic Value of the Tongue.—The condition of the mucous membrane of the tongue is an index of health or disease, especially the state of the gastro-intestinal tract.

The *coating* or *fur* upon the tongue is composed of desquamated epithelium, micro-organisms, and food debris. Hence, we note the white furring of the tongue in gastro-intestinal disorders, the dry, brown and fissured tongue in typhoid, and the "strawberry tongue" in scarlet fever, etc. Unilateral furring of the tongue may result from nerve irritation or paralysis.

The **intrinsic muscles of the tongue** are the superior lingualis, the inferior lingualis, the transverse lingual, and the vertical lingual. The inferior set are the most important; they extend from the apex to the base and are attached behind to the hyoid bone. A fibrous septum extends vertically downward from the median raphe and divides the tongue into two halves.

The **vessels of the tongue** are derived from the lingual, the facial, and ascending pharyngeal arteries. The veins empty into the internal jugular. The anatomy of the lingual artery

is described in the submaxillary region (pages 153 and 164). In front of the hyoglossus muscle they run forward, as the *ranine arteries,* along the under surface of the tongue to its tip.

The **lymphatics** accompany the lingual vein and pass to the submental, the deep cervical (internal jugular chain), and submaxillary lymph-glands. There is, however, little or no lymphatic connection between the two sides of the tongue in the anterior half.

The **nerves of the tongue** are five in number; the hypoglossal nerve is the motor nerve of the tongue.

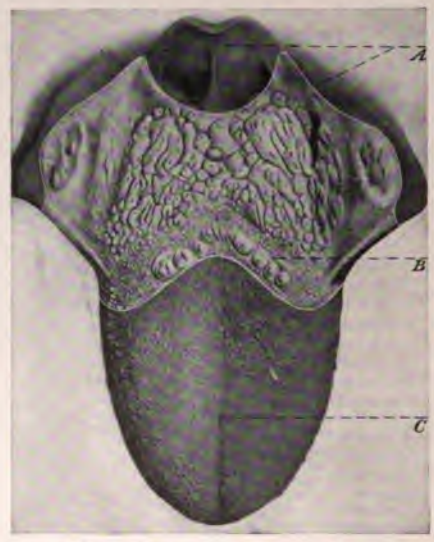

FIG. 69.—AREAS OF NERVE DISTRIBUTION ON THE SURFACE OF THE TONGUE.
A, Areas supplied by the internal laryngeal nerve; *B*, area supplied by the glossopharyngeal nerve; *C*, area supplied by the lingual nerve.

The lingual nerve supplies sensation to the anterior two-thirds.

The chorda tympani nerve is the nerve of taste for the same area (Fig. 69).

The glossopharyngeal supplies sensation and taste to the posterior third.

The internal laryngeal nerve supplies sensation to the root of the tongue near the epiglottis.

Pain in the tongue may be reflected to the ear through the auriculotemporal nerve; to the lower teeth and gums through the inferior dental nerve; and likewise trismus of the muscles

of mastication may be provoked through the motor fibers of the inferior maxillary nerve. The pain in cancer of the tongue is often so severe as to demand section of the lingual nerve.

Wounds of the tongue are rare. They may necessitate the introduction of a suture if the margins gape open. Hemorrhage is often severe and difficult to control if the artery be involved. Ligation of the lingual artery may sometimes be necessary.

Foreign bodies in the tongue may cause an induration which simulates cancer.

Macroglossia is a congenital enlargement of the tongue due to hypertrophy of the lymphoid tissue of the tongue. It may assume such dimensions as to protrude from the mouth and necessitate an excision of such a portion as will reduce it to normal size.

Ulcerations.—The tongue is frequently the site of syphilitic, tubercular, and malignant ulcers. The early recognition of the nature of these ulcerations, especially the latter, is of vital importance to the patient.

Leukoplakia lingualis, the formation of white patches on the surface of the tongue, are often the starting-point of an epithelioma.

Cancer of the tongue has many points of anatomic interest, both as to the course it pursues and its operative treatment. It usually starts as an ulcer with an indurated base on the side of the tongue, frequently opposite a jagged tooth which for a long period has been a source of irritation. It is accompanied by great pain, which radiates to the ear or lower teeth (see p. 61). It rapidly invades the entire organ, due to the mobility of the tongue. (Note the difference in the rapidity of malignant growths in parts that are movable and those that are fixed.)

Regional involvement follows the local process, and the tongue becomes fixed to the floor of the mouth and lower jaw. The lymphatic involvement must be understood from an anatomic standpoint or no satisfactory operation can be performed.

First: It must be remembered that the lymphatics in the anterior half of the tongue do not communicate across the median line; hence, when the disease is not extensive, and confined to one side of the anterior half of the tongue, it may be successfully removed by splitting the tongue down the center and removing the affected portion.

Second: If the disease involves the posterior half of the

tongue the entire tongue must be removed, although but one side is apparently involved. In this portion of the tongue the lymphatics communicate across the median line, and malignant disease of one side presupposes the involvement of the other.

Third: The lymph from the two halves of the tongue mixes in the posterior portion, and may be carried thence to either of both lymphatic chains in the neck. Hence, *any effectual extirpation of the lymphatics must include both sides of the neck.*

FIG. 70.—HAUPTGANGLION OF KÜTTNER.
A, The principal lymphatic terminus of the tongue.

Fourth: The most important lymphatic terminus of the tongue is in the large gland placed on the internal jugular vein immediately beneath the posterior belly of the digastric (Poirier)—the "*hauptganglion*" of Küttner (Fig. 70).

Excision of the Tongue.—The more the rapid progress of cancer of the tongue is appreciated, with its early lymphatic involvement, the less will surgeons resort to the incomplete

method of oral excision, except in those cases where the disease is circumscribed and confined to one side of the anterior half, when the affected portion may be removed by splitting the tongue down the center.

Preliminary ligation of the lingual artery in the lingual triangle (see pages 153 and 154) is a simple and effectual procedure in lessening the amount of hemorrhage, since there is little or no anastomosis between the two halves of the tongue through the median septum.

In the large majority of cases complete extirpation of the tongue, with the lymphatic glands on both sides of the neck, is the only procedure which offers a chance of cure. The best exposure of the parts to be removed is made by splitting the lower lip in the median line, dividing the lower jaw at the symphysis, and forcibly separating the two halves (Sedillot). After extirpation of the diseased structures the bone is replaced and sutured with silver wire.

The tongue may also be the site of lymphosarcoma, especially at the base; papillomas, lipomas, fibromas, and angiomas are fairly common.

The **palate** forms the superior wall or roof of the buccal cavity. It consists of two portions, the hard palate in front, with an osseous base; the soft palate behind, composed of soft tissues (Fig. 71).

The **hard palate** consists of an osseous base covered by mucous membrane. It forms a partition between the buccal and nasal cavities. The vault of the palate represents a flat arch resting on the lateral pillars of the alveolar arches and supporting, in the median line, the nasal septum (Tillaux). The bony portion of the vault is formed by the palate processes of the superior maxillæ and the horizontal portion of the two palate bones. This wall is very thin toward the median line, but thickens as it approaches the alveolar arches.

Its surface is rough and is perforated by foramina for the passage of vessels and nerves. The most important of these is the *posterior palatine canal*, situated on the inner side of the alveolus of the third molar tooth. Through this aperture is transmitted the posterior palatine artery and the great palatine nerve.

The mucous membrane of the hard palate is remarkable for the number of rugosities which it presents. The median raphe is very distinct and terminates in front in the *incisive papilla*, which overlies the anterior palatine foramen. On

each side of the raphe and in front are the transverse ridges which form the *palatine rugæ*. They vary in number and in prominence, becoming less distinct as age advances. The mucous membrane of the hard palate possesses many characteristics of practical importance.

(*a*) It is so intimately connected with the periosteum that it practically forms a mucofibrous membrane.

(*b*) It is thin in the median line; thickest on the sides near the alveolar arch, due to the interposition of mucous glands which are lacking in the median line.

FIG. 71.—PALATE AND ALVEOLAR ARCH.
A, Hard palate; *B*, soft palate; *C*, uvula; *D*, tonsils; *E*, posterior palatine artery; *F*, anterior and posterior pillars of fauces.

(*c*) It is tough and vascular, and large flaps can be utilized by the surgeon in plastic operations.

The *arteries* are the important factors in the pathology and operative technique of this region.

The *main nutrient artery* is the *posterior palatine*, which leaves the posterior palatine foramen and runs forward on the hard palate *near the alveolar margin* as far as the anterior palatine canal, where it anastomoses with the nasopalatine artery (see Fig. 71 *E*). The artery is placed nearer the deep than the superficial surface. The clinical importance of these arteries will be shown in discussing the operation of uranoplasty.

Necrosis of the hard palate may follow when it is denuded of its mucous membrane, and pathologic processes which produce

this, such as gumma, tubercular ulceration, and abscess, are often followed by perforation of the vault of the palate. Abscess of the hard palate should be opened as soon as possible to avoid necrosis.

When a pathologic perforation of the hard palate occurs there is established a communication between the nose and mouth which has no tendency to close spontaneously, and which, because of its offensiveness and its interference with articulation, debars the patient from social intercourse. Either a plastic operation or the wearing of a prosthetic apparatus will be necessary to remedy the defect.

The **soft palate** is the mobile fold of tissue continuous with the hard palate which, during deglutition and breathing through the mouth, assumes a horizontal position and forms a sort of valve to intercept all communication between the pharynx and posterior nares.

When the soft palate is not developed, when it is the seat of a pathologic perforation, or when it is paralyzed in diphtheria, it loses its function of a valve, and as the patient swallows the liquids return by the nasal fossæ and the voice acquires a nasal sound. The posterior border of the soft palate is free and is divided into two separate arches by the *uvula*, a median cone-shaped prolongation which varies in length in different individuals. The uvula may become so elongated that it irritates the pharynx and produces spasms of coughing. It will then be necessary to excise the hypertrophied portion.

From the uvula two folds of mucous membrane pass outward and downward on either side and constitute the *anterior and posterior pillars of the fauces*. The anterior pillars are formed by the palatoglossi muscles, covered by mucous membrane, and are attached to the tongue. The posterior pillars are formed by the palatopharyngei muscles, covered by mucous membrane, and are attached to the sides of the pharynx.

Between the two pillars is a fossa in which lodges the tonsil. The soft palate is about ¼ inch thick, and consists of two layers of mucous membrane which separate at the adherent border and unite at the free border. Beneath the mucous layers there is a considerable amount of adenoid tissue together with the muscles, vessels, and nerves.

The **palatal aponeurosis** forms the foundation of the soft palate and occupies its anterior third. It is attached to the posterior border of the hard palate and blends with the expanded tendon of the tensor palati muscle.

The **muscles of the soft palate** are, in addition to the palatoglossus and palatopharyngeus, which form the anterior and posterior pillars of the fauces, the levator palati, tensor palati, and azygos uvulæ.

These muscles, with the exception of the azygos uvulæ, unite in the median line with those of the opposite side and exercise a certain lateral traction, so that in operation for repair of a cleft of the palate, the operation must include division of the levator palati and palatopharyngeus muscles, otherwise the contraction of these muscles may pull apart the edges of the flap and render the operation useless.

The **vessels** of the soft palate are not important and are nearly absent in the median line where division can be made

FIG. 72.—CLEFT PALATE.

with little hemorrhage. They are derived from the ascending palatine branch of the facial, the posterior palatine branch of the internal maxillary, and the palatine branch of the ascending pharyngeal artery.

The **nerves** come from the small posterior palatine and the accessory palatine.

The **lymphatics** communicate with the deep cervical glands beneath the angle of the jaw.

Cleft palate (Fig. 72) is a congenital gap in the palate due to arrest of development and can be understood only by an intelligent appreciation of the changes which take place in the formation of the nasal and buccal cavities during fetal life.

First: In early fetal life the nasal and buccal cavities are one.

Second: The formation of a partition between these two

cavities is accomplished by the development of the palate which proceeds by the palatal plates of the superior maxillary bones and the palate bones growing horizontally inward on each side and meeting in the median line and thus closing the fetal gap between the two cavities.

Third: The fusing of the palatal plates does not form a complete partition; there still remains a V-shaped interval in front, the apex of which is at the anterior palatine canal, the sides extending to the interval between the lateral incisor and canine teeth (Fig. 73). This interval is filled by the intermaxillary bones, which are developed from the frontonasal

FIG. 73.—SHOWING THE INCOMPLETE FUSION OF THE PALATAL PLATES AND THE V-SHAPED INTERVAL FILLED BY THE INTERMAXILLARY BONE.
A, Median articulation; *B*, intermaxillary bone.

process, forming the septum of the nose. The central segment of the upper lip is also developed with the same process.

Bearing in mind the foregoing facts, it is readily seen that an arrest of development will produce a median gap or cleft which varies in degree from a notch in the soft palate to a complete gap involving both the soft and hard palates as far as the anterior palatine canal. If the cleft extends beyond this point and involves the alveolar margin it leaves the median line and follows the suture line of the intermaxillary bone, the anterior extremity of the cleft appearing between the lateral incisor and canine teeth. If the cleft involves only one side of the intermaxillary bones single hare-lip is usually

present, if it involves both sides of the intermaxillary bones double hare-lip is produced and the intermaxillary bones are attached to the tip of the nose.

This condition is a serious menace to the nutrition of the infant, since it is impossible for the infant to suck or satisfactorily swallow the food introduced into the mouth. Children with cleft palate should be fed in the upright position, so that the fluid will gravitate directly into the pharynx.

The Operative Treatment of Cleft Palate—Uranoplasty.—For the successful closure of cleft palate by plastic operation it is necessary to keep well in mind the anatomic factors which play such an important part in obtaining satisfactory results.

The closure of the cleft is accomplished by freshening the edges of the cleft, detaching mucoperiosteal flaps from the hard palate, and uniting them by suture in the median line. The point of prime importance in this operation is the *preservation of the vitality of the flaps.* Remember that the important arteries are the posterior palatine, and *gangrene cannot occur if we preserve the posterior palatine arteries in the flap.*

Rule.—*Make the incisions close along the inner border of the alveolar process and parallel to the alveolar arch, to avoid the posterior palatine artery and retain it uninjured in the flap.*

The flaps detached from the hard palate are tough and have no tendency to contract. The flaps of the soft palate contain the palatal muscles and may contract to such an extent as to pull out the sutures. This accident can be avoided by division of the muscles on each side by an anteroposterior incision through the entire thickness of the soft palate at the inner side of the hamular process.

The **tonsils** are two prominent lymphoid masses situated on the lateral walls of the pharynx in a recess between the anterior and posterior pillars of the fauces.

The form of the tonsil has been compared to that of an almond with its long axis vertical. Externally it corresponds to the angle of the jaw and when inflamed produces a swelling at this point. The pharyngeal surface is covered with mucous membrane and presents the openings of from twelve to fifteen crypts, which extend into the substance of the tonsil.

Blood Supply.—The *arteries* supplying the tonsils are derived from the ascending palatine and tonsillar of the facial, the ascending pharyngeal from the external carotid, the ascending palatine of the internal maxillary, and the dorsalis linguæ.

The veins form a small plexus, the tonsillar plexus, which joins the pharyngeal plexus, and empty into the internal jugular.

The **lymphatics** pass to the submaxillary lymph-glands below the angle of the jaw and thence to the deep cervical glands.

The **nerves** are supplied by branches from the glossopharyngeal nerve and the pharyngeal plexus.

Hypertrophy of the tonsils is a frequent result of repeated attacks of tonsillitis, and because of the obstruction which they offer to respiration and deglutition they give rise to a series of phenomena which offer a serious impediment to proper growth and development.

(*a*) Respiration cannot be carried on through the nose. The patient sleeps with the mouth open and snores.

(*b*) There is an alteration in the quality of the voice, the tones are guttural and thick.

(*c*) The lymphoid tissue about the Eustachian opening may share in the hypertrophy and deafness result.

(*d*) Arrest of development of the chest results from long-continued, insufficient expansion.

Hence, these should be anticipated by excision of chronically enlarged tonsils.

It is well to keep in mind that hypertrophied tonsils also occur in connection with Hodgkin's disease and lymphatic leukemia.

Tonsillotomy.—The operation for excising the tonsils is a simple procedure and, as a rule, attended only by slight oozing of blood. When the hemorrhage is excessive it can readily be controlled by pressure against the bleeding surface with a sponge in a sponge-holder while counterpressure is made behind the jaw.

The *source of tonsillar hemorrhage* is worthy of consideration, since the internal carotid artery still continues, in the minds of some operators, a possible factor in tonsillar hemorrhage.

Note the following facts:

(*a*) The *internal carotid artery is relatively remote from the tonsil*, lying an inch behind and external to the tonsil.

(*b*) *It is impossible to wound the internal carotid artery in tonsillotomy.* When the tonsil is drawn forward by a tenaculum for excision, the distance between the tonsil and artery is still further increased.

(*c*) The external carotid artery is even more remote, lying still further externally.

(*d*) The tonsillar arteries, as they penetrate the capsule, are surrounded by a fibrous sheath which causes them to gape open after being cut and likewise prevents retraction. This fact explains the abundant hemorrhage which sometimes occurs (Hodenpyl).

(*e*) Excessive hemorrhage sometimes comes from one of the tonsillar arteries which may be abnormally large—very frequently the tonsillar branch of the facial.

In *abscess of the tonsil* following a peritonsillitis (quinsy) the pus is situated between the tonsil and the pharyngeal wall.

While it is possible for the pus to burrow outward and ulceration of the coat of the artery result in fatal hemorrhage, there is *no danger of wounding the internal carotid artery* in incising a tonsillar abscess, providing:

(*a*) The blade of the scalpel be guarded by adhesive plaster to within ½ inch of the point.

(*b*) The knife enter the most prominent point of the abscess.

(*c*) The incision be made in an inward direction.

Neoplasms of the Tonsil.—It may be primarily the site of epithelioma or may be invaded by cancerous growths of neighboring organs. Lymphosarcoma is occasionally observed.

Malignant disease of the tonsil is characterized by rapidity of growth and extension to the neighboring lymphatics. Ulceration from such growths may invade the internal carotid and cause death by sudden hemorrhage.

Malignant growths of the tonsil should be removed by doing a pharyngotomy through an incision along the anterior border of the sternomastoid muscle. Removal of the growth and neighboring lymphatic glands is only possible by means of wide incision and extensive dissection.

The **pharynx** may be regarded as a large vestibule common to the respiratory and digestive tracts. It is a musculomembranous cavity extending from the base of the cranium to the superior orifice of the esophagus which corresponds to the inferior border of the cricoid cartilage. Into this vestibule open, in front, the nasal fossæ, the buccal cavity, and the larynx; on the sides, the Eustachian tubes.

The inspired air and food never occupy the pharynx at the same time. When deglutition takes place the soft palate assumes the horizontal position and acts like a valve, closing

the nasal fossæ above. The larynx is closed by the epiglottis below.

The orifice by which the buccal cavity communicates with the pharynx is known as the *isthmus of the fauces*, bounded by the soft palate, the base of the tongue, and the anterior pillars of the fauces. As food passes the isthmus into the pharynx, the mouth is shut off from the pharynx by an approximation of the pillars of the fauces and an elevation of the back of the tongue to the palate (Woolsey). The isthmus marks the line of demarcation between voluntary and reflex, or involuntary, movements. Thus, when foreign bodies pass beyond this point they enter the esophagus.

The pharynx is about 4½ inches in length. It is widest opposite the hyoid bone (1¾ inches). Its inferior opening, where it terminates in the esophagus, is narrowest (¾ inch). The distance from the incisor teeth to the lower extremity of the pharynx is about 6 inches. The inferior extremity of the pharynx corresponds to the sixth cervical vertebra. Foreign bodies passing into the pharynx are apt to be arrested at its inferior opening and by pressure upon the superior orifice of the larynx cause suffocation.

The **nasopharynx** is the portion of the pharynx behind the nasal fossæ and above the level of the soft palate (see Fig. 63). Its lateral walls are the site of the *pharyngeal orifices of the Eustachian tubes*, which lie about .5 cm. behind the posterior ends of the inferior turbinated bones. Just behind the Eustachian orifice is a deep depression, the *fossa of Rosenmüller*, which, according to His, represents the remains of the upper part of the second branchial cleft. This fossa may be a source of error in catheterizing the Eustachian tube, since the point of the catheter may easily engage in the fossa instead of the orifice.

On the posterior wall of the nasopharynx, extending between the Eustachian openings, is a mass of lymphoid tissue which constitutes the *pharyngeal tonsil* (Luschka's tonsil). It is well developed in children and frequently undergoes hypertrophy, giving rise to *adenoid growths* of the nasopharynx.

The lymphoid tissue surrounding the Eustachian orifice is known as the *tubular tonsil of Gerlach.*

Postnasal adenoids constitute a serious obstacle to the proper growth and development of the child. Their presence is marked by the following phenomena:

(*a*) *Imperfect Respiration.*—The nasal fossæ being obstructed and nasal respiration being impossible, the patient becomes

a mouth breather, in consequence of which the nasal cavity and the accessory sinuses do not reach their full development and the bony frenum of the upper face has a flattened appearance. The mouth being constantly open, the features are elongated and expressionless. As the teeth develop, respiration through the mouth causes them to protrude forward, producing a condition known as "buck teeth."

The deficiency of inspired air causes lack of development of the thorax and the subjects are flat-chested.

(*b*) *Imperfect Audition.*—The extension of the hypertrophic tissue about the Eustachian tubes closes the orifices and causes partial deafness or otitis media.

(*c*) *Imperfect Phonation.*—The mass of lymphoid tissue in the vault of the pharynx deprives the voice of its resonance and these patients talk thick and muffled.

In view of these unpleasant consequences the early removal of postnasal adenoids is demanded.

The Lymphatic Ring of Waldeyer.—The ensemble of lymphoid tissue which occupies the true pharynx constituted by the pharyngeal tonsil, the tubular tonsil of Gerlach, the palatine tonsil, and the lingual tonsil form a ring of lymphoid tissue which Waldeyer has named the lymphatic pharyngeal ring.

The buccal portion of the pharynx lies between the soft palate and the base of the tongue. The posterior wall corresponds to the vertebral column, and by introducing the finger through the mouth the upper three vertebræ may be explored for tumor, fracture, and dislocation.

The tubercle on the anterior arch of the atlas is opposite the prolongation of the soft palate. The axis is on a line with the edge of the upper teeth; the body of the third cervical vertebra can also be palpated below. The laryngeal portion of the pharynx extends from the epiglottis and base of the tongue to the inferior border of the cricoid cartilage. It is funnel-shaped from above down, and at its apex opposite the sixth cervical vertebræ it is continuous with the esophagus.

The pharyngeal wall is composed of mucous membrane, fascia, and muscles. It contains a large amount of lymphoid tissue, and is separated from the prevertebral fascia by a very loose layer of connective tissue, which forms a sort of bursa to allay the friction of constant movements.

The pharyngeal muscles are the three constrictors which form a thin, muscular sheet and overlap each other from below

upward. Beneath the base of the skull the superior constrictor is deficient. This muscular gap is the *sinus of Morgagni*, through which the levator palati and the Eustachian tube enter the pharynx.

These constrictor muscles enable the pharynx to handle the bolus in deglutition. In tetanus, contraction of these muscles forms an obstacle to deglutition.

Retropharyngeal abscess may be acute, due to inflammation of the loose cellular tissue between the pharyngeal wall and the vertebræ or an inflamed lymphatic gland; it may be chronic, originating in caries of the cervical vertebræ.

In either case it presents a prominence in front on the pharyngeal wall and may extend to the sides of the neck. It interferes with respiration and deglutition, and if it discharges spontaneously into the pharynx it may give rise to asphyxia and septic pneumonia.

These abscesses may be evacuated by an incision through the pharynx (always with the head hanging low to prevent the pus getting into the larynx), or better, by an incision along the posterior border of the sternomastoid muscle below the level of the mastoid process. The incision is deepened by blunt dissection till the abscess cavity is reached.

The **blood supply of the pharynx** is furnished by the ascending pharyngeal artery, from the external carotid, and branches from the facial, lingual, and superior thyroid. The veins flow into the internal jugular.

The **lymphatics** are numerous and flow either into the submaxillary or retropharyngeal lymphatics.

The nerves are furnished by the trifacial, the facial, the glossopharyngeal, and the pneumogastric.

CHAPTER X

THE NECK

THE neck is that portion of the trunk which connects the head and thorax and provides a passageway for the important structures which pass between the head and thorax. The many vessels and nerves and other important vascular and visceral structures which it contains, the numerous operations to which it is subject, make the neck a region of practical interest to the surgeon.

Its *limits* above are: the lower border of the jaw, a line extending from the angle of the jaw to the mastoid process, and the superior curved line of the occipital bone.

Below: the sternal notch, the clavicles, and a transverse line from the acromioclavicular articulation to the spinous process of the seventh cervical vertebra.

The contour of the neck varies according to age and sex. In women and children it is well-rounded; in men it is more or less angular. Hence, the landmarks of the neck are more conspicuous in men.

Topographically, the neck may be divided into an anterior and posterior portion. The anterior portion, in front of the vertebral column, contains the respiratory tube—larynx and trachea—and the alimentary tube—pharynx and esophagus—and, on the sides, the great vessels and nerves. The posterior portion contains the cervical segment of the spine and the surrounding muscles.

The anterior region of the neck is covered by fine and mobile skin, beneath which is an abundance of cellular tissue. Thus, it is admirably adapted for plastic operations. It likewise favors contraction following extensive burns which may produce marked deformity. The skin covering the posterior region is very thick and adherent. It contains numerous sebaceous glands, which explains the frequency of furuncles in this region.

Carbuncle very frequently attacks the subcutaneous connective tissue at the back of the neck. The density of the

tissues and their slight vascularity explain the severe pain and the extensive slough which characterize this process.

Beneath the skin, and closely attached by a layer of cellular tissue, is the *platysma myoides*, a broad, thin, muscular sheet, the fibers of which are parallel and directed obliquely from the lower jaw, the subcutaneous tissue of the lower part of the face, and muscles about the angle of the mouth to the fascia of the deltoid and pectoral regions. Thus, its action is to depress the

FIG. 74.—ACTION OF PLATYSMA MYOIDES MUSCLE.

lower jaw and to draw down the lower lip and angle of the mouth (Fig. 74).

The **external jugular vein** is readily seen through the skin when well filled, extending from the angle of the jaw to the middle of the clavicle, where it perforates the deep fascia and empties into the subclavian vein. It lies behind the platysma and crosses the sternomastoid obliquely, from before backward. The superficial lymph-glands lying in the course of this vein can be readily felt beneath the skin, when enlarged.

THE REGIONS OF THE NECK

The arrangement of the muscles on the sides of the neck is such that they naturally divide it into certain regions or triangles which may be utilized for purposes of description.

First, the anterolateral region of the neck may be viewed as a quadrilateral, the upper boundary being the lower border of the jaw and a line extending from the angle of the jaw to the tip of the mastoid process. The lower boundary is formed by

the clavicle, the sides by the median line of the neck in front, and the trapezius muscle behind.

The most conspicuous and important landmark of the neck is the sternomastoid muscle. When thrown into action it is seen beneath the skin, running diagonally from the mastoid process to the sternum. This muscle divides the cervical quadrilateral into two primary triangles (Fig. 75)—anterior and posterior cervical.

The anterior triangle is crossed obliquely by the posterior belly of the digastric above, and by the anterior belly of the omohyoid below, and is thus divided into three triangles, viz.:

FIG. 75.—THE PRIMARY CERVICAL TRIANGLES FORMED BY THE STERNOMASTOID MUSCLE.

the submaxillary and the superior and inferior carotid triangles (Fig. 76).

The posterior triangle is divided by the posterior belly of the omohyoid into an occipital and subclavian triangle. In addition to the regions covered by the triangles there is the median visceral region, extending in the medan line from the hyoid bone to the sternal notch.

The **submaxillary region** corresponds to a triangular area, the base of which is formed by the lower border of the jaw, the sides by the anterior and posterior bellies of the digastric muscle, the apex by the hyoid bone at a point corresponding to the intermediate tendon of the digastric muscle. This region is situated just below the floor of the mouth and separated from it by the mylohyoid muscle which, like a diaphragm, forms the floor of the mouth (Fig. 77).

Tumors developing above this muscle present under the buccal mucosa, those developing below present under the skin.

Ludwig's angina is an acute inflammation of the cellular tissue of the floor of the mouth and the submaxillary region. The infection probably originates in the buccal or pharyngeal cavities and spreads to the submaxillary lymphatic glands. It is marked by swelling, induration described as board-like, and intense pain in the submaxillary region. It rapidly invades the deeper structures and may prove fatal in a few days.

The patient's safety lies in rapid intervention—incision through the median line of the submaxillary region, penetrating the mylohyoid muscle to the base of the tongue (Tillaux).

FIG. 76.—TRIANGLES OF THE NECK.
A, Submaxillary triangle; *B*, superior carotid triangle; *C*, inferior carotid triangle; *D*, occipital triangle; *E*, supraclavicular triangle.

The **submaxillary gland** is one of the three principal salivary glands which pours its secretion into the buccal cavity. It occupies the greater part of the submaxillary triangle. It is quite superficial, being covered only by skin and platysma and enveloped completely by the cervical fascia, which divides at the border of the gland into two layers, and after enclosing the gland reunite, forming a complete capsule.

The two bellies of the digastric form a sort of hammock, in the angle of which rests the submaxillary gland. Deeply, the gland rests upon the mylohyoid and hyoglossus muscles; the facial artery grooves its posterior surface, the facial vein passes over it; beneath it are the lingual vein, the submental artery, and the hypoglossal nerve. It is separated from the lingual artery by the hyoglossus muscle. The relation of

the gland with its numerous vessels adds a certain amount of gravity to its extirpation, but it is easy, compared with that of the parotid, for it is not intimately associated, like the parotid, with an important artery and nerve which are necessarily incised in complete enucleation, nor has it the depth and narrowness of the parotid compartment which render operative procedures difficult.

Wharton's duct leaves the anterior extremity of the gland to penetrate the mylohyoid muscle and opens on a conspicuous papilla at the side of the frenum; a prolongation of the gland accompanies the canal.

FIG. 77.—THE SUBMAXILLARY REGION.

The **submaxillary lymph-glands** are not included in the submaxillary gland, as in the case of the parotid. They vary in number from three to six, and are situated below the border of the jaw, from the insertion of the anterior belly of the digastric to the angle of the jaw. They are placed at the junction of the bony and cutaneous surfaces of the submaxillary gland, upon which they rest, and receive the lymphatics of the nose, cheek, lips, gums, and the anterior third of the lateral border of the tongue (Poirier). When enlarged they may cover the gland and form a prominence so well circumscribed that it simulates the submaxillary gland itself. This is often

observed in tubercular adenitis when the submaxillary chain is involved. They receive the lymph from the nose, cheek, lips, gums, and anterior third of the lateral border of the tongue; hence, epitheliomas developing in these regions are accompanied by enlargement of the lymph-glands.

Submaxillary Abscess.—Primary suppuration of the submaxillary gland is very rare. It has been observed and the pus evacuated by way of Wharton's duct (Tillaux).

Abscess in the submaxillary region usually originates in the lymph-glands or follows fracture or disease of the lower jaw. Submaxillary cellulitis connected with the floor of the mouth (Ludwig's angina) has already been alluded to.

Submaxillary Calculi.—The submaxillary gland is more prone to develop calculi than the other salivary glands. When small they enter Wharton's duct and are either eliminated or present as a hard, submucous nodule. When of larger size they remain within the gland and form in the submaxillary region a hard kernel beneath the skin.

Retained calculi give rise to sudden circumscribed swelling and severe pain (salivary colic).

Tumors of the Submaxillary Gland.—In addition to the salivary cysts, due to obstruction of the duct, are found chrondroma, adenoma, and sarcoma.

Note the fact that the *vessels* in this region come from a common trunk—the arteries from the external carotid, the veins from the internal jugular. Note also that the facial artery and vein, as well as the lingual artery and vein, are parallel, but not contiguous. The facial artery and vein are separated by the submaxillary gland, the lingual artery and vein by the hyoglossus muscle. The facial vein joins the internal jugular so as to form the letter Y. This relation is of practical importance in the extensive dissections which attend the operation for cervical adenitis; after the facial vein is exposed it is followed to its termination in the internal jugular, which is identified and "cleaned."

The Lingual Triangle.—The disposition of the lingual artery and vein are of special interest to the surgeon. They are separated by the hyoglossus muscle, the vein coursing externally to the muscle accompanied by the hypoglossal nerve; the artery coursing internally to the muscle and running horizontally forward and parallel with the hypoglossal nerve.

The point of election for exposing the artery is within a

triangle formed by the hypoglossal nerve above the posterior belly of the digastric behind and the posterior border of the mylohyoid muscle in front (Fig. 78). The floor of the triangle is formed by the hyoglossus muscle, *beneath which courses the lingual artery.*

To expose the lingual artery at the point of election a curved incision is made in the submaxillary region from the symphysis menti, reaching down as far as the hyoid bone and back to the angle of the jaw. The skin and platysma having been

FIG. 78.—*A*, THE LINGUAL TRIANGLE.

divided, the capsule of the submaxillary gland is incised and the gland retracted upward.

The lingual triangle is now brought into view. The fibers of the hyoglossus muscle are separated about ¼ inch above the digastric tendon, and the lingual artery will be seen bulging through the opening.

The **lingual nerve** runs between the hyoglossus muscle and the deep part of the submaxillary gland. It sends branches to the submaxillary ganglion, which is situated above the deep

portion of the gland near the posterior border of the mylohyoid muscle.

The median portion of the submaxillary region contains one or two lymphatic ganglia which receive the lymphatic vessels from the middle of the lower lip and chin. In epithelioma of the lower lip they enlarge and are easily extirpated.

The fibers of the two mylohyoid muscles meet in the median line and form a fibrous raphe, which corresponds to the line between the subjacent genioglossus muscles.

The Sternomastoid or Carotid Region.—This region practically corresponds to the course of the sternomastoid muscle; it includes both the superior and inferior carotid triangles and is traversed by the great carotid trunks and their branches.

The **sternomastoid muscle**—the great landmark of the neck—is specially the landmark of the carotid region, since the great vessels of the neck lie beneath its anterior border throughout its entire extent, and it thus forms the surgeon's guide in many important operative procedures.

The muscle arises by two heads—from the sternum and clavicle. These two heads bound a triangular space filled with cellular and fatty tissue, behind which may be found the common carotid on the left and the bifurcation of the innominate artery on the right side.

The two heads of origin meet in the lower third of the neck and the muscle is inserted into the mastoid process and the superior curved line of the occiput. The muscle is enclosed in a sheath derived from the outer layer of the deep cervical fascia.

Action.—It draws the head toward the shoulder and turns the face to the opposite side.

The **nerve supply** is from the spinal accessory and branches of the cervical plexus.

Relations.—(*a*) Note the external jugular vein between the skin and the muscle, crossing the middle third of the muscle and running parallel with its posterior border as far as the clavicle.

(*b*) The superficial branches of the cervical plexus supplying the skin and subcutaneous structures emerge from beneath the posterior border of the sternomastoid muscle at the level of the upper border of the thyroid cartilage.

(*c*) The spinal accessory nerve enters the anterior border of the sternomastoid muscle 1 inch below the tip of the mastoid.

It traverses the upper and middle thirds of the muscle and emerges at the middle of its posterior border on a level with the upper border of the thyroid cartilage; it then crosses the occipital triangle to enter and supply the trapezius muscle. In its passage through the sternomastoid muscle it is joined by branches from the second cervical nerve.

(*d*) The relations of the deep surface of the sternomastoid to the important structures beneath are described in detail below.

Torticollis (wry-neck) refers to the special attitude which the head and neck assumes when the sternomastoid muscle of one side is rigidly contracted. It may be of the permanent or spasmodic type.

Permanent wry-neck is usually of congenital origin, resulting from a rupture of the muscle during parturition. The cicatrix undergoes subsequent contraction, and malposition of the head and neck result. This condition is relieved by open tenotomy of the sternal and clavicular heads of the muscle, care being exercised to avoid the external jugular vein which lies close to the posterior margin of the muscle.

Gerdes shows, in connection with wry-neck, that the scalenus anticus is as frequently at fault as the sternomastoid. This author advises resection of the scalenus anticus as well as that of the sternomastoid, which can be accomplished with safety if the phrenic nerve, the jugular vein, and brachial plexus be properly guarded while the muscle is isolated and severed immediately above the subclavian artery.

Spasmodic wry-neck is due to reflex irritation which throws the muscle into a state of clonic and, later, tonic contraction. It may be relieved by resection of the spinal accessory nerve which may be exposed—

(*a*) As it enters the sternomastoid muscle 1 inch below the tip of the mastoid. The transverse process of the atlas, which the nerve crosses on its way downward, can be felt and serves as a valuable guide in locating it.

(*b*) In the substance of the sternomastoid at the junction of the upper and middle thirds.

(*c*) As it emerges from under the posterior margin of the sternomastoid muscle opposite the upper border of the thyroid cartilage.

Beneath the anterior border of the sternomastoid muscle lies the carotid sheath formed by the deep layer of the cervical fascia, and containing the common carotid artery, the internal jugular vein, and the pneumogastric nerve, the vein being to

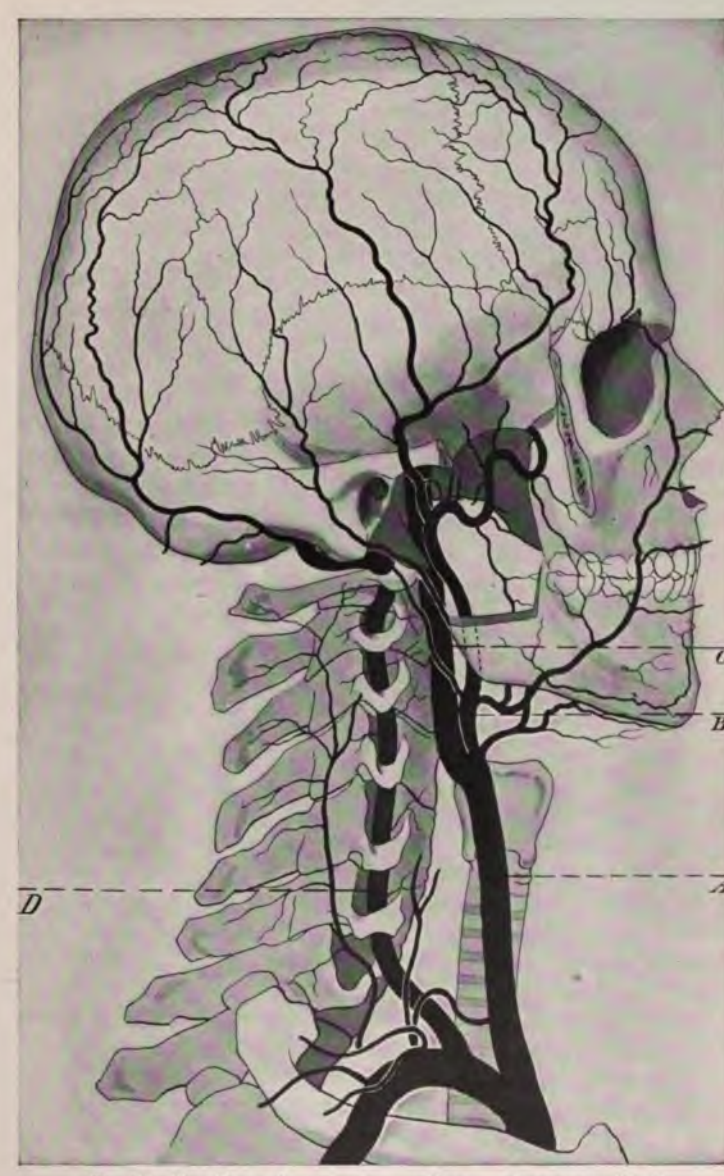

FIG. 79.—THE CHIEF ARTERIES OF THE NECK. (Deaver, modified.)
A, Common carotid; *B*, external carotid; *C*, internal carotid; *D*, vertebral.

the outer side of the artery and the nerve between and behind them.

The **common carotid artery** takes its origin from the innominate artery on the right; from the arch of the aorta on the left. In the neck the course of the artery is marked by a line drawn from the sternoclavicular articulation to a point midway between the angle of the jaw and the mastoid process. It extends from the sternoclavicular articulation to the upper border of the thyroid cartilage, where it bifurcates into the external and internal carotids (Fig. 79).

It gives off no branches in its course. Its satellite muscle is the sternomastoid, which, when the head is extended, covers it below, is in contact with it at its mid-point, and diverges from it above. These relations are important in all operations in this region.

The lower portion of the common carotid corresponds to the triangular interval between the two heads of the sternomastoid. The upper portion corresponds to the middle of the neck. Here the artery lies in a groove between the edge of the sternomastoid and the trachea. It is superficial at this point, being covered by the skin, the sternomastiod, and the cervical fascia.

FIG. 80.—RELATIONS OF THE CONTENTS OF THE CAROTID SHEATH.

The **relations of the common carotid in the neck** are of great surgical importance, since the region is frequently the site of operative interference.

The carotid sheath contains, besides the artery, the internal jugular vein and the pneumogastric nerve—the artery lying to the inner side, the internal jugular vein to the outer side, the pneumogastric nerve behind and between the two vessels (Fig. 80).

Note the fact that the *vein, when full of blood, is not only external to the artery, but is in front of it and nearly covers it completely* (Fig. 81).

The three structures are separated from each other by delicate fibrous partitions, nevertheless they are so intimately related that *a thorough denudation of the artery is necessary before passing a ligature.*

Behind, the common carotid is related to—

(*a*) The transverse processes of the lower cervical vertebræ.

(*b*) The prevertebral muscles.

(*c*) The cervical portion of the sympathetic nerve separated by the prevertebral fascia.

(*d*) The inferior thyroid artery.
(*e*) The recurrent laryngeal nerve.
Internally:
(*a*) The larynx and trachea.
(*b*) The thyroid gland.
(*c*) The esophagus.

FIG. 81.—THE CAROTID REGION AND THE CHIEF STRUCTURES.
Note the relation of the internal jugular vein, the common carotid artery and the pneumogastric nerve.

(*d*) The recurrent laryngeal nerve.
Externally:
(*a*) The internal jugular vein.
(*b*) The pneumogastric nerve.
In front:
(*a*) The skin, fascia, and platysma.

(*b*) The sternomastoid.

(*c*) The beginning of the sternohyoid and thyroid.

(*d*) The omohyoid, which crosses it opposite the cricoid cartilage.

(*e*) The descendens noni nerve, lying upon its sheath.

(*f*) The anterior jugular vein and the superior and middle thyroid veins.

Note the importance of two muscular relations:

(*a*) The omohyoid muscle, which crosses the carotid artery opposite the cricoid cartilage, divides it into two portions. Above the omohyoid the artery is superficial and is the point of election for applying a ligature. Below the omohyoid the artery is deeply placed and is related to the great venous trunks at the base of the neck, which may be wounded in exposing the vessel.

(*b*) The anterior border of the sternomastoid muscle is the guide to the artery; but the *relation of the artery to the muscle varies with the position of the head.* Only when the head is thrown back and turned to the opposite side is the artery covered by muscle throughout its entire extent.

The **carotid tubercle** (tubercle of Chassaignac) is a prominent tubercle on the transverse process of the sixth cervical vertebra, directly over which lies the common carotid artery. This tubercle is easily found by palpation about 2¼ inches above the clavicle, and forms a suitable *point for digital compression of the artery* as a provisional measure in case of hemorrhage, or as a preventive measure during the course of an operation.

The carotid tubercle also serves as a guide to the vertebral artery, below which it can be found just before entering the foramen in the transverse process of the sixth cervical vertebra.

Just below the carotid tubercle is the point where three arteries are superimposed and almost in contact—the common carotid, inferior thyroid, and vertebral from before back.

The **retrocarotid gland** is an inconstant gland situated behind the bulb of the common carotid and in the carotid bifurcation (Fig. 82). It is a small, reddish mass resembling in form and size a grain of wheat. Its inferior half is attached to the posterior surface of the common carotid, its superior half projects between the internal and external carotids. In structure it resembles a sympathetic ganglion (Testut). It is sometimes the site of a tumor which is benign in character and grows slowly. Its situation behind the carotid may cause

it to be mistaken, from its pulsation, for aneurysm. Note, however, that while pulsation is present, it is not expansile. Its intimate connection with the three carotids renders extirpation exceedingly difficult and delicate.

Just at the point where the common carotid bifurcates, it presents a slight dilatation, forming the *bulb of the common carotid.* This is the *most frequent site of aneurysm,* due to the resistance which the blood current meets at this point. Note the effect of pressure of an aneurysm upon the surrounding structures and the symptoms which follow—*dyspnea* from

FIG. 82.—THE RETROCAROTID GLAND.

pressure on the trachea; *dysphagia* from pressure on the esophagus; *hoarseness* from pressure on the recurrent laryngeal nerve; *venous congestion, headache,* and *edema* from pressure upon the internal jugular vein; and *dilatation of the pupil* from pressure on the sympathetic cord.

Aneurysm may be simulated by an enlarged lymphatic gland overlying the common carotid, a tumor of the retrocarotid gland, or a pulsating bronchocele: in the latter case an enlarged thyroid moves with the larynx during deglutition; an aneurysmal tumor does not. In the former case there is no bruit or expansile pulsation.

Ligation of the common carotid is performed for hemorrhage and aneurysm. It may be closed temporarily during

operations on the head and neck, according to the method of Crile. In conjunction with the subclavian it may be ligated for aneurysm of the innominate artery.

Anatomic Points to be Observed.—(*a*) The head should be placed in the anatomic position; *i. e.*, a sand-bag is placed beneath the shoulders, the head is thrown back, and the face turned to the opposite side. This position lengthens the operative field, pushes the artery toward the surface, and brings the anterior border of the sternomastoid parallel to the vessel throughout its course.

(*b*) *Surface Landmarks.*—*Muscular:* The anterior border of the sternomastoid muscle overlaps the carotid sheath. *Linear:* A line drawn from the sternoclavicular articulation to a point midway between the angle of the jaw and the mastoid process indicates the course of the artery. *Bony:* The cricoid cartilage nearly corresponds to the point where the omohyoid muscle crosses the artery. The carotid tubercle is slightly below the level of this point.

(*c*) The *point of election*, *i. e.*, the most superficial and favorable place to ligate the common carotid, is above the omohyoid muscle. Whether this point can be selected depends upon the condition for which the ligation is being performed; if contra-indicated, a point is selected below the omohyoid.

(*d*) *The Carotid Sheath.*—The descendens noni nerve usually descends in front of the sheath, occasionally within it. In opening the sheath the nerve should be preserved, since it supplies the infrahyoid muscles. The sheath should be opened upon the inner or arterial side to avoid wounding the vein.

(*e*) *Contents.*—Note not only the relation of these structures (vein, nerve, artery from without in), but that they are intimately connected, and a careful denudation is necessary before passing the ligature to avoid puncture of the vein or inclusion of the nerve. Also, that while the vein is external to the artery, when it is filled with blood it almost entirely covers it.

(*f*) *Mistakes* may arise from peculiarities as to the point of division. It may bifurcate as low as the cricoid cartilage, though this is rare. More commonly it divides at a higher level than usual. Gray asserts that very rarely the common carotid ascends in the neck without any subdivision, the internal carotid artery being wanting; and in a few cases the common carotid has been found to be absent, the external and internal carotids arising directly from the arch of the aorta.

Collateral circulation, after ligature of the common carotid, is

established by the free anastomosis of the branches of the two external carotid arteries; the internal carotids through the circle of Willis; between the superior thyroid from the external carotid and the inferior thyroid from the subclavian; the profunda cervicis from the superior intercostal (subclavian) and the princeps cervicis, a branch of the occipital artery.

Chief Danger.—While the free anastomosis which obtains in the circle of Willis should compensate for the loss of the common carotid by maintaining the cerebral circulation unimpaired, this does not invariably follow. Forty-one per cent. of the cases have been followed by cerebral softening.

The **internal and external carotid arteries** are the terminal branches of the common carotid, which bifurcates at a point opposite the upper border of the thyroid cartilage (see Fig. 79). At their origin they lie side by side, nearly parallel, the external carotid being internal and the internal carotid external. Higher up, the external carotid becomes superficial to the internal carotid, being separated by a portion of the parotid gland.

Characteristics which Differentiate the Internal and External Carotids.—It is often difficult to distinguish the internal and external carotids at the bottom of a wound. Even in a well-planned operation for ligation the one has been mistaken for the other. The following points should be noted:

(*a*) The internal carotid furnishes no branches in the neck.

(*b*) The external carotid gives off three anterior branches near each other.

(*c*) The external carotid is in immediate contact with the hypoglossal nerve.

(*d*) If compression of the vessel found causes pulsation in the temporal artery to cease it is the external carotid.

(*e*) The great cornu of the hyoid bone is in contact with the external carotid.

The **internal carotid artery** is the larger of the two terminal branches of the common carotid. It is distributed to the brain and to the eye and its appendages. It extends from its origin, at the level of the upper border of the thyroid cartilage, to the carotid canal of the temporal bone. It turns forward in the cavernous sinus and perforates the dura mater on the inner side of the anterior clinoid process, and divides near the inner end of the Sylvian fissure into the anterior and middle cerebral arteries.

Its relation to the tonsils and its course within the cranial cavity have already been described.

In the neck the internal carotid at first lies external to the external carotid. As it ascends it passes beneath the digastric and stylohyoid muscles, lies deeply beneath the parotid gland, and ascends by the side of the pharynx and tonsil.

It is accompanied, in the neck, by the internal jugular vein and pneumogastric nerve, which continue the same relations as in the case of the common carotid. It is but seldom ligatured, and, when necessary, the same muscular guides may be used as for the external carotid. The *point of election* is that just above the bifurcation.

The **external carotid artery** is the smaller of the two terminal branches, and is placed internal and superficial to the internal carotid. It supplies the face and the soft parts covering the vault of the cranium.

From its origin opposite the upper border of the thyroid cartilage it bends slightly forward to the angle of the jaw, thence ascends vertically in the substance of the parotid gland, and ends opposite the neck of the lower jaw by dividing into its terminal branches—the internal maxillary and superficial temporal (see Fig. 79).

Branches below the Digastric Muscle.—(*a*) *Ascending pharyngeal*—from the back part of the external carotid near its commencement.

(*b*) *Superior thyroid*—first internal branch given off at a point just below the great cornu of the hyoid bone. It is closely associated with the superior laryngeal nerve.

(*c*) *Lingual*—second internal branch given off opposite the hyoid bone, ¾ inch above the bifurcation of the common carotid (see lingual triangle).

(*d*) *Facial*—third internal branch given off at point where the hypoglossal nerve crosses the external carotid, and about an inch above the bifurcation of the common carotid.

(*e*) *Occipital*—first external branch given off just above the point where the hypoglossal nerve crosses the external carotid artery.

Above the Digastric Muscle.—*Posterior auricular* and the two terminals have already been described.

Ligation of the external carotid is performed for hemorrhage, especially of the middle meningeal, when other procedures have failed; for aneurysm of the scalp; as a preliminary procedure in operations about the face, jaws, and mouth; and

as a step in excision of the external carotid artery to retard the progress of certain malignant growths (Dawbarn).

Anatomic Points to be Observed.—(*a*) The *surface landmarks*, both linear and muscular, are the same as those of the common carotid. The greater cornu of the hyoid bone lies to the inner side of the vessel.

(*b*) The *point of election* is below the digastric muscle, where the vessel is most superficial and the ligature is passed between the origins of the superior thyroid and lingual arteries.

(*c*) The *line of incision* starts at the angle of the jaw and reaches the anterior border of the sternomastoid, opposite the superior border of the thyroid cartilage.

Mistakes.—The internal carotid is frequently taken for the external. This mistake will be avoided if the characteristics given above, which differentiate the two vessels, are carefully noted.

The external carotid may arise at a higher or lower level than usual, or it may be absent, and its branches arise from the common carotid artery, which continues upward, without bifurcation, as the internal carotid artery (Dawbarn).

As noted in the anomalies of the common carotid, the external carotid may arise directly from the arch of the aorta.

The **internal jugular vein** takes its origin at the base of the cranium, where it receives all the blood from the cranial cavity. Its course and relation to the internal and common carotid arteries has already been noted. At the root of the neck it unites with the subclavian vein to form the innominate vein (see Fig. 81).

Surgically, it is a vein of great importance. Its large size and thin walls render it liable to injury. When wounded, the result may prove fatal, either from hemorrhage or air embolism (the air being sucked in during inspiration).

Septic thrombophlebitis of the internal jugular may follow disintegration of an infective thrombus within the lateral sinus. In these cases the vein should be exposed and ligated before attempting to remove the infected clot within the lateral sinus, in order to avoid a dissemination of the infective material throughout the general circulation.

Deep abscess of the neck has been followed by ulceration of the internal jugular and death. Owing to the number of anastomoses, the internal jugular can be ligated and excised without any obstacle to the return circulation.

Crile reports a case in which both the internal and external

jugulars of one side were excised their whole length, from the bottom to the top of the neck, and several months later a similar excision of both veins was made on the opposite side, without the slightest circulatory disturbance, congestion, or hint of insufficient return circulation.

Farabeuf's triangle (Fig. 83) is situated in the upper part of the neck. Its sides are formed by the internal jugular vein and the facial vein, its base by the hypoglossal nerve. Bisecting this triangle from base to apex is the external carotid artery. This triangle is a helpful landmark in extensive dissections of the neck, especially in locating the internal jugular vein, the safety of which is best conserved by promptly exposing it.

FIG. 83.—FARABEUF'S TRIANGLE.

The **cervical sympathetic group** consists of three ganglia with connecting branches forming a chain, lying deeply behind the carotid sheath and upon the prevertebral fascia. It extends from beneath the mastoid process to the first rib. These ganglia have been known as superior, middle, and inferior. We might well name them, respectively, carotid, thyroid, and vertebral, from their almost constant association with these arteries (Fig. 84).

The *superior* or *carotid ganglion* lies opposite the second and third vertebræ and extends up beneath the mastoid process. It is the largest of the three. It is constant, fusiform in shape, and sends a branch downward to connect with the middle or thyroid ganglion.

The *middle* or *thyroid ganglion* is the smallest of the three. It is very inconstant, being found by the author in only four of twenty subjects. It is in fairly constant relation with the inferior thyroid artery about opposite the sixth cervical vertebra. When no distinct ganglion is present a number of branches from the descending branch of the superior ganglion spread out and interlace about the inferior thyroid artery.

The *inferior* or *vertebral ganglion* is next in size to the superior. It is constant and usually situated beneath the vertebral artery just as it is given off from the subclavian. In one case the

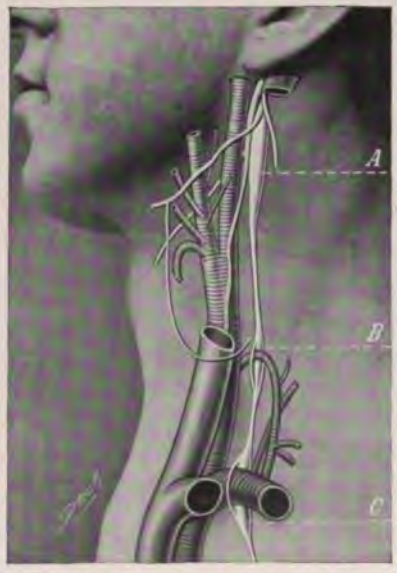

FIG. 84.—THE CERVICAL SYMPATHETIC GANGLIA.
A, Superior ganglion; *B*, middle ganglion; *C*, inferior ganglion.

author found it 1 inch above its usual location and not connected with an artery. These practical facts should be noted:

(*a*) The constancy, large size, and accessibility of the superior ganglion.

(*b*) The inconstancy and small size of the middle ganglion, and its intimate connection with the inferior thyroid artery.

(*c*) The constancy of the inferior ganglion, its relation with the vertebral artery; and its inaccessibility.

Surgical Considerations.—Resection of the cervical ganglia produces increased supply of blood to the head, paralysis of the

pupil dilators, decrease of intra-ocular tension, retraction of the globe, retarded pulse, and increased secretion from the sweat and salivary glands.

From these physiologic facts has come the proposition that resection of the ganglia might prove beneficial and even curative in such conditions as glaucoma, epilepsy, and exophthalmic goiter. Further than this, the ganglia have been resected for vertigo of cerebral anemia, facial neuralgia, and spasmodic torticollis, with successful results reported in each of these conditions. Jonnesco has demonstrated that there are two conditions, at least, in which removal of the cervical ganglia are followed by satisfactory results, viz.: glaucoma and primary exophthalmic goiter. The operation, to be efficacious, should be a complete bilateral excision of the three cervical ganglia.

Exposure of the Cervical Ganglia.—The best exposure of the ganglia is obtained by making an incision along the middle line of the sternomastoid muscle, parallel with its fibers, from the mastoid process to the clavicle, including skin and platysma. At this point it will be necessary to ligate the external jugular vein. The fibers of the sternomastoid are now split with the handle of the scalpel, care being taken not to injure the spinal accessory nerve, which is found penetrating the muscle in its upper third. Obliquely crossing the lower part of the wound is seen the omohyoid muscle, which can be retracted or divided to secure easy access to the lower ganglion. The split sternomastoid is drawn apart. In the inner retraction is included the carotid sheath and its contents. The outer retraction pulls to one side the outer fibers of the sternomastoid. Upon retracting these structures there is found the floor of the wound formed by the prevertebral fascia, upon which rests the chain of cervical ganglia.

The **outer region of the neck** corresponds to the area bounded by the posterior margin of the sternomastoid in front, the anterior margin of the trapezius behind, and the clavicle below. The posterior belly of the omohyoid divides this space into two triangles—the upper or occipital, and the lower or supraclavicular (Fig. 85).

The **occipital triangle** contains few structures of practical importance. The external jugular vein, superficially, and the posterior jugular behind and at a deeper level pass vertically downward. The spinal accessory nerve traverses the middle of this triangle, passing obliquely downward from beneath the

sternomastoid to enter the trapezius. Winding around the posterior border of the sternomastoid, near its center, are the superficial branches of the cervical plexus, viz.: the great auricular, the small occipital, and the transverse cervical nerves; passing obliquely downward are the supraclavicular and supra-acromial branches.

FIG. 85.—THE OUTER REGION OF THE NECK SHOWING THE OCCIPITAL AND SUPRACLAVICULAR TRIANGLE.
The omohyoid is indicated semitransparently.

The lower part of the triangle is traversed by the transversalis colli artery and vein. A chain of lymphatic glands extends deeply along the posterior border of the sternomastoid.

The **supraclavicular triangle** (subclavian) is bounded below by the clavicle, in front by the sternomastoid, and above by the posterior belly of the omohyoid muscle. Superficially, it corresponds to the supraclavicular fossa, a depression lying immediately above the clavicle and well marked in thin people. This depression diminishes or disappears in certain fractures of

the clavicle. This region contains structures of great surgical interest—the subclavian artery and vein, the great nerve-trunks which supply the upper extremity, and the phrenic and pneumogastric nerves. It will, therefore, be seen that it is one of the most important triangles of the neck. The position of the shoulder has a marked effect in increasing or diminishing the depth of this space. In all operations in this triangle the shoulder should be depressed and the head rotated to the

FIG. 86.—SUBCLAVIAN TRIANGLE SHOWING RELATION OF THE STRUCTURES.
The subclavian vein shown in dotted line.

opposite side, so that the contents of the triangle may be brought nearer to the surface.

This region is covered by the skin, superficial fascia, and platysma. It is crossed by the supraclavicular nerves. The deep fascia covers all the principal structures of this region; it splits into two layers to ensheath the omohyoid muscle, reunites at its lower border and descends, to become attached to the posterior border of the clavicle.

The scalenus anticus muscle, at a deeper level, corresponds to the posterior border of the sternomastoid and thus forms within the supraclavicular triangle, a second triangle bounded by the clavicle, the posterior belly of the omohyoid, and the scalenus anticus muscle (Fig. 86).

The *principal landmark* of this region is the *scalenus anticus muscle.* It arises from the transverse processes of the third, fourth, fifth, and sixth cervical vertebræ, descends vertically, and is attached below to a tubercle (the *tubercle of Lisfranc*) on the upper surface of the first rib. The following points should be noted:

(*a*) The scalenus anticus separates the subclavian artery from the subclavian vein, the artery being behind, the vein in front (Fig. 87).

(*b*) The phrenic nerve descends vertically in front of the scalenus anticus to its lower extremity and passes behind the subclavian vein.

(*c*) The cords of the brachial plexus make their exit from behind the scalenus anticus.

(*d*) The tubercle of Lisfranc is an excellent guide in ligating the subclavian artery. It marks the commencement of the third portion of the artery and is the point where the artery can be effectually compressed against the first rib.

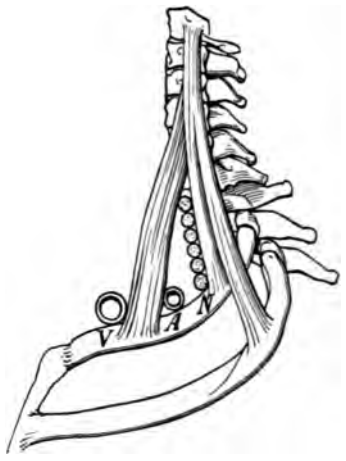

FIG. 87.—THE SCALENUS ANTICUS MUSCLE.
Note its relation to the subclavian arteries and veins.

Structures of Surgical Importance.—The *suprascapular artery*, a branch of the thyroid axis: its direction is outward, parallel to the clavicle. It traverses the entire base of the supraclavicular triangle and terminates in the supraspinous fossa. It crosses the scalenus anticus muscle, the phrenic nerve, and the subclavian artery. This artery should be avoided in making the skin incision for performing ligation of the subclavian artery, and in resection of the clavicle. An incision ¾ inch above the clavicle will clear the artery.

External jugular vein, as already described, descends vertically from the parotid region, crossing the sternomastoid and penetrating the deep fascia about ½ inch above the clavicle and

just behind the sternomastoid; it empties into the subclavian vein.

Note the fact that the coat of the external jugular vein is adherent to the deep fascia which it pierces, and, consequently, wounds of the vein at this point are exposed to the danger of air embolism.

Note also the *venous plexus* at the termination of the external jugular, where it receives the suprascapular and transverse cervical veins. This plexus is sometimes troublesome in operations about this region.

FIG. 88.—*A*, THE THORACIC DUCT.
Note the point at which it empties into the left subclavian vein.

The **subclavian vein** at the inner end of the triangle lies between the clavicular portion of the sternomastoid and the scalenus anticus. In front is the clavicle and the subclavius muscle, behind the scalenus anticus and phrenic nerves, which separate it from the subclavian artery. The space between the clavicle and first rib form the gateway through which the subclavian vessels and nerves pass into the axilla. Hence, the vessels ascending from the thorax form an arch over the

first rib on their way to the axilla (Bardeleben). The walls of the vein are adherent to the clavicle and the first rib; when the vein is wounded it cannot collapse and there is danger of air embolism. Should the vein be punctured during operations, it should be sutured during continuous irrigation, or both ends ligated. Just at the angle of junction with the internal jugular the left subclavian vein receives the thoracic duct (Fig. 88), while the right subclavian vein receives the right lymphatic duct (Gray).

Wounds of the thoracic duct, though rare, may occur during the extirpation of tuberculous or cancerous glands in this region. They are evidenced by a sudden gush of limpid whitish fluid, which may be effectually treated by a gauze tampon. Remember that the thoracic duct is so thin and transparent that it easily escapes detection.

The **subclavian artery,** like the carotid, arises on the right side from the innominate, just behind the sternoclavicular joint, and on the left side from the arch of the aorta. The left subclavian is deeper, longer, and more curved than the right. The subclavian artery in the neck describes a curve which commences at the level of the sternoclavicular articulation and ends at the center of the clavicle, the highest point of the arch being about ¾ inch above the latter bone. The artery passes behind the scalenus anticus muscle and descends to the lower border of the first rib, where it passes into the arm with the vein and nerves and becomes the axillary. The scalenus anticus muscle divides the artery into three portions: The first portion is situated between its point of origin and the inner border of the scalenus anticus; the second portion lies behind the scalenus anticus; and the third portion extends from the outer border of the scalenus anticus to the lower border of the first rib.

Important Relations to be Noted.—(*a*) The height to which the artery rises in the neck varies according to the individual conformation. In long, thin necks the artery reaches a higher level than in short, thick necks, where the artery is deeply placed and does not rise above the upper border of the clavicle.

(*b*) The relation between the clavicle and the artery varies according to the position of the shoulder—when elevated the depth of the artery is considerably increased. When the shoulder is depressed and the head extended and turned to the opposite side, the artery is thrown into its most superficial position.

(*c*) The first and second portions of the subclavian artery groove the dome of the pleura, which rises in the neck at this point about 1 inch above the upper border of the sternal extremity of the clavicle. Hence, the danger of puncturing the pleura when applying a ligature in this region, or in removing deep-seated tumors at the root of the neck.

(*d*) The pneumogastric nerve on the right rests directly on the anterior surface of the first portion of the subclavian and may be included in a ligature at this point. Note also that it

FIG. 89.—THE RELATION OF THE SUBCLAVIAN VESSELS AS THEY PASS BENEATH THE CLAVICLE.

gives off the right recurrent laryngeal, which winds around the artery, forming a loop as it ascends to the larynx. The left pneumogastric, instead of crossing the vessel at right angles, runs parallel to it, giving off the left recurrent laryngeal loop as it crosses the arch of the aorta.

(*e*) The brachial plexus lies above and to the outer side of the artery. Its lowest trunk runs nearly parallel with the artery and may be a source of error in performing ligation.

(*f*) Compression of the subclavian artery is applied at the point where the artery crosses the first rib. To be effectual, the shoulder should be depressed and the thumb inserted at the junction of the posterior border of the sternomastoid with the clavicle, the pressure being directed downward, backward, and inward.

(*g*) As the subclavian vessels pass beneath the clavicle the vein is internal, the artery in the middle, and the nerves to the outer side, forming the common relation, from within out, of vein, artery, nerve (Fig. 89).

(*h*) All the branches of the subclavian arise on the left side from the first portion; the right side differs in that the superior intercostal generally arises from the second portion.

The branches of the subclavian are seven:

Two superior—the inferior thyroid and vertebral.

Two inferior—the internal mammary and superior intercostal.

Three external—the suprascapular, transversalis colli, and deep cervical, which generally arise from the superior intercostal; occasionally directly from the subclavian.

Ligation of the subclavian artery is usually performed for aneurysm of the axillary, or on the right side, in conjunction with ligation of the common carotid, for aneurysm of the innominate. When the relations of the subclavian artery are considered it will be observed that ligation of its first and second portions is not only a difficult, but perilous, procedure, and surgical judgment concedes that ligation of the subclavian should be confined to its third portion.

Remember the following points:

(*a*) The *point of election* for ligating the subclavian is its third portion, that is, on the outer side of the scalenus anticus, where the artery may be tied with little difficulty.

(*b*) *Position.*—The shoulder should be well depressed (sandbag between the shoulders), with the head extended and turned to the opposite side.

(*c*) *Anatomic Guide.*—Superficially, the posterior border of the sternomastoid; deeply, the scalenus anticus. The tubercle of Lisfranc can be felt on the inner border of the first rib and marks the beginning of the third portion of the artery. The relation of the structures from within out is vein, artery, nerve.

(*d*) *Incision* is made 1 cm. above and parallel to the clavicle.

(*e*) *Mistakes.*—The right subclavian may arise from the aorta and reach the scalenus by passing behind the esophagus

or between it and the trachea. The artery may pass in front of the scalenus and the vein behind the muscle. The cord of the brachial plexus may be mistaken for the artery. The structures may be differentiated by palpation—the artery is a compressible tube, the nerve is solid and cord-like; compression of the artery causes pulsation to cease below.

The **collateral circulation** after ligature of the third part of the subclavian artery is established between the suprascapular and the dorsalis scapulæ (branch of the subscapular); between the internal mammary, the aortic intercostals, the superior intercostal, and the long and short thoracic branches

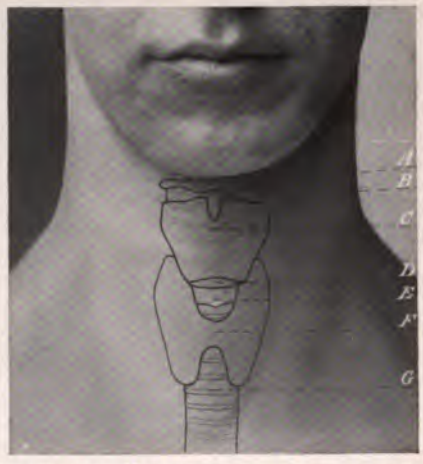

FIG. 90.—SURFACE MARKINGS OF THE INFRAHYOID REGION.
A, Hyoid bone; *B*, thyrohyoid membrane; *C*, thyroid cartilage; *D*, cricothyroid membrane; *E*, cricoid cartilage; *F*, thyroid isthmus; *G*, trachea.

of the axillary; between the supra-acromial branch of the suprascapular and the acromiothoracic; between the posterior scapular and the subscapular and dorsalis scapulæ (Holden).

The **infrahyoid region** extends from the hyoid bone above to the suprasternal notch below. Laterally, it is limited by the anterior border of the sternomastoid muscles. Our interest in this region centers above the structures in the central line of the neck, many of which are sufficiently superficial to be palpated. The surface anatomy should be constantly rehearsed by recognizing the various parts of the laryngotracheal tube, which can be palpated throughout its course in the neck (Fig. 90). Beginning above, the hyoid bone is recognized by the greater cornua, which form a bony prominence on either

side. Next is felt the transverse groove below the hyoid bone, representing the position of the thyrohyoid membrane, which is attached above to the posterior border of the hyoid bone and below to the thyroid cartilage.

Further down is the pomum Adami (Adam's apple), specially developed in males, which represents the projection of the thyroid cartilage, and below this the cricoid cartilage, connected by the cricothyroid membrane, and, finally, below the cricoid cartilage is the trachea.

The coverings in the median line of the laryngotracheal tube differ from that on the sides in the absence of the platysma, the existence of a median fibrous union between the superficial and deep fascias, and the presence of a median cellular interval between the sternohyoid and sternothyroid muscles. It will be observed, therefore, that the laryngotracheal tube in the median line has only two coverings—skin and aponeurosis.

The **hyoid bone** has no immediate relation with the skeleton. It lies in the soft parts of the neck and possesses great mobility.

Fractures, although rare, may occur from hanging, throttling, and muscular action. The most frequent site is at the junction of the greater cornua with the body. The symptoms are pain in speaking, swallowing, or opening the mouth. Sometimes the fragment becomes necrotic and is eliminated by the mouth.

The **thyrohyoid membrane** acts as a ligament, suspending the larynx from the hyoid bone. It extends from the superior border of the thyroid cartilage to the posterior border of the body and the greater cornua of the hyoid bone; it forms an interval of from 1 to 1½ inches between the two bones.

The **thyrohyoid bursa** (bursa of Boyer) (Fig. 91) is a serous cavity between the thyrohyoid membrane behind, and the thyrohyoid muscle in front, which facilitates the constant movement of the larynx in deglutition. Cysts in the median line may be due to a bursitis of this cavity, and when opened are apt to be followed by fistula unless thorough extirpation is performed. Laterally, the thyrohyoid membrane is pierced by the superior laryngeal nerve and artery and covered by the sternohyoid and thyrohyoid muscles.

The **thyro-epiglottic space** is a pyramidal shaped space situated behind the thyrohyoid membrane and in front of the epiglottis (see Fig. 91). It is filled with cellular and glandular tissue, which may be the site of abscess complicated by symptoms of asphyxia. They should be opened promptly by puncturing the thyrohyoid membrane.

Suicidal wounds of the throat most frequently involve the thyrohyoid membrane. The wounds in this region may be quite extensive without involving any important vessels.

Should the wound penetrate deeply, it would divide the epiglottis and open the pharynx.

While these wounds are not immediately serious, they may be followed by grave results—

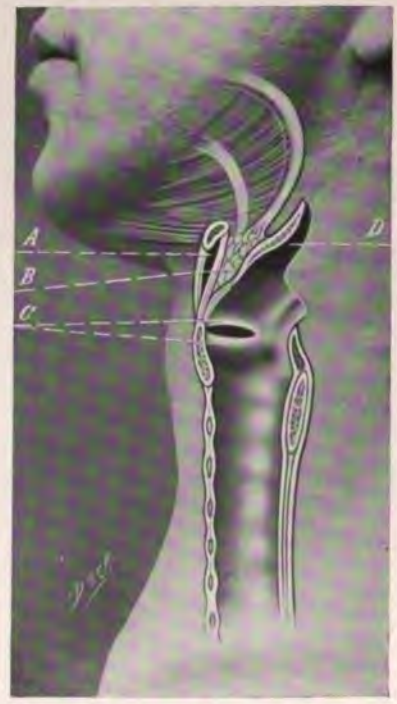

FIG. 91.—SAGITTAL SECTION OF THE LARYNX.
A, Thyrohyoid bursa; *B*, thyro-epiglottic space; *C*, vocal cords; *D*, epiglottis.

(*a*) From paralysis of the superior laryngeal nerve sensation of the laryngeal mucosa is destroyed, and septic pneumonia may follow from the introduction of foreign material into the air-passages.

(*b*) The detached epiglottis may fall into the glottis and cause asphyxiation. These wounds being above the vocal cords there is no alteration of the voice.

The **larynx** (see Fig. 91) is the upper and specialized

portion of the windpipe which forms the organ of the voice; above, it is attached to the hyoid bone; below, it is continuous with the trachea. Before the age of puberty there is little difference between the larynx of the male and female. At this time, however, the larynx of the male increases considerably in size, forming the prominence in the middle line of the neck known as "Adam's apple" and producing the "change of voice." The larynx is lined with a highly sensitive mucous membrane continuous above with that of the pharynx and below with that of the trachea. The larynx is composed of nine cartilages, the largest of which are the thyroid and cricoid.

The **thyroid cartilage** is the largest cartilage of the larynx and acts as a protection to the mechanism within. It occupies the superior and anterior portion of this organ, and is composed of two quadrilateral plates which unite to form a prominent angle in front (Adam's apple). It is easily palpated, especially in men, and forms the *principal landmark in all operations on the larynx.*

In the median line the cartilage is covered only by skin and fascia; on the sides it is covered by muscles.

The lower border of the thyroid rests on the circumference of the cricoid, to which it is attached by the cricothyroid membrane. The superior border presents a notch in the median line and affords attachment to the thyrohyoid membrane. The two posterior borders give attachment to the pharynx and terminate above and below in the form of two vertical projections, the upper and lower cornua; the latter articulate with the sides of the cricoid cartilage.

Fracture of the thyroid cartilage occurs more frequently than in other cartilages of the larynx, because of its form and exposed situation. It is caused by lateral compression, or compression backward against the vertebral column, as in strangling, hanging, or direct blows. The symptoms are loss of voice, painful deglutition, bloody expectoration, and dyspnea. Tracheotomy may be necessary. Death may occur suddenly from edema of the glottis.

The **cricothyroid membrane** covers in the space which separates the cricoid and thyroid cartilages. It is a lozenge-shaped space widest in the median line and tapering toward the sides (see Fig. 90). This fibrous membrane firmly connects the two cartilages in front, but on the sides it ascends free on the inner side of the thyroid and becomes continuous above with the lower border of the true vocal cord (Owen). On its

surface are found the two cricothyroid arteries, anastomosing, and sometimes one or two lymphatic ganglia.

Through this membrane the easiest and most rapid "tracheotomy" may be done for the immediate relief of dyspnea. If the case is desperate the operation may be performed with a pocket knife. Note that the *membrane should be divided, transversely,* close to the upper border of the cricoid cartilage to avoid the cricothyroid arteries.

In the adult this space is sufficiently large (½ inch) to allow the introduction of a tracheotomy tube. Should more room be needed the cricoid cartilage may be divided in the median line.

This operation is not applicable to children, because of the narrowness of the cricothyroid space.

It should not be performed in those cases where the tracheotomy tube is to be worn for a long period, because of its proximity to the vocal cords.

It is an operation of extreme simplicity and practical value in an emergency, and one with which every practitioner should be familiar.

The **cricoid cartilage** may be considered the first ring of the trachea so modified as to form a support for the larynx. In front it is narrow (½ inch), attached above to the cricothyroid membrane and below, by a fibrous membrane, to the first tracheal ring.

Behind it is expanded into a quadrate portion 1 inch in depth, situated between the alæ of the thyroid. This portion gives attachment in the middle line to the longitudinal fibers of the esophagus, and on each side to the crico-arytenoideus posticus muscle. The arytenoid cartilages articulate with the two oval convex surfaces on its upper border.

The cricoid cartilage is a landmark of considerable value.

Note the following facts:

(*a*) It marks the beginning of the trachea.

(*b*) It is on a level with the commencement of the esophagus.

(*c*) It is opposite the carotid tubercle.

(*d*) It is opposite the point where the omohyoid muscle crosses the carotid.

The **arytenoid cartilages** consist of two small, triangular pyramids about ½ inch in height. They articulate by their base with the upper border of the posterior portion of the cricoid. At the base are two processes—the anterior or vocal process gives attachment to the true vocal cords; the external

or muscular process gives attachment to the muscles which move the cartilage. Its apex is surmounted by a cartilaginous nodule, the cartilage of Santorini.

The **epiglottis** is a fibrocartilaginous valve, shaped like a leaf (see Fig. 91). During respiration its position is horizontal, but in the act of deglutition it falls downward and backward over the entrance of the larynx, protecting it from the entrance of food. It is attached to the back of the thyroid, just above the vocal cords, also to the hyoid bone and is connected with the base of the tongue by the glosso-epiglottidean folds.

The *interior of the larynx* is divided into three regions by the vocal cords—two conspicuous folds which run from before backward and encroach upon the lumen of the passage.

The triangular space between the vocal cords and the bases of the arytenoid cartilages is the glottis, which forms the middle and most important region within the larynx.

The **glottis,** as noted above, comprises the space between the true vocal cords and the bases of the arytenoid cartilages; it is the narrowest part of the interior of the larynx. The space is triangular, the apex being forward and corresponding to the attachment of the vocal cords on each side of the thyroid angle. The length of the glottis in the adult is about 1 inch, its width ¼ inch. In children these dimensions are much less. The level of the glottis is located externally at a point corresponding to the middle of the thyroid ridge. During ordinary respiration the glottis is open, but in speaking or singing the space is narrowed and the edges become parallel.

The **false vocal cords** are two folds of mucous membrane lying above the true cords, which play no part in the role of phonation.

The **true vocal cords** are two elastic bands fixed, in front, near the angle of junction of the thyroid and, behind, to the vocal processes at the base of the arytenoid cartilages (see Fig. 91). These cords are approximated or separated by the action of the muscles attached to the arytenoid cartilages. They are of a brilliant, pearly white color and covered with mucous membrane, which is intimately adherent to the subjacent tissue.

Edema of the glottis is an expression which does not convey a correct idea of the true pathologic lesion, since the vocal cords are never the site of an acute edema. This term refers to an edema of the aryteno-epiglottic folds, where the mucous membrane is loose and there is an abundance of submucous

tissue. This condition is produced by an inflammation of the mucous membrane of the larynx induced by irritation from heat, caustics, injury, or inflammation spreading from adjacent regions. It is marked by hoarseness, dyspnea, and asphyxia. An immediate tracheotomy may be necessary to prevent suffocation.

The Laryngeal Vessels.—The larynx is supplied by the superior laryngeal and the cricothyroid from the superior thyroid artery, and the inferior laryngeal from the inferior thyroid artery.

The **laryngeal lymphatics** are divided into two systems: those above the glottis drained by the glands about the bifurcation of the common carotid; those below the glottis terminating in glands situated on each side of the trachea.

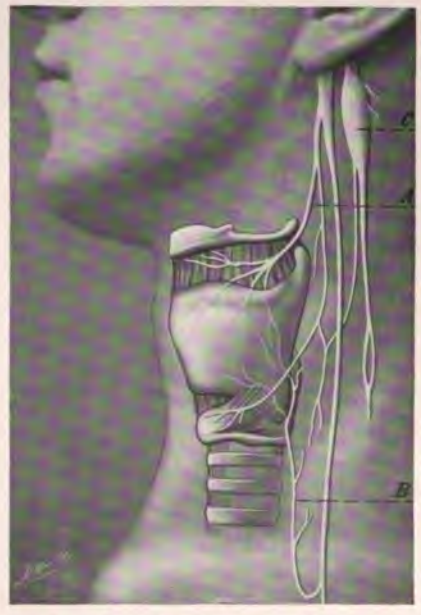

FIG. 92.—THE LARYNGEAL NERVES.
A, Superior laryngeal nerve; *B*, recurrent laryngeal nerve; *C*, superior cervical sympathetic ganglion.

The Laryngeal Nerves (Fig. 92).—The *superior laryngeal nerve*, a branch of the pneumogastric, is the sensory nerve of the larynx. It supplies the mucous membrane of the larynx and imparts to it a high degree of sensibility. Its division would

result in loss of laryngeal sensibility, which might permit foreign matter to enter the air-passages and result in a septic pneumonia.

The *inferior* or *recurrent laryngeal* is the motor nerve of the larynx, and supplies all the intrinsic muscles except the cricothyroid. Compression on this nerve by tumor or aneurysm causes hoarseness and sometimes complete loss of voice.

Direct access to the larynx may be obtained by means of—

Thyrotomy, which consists in splitting the thyroid cartilage exactly in the median line in order to avoid the anterior insertions of the vocal cords and retracting the two halves outward. This opening gives an excellent exposure of the interior of the larynx through which foreign bodies may be extracted or new growths removed.

Laryngotomy has already been alluded to as the simplest and quickest method of relieving dyspnea when prompt intervention is demanded (pages 23 and 180). It consists in opening the larynx through the cricothyroid membrane, by a transverse incision made close to the upper border of the cricoid cartilage. It is applicable only to adults. In children tracheotomy should be chosen.

Excision of the larynx (laryngectomy) is performed for malignant disease. Though seemingly a difficult procedure it loses much of its difficulty when certain technical and anatomic details are observed. These include preliminary tracheotomy, an incision that completely exposes the parts to be removed, careful hemostasis, and prevention of blood flowing down into the lungs.

The best exposure is made by a median incision from the hyoid bone to below the level of the cricoid cartilage, with the addition of transverse incisions at each end of the vertical incision (Périer's method).

Remember that no operation for malignant disease is complete without the removal of associated lymphatic glands.

The **trachea** is a fibrous tube reinforced by fifteen to twenty cartilaginous rings, and extends from the cricoid cartilage to the origin of the bronchi opposite the body of the fourth dorsal vertebra. It is about 4½ inches long and ¾ inch wide. Note the fact that the cartilaginous rings do not completely encircle the trachea, but are deficient behind, the interval being filled by a transverse layer of nonstriated muscular fibers. Thus, the tracheal tube is flattened behind to avoid pressure upon the esophagus, with which it is in immediate contact.

The trachea is remarkably elastic, which permits it to conform to all the movements of the neck.

Relations of the Trachea.—Practically, we are concerned with the upper 2¼ inches of trachea which belongs to the neck, since the surgical limit of the trachea is at the sternal notch. This portion of the trachea is divided into two parts by the isthmus of the thyroid, which lies in front of the second, third, and fourth tracheal rings. The portion above the isthmus is superficial and easily accessible; the portion below the isthmus

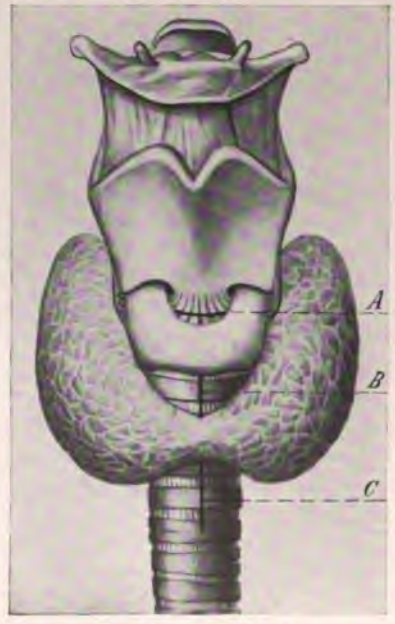

FIG. 93.—THE TRACHEA.
Showing the isthmus of the thyroid gland and line of demarcation between high and low tracheotomy: *A*, Laryngotomy; *B*, high tracheotomy; *C*, low tracheotomy.

is deep, surrounded by important structures, and difficult of access (Fig. 93).

In cutting down upon the trachea above the isthmus we encounter skin, superficial fascia, deep fascia, the sternohyoid, and sternothyroid muscles on either side the median line, and a second layer of deep fascia which is attached to the lower border of the hyoid bone above, and gives off an expansion to enclose the isthmus.

Below the isthmus the same layers of tissue exist, save that

in front of the trachea is a large quantity of loose cellular tissue containing—

(*a*) One or two lymphatic glands which drain the larynx.

(*b*) A venous plexus formed by the inferior thyroid veins and connected by several cross-branches.

(*c*) The thyroidea ima artery, an occasional branch of the innominate, which, when present, passes from below upward in front of the trachea.

Remember that the left innominate vein and the innominate artery cross the trachea at the root of the neck, and may extend above the sternum when the neck is extended and the vessels congested.

In children the thymus gland overlies the trachea at a variable distance above the sternal notch.

Posteriorly, the trachea is in constant relation with the esophagus, and in the lateral grooves between these two tubes lie the recurrent laryngeal nerves.

Laterally, are the common carotid arteries, in close relation to the trachea at the root of the neck, even sometimes overlapping it. As they ascend they diverge to the outer side. The lobes of the thyroid gland and the inferior thyroid arteries are also on the sides.

Tracheotomy.—The surgical anatomy of the trachea is concerned chiefly in the operation of tracheotomy. From the relations above described it is evident that the trachea may be opened at two points: either above the isthmus of the thyroid—*high tracheotomy*, or below the isthmus—*low tracheotomy* (see Fig. 93), and that the former is to be preferred because of its simplicity.

Anatomic Points to be Remembered.—(*a*) The isthmus of the thyroid covers the second, third, and fourth tracheal rings.

(*b*) Tracheotomy is high or low, as it is performed above or below the isthmus of the thyroid.

(*c*) The difficulties of tracheotomy increase, the nearer the incision is made to the sternal notch, just as the depth of the trachea increases and the number and importance of the overlying structures.

(*d*) The patient's shoulders should be raised by a sand-bag and the head thrown back and steadied. This position draws the trachea up and throws it forward, thereby increasing the operative field and bringing the trachea nearer the surface.

(*e*) The incision should be made *exactly in the median line*, aptly called by Woolsey the "linea alba" of the neck. This

line corresponds to the point where the layers of fascia meet, to the median raphe between the muscles, and incurs the least amount of hemorrhage by avoiding the greatest number of vessels. The exact median incision is also the best preliminary precaution against "losing the trachea" by getting off to one side.

(*f*) The trachea has a considerable range of mobility; it rises and falls with each respiration; it should, therefore, be steadied by transfixing it with a sharp hook and drawing it forward before opening it.

(*g*) The trachea should be opened by a short thrust of the knife in order to penetrate the lining mucous membrane. The mistake has been made of pushing the mucosa in front of the knife and introducing the tube between the mucous membrane and the fibrocartilaginous portion of the trachea.

(*h*) In children the difficulties of tracheotomy are increased by its smaller size and its greater depth. The presence of the thymus gland and the higher level of the vessels at the root of the neck must be taken into consideration.

(*i*) The greatest danger in tracheotomy is hemorrhage getting into the trachea and causing asphyxiation by obstructing the bronchi; therefore, *hemostasis should be complete before opening the trachea.*

The trachea may be the site of tubercular or syphilitic ulceration which finally destroys the tracheal rings and results in the production of a stricture.

Foreign bodies may pass the larynx and become fixed in the trachea at its bifurcation, or, if they pass beyond this point, they usually plug the right bronchus, since the right bronchus is the larger and more direct continuation of the trachea.

The **thyroid gland** is a ductless and vascular structure of considerable volume situated on the sides and in front of the upper part of the trachea, and extending upward on each side of the larynx. It is larger in the female than in the male, enlarges during menstruation and pregnancy, and atrophies in old age. The thyroid gland elaborates an internal secretion which is indispensable to the animal economy. If this secretion be considerably increased or diminished, grave pathologic conditions follow. If total extirpation of the gland be done, *myxedema* follows—a condition characterized by the deposition of mucous fluid in the subcutaneous tissues, especially in the eyelids, lips, and hands. It is due to an excess of mucin in the system and is accompanied by mental dulness, sluggish move-

ments, and unsteadiness of gait. Cretinism is also associated with this condition when the gland is congenitally absent. On the other hand, if the secretion of this gland be excessive, as in Graves' disease (exophthalmic goiter), there is produced an over-activity of the heart, exophthalmos, and general organic disturbance.

It will, therefore, be observed that the thyroid region is one of great importance, and its exact topographic anatomy of practical interest to the surgeon.

The thyroid gland consists of two lateral lobes running parallel to the sides of the trachea and larynx, and connected in front by the isthmus (Fig. 94).

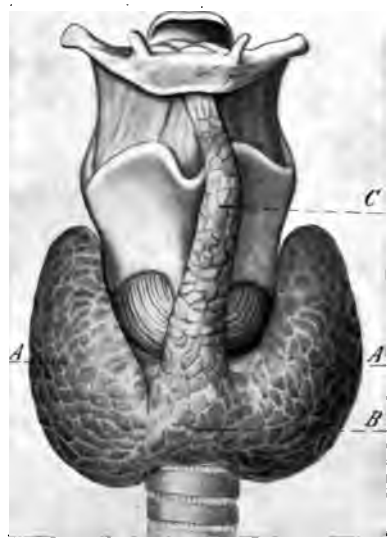

FIG. 94.—THE THYROID GLAND.
AA, The lobes; *B*, the isthmus; *C*, the inconstant middle lobe.

The lateral lobes are about 2 inches in length, extending from the fifth tracheal ring to the middle of the thyroid cartilage. Their outer surface is convex, their inner surface concave and molded to the upper five tracheal rings, the cricoid, and the lower part of the thyroid cartilage.

The isthmus connects the two lateral lobes in front (see Fig. 94), measuring about ¾ inch in height, and lying in front of the second, third, and fourth tracheal rings.

Close to the upper border of the isthmus is an arterial anasto-

mosis formed by branches of the superior thyroid arteries. It may attain considerable size, and should be remembered when operating in this region.

The *middle lobe* (pyramid of Lalouette) *is occasionally present.* It consists of a slender glandular prolongation extending from the superior border of the isthmus and reaching in some cases to the hyoid bone (see Fig. 94).

The entire gland is enclosed in a fibrous capsule derived from the deep cervical fascia, which forms a suspensory ligament and connects it with the larynx and the upper tracheal rings.

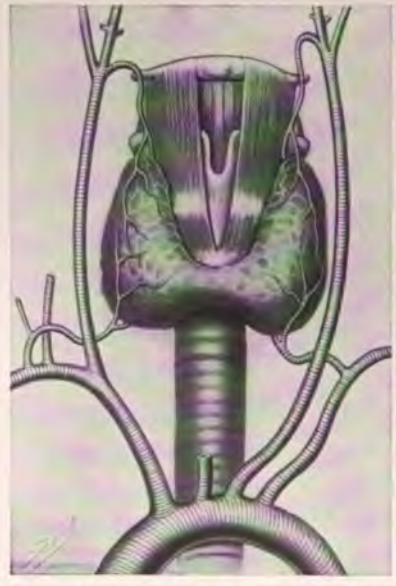

FIG. 95.—THE ARTERIES OF THE THYROID GLAND.
Note the four arteries at the four angles of the gland.

Relations of the Thyroid Gland.—*In front* the thyroid gland is covered by the same layers as the trachea, and overlapped by the anterior border of the sternomastoid.

Behind, it is in contact with the trachea, larynx, pharynx, esophagus, inferior thyroid artery, and recurrent laryngeal nerve. The posterior border is in contact with the carotid sheath and is grooved by the common carotid artery.

Vessels.—The *arteries* are four: the two superior thyroids from the external carotid and the two inferior thyroids from the subclavian. They are situated at the four angles of the gland

and form four vascular pedicles (Fig. 95); occasionally, the thyroidea ima arises from the innominate and ascends in front of the trachea.

The superior thyroid from the external carotid descends to the upper angle of the gland, and after giving off a branch which goes to the posterior surface of the gland it reaches the isthmus and anastomoses with the artery of the opposite side.

The inferior thyroid, from the subclavian, passes up behind the common carotid and in front of the vertebral, reaches the inferior angle of the gland, and is distributed mainly to its posterior surface.

The relation of the recurrent laryngeal nerve to the inferior thyroid artery is of great practical importance in ligating the

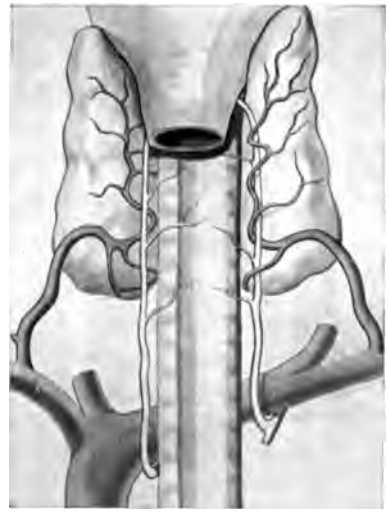

FIG. 96.—THE RELATIONS OF THE RECURRENT LARYNGEAL NERVE TO THE INFERIOR THYROID ARTERY.

artery (Fig. 96). In the upper part of its course the artery is closely accompanied by the recurrent laryngeal nerve, the artery passing behind the nerve as it enters the gland.

The **veins** are very numerous, and form a rich plexus at the lower border of the isthmus. The inferior thyroid veins complicate the operation of low tracheotomy.

The **nerves** are derived chiefly from the middle cervical sympathetic ganglion. It also receives a few filaments from the superior and recurrent laryngeal nerves.

The **lymphatics**: the descending trunks are drained by the glands in front of the trachea, the ascending trunks by one or two small glands in front of the larynx and the glands at the bifurcation of the carotid.

Goiter (bronchocele) is a pathologic enlargement of all the constituent elements of the thyroid gland. It may be lateral, involving a single lobe, or bilateral. When the glandular elements predominate, a *cystic goiter* is formed. When the vascular elements predominate, we get a *pulsating* or *aneurysmal goiter*.

If the enlargement is associated with exophthalmos, tachycardia, and general constitutional disturbances due to excess of thyroid secretion, the condition is known as *exophthalmic goiter*.

Some Phenomena of Enlarged Thyroid Explained by the Anatomic Relations.—(*a*) *A thyroid tumor rises and falls with the larynx in deglutition*, because the thyroid gland is intimately connected with the larynx and trachea and participates in all its movements.

(*b*) *Dysphagia* caused by backward pressure against the pharynx and esophagus.

(*c*) *Dyspnea* caused by pressure on the trachea. Compression may be such that there is a lateral deviation of the trachea, or, should the tumor invade the mediastinum, the trachea may be compressed between the two osseous planes formed by the sternum and the vertebral column.

(*d*) *Hoarseness* or *loss of voice* is due to pressure of the recurrent laryngeal nerve causing paralysis of the intrinsic muscles of the larynx.

(*e*) *Dilatation of the pupil* is caused by pressure on the sympathetic nerve affecting the pupil of the same side.

(*f*) *Cerebral congestion* from pressure on the internal jugular vein.

Thyroidectomy.—In contemplating an extirpation of the thyroid gland it must be remembered that the secretion of this gland is necessary to the animal economy; hence, *total extirpation of the thyroid gland should not be done*.

As a rule, not more than one lateral lobe with the isthmus is removed. In this operation local anesthesia possesses two important advantages:

(*a*) It does not produce engorgement of the vessels and increased hemorrhage.

(*b*) It enables the operator to note any change in the char-

acter of the voice, should the recurrent laryngeal nerve be accidentally included in a ligature.

In removing a thyroid tumor note the following points:

(*a*) The most advantageous incision, both from an operative and cosmetic standpoint, is Kocher's "collar incision," a curved transverse incision with the convexity downward.

(*b*) The normal relations of the contiguous structures are all modified by the size and extent of the growth.

(*c*) Be sure that the capsule of the gland is reached before proceeding to enucleate. Much confusion will be avoided by following this suggestion.

(*d*) After the upper portion of the growth is freed and displaced forward, ligate the superior thyroid artery and vein.

(*e*) The inferior thyroid artery is accompanied in the upper part of its course by the recurrent laryngeal nerve. Avoid this nerve by ligating the inferior thyroid artery, not too close to the trachea.

(*f*) Remember the intimate relation between the middle laryngeal, sympathetic ganglion, and the inferior thyroid artery and protect it from injury.

Resection of the cervical sympathetic ganglia for exophthalmic goiter has been exploited by Jonnesco, and Deaver regards it as the operation of choice, since the results of operation are far better than in other procedures, the mortality is much lower, and in cured cases the improvement is permanent (see pages 167 and 168).

Accessory thyroids are small isolated masses of thyroid tissue which may be located anywhere between the arch of the aorta and the hyoid bone. They have been recognized at the base of the tongue, commonly between the hyoid bone and the isthmus of the gland, and about the lateral lobes of the thyroid. Rarely they have been found below the level of the thyroid as far as the arch of the aorta. They are subject to the same pathologic changes as the normal thyroid and undoubtedly contribute their share of thyroid secretion, which explains those cases of total extirpation of the thyroid gland unattended by subsequent myxedema (Testut).

The Parathyroid Glands.—The investigations of Moussu, Vassale, and MacCullum have demonstrated that these glands play an important rôle in thyroid pathology. They possess a distinct function indispensable to the animal economy and their complete removal leads to tetany and death. The parathyroid glands, while inconstant in number and position, may

be said to have a fairly typical arrangement, as demonstrated by MacCullum and verified by the author in a number of dissections.

They are flat, oval-shaped bodies of bright brown color and flabby softness. Their color and consistency distinguishes them from thyroid tissue or lymph-glands, which are much firmer. They are usually four in number—two each on the posterior surface of the lobes of the thyroid close to the tracheo-esophageal groove. They are found in the loose areolar tissue not intimately connected with the capsule of the thyroid.

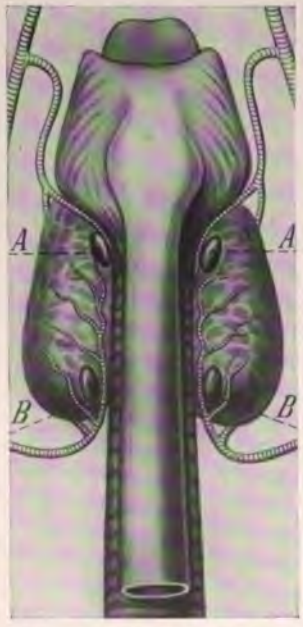

Fig. 97.—The Parathyroid Glands.
A, A, Superior parathyroids; *B, B*, inferior parathyroids.

The two superior parathyroids lie near the esophagus and are in relation with the posterior branch of the superior thyroid artery. The two inferior parathyroids are the larger and are situated near the posterior edge of the thyroid lobe in relation with the branches of the inferior thyroid artery (Fig. 97).

Clinical Considerations.—In the surgery of the thyroid gland the intimate relations of the parathyroids and the danger of their removal must be distinctly understood.

These two varieties of glands represent two distinct functions. Suppression of the thyroid function is followed by chronic symptoms, as manifested by myxedema. Suppression of the parathyroid function is followed by acute symptoms—tetany, muscular spasm and rigidity, rapid respiration, profuse salivation, and death.

If, therefore, in incomplete excision of the thyroid there be even a partial removal of the parathyroids, a condition of parathyroid insufficiency may result, giving rise to alarming symptoms which may prove fatal.

The parathyroids may be avoided by remembering that they lie in loose areolar tissue and have no intimate connection with the thyroid capsule; that after ligation of the thyroid

arteries and recognition of the recurrent laryngeal nerves, the parathyroid glands are to be protected by keeping close to the capsule or by leaving behind that portion of the thyroid which is in close contact with the trachea.

The **esophagus** is a flat musculomembranous tube, about 10 inches in length, extending from the pharynx to the cardiac

FIG. 98.—THE ESOPHAGUS IN ITS RELATIONS TO THE TRACHEA AND AORTA.

Note the deviation to the left of the median line: *A*, the esophagus; *B*, the trachea; *C*, the aorta; *D*, line of diaphragm.

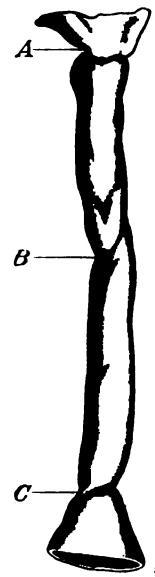

FIG. 99. — THE ESOPHAGEAL TUBE SHOWING THE THREE POINTS OF CONSTRICTION.

A, Opposite the cricoid cartilage; *B*, where it is crossed by the left bronchus; *C*, where it passes through the diaphragm.

orifice of the stomach. It begins at the border of the cricoid cartilage (at the level of the sixth cervical vertebra), passes downward behind the trachea, and ends at a point opposite the tenth dorsal vertebra. From the incisor teeth to the beginning of the esophagus is about 5 inches; hence, a tube

passed into the esophagus would reach the stomach at a point 15 inches from the incisor teeth.

The direction of the esophagus is oblique, from above down and from right to left. At its origin it is in the median line, but it gradually deviates to the left until at its lower extremity it is about ¾ inch to the left of the median line (Fig. 98).

The *caliber* of the esophagus is very important in its practical bearing upon the impaction of foreign bodies, the formation of strictures, and the passage of esophageal bougies.

The Three Points of Constriction (Fig. 99).—When the caliber of the esophagus is examined closely, there are found three points of constriction.

(*a*) At its beginning, opposite the cricoid cartilage. The pharynx, like a funnel, leads down to the narrow opening of the esophagus; hence, foreign bodies are very apt to become impacted at this point.

(*b*) At the point where the left bronchus and the arch of the aorta cross, about 2¾ inches below the cricoid.

(*c*) At the point where it passes through the diaphragm.

At these points the caliber is about ½ inch; elsewhere it is about ¾ inch.

Relations of the Esophagus in the Neck.—Since the surgical limits of the esophagus are confined to the neck, the relations here are of great practical importance.

In front is the membranous portion of the trachea (portion where the cartilaginous rings are absent). Loose cellular tissue separates the two tubes and thus facilitates motion between them. If deep suppuration invades this tissue it may become the cause of dysphagia.

The trachea forms a protection for the esophagus, and hence the latter is rarely injured in suicidal wounds of the throat. It is also a valuable landmark in locating the esophagus when performing esophagotomy.

Behind is the vertebral column, covered by the prevertebral muscles and separated by a layer of cellular tissue which is continuous with the retropharyngeal cellular tissue; hence, *retropharyngeal abscess* may burrow along the esophagus and produce dysphagia.

Laterally the esophagus corresponds to the sheath of the great vessels, part of the lateral lobes of the thyroid gland, and the recurrent laryngeal nerves lie between it and the trachea.

In the thorax the esophagus lies in the posterior mediastinum.

The bifurcation of the bronchi corresponds to the anterior surface of the esophagus, especially the left bronchus, which grooves the wall of the esophagus.

Behind is the thoracic duct and the great azygos vein. Loose cellular tissue and lymphatic ganglia separate it from the vertebral column.

Laterally, on the left the aorta and its branches, the common carotid and left subclavian. The aorta at first placed to the left of the esophagus, passes behind it to reach the aortic orifice of the diaphragm which is situated behind and a little to the right of the esophagus; hence, these two tubes cross like the letter X, the esophagus in front and the aorta behind (see Fig. 98).

The esophagus is accompanied by the two pneumogastric nerves, the left in front and the right behind.

The *abdominal portion* of the esophagus is not over ½ inch in length and corresponds in front to the posterior border of the left lobe of the liver.

The **lymphatics** enter the deep cervical and the posterior mediastinal glands.

The **nerves** are derived from the two pneumogastrics and the sympathetic ganglia in the thorax. From the left pneumogastric is derived the anterior esophageal plexus and from the right pneumogastric the posterior esophageal plexus. They form an interlacement of nerves which surround the esophagus.

Clinically.—Foreign bodies are most apt to become impacted at the cricoid constriction; if they pass this point they usually reach the stomach.

Note the relation of aneurysm of the aorta and symptoms of dysphagia. In this condition pressure may cause a thinning of the coats of the esophagus and the passage of a bougie may be attended by perforation and fatal hemorrhage. Foreign bodies impacted at this point may ulcerate through the esophagus and penetrate the aorta.

The three points of constriction are the three points of cicatricial contraction following the swallowing of corrosive substances. The reason for this is apparent: it takes a longer time for the corrosive fluid to pass through the constricted portions; hence, there is more tissue damage and the subsequent formation of stricture at these points.

In passing a stomach-tube or esophageal bougie the base of the tongue should be depressed by the index and middle fingers and the tube guided toward the posterior wall of the pharynx

and a little toward the left. Resistance will be felt when the tube reaches the beginning of the esophagus opposite the cricoid; this is due to spasm of the muscles. If the patient at this point be encouraged to swallow, the muscles will relax and the tube pass without further difficulty. *Always use the largest possible bougie. The largest bougie does the least damage.*

Stricture of the esophagus may be (*a*) *spasmodic,* occurring in neurotic individuals and giving rise to intermittent dysphagia. In these cases the esophageal bougie passes through without obstruction, the constriction being due to muscular spasm.

(*b*) *Cicatricial,* due to contraction of a scar following injury from swallowing corrosive fluids. These strictures are most apt to occur at the three normal points of constriction, as described above.

(*c*) *Malignant growths,* most common at the upper end opposite the cricoid cartilage, or at the lower end near the diaphragm. In cancer of the lower extremity of the esophagus patients frequently experience pain at its upper extremity (Tillaux).

Esophagotomy is performed for the removal of a foreign body in the cervical and upper dorsal portions of the esophagus. The left side is always selected because of the deviation of the esophagus to the left. The best exposure is made through an incision beginning at the upper border of the thyroid cartilage and along the anterior border of the sternomastoid muscle. The sheath of the carotid is found and drawn outward, the lobe of the thyroid gland is raised and drawn inward. The trachea is the guide to the esophagus, which latter lies immediately behind it. The esophagus may be more definitely shown by the introduction of a bougie through the mouth. Remember the position of the recurrent laryngeal nerve—in the tracheo-esophageal groove—and carefully avoid it by incising the esophagus as far posteriorly as possible.

If the foreign body be located in the lower part of the esophagus, removal may be attained by performing gastrotomy.

The **deep cervical fascia** plays an important part in the pathology of the neck, because of its influence upon the direction in which pus may travel or new growths extend, it is not difficult to understand the arrangement of this fascia if it is regarded as a fibrous cuff completely investing the neck from the lower jaw to the clavicle, and from the external occipital protuberance to the spine of the scapula. Furthermore, this fibrous cuff not only invests the neck, but from its inner sur-

face sends out a number of partitions which form sheaths for the muscles, vessels, and glands, dividing the neck into compartments and giving stability to the important structures within.

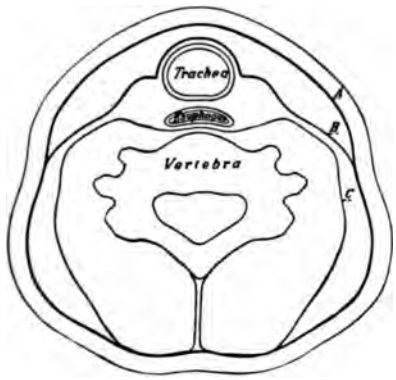

Fig. 100.—The Layers of the Deep Cervical Fascia in Diagram.

A, The outer or investing layer; *B*, the middle or pretracheal layer; *C*, the inner or prevertebral layer.

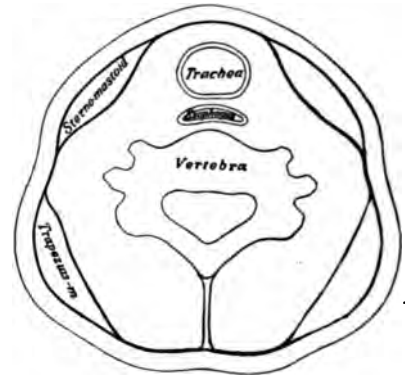

Fig. 100 *a*.—The Outer or the Investing Layer, Split to Ensheath the Muscles.

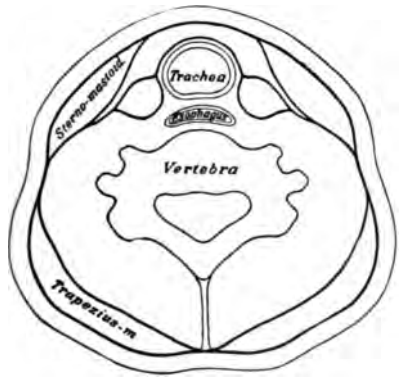

Fig. 100 *b*.—The Outer Layer and Middle Layer Split to Form the Carotid Sheath.

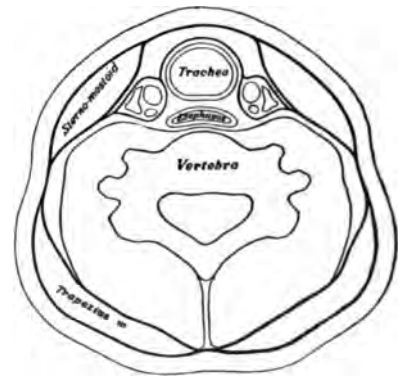

Fig. 100 *c*.—The Final Arrangement of the Three Layers of Deep Cervical Fascia.

Divide the deep cervical fascia into three principal layers—

(*a*) the *outer* or *investing layer*,

(*b*) the *middle* or *pretracheal layer*,

(*c*) the *inner* or *prevertebral layer*.

Thus, the three names "*investing*," "*pretracheal*," and "*prevertebral*" suggest the general trend of the three layers (Fig. 100).

(*a*) The *outer* or *investing layer* forms the fibrous cuff which completely encircles the neck. In its investment of the neck, however, it splits into layers to form sheaths for the muscles in the following manner: Tracing it from behind, where it is attached to the ligamentum nuchæ and the spinous processes of the cervical vertebræ, it immediately splits to encircle the trapezius muscle. The two lamellæ unite again at the anterior border of this muscle and pass forward to the posterior edge of the sternomastoid muscle, where it again divides to ensheath the muscle and unite at its anterior border into a single layer, which finally blends in the middle line with that of the "linea alba" of the neck.

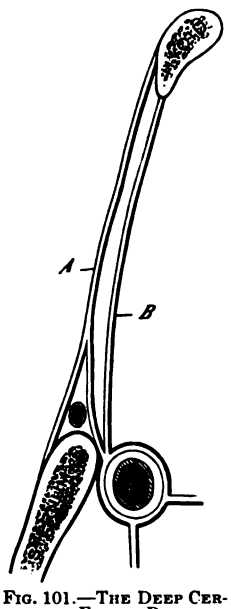

FIG. 101.—THE DEEP CERVICAL FASCIA BETWEEN THE HYOID AND STERNUM.
A, The outer layer; *B*, the middle layer.

Laterally, the outer fascia is attached. above, to the lower border of the jaw, the mastoid process, and the superior curved line of the occipital bone; below, to the clavicle, just above which it is pierced by the external jugular vein. In the median line it is attached to the hyoid bone, and, below, it divides into two layers which are attached, respectively, to the anterior and posterior margins of the upper border of the sternum. Between these layers is a space containing fat and one or two small lymphatic glands (Fig. 101).

(*b*) The *middle* or *pretracheal layer* is given off from the outer layer behind the sternomastoid muscle. It passes forward and forms the carotid sheath (containing the common carotid, the internal jugular vein, pneumogastric nerve, and a number of lymphatic glands). It encloses the omohyoid muscle, passes in front of the trachea, enveloping the thyroid gland, and joins the fascia of the opposite side.

Above, it is attached to the hyoid bone; below, it passes down to the sternum, enclosing the brachio-cephalic vein and thence into the anterior mediastinum, where it unites with the pericardium.

(*c*) The *inner* or *prevertebral layer* is given off from the outer layer at the anterior border of the trapezius muscle.

It passes behind the pharynx and esophagus, and in front of the spine and prevertebral muscles; above, it is attached to the base of the cranium; below, to the first rib, where the inner portion becomes continuous with the posterior mediastinum; the outer portion forms the sheath of the subclavian vessels and continues downward with them into the axilla.

According to Tillaux, this arrangement of the cervical fascia forms four spaces and has an important influence upon the course of cervical abscess.

(*a*) The space between the skin and outer layer is common to the whole cervical region, and, when the site of subcutaneous abscess, shows a great tendency toward extension.

(*b*) The space between the outer and middle layers is narrow above, where the two layers are in contact. Below, it is equal in depth to the sternum and clavicle, which space is filled with fat and a few lymph-glands; most of the abscesses of the neck originate in this space and usually point externally. They are prevented from burrowing, either into the mediastinum or axilla, by the attachment of the middle layer of fascia to the clavicle and sternum.

(*c*) The space between the middle and inner layers (pretracheal and prevertebral layers) is the largest space and contains all the essential organs of the neck. Below, this space communicates directly with the thorax and axilla; hence, a collection of pus in this compartment might burrow either into the thorax or axilla. *This is the dangerous area of the neck, and abscesses here should be promptly drained.*

(*d*) The space behind the inner or prevertebral layer is very narrow. It is most frequently the site of cold abscesses, due to tuberculosis of the vertebræ. The acute abscesses originate in the lymphatic glands. An abscess in this space in the region of the pharynx is known as *retropharyngeal abscess.* If such an abscess is not drained through the mouth or neck it may gravitate into the mediastinum. In general, it may be well to remember that collections of pus in the neck may clinically be divided into two classes:

(*a*) Pus in front of the middle or pretracheal layer usually points to the surface and confines itself to the neck.

(*b*) Pus behind the middle or pretracheal layer is in the dangerous area; there is no tendency to point to the surface, and unless promptly drained it will gravitate toward the mediastinum or axilla.

The **lymphatic glands of the neck** have already been discussed in their appropriate regions. A brief résumé of their

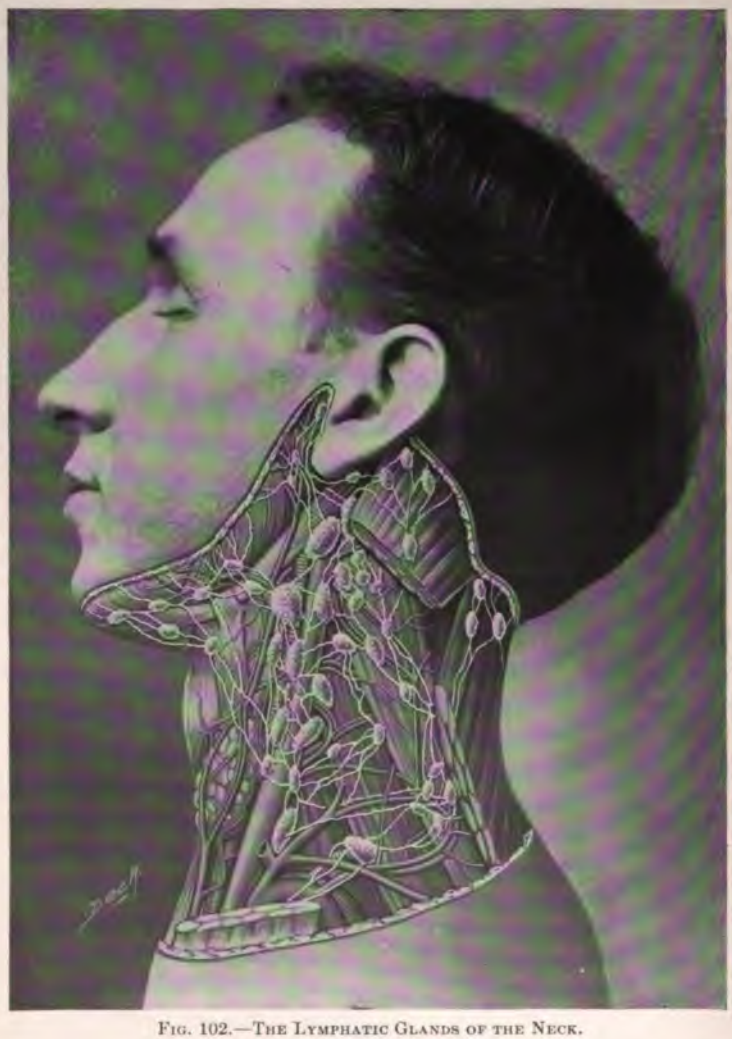

FIG. 102.—THE LYMPHATIC GLANDS OF THE NECK.

applied anatomy will serve to emphasize their surgical importance.

The neck is one of the most important lymph stations of the body. Not only is it rich in lymphatic glands, but at the

base of the neck empty the two great lymphatic canals—the thoracic duct and the right lymphatic duct. The general arrangement of these glands, according to Poirier, is as follows: A glandular collar encircles the neck at its junction with the head. From this passes, on either side, a vertical chain underneath the sternomastoid, accompanying the vessels and nerves as far as the junction of the neck and thorax (Fig. 102).

Regions Drained.—Not only do the cervical lymphatics drain the surrounding regions—the head, face, nose, mouth, and throat—but lymphatics from the breast, stomach, and esophagus also communicate.

Enlarged glands of the neck, while they may be due to primary inflammation or tumor, are usually secondary to infection or cancer.

Remember that the lymph-stream, when blocked, may travel in any direction; hence, the glandular collar about the neck constitutes a formidable barrier to infection from the head and neck above, and from the thorax below.

Tuberculous glands are by far the most common tumor of the neck and the most frequent cause of abscess. The original lesion is in those parts drained by the glands, usually in the nasopharynx or tonsils.

Remember, in operating upon tubercular glands of the neck, that the palpable enlargement is no index of the extent of involvement; one or two enlarged glands on the surface usually lead to a nest of tubercular glands extending along the internal jugular vein even as far as the clavicle; hence, the operation for extirpation of tubercular glands requires an exact anatomic dissection and is a procedure of major importance.

Cancerous Glands.—Involvement of the neighboring lymphatics is secondary to every cancerous growth. Hence, modern surgery recognizes no operation for cancer which does not include a thorough removal of all the neighboring lymphatic glands. In cancer of those parts drained by the cervical lymph-glands the possibility of extirpating the infected glands is not insurmountable, since, as Crile has shown, the collar of lymphatics forms an extraordinary barrier through which cancer rarely penetrates, and every portion of this barrier is surgically accessible.

The thorough extirpation of cancerous glands of the neck usually necessitates excision of the internal jugular vein. Many observers have shown that both internal jugulars may be excised without circulatory disturbance.

While the enlargement of the lymph-glands usually occurs on the side of the original lesion, yet this does not invariably follow; a notable exception is found in cancer of the posterior surface of the tongue, where enlarged glands may be found on the opposite side of the lesion. Hence, in cancer of the tongue the lymphatic glands should be removed from both sides of the neck.

Note also that cancer of the breast, stomach, and esophagus is followed by enlarged glands of the neck.

Beside the secondary affections the cervical glands may be primarily the site of *sarcoma*, which may attain a large size and destroy life by compression of important structures.

Fig. 103.—Location of the Orifices of Persistent Branchial Fistulæ.

Hodgkin's disease is a multiple hypertrophy of the lymphatic glands, beginning in the neck and later involving the glands of the axilla and groin. It is associated with progressive anemia and enlarged spleen.

Branchial fistulæ and **cysts** are due to imperfect obliteration of one of the branchial clefts. Senn, in quoting Roser, shows that imperfect closure of any one of the branchial tracts may result in three conditions:

(*a*) *Branchial fistula*, when the entire tract remains open, there being an internal and external orifice.

(*b*) *Cystic fistula*, when one end of the tract is closed.

(*c*) *Branchial cyst*, when both ends of the tract are closed, the intermediate portion remaining open.

The external orifices of these fistulæ are usually indicated by a nodule of skin and are situated, according to Sutton, in the line of the anterior border of the sternomastoid muscle opposite the angle of the jaw, the thyrohyoid space, and the sterno-clavicular articulation (Fig. 103).

The internal orifices are either in the region of the tonsil or the sinus pyriformis. The treatment consists in complete extirpation. This, as can be conjectured, consists in an exact anatomic dissection of some difficulty, owing to the adherence of the wall of the tract to the sheath of the great vessels and the difficulty of following the tract to its ultimate termination in the wall of the pharynx.

PART II

THE THORAX

CHAPTER XI

SURFACE ANATOMY

In examining the surface of the thorax note that the *sternum* may be palpated from its upper to its lower border. Note the *suprasternal notch* on the upper border between the sterno-clavicular articulations. The trachea may be felt passing behind it, and it is just above the notch that low tracheotomy is performed (Fig. 104).

Pass the fingers along the surface of the sternum and note the prominent transverse ridge which marks the junction of the manubrium and gladiolus. This junction is known as the *angulus Ludovici,* directly behind which lie the arch of the aorta and the bifurcation of the trachea. It also marks the junction of the second costal cartilage; hence, the second rib may thus be readily located. At the lower end of the sternum may be felt the *ensiform cartilage.*

Identify and count the ribs. Remember that the first rib can be felt only by pressing the finger downward and backward behind the clavicle. The second rib is the first rib that can be palpated on the surface, and is opposite the transverse ridge on the sternum. All the ribs should be identified and their oblique direction noted. Their spinal attachment being higher than their sternal attachment, it follows that the anterior extremity of the ribs is on a lower plane than the posterior; thus the first rib in front corresponds to the fourth rib behind, etc.

The *intercostal spaces* in front are wider than behind, the third being the widest.

Examine the *mammary gland.* In the male it is rudimentary; in the female it is more or less developed, and extends from

the third to the seventh rib, and from the border of the sternum to that of the axilla. The nipple is situated a little below the summit of the gland (opposite the fourth intercostal space and in the midclavicular line), and is surrounded by a darker circular area, the areola.

Examine the *pectoralis major muscle.* Bring the arm at right angles to the body and throw the muscle into a state of tension. Note the prominent ridge formed by its lower border, extending

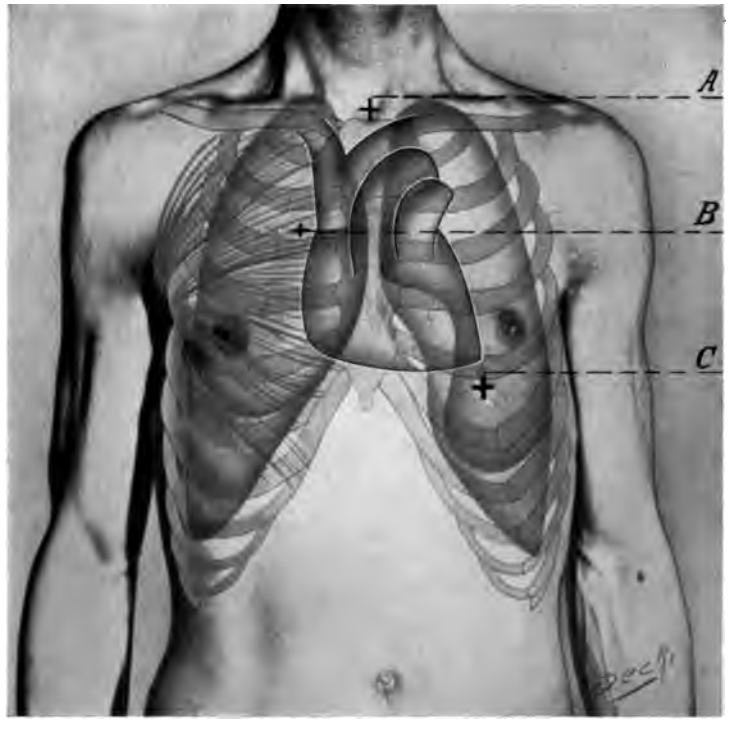

FIG. 104.—THE THORAX.
A, suprasternal notch; *B*, pectoralis major muscle; *C*, apex beat.

from the fifth rib to the upper part of the arm, and thus forming the anterior wall of the axilla.

In the same manner demonstrate the *latissimus dorsi*, forming the posterior wall of the axilla.

In a thin and muscular subject the digitations of the *serratus magnus muscle* may be seen on the side of the chest by raising the arm to the side of the head. Only the digitations con-

nected with the fifth, sixth, seventh, and eighth ribs are visible, the most prominent being the sixth.

Palpate the *apex beat.* Its normal position is in the fifth intercostal space, about 3½ inches to the left of the middle line of the sternum.

Behind, the scapula covers the ribs from the second to the seventh.

The inferior angle of the scapula corresponds to the fifth intercostal space in the axillary line, the point at which a puncture is made for withdrawing the fluid in pleuritic effusion.

CHAPTER XII

THE THORAX

THE **thorax** is a bony cage situated between the neck and abdomen, containing the heart, lungs, esophagus, and roots of the great vessels.

It is bounded in front by the sternum, behind by the vertebral column, and laterally by the ribs.

Above, it directly communicates with the neck; below, it is separated from the abdomen by a musculo-aponeurotic partition, the diaphragm.

Below, the thorax is overlapped above by the lower cervical region, the pleural apex extending into the neck from ½ to 1 inch.

The thorax overlaps the upper part of the abdomen, the diaphragm forming a dome with its convexity above, rising in front as far as the level of the fifth rib. The arched diaphragm thus greatly increases the capacity of the abdomen and portions of the abdominal viscera, such as the liver, stomach, and spleen, are hidden under the thorax. Note, therefore, how penetrating wounds of the inferior portion of the thorax may enter both the thoracic and abdominal cavities.

In the normal chest the anteroposterior diameter is much shorter than the transverse. The ribs slope downward and forward and form a subcostal angle of 90°.

The two halves of the chest are rarely symmetric.

The circumference of the chest should measure not less than half the length of the body.

In *flat chest* the anteroposterior diameter is shorter than normal; the ribs slope downward so as to form a subcostal angle of less than 90°. This form of chest is found in individuals predisposed to pulmonary tuberculosis.

Barrel-shaped or **emphysematous chest** is due to permanent distention of the air-vesicles of the lung. The anteroposterior diameter is nearly equal to the transverse, and the subcostal angle is greater than 90°.

Retracted chest is a unilateral condition sometimes following

pneumonia. It is brought about by a fibroid condition of the lung and the pleura, which by being adherent substantially retract the diameters of the chest.

Pigeon breast is an abnormal projection of the sternum beyond the level of the ribs, the anteroposterior diameter being considerably lengthened. It is found where respiration is obstructed by enlarged postnasal adenoids, and in rachitic children in whom, also, there frequently occur nodular enlargements at the junction of the ribs with their cartilage which produce a beaded appearance termed the "*rachitic rosary.*"

The **sternum** forms the anterior boundary of the chest cavity. It presents a median vertical depression corresponding to the line of fusion of its two lateral halves, and transverse crests which represent the line of juncture of its three distinct parts. The skin covering it is thick and not very mobile, and almost devoid of sensation in the median line. It is a favorite site for the formation of keloid after a cicatrix; hence, the importance of primary union in wounds of this region.

Gummatous tumors have a predilection for the soft parts covering the sternum.

The sternum consists of three parts: the manubrium, gladiolus, and ensiform cartilage. It has been compared to a sword, the three parts representing, respectively, the handle, blade, and point. A distinct transverse ridge marks the line of junction between the manubrium and the gladiolus. It corresponds to the articulation of the second rib and may be of service in counting the ribs in a fleshy subject.

The top of the sternum presents a depression, the *interclavicular notch*, on the sides of which are the articular surfaces for the sternal end of the clavicle.

On the lateral borders of the sternum are the seven articular cavities which receive the costal cartilages of the seven true ribs. Each of these forms an arthroidal joint and is held in place by the perichondrium, which is continuous with the periosteum of the sternum.

At the lower part of the sternum, near the ensiform appendix in the median line, there sometimes exists a round hole, *the sternal foramen*, sometimes large enough to admit the little finger. This orifice may establish communication between a mediastinal abscess and the exterior, or a subcutaneous abscess may invade the cellular tissue behind the sternum.

The sternum is developed in lateral halves. When, because of lack of development, the two halves fail to fuse in the median

line, we have a condition of *cleft sternum*, which may give rise to displacements of the viscera behind.

Fracture of the sternum by direct violence is unusual, owing to the elasticity of the ribs to which it is attached. It is more liable to occur indirectly by overextension or flexion of the trunk. It has more frequently occurred from a fall on the head, the chin being forcibly driven against the sternum.

The spongy character of the tissue predisposes it to osteitis. Those whose occupations bring constant pressure against the sternum, such as shoemakers, are liable to be affected with periostitis, abscess, and tubercular osteitis.

The sternum has been trephined for mediastinal abscess and for paracentesis of the pericardium.

The **ribs** are twelve in number. Seven of these articulate directly with the sternum (the true ribs). The lower five are the false ribs, the first three of which have their cartilages attached to the cartilage of the rib above, and the last two (the floating ribs) are free at their anterior extremities. The ribs are composed of spongy bone tissue covered with a thin layer of compact bone. They may be the site of caries from traumatism, or from tubercular, syphilitic, or typhoid infection.

Supernumerary ribs are rare. The most frequent appearance of this phenomenon, and the most interesting from a surgical standpoint, is that of the seventh cervical rib. It comes from the transverse process of the seventh cervical vertebra and is found on both sides, but unequally developed.

Surgically, it presents an exostosis occupying the subclavian fossa and independent of the clavicle. It may compress the vessels and nerves beneath the clavicle, in which case it should be extirpated. It is worth noting that it is frequently adherent to the pleural cul-de-sac, and delicate dissection will be necessary to free it.

The ribs are attached behind, to the vertebræ, and in front, to the sternum by the interposition of cartilage, which gives to the thorax great elasticity. It must be remembered that the direction of the ribs is oblique from above down and that the posterior extremities are much higher than the anterior.

Because of the external convexity of the ribs a bullet may strike a rib without entering the chest and, following the rib around, may lodge at a point opposite the wound of entrance.

The inferior angle of the scapula is a convenient point from which to locate the ribs. If a horizontal line be passed around the thorax at this angle, this line at the sternum will correspond

to the interspace between the fourth and fifth ribs, and at the nipple to the fifth rib. The fifth rib in front corresponds to the ninth rib behind.

Fracture of the Ribs.—The ribs most frequently broken are the middle ones: the sixth, seventh, and eighth. The rib least frequently fractured is the first, since it lies under the protection of the clavicle.

The floating ribs are rarely fractured.

The ribs are broken by muscular action, as in coughing or sneezing, or by indirect violence when pressure is exaggerated and exceeds the limits of elasticity, as when a wheel passes over the chest, or by direct violence from a blow. The point of fracture is very apt to be in its weakest part, just in front of the angle of the rib. No shortening or vertical displacement occurs, because of the attachment of the intercostal muscles.

When the fragments are bent inward they may tear the pleura, penetrate the lung, and give rise to severe pain, dyspnea, spitting of blood, and traumatic pneumonia; in some instances fatal hemorrhage has ensued.

Incomplete fracture of the rib is quite common where the ordinary symptoms of fracture are wanting. The most reliable symptom of this condition is pain at a fixed point, increased at the time of inspiration.

In cases of *empyema*, when it is necessary to give free vent to the pus, resection of a rib is the proper procedure. The point of election is the sixth rib in the midaxillary line. The rib is removed subperiosteally, to preserve the intercostal vessels.

In old cases of empyema where the lung is prevented from expanding because of adhesions, the rigid chest wall can no longer adapt itself to the crippled lung and it may be necessary to resect a number of ribs to effect a permanent depression of the chest wall. This may be accomplished by *Estlander's operation*, which consists in the removal of portions of the second, third, fourth, fifth, sixth, and seventh ribs.

The **intercostal spaces** correspond to the ribs between which they are placed, taking their name from the rib above; thus the space between the second and third is the second intercostal space.

They are narrower behind than in front. The spaces are widest above. The last four are the narrowest. These spaces are occupied by the intercostal muscles, vessels, and nerves.

Along the under and inner border of each rib is the *costal groove*, which lodges and protects the vessels, the vein being

above, the artery in the middle, and the nerve below—(*V-A-N* from above down) (Fig. 105).

The **intercostal arteries** come from the aorta, the superior intercostal of the subclavian, and from the internal mammary. They occupy the costal groove by which they are protected in nearly their entire course. In paracentesis of the thorax the needle should be inserted close to the upper border of the rib to avoid wounding the vessels.

FIG. 105.—SHOWS THE COSTAL GROOVE WHICH LODGES AND PROTECTS THE VESSELS.

The **internal mammary artery** lies between the costal cartilages and the pleura, running parallel with the sternum and about ½ inch external to its border. It anastomoses by its terminal branch with the deep egipastric artery, thus forming an anastomosis between the upper and lower extremities. It may be wounded in stabs of the chest. Ligation of the artery is performed through a vertical incision in the second intercostal space, a finger's-breadth from the external border of the sternum.

The **intercostal nerves** are of great practical interest, not only because of the local affections to which they are subject, but more especially, on account of the referred pains which traverse their area of distribution. The first five intercostal nerves supply the chest wall and the overlying skin. A branch of the second intercostal nerve—the *intercostohumeral nerve*—crosses the axilla and supplies the skin on the inner and back part of the arm and is often joined by the lesser internal cutaneous. Hence, in mammary tumors, and in enlarged glands of the axilla, pain is often reflected down the arm to the internal condyle.

Intercostal neuralgia is frequently accompanied by groups of vesicles developing in the skin along the course of the nerve. This affection belongs to that class of skin diseases known as *herpes zoster*, or *shingles*—names which describe the girdle-like character of the eruption.

The lower six intercostal nerves and the last dorsal nerve not only supply the chest wall, but are continued on to the abdomen, supplying skin, muscles, and peritoneum of the abdominal wall.

The sixth and seventh supply the area over the pit of the

stomach, the tenth the region of the umbilicus. The last dorsal sends filaments to the skin of the gluteal region.

The distribution of these nerves is of great diagnostic importance, for in many diseases affecting the nerve trunks pain is referred to their peripheral terminations. Hence, we frequently hear children suffering from *Pott's disease* complain of "pain in the belly." Irritation of a single pair of nerves gives the sensation as if a cord were tied around the abdomen. *Pleurisy* and *pneumonia* may be accompanied by an apparent "*acute abdomen*," the pain, tenderness, and rigidity of the abdominal walls simulating peritonitis. The *pneumonias of children* frequently start with *pain in the epigastrium.* Pain in the upper and front part of the chest may be due to irritation of the third

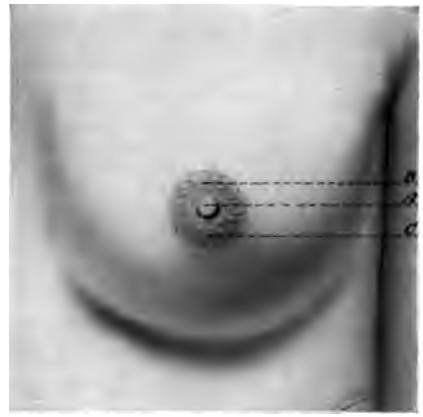

FIG. 106.—THE FEMALE BREAST.
A, nipple; *B*, areola; C, tubercles of Montgomery.

and fourth cervical nerves, which furnish cutaneous branches to this region.

The **mammary region** has for its chief interest a consideration of the female breast (Fig. 106).

The mammary gland, rudimentary in the male, presents in the female a smooth, rounded prominence forming the bust. It lies between the two layers of superficial fascia, extending from the third to the seventh rib, and from the sternum to the anterior axillary border. Instances are recorded of supernumerary glands in the axilla and in the region of Scarpa's triangle. Portions of the mammary gland may be congenitally implanted beneath the deep fascia and become the starting-point of tumor.

The female breast varies in size during life, following closely in its cycle the activity of the uterus. In childhood it is rudimentary, at puberty it develops, during pregnancy and lactation it reaches its greatest size, after the menopause it atrophies.

The gland is surmounted at its summit by the *nipple*, a "cylindric elevation of erectile tissue covered with dark wrinkled skin." The top of the nipple presents the terminations of fifteen to twenty lactiferous ducts which form little dilatations, or ampullæ, just before entering the nipple, and end in orifices smaller than the duct. The nipple is opposite the fourth intercostal space.

Immediately surrounding the nipple is a pigmented area of skin, the *areola*. In women who have not borne children it is of a pinkish hue; during pregnancy it becomes deeply pigmented (dark brown) and remains ever after as evidence of the first pregnancy. In the areola are a number of sebaceous glands, the *tubercles of Montgomery*. They become prominent during pregnancy, and secrete an oily substance which acts as a lubricant to protect the nipple during lactation.

The nipple is frequently the site of excoriations and fissures during glandular activity, which may be the starting-point of mammary abscess.

Chronic inflammation of the skin of the nipple (eczematous) is often the beginning of *Paget's disease* and may finally terminate in mammary carcinoma.

The subcutaneous mammary tissue frequently contains a large amount of fat. It passes in front and behind, the gland sending prolongations between the lobes; hence, the size of the breast is due to the amount of fatty tissue rather than the amount of glandular structure. A large breast does not mean large glandular capacity.

Lipomata of the mammary gland are rare. When they develop in the submammary tissue they push the gland forward and render diagnosis difficult.

Structure of the Mammary Gland.—The mammary gland consists of three kinds of tissue: fibrous, glandular, and fatty (Fig. 107).

The *fibrous structure* is formed by the two layers of superficial fascia which furnishes—

(*a*) The *capsule*—the two layers of fascia between which the gland is contained.

(*b*) The *septa*—the fascial partitions extending between the lobes of the gland. Some of these processes are attached to the

nipple and skin, and form the "suspensory ligaments" of Sir Astley Cooper.

The **gland structure** is of the racemose variety. It consists of small secreting lobules with confluent ducts which unite to form a lobe. From each lobe runs a *lactiferous duct* which terminates in the nipple. The fifteen or twenty lactiferous ducts just before entering the nipple are dilated, the ampullæ forming temporary reservoirs for the milk. The terminal orifice is smaller than the duct. When a lactiferous duct becomes obstructed and distended with milk there is sometimes formed a large tumor—*galactocele* or *lacteal cyst*.

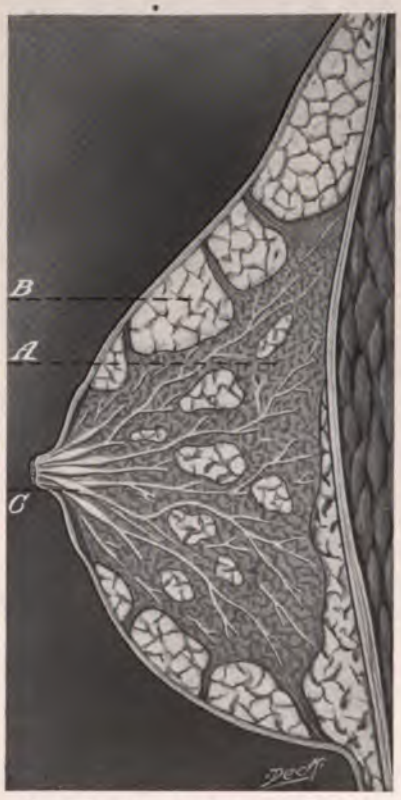

FIG. 107.—SAGITTAL SECTION OF BREAST. *A*, Gland substance; *B*, fatty tissue; *C*, lactiferous ducts.

These ducts are lined with epithelium, continuous with the skin externally and the glandular epithelium internally.

A **submammary bursa** sometimes exists in the lower cellular tissue between the gland and the pectoral fascia. It may be the site of a retromammary abscess developed during the puerperal period; as it increases in size the gland is projected forward.

The **arteries** supplying the mammary gland are branches of the long thoracic, the internal mammary, and the intercostals. The arteries are all of small caliber while the gland is quiescent. During lactation they increase and acquire a considerable size.

The **nerves** supplying the breast are the anterior cutaneous branches of the second, third, fourth, and fifth intercostals, the lateral branches of the third, fourth, and fifth intercostals,

and the supraclavicular branches of the cervical plexus. This nerve supply explains the pain areas in affections of the breast which are manifest in the shoulder, neck, back, and down the inner side of the arm (from the intercostohumeral).

The **mammary lymphatics** play a very important rôle in the pathology of this region (Fig. 108). They consist of:

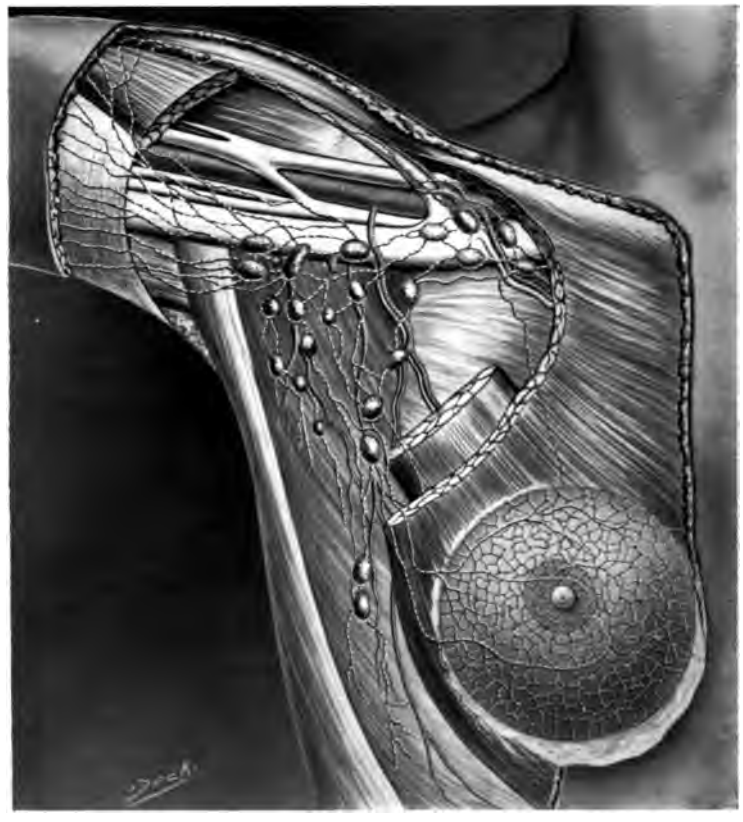

FIG. 108.—LYMPHATICS OF BREAST AND AXILLA.

(*a*) The cutaneous lymphatics;
(*b*) The areolar lymphatics;
(*c*) The glandular lymphatics.

The cutaneous lymphatics carry the lymph from the integument of the breast, *except the nipple and areola*, and converge in collecting trunks which terminate in the axillary glands of the same side. The cutaneous lymphatics near the sternum may

cross over and *the lymphatics of one side terminate in the axillary glands of the opposite side.*

The *areolar lymphatics* drain the nipple and areola and the trunklets pass into the important plexus situated beneath the areola—the *subareolar plexus of Sappey.*

The *glandular lymphatics* form a network about the lobules and milk-ducts and the collecting trunks pass into the *subareolar plexus.*

Thus the subareolar plexus is the central plexus which collects the lymphatics from the nipple, areola, and glandular substance.

From the subareolar plexus two large trunks pass to the axilla. The internal trunk passes from the internal side of the gland around the inferior border of the subareolar plexus and along the lower border of the pectoralis major to the axilla.

The external trunk passes from the external side and runs directly outward to the axilla.

The **accessory mammary lymphatics** are:

(*a*) The *axillary*—a small inconstant channel which comes from the inferior part of the mammary gland and passes directly to the axilla.

(*b*) The *subclavian*—a trunk which comes from the posterior surface of the mammary gland, penetrates the pectoralis major, and running between the two pectoral muscles empties into the subclavian glands.

(*c*) *The Internal Mammary.*—These lymphatics come from the inner part of the mammary gland, they follow the course of the perforating branches of the internal mammary artery, and reach the retrosternal glands.

The *lymphatics of the great pectoral* ramify throughout the muscle and are collected in trunks which empty into the subclavian, the axillary, and the retrosternal glands.

Neoplasms of the Breast.—The breast is a region specially inclined to morbid manifestations.

Painful Subcutaneous Tubercle.—In the subcutaneous tissue about the circumference of the gland are sometimes found small hard nodules, about the size of a pea. They are composed of fibrous tissue and cause excruciating pain because of the involved nerve filaments.

Lipomata may develop superficially, interstitially, or submammary. In the latter case the gland is pushed forward and diagnosis is difficult. Contrary to what might be supposed, lipomata are rare.

The other tumors are adenoma, fibroma, sarcoma, and carcinoma. There is a great tendency of the gland structure to undergo cystic degenerations, such as cystic adenoma and multilocular cystadenoma. These tumors may attain an enormous size and are usually movable on the pectoral muscle. The sarcomas are late in involving the lymphatics, the fibrous capsule protects the neighboring parts, and operative results are good.

Cancer of the breast from an anatomic aspect presents many points of interest. Cancer spreads by way of the lymphatics and a *cancerous breast from a surgical standpoint is co-extensive with the lymphatics which drain it.*

The symptomatology of this affection is readily explained by applying the anatomic facts.

(*a*) *Pain* is rarely an early symptom, since the nerves are not involved until the process begins to involve adjoining lobes. Pain when present is reflected to the shoulder, neck, back, and down the inner side of the arm (see pages 271 to 273).

(*b*) *Retracted nipple* occurs only when the part immediately below the nipple is involved. The nipple is pulled inward by the contraction of the fibrous septa and the lactiferous ducts immediately beneath it; hence, cancer in other parts of the gland would not produce this condition.

(*c*) *Puckering of the skin* is caused by the contraction of the fibrous septa which run to the skin and produce multiple points of retraction, resembling pig skin or the skin of an orange. By the general contraction of these fibrous septa the skin finally becomes adherent to the growth.

(*d*) *Adhesion of the Gland to the Pectoralis Major.*—As the growth proceeds backward the gland becomes adherent to the sheath of the pectoralis muscle. In order to appreciate this symptom *the gland should be moved in the direction of the fibers of the muscle,* never across the fibers, since in the latter movement the muscle moves with the gland.

(*e*) *Glandular Involvement.*—Cancer soon ceases to be a local affection and becomes regional by being disseminated along the lymphatic channels which drain the part; hence, the second stage of cancer is manifest by glandular involvement. Most of the lymphatics of the breast go to the *axillary glands* and these are usually the first to be involved.

The *subclavian glands* become involved by extension from the axillary glands or by the accessory subclavian trunk,

which comes directly from the posterior surface of the mammary gland.

The *retrosternal glands* are infected by way of the internal mammary lymphatics and mediastinal involvement follows. This infection is more frequent when the inner portion of the breast is involved.

Cross Infections.—Some of the cutaneous lymphatics at the sternal border cross from one side to the other; hence, infections in one breast may involve the other, or cancer of one breast may involve the axillary glands of the opposite side.

A block in the lymphatic circulation causing the lymph to flow in the opposite direction will cause unusual infections to occur in the head of the humerus, the retrosternal glands, etc.

When the nipple or areola is involved the entire gland becomes infected through the subareolar plexus.

The *sternal portion* of the *pectoralis major* becomes early involved. The clavicular portion is anatomically distinct and becomes involved only as a late manifestation of the disease. The *treatment of cancer of the breast* to be effective must depend upon the surgeon's appreciation of the regional anatomy. In carcinoma of the breast the mammary gland *per se* is but a fractional part of the tissue involved. *Remember that a cancerous breast is co-extensise with the lymphatics which drain it,* and upon this anatomic basis is founded the modern operation for the removal of mammary carcinoma. It includes a removal of the gland and integument, the sternal portion of the pectoralis major, division of the pectoralis minor (to facilitate the clearing of the great vessels), removal of the axillary glands and the vein if involved, together with the supra- and infraclavicular glands. It is not necessary to endeavor to save the pectoralis minor, since its retention adds nothing to the functional result.

Abscess of the breast is quite frequent because of its exposure to infection. The most common atria of infection are:

(*a*) The *lactiferous ducts*, ten or fifteen in number, terminating at the summit of the nipple.

(*b*) The "*tubercles of Montgomery,*" the sebaceous glands surrounding the nipple.

The majority of infections take place during lactation. The sucking infant produces a congestion of the parts, and unless they are kept scrupulously clean bacteria easily find their way into the lactiferous ducts or the sebaceous glands, and an inflammatory focus which results in an abscess of—

(*a*) The *areola*—usually circumscribed and showing no tendency to spread.

(*b*) A *lobe*—the process being confined between the septa.

(*c*) The *breast*—the septa being broken down and the process diffusing itself among a number of lobes.

(*d*) The *submammary connective tissue* becoming involved, the pus is likely to point at the anterior axillary fold.

Incisions of the breast should radiate from the nipple to avoid severing the lactiferous ducts.

The close relation of the mammary gland to the pectoralis major causes movements of this muscle to be communicated to the gland. Hence, in all inflammatory affections and after operations upon the gland, where rest to the part is desired, the arm should be bandaged to the chest.

The **thoracic cavity** may be divided into three irregular compartments. Two of these compartments are occupied, respectively, by the right and left lungs with their pleural investments. The remaining compartment, occupying a position between the two, is the mediastinal space; it lodges the remaining thoracic viscera.

The **diaphragm** is the musculo-aponeurotic partition which separates the chest from the abdomen. It forms the floor of the thoracic cavity and the roof of the abdomen. In respiration it helps to increase or diminish the cavity of the thorax. It is composed of three layers—a fibromuscular layer, covered above by the pleura and pericardium, and below by peritoneum. It forms an irregular dome, with the convexity above. It is about ¾ inch higher on the right side than on the left. On the right side it reaches to the level of the fifth chondrosternal articulation, on the left only to the sixth chondrosternal articulation, at the median line it forms a plateau on which rests the pericardium.

It is inserted along the interior of the whole circumference of the thoracic cage, and, above, it is attached to the pericardium.

Between the two fasciculi, attached to the base of the ensiform cartilage, is a space filled with connective tissue, which is continuous with the subperiosteal connective tissue. Through this channel inflammations of the thorax may be communicated to the abdomen or *vice versa*.

The **central tendon of the diaphragm** is a strong aponeurosis forming the center of the dome. It is situated immediately below the pericardium, with which structure it is partly blended.

It is composed of several layers of intersecting fibers which give it additional strength.

The **openings in the diaphragm** are three:

(*a*) The aortic opening, an osseo-aponeurotic notch in front of the twelfth dorsal vertebræ which transmits the aorta, the vena azygos major, and the thoracic duct.

(*b*) The *esophageal opening*, situated between the muscular fibers of the two crura. It transmits the esophagus and the pneumogastric nerve.

(*c*) The *vena cava opening*, situated between the right and middle leaflets of the tendon, transmits the vena cava and usually a branch from the right phrenic nerve. To the margins of the opening are attached the walls of the vein, which is thus kept open when the diaphragm contracts.

The **nerves** of the diaphragm are the phrenic, the lower intercostals, and the phrenic plexus of the sympathetic.

The diaphragm is the principal muscle of inspiration. When paralyzed, respiration is carried on almost entirely by the intercostals, and the abdominal viscera push upward against the relaxed thoracic floor, crowding the heart and preventing free circulation through the great vessels. In embarrassed respiration the patient breathes better in the sitting posture, since this position relieves the diaphragm of the pressure from the abdominal viscera.

Hiccup is a sharp inspiration due to irritation of the phrenic nerve causing an intermittent spasm of the diaphragm. It is also caused by distention of the stomach, pleurisy, pericarditis, or peritonitis.

Rupture of the diaphragm may occur as the result of great violence. The abdominal viscera, stomach, colon, etc., may then penetrate the thoracic cavity, but the lungs never pass into the abdomen in this injury.

Wounds of the diaphragm are very serious. They are the result of penetrating wounds of the chest and abdomen, and usually involve important viscera.

The **pleura** is a serous membrane forming a closed sac. It invests the lung as far as the root and is reflected on the inner surface of the thorax and the upper surface of the diaphragm (Fig. 109). The cavity of the pleura is in the interior of the sac. There is, however, no actual cavity normally existing between the parietal and visceral pleura. Such a cavity is potential and exists when the lung collapses and separates from the chest wall. The right and left pleura do not com-

municate. They are separated at the median line by the mediastinal space.

The **pleural sinus** is a triangular interval at the base of the pleural cavity, unoccupied by the lung. It separates the thoracic wall from the external and superior surface of the diaphragm (see Fig. 109). Through this interval the diaphragm may be penetrated without wounding the lung. Hernia of the omentum through a wound of the chest has followed such an injury.

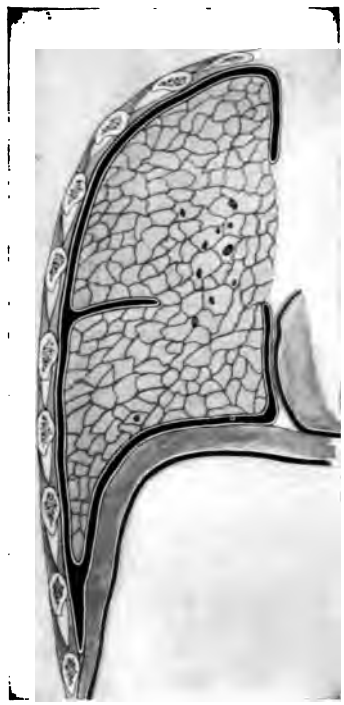

FIG. 109.—REFLECTIONS OF THE PLEURA INVESTING THE LUNG AND THORACIC CAVITY.

FIG. 110.—SHOWING THE LUNG COMPRESSED INTO SMALL SPACE BY A PLEURAL EFFUSION.

In operating upon the kidney through the lumbar incision the surgeon should not carry the incision too near the twelfth rib, or the pleura may be opened.

The pleura does not entirely cover the superior surface of the diaphragm, the central portion is intimately blended with the pericardium, at the border of which it is reflected above and forms the mediastinal pleura.

The *apex of the pleura* rises from 1 inch to 1½ inches above the first rib and the subclavian artery passes over it, forming a slight groove.

Pleurisy is an inflammation of the pleura which may be the result of an extension from the lung, as in pneumonia or tuberculosis, or it may be primary, as in rheumatism. When it is thus affected an exudate is thrown out which may fill up almost the whole of one side of the chest, obliterating the intercostal furrows, compressing the lungs, and displacing the heart (Fig. 110). This effusion is termed *hydrothorax*.

The presence of fluid in the chest gives a flat percussion note, which shifts with the position of the patient.

When the exudate thrown out is plastic in character, roughenings are produced on both the visceral and parietal pleura, which, rubbing against each other, give rise to a *friction sound;* hence the term dry pleurisy.

When the fluid in the chest is purulent it is called *pyothorax* or *empyema.*

Pus in the pleural cavity may discharge spontaneously through the lung, through the diaphragm and into the abdomen, into the pericardium, or externally, through the chest wall.

Thoracentesis is the process of puncturing the chest wall by means of an aspirator for the purpose of withdrawing the fluid. The point for inserting the needle is in the fifth interspace on the midaxillary line, which is on a level with the *angle of the scapula.* Note that the angle of the scapula is a safe guide on either side for puncturing the thorax without wounding the diaphragm. When the fluid is purulent it may be necessary to resect a rib for the purpose of securing efficient drainage.

Pneumothorax is an accumulation of air in the pleural cavity. It may be caused by a penetrating wound of the chest, by a perforation of the lung, and, according to Owen, a malignant ulceration of the esophagus may sometimes let air into the pleura. "The most dangerous form of pneumothorax is that associated with a valvular wound of the lung. The air is pumped into the pleural cavity with each inspiration and continues to accumulate within it; the lung, meanwhile, collapses and becomes compressed, and the heart is pushed over to the opposite side. Dyspnea becomes extreme and relief must be afforded by introducing a trocar through an intercostal space and allowing the cannula to remain *in situ*" (Taylor).

Neoplasms of the Pleura.—The pleura may be the site of endothelioma, carcinoma, sarcoma, or fibroma. The malignant forms are secondary to a growth in the lung.

Tumors of the pleura simulate pleural effusions and render diagnosis difficult.

The **lungs** occupy four-fifths of the thoracic cavity and are situated on each side of the mediastinum. "They are suspended by the root and hang free in the pleural cavity." The costal surface is convex and in relation with the ribs and intercostal spaces. It is this surface which is wounded in fractures of the ribs or penetrating wounds of the chest. The internal or mediastinal surface is concave, especially the left. On this surface is formed the *root of the lung*, a pedicle composed of the bronchi which lie behind, with the pulmonary artery in the middle, and the pulmonary veins in front. From above down the arrangement of the two sides differs; on the right side it is bronchus, pulmonary artery, pulmonary vein; on the left, pulmonary artery, bronchus, pulmonary veins. These structures are surrounded by an abundance of cellular tissue and lymphatics. They are bound together by the pleura, which envelops the pedicle and is reflected on to the mediastinal surface of the lung. The internal surface of the left lung is much more concave than the right lung because of the obliquity of the heart; hence, the left lung covers a great part of the pericardium, so that in wounds of the heart the anterior portion of the left lung is frequently involved and emphysema of the mediastinum follows.

The *apex of the lung* projects 1 or 1½ inches above the first rib, in a cul-de-sac of the pleura, which is grooved externally by the subclavian artery.

The *bases of the lungs* correspond to the diaphragm and are concave and much lower behind than in front. The base of the right lung is separated from the liver only by the thickness of the diaphragm; hence, an abscess or cyst of the liver may easily penetrate the diaphragm and open into the pleura or bronchi.

The landmarks for the lower border of the lung are: in the *nipple line*—the sixth rib.

In the *mid-axillary line*—the ninth rib.

In the *line of the lower angle of the scapula*—the tenth rib.

The *anterior borders* converge from the apices to the junction of the manubrium and gladiolus, where they are in immediate contact. From this point they diverge; the right descending almost vertically to the sixth chondrosternal joint, where it

turns outward to follow the line of the diaphragm; the left anterior border of the lung descends alongside the right as far as the fourth chondrosternal articulation, where it deviates outward in the direction of the apex of the heart. In the child the lungs are separated above and in front by the interposition of the thymus gland.

The *posterior border* of the lung is round, almost resembling a surface. It occupies the costovertebral groove and descends to the eleventh rib.

The lungs are characterized by their great elasticity, the air-cells themselves being particularly tenacious and difficult to rupture. Hence, they may be compressed within a very small space, or they are capable of great expansion. When the chest is opened the pressure of the outside air causes the lung to retract toward the vertebral column, though, rarely, the lung may protrude through a wound of the chest wall and prevent the air from entering the pleural cavity.

The blood supply of the lungs is from:

(*a*) The *pulmonary artery* and veins which carry the blood to and fro for purposes of oxygenation. These vessels accompany the bronchial tubes and terminate in a capillary network upon the walls of the air-cells.

(*b*) The *bronchial arteries*, which supply nutrition to the tissues of the lung, are branches of the thoracic aorta or the intercostals.

The **lymphatics** of the lung form a rich plexus beneath the pleura and about the lobules and bronchi. They accompany the blood-vessels and bronchi throughout the lung and empty into the bronchial glands at the root of the lung.

The **nerves** are from the sympathetic and pneumogastric, from which plexuses are formed, the filaments of which accompany the bronchial tubes.

Pulmonary Embolism.—The pulmonary arterioles are frequently blocked by clots dislodged from one of the systemic veins. The embolus is carried to the right heart and into the pulmonary artery, where it acts as a plug and blocks the circulation in the area supplied by the occluded vessel. The infarcted area is wedge-shaped, the apex being at the site of the embolus, the base at the surface of the lung. *The lung is the only organ in which the embolus can come from a systemic vein.* A pulmonary infarct may either undergo organization or end in abscess or gangrene, and is frequently associated with hemorrhagic pleurisy.

Emphysema of the lungs is a condition due to the presence of air in the interstices of the connective tissue, or to excessive dilatation of the air passages. In patients thus affected the chest is barrel shaped and although the expansion may be large they suffer from dyspnea.

Subcutaneous emphysema in the region of the lungs may be due: (1) to air from an emphysematous lung leaking into the connective tissue of the neck and spreading over the face and trunk. Such a condition has been noted in women during labor, the expulsive effort having produced rupture of the air-cells and subsequent infiltration of the tissues of the face and eyelids (Owen).

(2) The most common cause is a wound of the thoracic wall. This may be due to a penetrating wound involving the visceral pleura, in which case the air from the pneumothorax may be pressed into the subcutaneous tissues by respiratory movements, or the lung may be lacerated without an external wound, as in complicated fracture of the ribs, the air from the lung passing into the pleura and thence into the subcutaneous tissues, or there may be a nonpenetrating wound of the thorax in which air is sucked into the subcutaneous tissue by the movements of respiration alone. This condition may simulate at first a penetrating wound of the lung.

Wounds of the lung are characterized by hemoptysis (spitting of blood which has escaped into the bronchi), by hemothorax (blood escaping into the pleura), by pneumothorax, and emphysema. Superficial wounds of the lung, as a rule, cicatrize quickly and are not attended with serious consequences. They may, however, be followed by traumatic pneumonia. The gravity of the wound increases as it approaches the root of the lung.

In *gun-shot wounds of the lung* the Röntgen ray is an invaluable aid in localizing the bullet. No exploration should be attempted unless the location of the bullet is known. No removal of the bullet should be attempted unless it can be accomplished without serious injury to the viscus. Expectant treatment in bullet wounds of the lung has accomplished more than radical interference.

The lung has been successfully opened and drained for gangrene and abscess, and resection of a diseased portion has been performed.

The **mediastinum** is a space corresponding to the middle of the thoracic cavity, of which it occupies the fifth part. It is

bounded laterally by the mesial pleura of the lungs, in front by the sternum, behind by the vertebral column, and below by the diaphragm. Above it communicates directly with the neck. The middle of the mediastinal space is occupied by the heart and its pericardial investure.

While the subdivisions of this space are purely arbitrary, yet for purposes of description we may take the root of the lung as the line of demarcation and divide the mediastinum into two parts. The *anterior mediastinum* is the space between the sternum and the anterior surface of the root of the lung, and

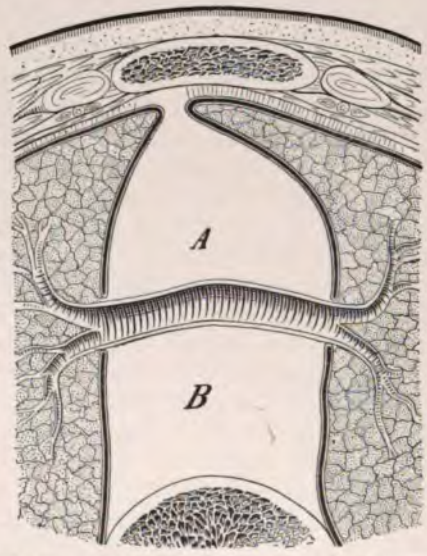

FIG. 111.—THE MEDIASTINUM DIVIDED BY THE ROOT OF THE LUNG INTO (*A*), ANTERIOR AND (*B*) POSTERIOR MEDIASTINUM.

the *posterior mediastinum*, the space between the posterior surface of the root of the lung and the vertebral column (Fig. 111). Except the heart and pericardium, the most important structures are found in the superior and posterior portions of the mediastinum. They are the trachea, the esophagus, the great vessels connected with the heart, the pneumogastric nerves, with the left recurrent laryngeal, the phrenic and cardiac nerves, the thymus gland or its remains, bronchial lymphatic glands, and the thoracic duct.

The **pericardium** is the serofibrous sac which invests the heart. It is the shape of a cone, its base below resting on

the central tendon of the diaphragm, its apex directed upward and surrounding the great vessels for about two inches above their cardiac origin. The fibrous character of the sac does not permit of sudden distention. In wounds of the heart death is due to the compression caused by the blood which fills the pericardial cavity. In pericardial effusions the distention is gradual and the pericardial cavity may contain from ½ pint to 3 pints.

The most important relation of the pericardium, from a surgical standpoint, is that which it bears to the anterior wall of the chest. It lies in a vertical direction behind the sternum,

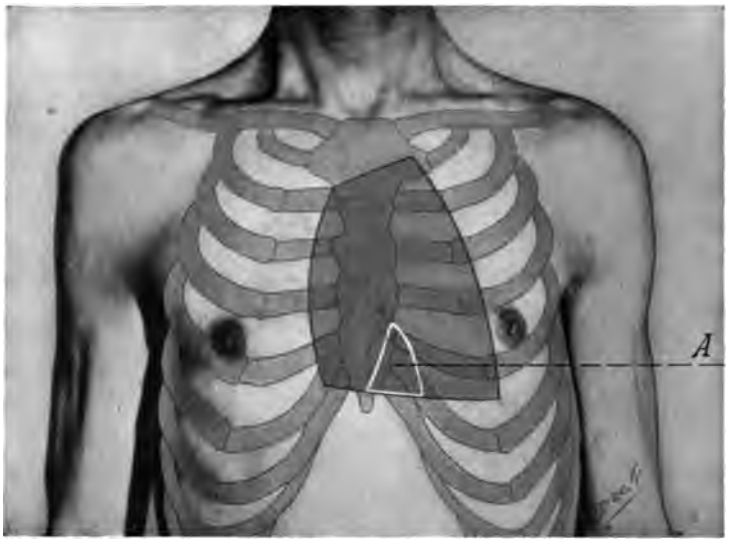

FIG. 112.—RELATIONS OF THE PERICARDIUM TO THE ANTERIOR CHEST WALL. *A*, Superficial cardiac triangle.

extending above from the second chondrosternal articulation on the right, to the first on the left. Below it corresponds to a line passing through the base of the ensiform cartilage and extending 2 cm. beyond the right border of the sternum and from 6 to 8 cm. beyond the left border. It will thus be seen that the pericardium has a very extensive relation to the anterior thoracic wall, but *the relation is not immediate, except* over *a very small area*. Over the greater part of the pericardium is interposed the anterior cul-de-sac of the pleura and the anterior borders of the right and left lungs; hence, wounds of

the heart are associated with injury to the pleural cavity and the lung.

The **superficial cardiac triangle** corresponds to that portion of the pericardium which is not separated from the chest wall by lung. It is found by drawing a base-line from the apex of the heart to the base of the ensiform cartilage. A second side is formed by a sternal line drawn from the level of the fourth cartilage to the base of the ensiform. The third side is formed by the anterior border of the left pleural cul-de-sac (Fig. 112). Although this triangle is small, it is of great surgical importance, since it represents the only directly accessible portion of the pericardium. In *paracentesis of the pericardium the aspirating needle should enter the fifth left space, hugging the border of the sternum.* It must be remembered that the internal mammary artery is situated only ½ inch from the border of the sternum. It is much safer to make an incision and use the needle only when the pericardial sac is reached.

In suppurative pericarditis the pericardium should be incised and the cavity irrigated. This may be done by resecting the fifth, sixth, and seventh cartilages on the left.

The **precardial region,** that portion of the chest wall which covers the anterior surface of the heart, is in the form of an irregular quadrilateral and may be traced upon the surface. The four angles of the quadrilateral are located, according to Testut, in the following simple manner:

(*a*) At the superior border of the third costal cartilage, 1 cm. to the right of the sternum.

(*b*) At the sternal articulation of the fifth right costal cartilage.

(*c*) At the apex beat, the superior border of the fifth left costal cartilage, midway between the nipple and the sternum.

(*d*) In the second left intercostal space, 2 cm. from the left border of the sternum (Fig. 113).

The Heart.—The **relation of the heart to the chest wall** is important both from a medical and surgical standpoint. Until recent years the heart was exclusively within the domain of the physician. Recent investigations have shown that it is not beyond the pale of surgery. In wounds of the heart, where prompt intervention has been afforded, suture of the wound has in many cases been successful and the patient's life saved.

The relations of the heart to the chest wall are nearly iden-

tical with those of the pericardium. It lies behind the sternum, two-thirds of its surface being to the left of the median line of the sternum and one-third to the right. It extends vertically from the upper border of the third rib to the upper border of the fifth.

The Situation of the Valves of the Heart.—The *pulmonary orifice* corresponds to the junction of the third left costal cartilage with the sternum (see Fig. 113).

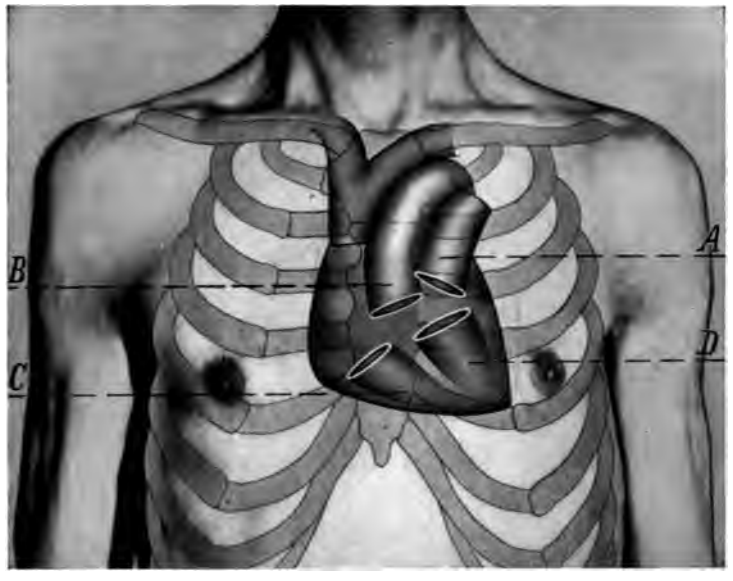

FIG. 113.—RELATIONS OF THE HEART TO THE CHEST WALL AND LOCATION OF THE VALVES.
A, Pulmonary valve; *B*, aortic valve; *C*, tricuspid valve; *D*, mitral valve.

The *aortic orifice* is situated a little below the preceding, behind the sternal end of the third left intercostal space (see Fig. 113).

The *tricuspid orifice* corresponds to the sternal end of the fourth right intercostal space (see Fig. 113).

The *mitral orifice* is situated above the preceding and to the left of the median line of the sternum at about the level of the third intercostal space (see Fig. 113).

Wounds of the Heart.—The portion of the heart in relation with the anterior wall of the chest is the right auricle and ventricle; hence, wounds in the third, fourth, and fifth spaces, to the right of the sternum, may injure the right auricle; in

the same region in the left, the right ventricle. Wounds of the auricle are more rapidly fatal than those of the ventricle, because of its thicker walls and its tendency to contract and prevent the escape of blood.

Likewise, wounds of the right ventricle are more serious than those of the left. Except the superficial cardiac triangle be penetrated, wounds of the heart involve the pleura and lung. Wounds of the heart are not necessarily fatal. The greatest danger arises from the accumulation of blood in the pericardium, which embarrasses the heart's action. Surgical intervention has proven efficacious and should be attempted in appropriate cases.

Exposure of the Heart in Cardiorrhaphy.—When suture of the heart is contemplated, a trap-door flap should be made, consisting of the entire thickness of the thoracic wall, the flap opening outward.

The hinge of the flap corresponds to the left anterior axillary line, the internal incision corresponds to the line of the left chondrosternal articulations, from the third to the fifth intercostal space. The left pleural cul-de-sac and lung are retracted externally, the pericardium incised, and the heart exposed.

The **aorta** arises from the base of the left ventricle and ascends to the second right chondrosternal junction, where it arches backward and to the left, over the root of the left lung, and descends on the left side of the vertebral column to the aortic opening in the diaphragm.

The **relations of the aorta** with surrounding structures are of prime importance in interpreting the pressure symptoms which follow in the wake of aneurysm.

The *ascending portion* has in *front* the posterior surface of the sternum, *behind* the root of the right lung, *to the right* the superior vena cava and the right auricle, *to the left* the pulmonary artery.

The *transverse aorta* has, in *front*, the pleura, the lungs, the remains of thymus gland, and the left pneumogastric, phrenic, and cardiac nerves. *Behind* is the trachea, esophagus, thoracic duct, and the left recurrent laryngeal nerve. *Above*, it gives off the innominate, the left carotid, and subclavian arteries. *Below* are the pulmonary artery, the ductus arteriosus, and the left recurrent laryngeal nerve.

The *descending portion* lies to the left of the fifth dorsal vertebra, in *front* is the root of the left lung, on the *right* the esophagus and thoracic duct, on the left the lung and pleura.

These relations explain the symptomatology of aneurysm of the aortic arch. The ascending portion is most frequently affected, probably because the outer side of the first part receives the full force of the cardiac impulse. When the aneurysm has attained sufficient size it may absorb the sternum and appear as a pulsating tumor on the anterior surface of the chest. Aneurysm of the aortic arch may project as a pulsating tumor above the suprasternal notch. It may press upon the veins at the root of the neck and cause venous engorgement, upon the recurrent laryngeal and produce of voice, by pressure on the trachea causing cough and dyspnea, or upon the esophagus, producing dysphagia. The phrenic nerve may be irritated and hiccup result. Pressure on the sympathetic will cause dilatation of the pupil on the affected side.

Aneurysm of the descending portion presses against the vertebra, causing absorption of the bone and a boring pain in the back. The pain may be referred to areas supplied by the intercostal nerves. It may be in immediate contact with the esophagus, trachea, left bronchus, pericardium, and pleura, and rupture into any one of them.

The **lymphatics of the mediastinum** play an important part in the pathology of this region. The glands of the mediastinum are very numerous, and, according to Delamere, may be divided into an anterior group (those in the anterior mediastinum), a middle group (the peritracheobronchial glands), and a posterior group (those in the posterior mediastinum).

Those in the anterior mediastinum lie in front of the pericardium, behind the sternum. They receive lymphatics from the anteromedian portion of the diaphragm and from the lower internal mammary glands.

The peritracheal and bronchial glands are placed between the divisions of the bronchi and about the bifurcation of the trachea. These glands are frequently enlarged because of the frequent infections to which they are exposed.

The posterior mediastinal glands are scattered about the esophagus.

The **thymus** is a gland of considerable importance in its bearing upon tumor formation. It is a vascular gland situated in the superior mediastinum. Like the thyroid and suprarenals, it secretes a substance which passes directly into the circulation, the nature of which we do not know.

It differs, however, from other glands in the fact that it is a transitory organ, pertaining especially to fetal and embryonic

life. It begins to atrophy at the age of two, and at the twenty-fifth to the thirtieth year we find but a vestige of it. The remains are represented by a fatty mass of tissue, with some particles of thymus tissue persisting, and in this is developed, undoubtedly, certain of the mediastinal tumors.

The lymphatics of the mediastinum are secondarily involved in cancer (breast, esophagus, etc.) or they may be infected and give rise to abscess.

Mediastinal Abscess.—The mediastinum contains an abundance of loose cellular tissue which communicates, above, with the cellular tissue of the neck, and below, through the aortic orifice of the diaphragm, with the abdomen. Thus, pus originating in any of these regions may burrow into the other. Abscess may be consecutive to a wound of the chest, fracture of a rib, or to disease of surrounding structures. Pericarditis is said to be a frequent cause.

Retropharyngeal and retro-esophageal abscesses may open into the posterior mediastinum. Abscesses originating in the vertebræ of the neck may follow along the vertebral column and point in the ischiorectal fossa.

Mediastinal Tumors.—Among the benign tumors are found hypertrophic thymus, endothoracic goiter, lipoma, fibroma, dermoid cysts, teratoma, lymphadenoma; sarcoma, endothelioma, and carcinoma represent the malignant varieties, the first being twice as frequent as the last.

The majority of primitive cancers develop from the thymus or its atrophic débris (Letulle).

If the arrangement of the structures within the mediastinal space be kept in mind, the general trend of the symptomatology is easily understood. These symptoms are referable to disturbances of respiration, circulation, or innervation.

The *diagnosis* of these tumors is always difficult; they are seldom diagnosed definitely. In the Röntgen ray we have an excellent means of verifying the percussion outlines.

Aneurysm never causes as many or as severe symptoms of pressure as a mediastinal tumor.

PART III

THE UPPER EXTREMITY

CHAPTER XIII

SURFACE ANATOMY

THE upper extremity is essentially the organ of prehension, touch, and defense. In former times when man had to fight for his food and his very life, the latter function was quite as important as the two preceding. With the advance of civilization the necessity for defense has diminished, so that now the two important functions of this member are prehension and touch. In the further study of its bones and joints, its range of movements, the arrangement of its vessels and muscles, will be seen the relation of structure to function and the evidence of its wonderful adaptability.

Surface Markings.—The *clavicle* can be palpated throughout its entire extent. Its outer extremity articulates with the *acromion process*, forming the bony summit of the shoulder. *The tip of the acromion forms a prominent point from which measurements of the upper extremity are made* (Fig. 114). When the arm is hanging with the palm forward it is in a line with the external condyle of the humerus and the styloid process of the radius. Starting from the acromion process, the spine of the scapula may be traced backward. Under the inner edge of the deltoid are the *two tuberosities of the humerus*. The greater tuberosity is the more prominent and is in a line with the external condyle. The lesser tuberosity is more anterior and more prominent, although smaller than the greater. Between the two lies the *bicipital groove*, lodging the long tendon of the biceps muscle. With the arm in the dependent position, and by making deep pressure in the axilla, the neck of the scapula and the edge of the glenoid cavity may sometimes be distinguished.

The **head of the humerus** may be recognized in its general outline by rotating the arm while the hand grasps the shoulder just below the acromion process. The articular surface lies in a line with the internal condyle.

FIG. 114.—LINE OF MEASUREMENT OF THE ARM FROM THE ANGLE OF THE ACROMION PROCESS TO THE EXTERNAL CONDYLE.

The **coracoid process** may be felt under the edge of the deltoid by making deep pressure beneath the clavicle in the interval between the deltoid and the pectoralis major. In well-developed subjects the triangular *deltoid muscle* forming the shoulder-cap can easily be defined (Fig. 115). The deltoid, with the head of the humerus, gives to the shoulder its rounded form. Hence, in dislocation of the humeral head, or in paralysis of the deltoid following injury to the circumflex nerve, the rounded form of the shoulder will be replaced by a depression. In the interval between the deltoid and the pectoralis major muscle lies the cephalic vein and the humero-thoracic artery.

The **subclavian fossa** is a depression beneath the outer half of the clavicle in which lie the axillary vessels. This fossa is obliterated in certain forward dislocations of the shoulder.

The Axilla.—With the arm held at an angle of 45°, the axillary space will be seen to resemble a pyramid, lying between the chest and the upper part of the arm (see Fig. 115). The apex points upward between the clavicle and the first rib, the base is formed by the integument and axillary fascia. In front it is bounded by the pectoralis major and minor; behind by the subscapularis, teres major, and latissimus dorsi; on the inner side by the four upper ribs, the intercostal, and serratus magnus muscles; the outer side by the upper part of the humerus and the coracobrachialis and biceps muscles.

The **coracobrachialis muscle,** when the arm is held at a right angle, may be distinctly felt passing down the inner side of the humerus.

The **course of the axillary artery** may be traced by abducting the arm, rotating it outward, and drawing a line from the center of the clavicle to the groove on the inner side of the biceps.

The **biceps muscle** is the muscular prominence on the anterior portion of the humerus. On each side of the muscle is a groove, the inner being the more marked. The *outer groove* contains the *cephalic vein*; the *inner groove*, the *basilic vein* and the brachial artrey. The **course of the brachial artery** corresponds to a line drawn from the center of the clavicle to the middle of the bend of the elbow, the arm being held at a right angle. The **triceps muscle** is at the back of the arm, and may be demonstrated by forcibly extending the forearm on the arm (Fig. 115).

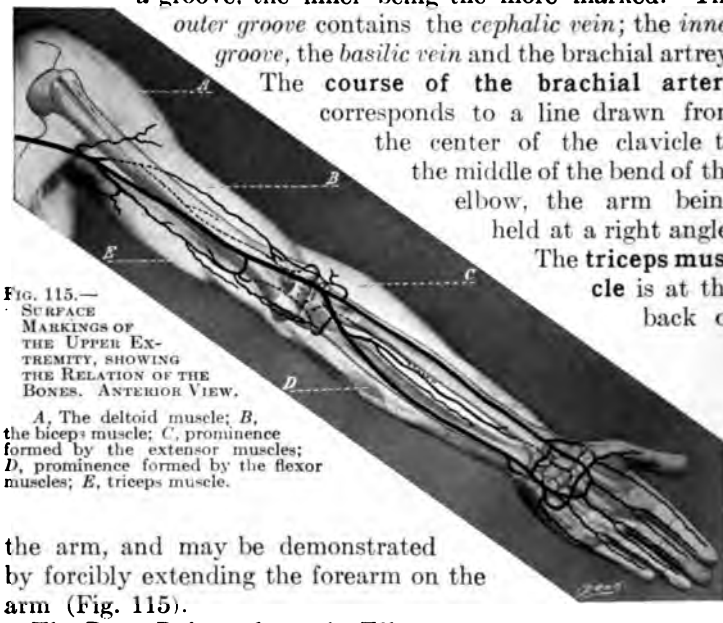

FIG. 115.—SURFACE MARKINGS OF THE UPPER EXTREMITY, SHOWING THE RELATION OF THE BONES. ANTERIOR VIEW.

A, The deltoid muscle; *B*, the biceps muscle; *C*, prominence formed by the extensor muscles; *D*, prominence formed by the flexor muscles; *E*, triceps muscle.

The Bony Points about the Elbow (Fig. 116).—The **internal condyle** is sharper, more prominent, and lower than the external, and lies just beneath the skin. Between the internal condyle and the olecranon is a depression which lodges the ulnar nerve.

The **external condyle** is more rounded and is placed higher than the internal. Just below the external condyle is a dimple in which can be felt the rounded head of the radius when the forearm is rotated.

The **olecranon process** can be felt distinctly in all positions of the joint.

The relation of the three bony points, the external and inter-

nal condyles, and the tip of the olecranon, are important landmarks in diagnosing injuries of the elbow-joint.

Relation of the Three Bony Points (Fig. 117).—If the thumb and middle fingers be placed on the internal and external condyles and the index finger on the tip of the olecranon, it will be found that these bony points change their relationship as the forearm is flexed or extended. When the forearm is fully extended the three bony points lie on the same transverse line. In semi-flexion the tip of the olecranon is below the condyles. In extreme flexion it lies in front of them. This relationship is extremely helpful in diagnosing fractures and dislocations about the elbow-joint.

Fig. 116.—Relations of the Bones of the Arm. Posterior View.

The **fold of the elbow** is well marked when the forearm is semiflexed; it does not correspond to the articulation, but is a little above it.

The Superficial Veins.—In a well-muscled arm, if the muscles be held in a state of tension, the superficial veins of the forearm will stand out so that their situation may be easily studied. It will be seen that the ulnar vein courses along the ulnar side of the forearm and the radial vein along the radial side. The median vein takes a median course between the two, and all receive various tributaries in their course. About 1½ inches below the bend of the elbow the median vein divides into two; the *median basilic*, which takes an inward direction to join the ulnar and form the *basilic vein* and the median *cephalic*, which takes an outward direction to join the radial and form the *cephalic vein*. These veins form, at the bend of the elbow, the letter M (Fig. 118). In front of the elbow is seen a depression, the *antecubital fossa*. It is bounded on the outer side by a muscular eminence composed of the extensor muscles, on the inner side by a similar eminence composed of the flexor muscles. At the center of the fossa may be felt the tendon of

the biceps, made more prominent by flexing the forearm. To the inner side of this tendon may be felt the pulsations of the brachial artery.

The **radius** can be palpated throughout its entire extent. Although it is covered by muscles to some extent below its head, yet if the muscles be made flaccid, the palpating finger can

FIG. 117.—RELATIONS OF THE THREE BONY POINTS OF THE ELBOW.

FIG. 118.—VEINS AT THE BEND OF THE ELBOW FORMING THE LETTER M.

distinctly feel the bone between the muscles. The lower two-thirds is subcutaneous.

The **ulna** is distinctly felt beneath the skin from the olecranon to the styloid process. The tip of the ulnar styloid process corresponds to the line of the wrist-joint. The tip of the radial styloid is below the line of the joint.

The **"anatomic snuff-box"** is the depression seen on the dorsum of the hand at the radial side when the thumb is extended. It forms a triangular hollow bounded on each side by the tendons of the extensor brevis and longus pollicis; its

base is formed by the styloid process of the radius. It contains the radial artery and vein.

The **radial artery** can be felt pulsating against the lower extremity of the radius where the pulse is usually observed.

The **ulnar artery** can be felt by relaxing and flexing the wrist and thrusting the finger under the tendon of the flexor carpi ulnaris.

The **tubercle of the scaphoid** may be felt on the radial side of the hand at the upper part of the muscles of the thumb.

The **pisiform bone** is palpable on the ulnar side of the hand at the upper extremity of the muscles of the little finger.

The distal ends of the metacarpal bones may all be palpated. The proximal ends are obscured by the muscles and tendons in which they are embedded.

The **knuckles** are in every instance formed by the head of the proximal bone of the articulation, but the *line of the joint is lower than the corresponding knuckle.*

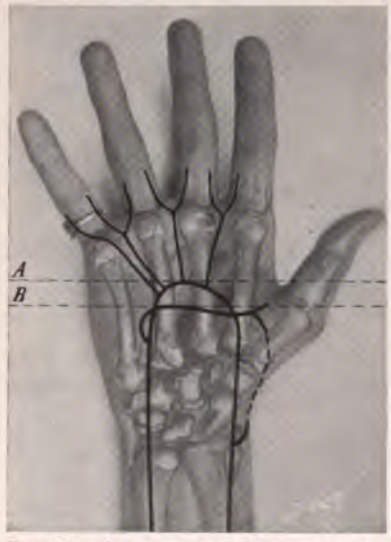

FIG. 119.—LINES OF (*A*) SUPERFICIAL AND (*B*) DEEP PALMAR ARCHES.

In the palm of the hand will be seen a triangular hollow, the apex pointing upward. It is bounded on either side by a muscular elevation belonging to the thumb and little finger. The one at the base of the thumb is the *thenar eminence* (the ball of the thumb), the one at the base of the little finger is the *hypothenar eminence* (the ball of the little finger). The apex of this triangle corresponds to the lower border of the anterior annular ligament. On the back of the hand are the venous arches from which originate the radial and posterior ulnar veins. The spaces between the metacarpal bones are filled by the dorsal interosseous muscles. When the ulnar nerve is paralyzed these muscles atrophy and a peculiar prominence of these bones follows.

The Palmar Folds.—By slightly flexing the fingers and adducting the thumb there appear in the palm three promi-

nent creases or folds. The first curves about the base of the thenar eminence and is produced by the apposition of the thumb. It starts at the wrist, between the thenar and hypothenar eminences, curves about the base of the former, and ends at the radial border of the hand at the base of the index finger.

The **radial transverse fold** starts where the first fold ends, runs transversely and slightly downward across the palm, and ends at the radial border of the hypothenar eminence.

The **ulnar transverse fold** starts at the ulnar border of the hand at the base of the little finger, runs transversely and slightly upward, and ends opposite the cleft between the index and middle fingers. When the hand is tightly flexed these two transverse folds merge and practically form one.

The **superficial palmar arch** is represented by a line drawn transversely across the hand from a point where the web of the thumb joins the palm (Fig. 119).

The **deep palmar arch** is about ½ inch nearer the wrist.

Across the front of the fingers are seen three transverse folds, the highest of which is placed about ¾ inch below the metacarpophalangeal joint; the middle folds are exactly opposite the first interphalangeal joint; the lowest folds are placed a little above (about 2 mm.) the second interphalangeal joint. On the thumb the two palmar creases are opposite the corresponding joints.

CHAPTER XIV

THE SHOULDER

In using the term *shoulder* it should be remembered that its meaning varies according as we consider it in an *anatomic* or *surgical* sense.

Surgically, the term shoulder alludes to the joint and the structures immediately surrounding it.

Anatomically, it alludes to a region where three bones meet (the scapula, clavicle, and head of humerus) to form the *root* of the upper extremity.

The **shoulder** is formed by the articulation between the *clavicle* and *acromion*, presenting a prominent bony arch.

The *shoulder-joint* is formed by the articulation between the head of the humerus and glenoid cavity. Roundness of the shoulder must not be confused with prominence of the bony arch.

Roundness of the shoulder is due to:

(1) Head of humerus and greater tuberosity.

(2) Superimposed deltoid muscle.

Hence roundness of the shoulder *is lost:*

(*a*) After exsection of the head of the humerus.

(*b*) In dislocation of the humeral head.

(*c*) Atrophy of deltoid muscle.

Clavicular Region.—The region immediately surrounding the clavicle.

The clavicle is a bone of great surgical interest because of its position in the bony architecture and the important structures to which it is related.

Salient Points.—(*a*) The first point of ossification to appear in the fetus is in the clavicle (at the thirtieth day of intra-uterine life).

(*b*) It is subcutaneous and can be palpated throughout its length.

(*c*) In shape it presents a double curvature (less in woman than in man). Seen from the front it is rounded and convex at the sternal half, and flattened and concave at the acromial half.

(*d*) It forms the only bony connection between the upper extremity and the trunk, and by acting as a buttress it prevents the shoulder from falling inward or approaching the trunk.

The clavicle articulates at its inner end with the sternum and cartilage of the first rib. The joint is arthroidal in character and allows of gliding motion.

Between the clavicle and sternum is interposed a disc of interarticular fibrocartilage which facilitates movements and serves to break the shocks which are transmitted by a fall on the hand.

The sternal end of the clavicle is firmly bound to the first rib by the costoclavicular or rhomboid ligament. Hence *dislocations* of the *sternal end of the clavicle are rare.*

The outer end of the clavicle articulates with the acromion process, the articular surface slanting obliquely from within outward. This joint is also arthroidal in character.

The acromial end of the clavicle is firmly bound to the coracoid process by the coracoclavicular ligament, which consists of two fasciculi (conoid and trapezoid). Hence *dislocation of this joint is also rare.*

Dislocations of the Clavicle.—While dislocations of the clavicle are rare because of the strong ligamentous attachments, yet violence transmitted in certain directions will produce them. The sternal end may be dislocated forward, backward, or upward.

In backward dislocation the bone may press upon the trachea and esophagus so as to produce dyspnea and dysphagia.

The acromial end is usually dislocated upward because of the oblique slant of the articular surface.

Reduction of these dislocations *is simple.*

Retention is always difficult and sometimes unsatisfactory. Retention of the acromial end may be facilitated by division of the clavicular portion of the trapezius close to its insertion and thus prevent the action of these fibers in pulling the end upward.

Although the clavicle is subcutaneous it lies in a muscular plane (Fig. 120). To the sternal half we have the sternomastoid attached above and the pectoralis major below. To the acromial half we have the trapezius above and the deltoid below.

In a groove on the under surface is inserted the subclavius muscle.

It will be seen that at the middle third there is a gap in the muscular plane (Fig. 120) the bone here lacking the support of the muscles. The bone at this point is also thinner. Hence, *the most common seat of fracture of the clavicle is in the middle third* (Fig. 121).

A proper appreciation of the action of the muscles attached to the clavicle explains the typical deformity following fracture.

Fracture of the clavicle is very frequent because of—

(*a*) Its exposed position.

(*b*) It is the only bony connection between the upper extremity and the trunk.

FIG. 120.—CLAVICLE IN ITS MUSCULAR PLANE.

FIG. 121.—FRACTURE OF CLAVICLE.

One-third of these fractures occur in children under five years and are usually of the green-stick variety.

A *typical deformity* follows complete fractures of the clavicle. The shoulder falls forward, downward, and inward. *Forward* because it is no longer held in place by the clavicle. *Downward* because of the weight of the arm and the action of the pectoralis minor and latissimus dorsi muscles. *Inward* because of the subclavius and trapezius muscles.

The sternal fragment may be drawn upward by the sternomastoid muscle.

Attitude of Patient.—The patient assumes the attitude of greatest comfort. The typical pose shows the head inclined

to the injured side to relax the pull of the sternomastoid. The elbow and forearm of the injured side is supported by the well hand to relieve the weight of the arm and relax the downward pull.

Complications.—The dangers attending fracture of the clavicle are: injuries to the subclavian artery, vein, or brachial plexus. These structures, though situated beneath the clavicle, are protected by the intervening subclavius muscle, which renders complications comparatively rare. If the vein or artery be torn blood gravitates to the axilla. Injury to the brachial plexus causes motor or sensory disturbance.

The vein is most liable to injury because of—

(*a*) Its closer relation to the bone.

(*b*) Thinness of its walls.

The Infraclavicular Fossa.—Immediately below the clavicle we note a depression which corresponds to the interval between the deltoid and pectoralis major at their clavicular origin. In its depths can be felt the coracoid process.

This fossa is obliterated in subcoracoid dislocations, fracture of the clavicle, and enlarged lymphatic glands following cancer of the breast.

The **subclavius muscle** is attached to a groove on the under surface of the clavicle, taking its origin by a thick tendon from the first rib and its cartilage, at their junction. Its function is to draw the clavicle downward and forward and act as a pad between the bone and the vessels beneath.

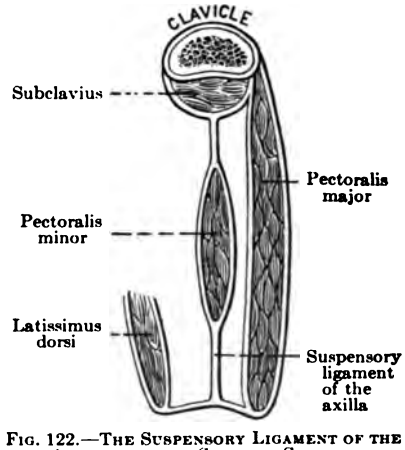

FIG. 122.—THE SUSPENSORY LIGAMENT OF THE AXILLA, SEEN IN SAGITTAL SECTION.

The **clavipectoral fascia,** attached to the clavicle, ensheaths the subclavius muscle and continues to the border of the pectoralis minor, where it splits and surrounds it. Continuing from its lower border it extends to the axillary fascia and forms the *suspensory ligament* of the axilla (Fig. 122). The upper portion of this fascia, surrounding the subclavius muscle and attached to the first rib, is known as the *costocoracoid*

membrane and is pierced by the cephalic vein, the acromio-thoracic artery, and the anterior thoracic nerve.

Beneath this fascia pus may find its way from the neck to the axilla.

Beneath the clavicle and separated from it by the subclavius muscle lie the subclavian artery and vein just at the point where they change their name to axillary. The artery is just beneath the center of the clavicle and the following relation obtains:

The Vein is internal and in front of the artery.

The Artery external to vein and a little posterior.

FIG. 123.—THE RELATION OF THE SUBCLAVIAN VESSELS AS THEY PASS BENEATH THE CLAVICLE.

The Nerves (cords of brachial plexus) are external to artery.

We, therefore, have, from within outward: vein, artery, nerve (*V-A-N*) (Fig. 123). It is in this fossa that the first portion of the axillary artery is ligated. The mistake has been made here of tying the nerve instead of the artery. This ought not to occur if we remember that the nerve is in immediate contact with the artery and in the same plane.

The cephalic vein is a guide to the axillary vein and should be preserved in operations for ligation of the artery at this point.

The axillary vein, being internal and occupying the angle between the clavicle and first rib, is subject to pressure from tumor, depressed fracture of the clavicle, and enlarged glands. *Edema of the extremity follows continued pressure.*

In addition to dislocations and fractures of the clavicle already mentioned *excision of the clavicle* is done for necrosis and neoplasms. If the excision can be done subperiosteally it is an operation of comparative ease and safety, and restoration of the bone may be expected. Where the clavicle has been entirely removed it is surprising to find how little the function of the shoulder has been impaired.

Where neoplasms of the clavicle have been followed by adhesions, excision is a formidable operation, the greatest danger being at the sternal end, behind which lie the innominate and left carotid arteries, the innominate and internal jugular veins, the pneumogastric, phrenic, and recurrent laryngeal nerves, and the thoracic duct.

There have been a number of cases of *avulsion of the upper extremity.* It is readily seen that after the clavicle is broken that the extremity is held to the trunk only by muscles and vessels and these can not withstand great violence.

The Scapular Region.—The structures in this region are naturally grouped about the scapula, which is imbedded in firm muscular and aponeurotic structures. It is held in position by the trapezius, levator anguli scapulæ, the rhomboidei, and serratus magnus muscles. The clavicular ligaments also assist. A few fibers of the latissimus dorsi cross its inferior angle, but are rather inconstant.

The scapula presents three fossæ lodging three muscles.

The **supraspinous fossa** lodges the supraspinatus muscle, which passes across the upper part of the capsular ligament, and its tendon is inserted into the highest point of the greater tuberosity.

Nerve.—The suprascapular.

Action.—It assists the deltoid in raising the arm from the side and is a *protection to the shoulder-joint.*

The **infraspinous fossa** lodges the infraspinatus muscle, which passes across the posterior portion of the capsular ligament. Its tendon is inserted into the middle portion of the greater tuberosity.

Nerve.—The suprascapular.

Action.—It rotates the head of the humerus outward. When the arm is raised it assists in retaining it in that position and is a *protection to the shoulder-joint.*

The **teres minor,** which may be considered a divorced partner of the infraspinatus, arises from the dorsal surface of the axillary border (upper two-thirds), crosses the posterior portion of the capsular ligament, and its tendon is inserted into the lowest part of the greater tuberosity.

Nerve.—The circumflex.

Action.—It rotates the head of the humerus outward. When the arm is raised it assists in retaining it in that position, carrying it backward; it is a *protection to the shoulder-joint.*

The **subscapular fossa** lodges the subscapular muscle, whose fibers gradually converge and form a tendon which is in close contact with the anterior portion of the capsular ligament of the joint. This tendon passes over a large bursa (the *subscapularis bursa*) connected with the joint cavity, and is inserted into the lesser tuberosity of the humerus.

Nerves.—The upper and lower subscapular nerves.

Action.—It rotates the head of the humerus inward. When the arm is raised it draws the humerus downward and forward and is a *protection to the shoulder-joint.*

These muscles are covered by a strong aponeurosis and are practically lodged in osseous aponeurotic compartments, so that pus or blood must follow the tendons of insertion and finally settle beneath the deltoid.

The protection which these muscles afford the articulation will be discussed in connection with the shoulder-joint.

In studying the arrangement of the muscles on the posterior surface of the scapula it will be seen that the teres minor and teres major muscles, in passing from the scapula to their attachments to the humerus, form a triangular space which is bisected

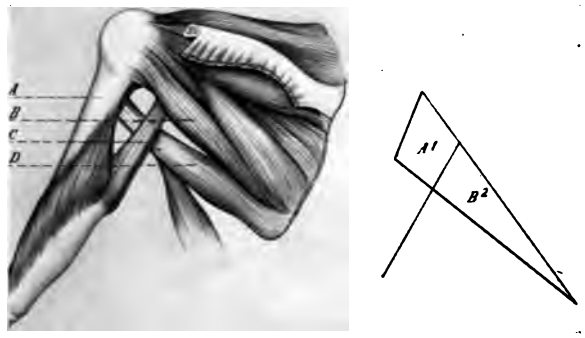

FIG. 124.—MUSCLES ON THE DORSUM OF THE SCAPULA AND TRICEPS FORMING (A^1) THE QUADRILATERAL AND (B^2) THE TRIANGULAR SPACES.
A, Humerus; *B*, teres minor; *C*, long head of triceps; *D*, teres major.

by the long head of the triceps, forming a quadrilateral and a triangular space of some topographic importance (Fig. 124).

The **quadrangular space** is formed by the teres minor above, the teres major below, the long head of the triceps internally, and the humerus externally. This space transmits the circumflex nerve and the posterior circumflex artery before entering the deltoid muscle.

The **triangular space** is formed by the teres minor, the teres major, and the long head of the triceps. It transmits the dorsalis scapulæ artery, which anastomoses with the suprascapular artery and establishes a collateral circulation after ligature of the axillary artery.

So-called luxation of the scapula is a projecting backward of its inferior angle, producing a deformity known as "*winged scapula,*" formerly described as due to the slipping out of the

angle of the scapula from under the fibers of the latissimus which cross it. The latissimus, however, has no retentive function on the angle of the scapula. The deformity is caused by a paralysis of the long thoracic nerve supplying the serratus magnus, a part of which holds the inferior angle against the chest. This deformity is brought about by certain exercises where there is an over-stretching of the serratus muscle. Rest and electricity to the long thoracic nerve usually effect a cure.

Fractures of the scapula are comparatively rare (Stimson estimates about 1 per cent.). They usually follow great violence. They are rare because of two anatomic facts:

(*a*) The bone is freely movable.

(*b*) It is imbedded in muscles.

Fracture of the body is detected with great difficulty and the displacement is slight, because of the thick overlying muscles.

Fracture of the spine is easily recognized because of its subcutaneous position.

Fracture of the acromion is one of the most common in this group, because—

(*a*) Its position exposes it to direct blows.

(*b*) It may be indirectly injured by the head of the humerus through a fall upon the elbow. Bony union after this fracture is the exception. Fibrous union usually results because the fragments are not closely coapted and because of the interposition of aponeurotic tissue.

It must be remembered that the acromial epiphysis does not ossify before the twentieth year. This fact may lead to errors of diagnosis in young subjects.

Fracture of the anatomic neck is so rare that, according to Stimson, no known example of this fracture exists. While its possibility must be conceded, we must, because of their symptomatology, include in this classification fractures which begin at the suprascapular notch and extend to the axillary border of the scapula, following a line parallel with the surface of the glenoid cavity (the *surgical neck*). Such fractures would include the coracoid process and the attachment of the triceps in the fragment (Fig. 125). The main interest in this fracture is the fact that it simulates subglenoid dislocation of the humerus.

RULE.—*This fracture and subglenoid dislocation are the only injuries in which the arm is lengthened.*

A diagnosis is easily made by noting the ease with which reposition of the fragment is made by lifting the elbow, and the

immediate displacement which follows when the support to the elbow is withdrawn. Crepitus will be elicited in these movements.

Fracture of the coracoid process is not common. It is well to remember that the coracoid process is not completely ossified to the body of the scapula until puberty. It is caused by direct or indirect violence and muscular action.

FIG. 125.—FRACTURE OF THE SURGICAL NECK OF THE SCAPULA.

The coracoid process being well protected, it is rarely fractured by direct violence unless in crushing injuries.

In dislocation of the humeral head the coracoid may be fractured by upward pressure.

As an instance of the effect of muscular action may be cited the case of fracture of this process reported as following the wringing of wet clothes. In the treatment of this fracture it is important to bear in mind that to this process are attached three muscles (the pectoralis minor, coracobrachialis, and short head of biceps). To retain the fragment in position the forearm should be flexed to slacken the biceps and the arm drawn to the chest to relax the pectoralis minor and coracobrachialis, this position being retained until union is firm.

The **suprascapular notch** is a semicircular notch situated on the superior border of the scapula just at the base of the coracoid process. It is frequently converted into a foramen by the transverse ligament or a lamella of bone. *This foramen transmits the suprascapular nerve.* The suprascapular artery passes above the ligament.

The **arteries of the scapular region** form an anastomotic circle between the subclavian and the axillary, and thus permit a re-establishment of the circulation after ligation of the subclavian (Fig. 126). The *posterior scapular* artery, a branch of the transversalis colli, runs along the vertebral border to

the inferior angle and anastomoses with the dorsalis scapulæ and the subscapular.

The *suprascapular*, from the thyroid axis, sends a branch to the supraspinous fossa, then winds around the neck of the scapula and enters the infraspinous fossa to anastomose with the dorsalis scapulæ.

The *subscapular*, the largest branch of the axillary, passes downward to the inferior angle of the scapula and anastomoses with the posterior scapular. About 1½ inches from its origin it gives off the dorsalis scapulæ which curves around the axillary border of the scapula, passes through the triangular space bounded by the teres minor, teres major, and long head of the triceps, and, entering the infraspinous fossa, anastomoses with the posterior scapular and suprascapular arteries.

FIG. 126.—ANASTOMOSIS OF THE ARTERIES ABOUT THE SCAPULA. (After Deaver.)

The **supra-acromial bursa** above the acromial process is a bursa which sometimes enlarges and becomes inflamed in those who carry heavy burdens upon the shoulder.

Lymphatics.—The lymphatics of the shoulder empty into the glands of the neck and axilla.

Tumors.—The scapula is the seat of benign and malignant growths. The benign tumors manifest themselves in the form of myxochondroma and cystic enchondromas.

The malignant type is sarcoma.

The scapula has been resected with success.

In malignant disease of the scapula it is necessary to remove the entire upper extremity with the scapula, performing an *interscapulothoracic amputation*. The important precaution in this formidable procedure is hemostasis.

The Scapulohumeral Region.—The central structure of this region is the shoulder-joint, or articulation of the head of the humerus with the glenoid cavity. Contiguous to it is the

capsular ligament, the coracobrachialis muscle, and the tendons of the biceps, triceps, and the deltoid muscle.

The **deltoid muscle** is triangular in shape, covers the shoulder-joint, and partly forms the rounded prominence of the shoulder. It takes its origin from the outer third of the anterior and upper surface of the clavicle, the outer border of the acromion, and the lower border of the spine of the scapula. The fibers converge toward their insertion and form a tendon which is inserted into the deltoid eminence of the humerus.

Action.—It raises the arm so as to bring it at right angles to the trunk.

Its clavicular fibers assist the pectoralis major in drawing the arm forward. Its scapular fibers act with the teres major and latissimus dorsi in drawing it backward.

Nerve.—It is supplied by the circumflex nerve.

The deltoid is the only abductor muscle of the arm and the circumflex nerve is its only means of innervation; hence, paralysis of the deltoid is a very serious accident.

Atrophy of the deltoid is caused—

(*a*) By disuse, ankylosis of shoulder-joint, etc.

(*b*) Ascending neuritis of the circumflex nerve.

(*c*) Injury to circumflex nerve following fracture or dislocation of the humerus.

Following atrophy of the deltoid there is a noticeable flattening and a corresponding prominence of the acromion process. This condition simulates a flattening of the shoulder in dislocation. These two conditions will not be mistaken if we remember that in atrophy of the deltoid the mobility and the position of the head of the humerus and tuberosities are normal.

The Subdeltoid Bursa.—Beneath the deltoid muscle is situated a large bursa which, when inflamed, may simulate effusion into the joint cavity.

The *long tendon of the biceps* muscle, arising from the upper margin of the glenoid cavity, arches over the head of the humerus, enclosed in a sheath of synovial membrane of the shoulder-joint, and, passing through an opening in the capsular ligament, descends in the bicipital groove between the greater and lesser tuberosities.

The **shoulder-joint is enarthroidal,** or ball-and-socket in character, allows of a wide range of motion, and is formed by the large, round head of the humerus articulating with the small, shallow glenoid cavity of the scapula.

The **glenoid cavity** of the scapula is in the form of an oval and receives three heads (Fig. 127):

(1) Middle—bony head of humerus.
(2) Above—long head of biceps.
(3) Below—long head of triceps.

The articulation is surrounded by the loose *capsular ligament* attached to the rim of the glenoid cavity and the anatomic neck of the humerus.

The glenoid cavity is further deepened by a fibrocartilaginous rim attached to the circumference of the cavity and lined by synovial membrane.

FIG. 127.—THE GLENOID CAVITY, THE MEETING PLACE OF THREE HEADS.
A, Bony head of humerus; *B*, long head of biceps; *C*, long head of triceps.

The synovial membrane lining the joint cavity and reflected upon the articular surfaces of the bones sends a tubular sheath to line the bicipital groove for purposes of lubrication, so that while the tendon of the biceps traverses the joint it is not within the synovial cavity.

The synovial sac communicates with the bursa beneath the subscapularis and sometimes with the subdeltoid bursa.

If we note the disproportion between the large articular head of the humerus and the small cavity of the glenoid, and the remarkable laxity of the capsular ligament it is seen that there is no adequate protection from dislocations of the humeral head save from the reinforcement which it receives from the surrounding muscular tendons (the *shoulder-strap muscles*).

The integrity of this joint depends for its support upon the muscles which surround it.

Lying in close contact with the capsule are, above, the supraspinatus, the infraspinatus, and teres minor, and, within, the long tendon of the biceps.

The arteries supplying the joint are branches of the anterior and posterior circumflex and the suprascapular.

The nerves are derived from the circumflex and the suprascapular. (Note in this connection *Hilton's law*, viz.: The nerve supplying a joint supplies the muscle moving the joint and the skin over the muscle.)

In *synovitis of the shoulder-joint* with effusion the capsule is distended and is best *detected in the axilla,* where a fluctuating swelling can be felt.

The serous cavities which surround the joint are frequent sources of error in diagnosis and the locations of the supra-acromial, subdeltoid, subscapular, and bicipital bursa must be kept in mind in differentiating effusions in this region.

Pus in the joint finds its easiest outlet along the bicipital groove where it may present beneath the anterior or posterior border of the deltoid muscle.

Dislocations of the shoulder are very frequent, as frequent as all others combined. The reasons for this are obvious.

(*a*) The freedom of movement which obtains in this joint.

(*b*) It is a joint which depends for its strength upon the surrounding muscles; hence, if these muscles are relaxed and force is suddenly applied to the shoulder, the head of the humerus can easily break through the thin capsule and slip out of the glenoid cavity.

(*c*) The disproportion between the size of the articular head of the humerus and the shallow glenoid cavity.

(*d*) The laxity of the capsular ligament, its weakness on the anterior side, especially between the tendon of the subscapularis and the triceps.

If the structures surrounding the joint be carefully considered, the frequency and variety of dislocation are easily understood and a rational basis for classification attained. The coracoid and acromion processes, with their connecting coraco-acromial ligament, form a perfect arch above the shoulder. This, with the strap-like tendon of the supraspinatus over the superior portion of the capsule, makes upward dislocation well nigh an impossibility. The strap-like tendons of the infraspinatus and teres minor passing over the posterior portion of the capsule strengthen and support it and posterior dislocations are, therefore, rare. A direct downward dislocation is hardly possible when we consider that the axillary border of the scapula extends up to the lower border of the glenoid cavity and the dislocated head must rest either anterior or posterior to this

border. The least protected and weakest part of the capsule is the anterior portion; it has but one strap-like tendon, the subscapularis, protecting it in front, and between the subscapularis tendon and the triceps there is an unprotected portion through which the humeral head can easily slip.

Classification of Shoulder Dislocations.—If we extend a vertical line through the glenoid cavity from a point where the axillary border of the scapula joins it, we divide the glenoid cavity into two unequal portions (Fig. 128). Three-fifths of the articular surface is anterior and two-fifths posterior.

We can likewise divide all dislocations of the shoulder into anterior or posterior. It is evident that the variety of dislocation will depend upon the distance of the excursion which the head of the bone makes in its departure from the glenoid cavity, and we again find that the head of the bone may assume three anterior positions and two posterior.

The anterior dislocations are, therefore—

(1) Subglenoid—low anterior.
(2) Subcoracoid—middle anterior.
(3) Subclavicular—high anterior.

The posterior dislocations are—

(1) Subacromial—middle posterior.
(2) Subspinous—high posterior.

FIG. 128.—VERTICAL LINE EXTENDING THROUGH THE GLENOID CAVITY DIVIDING IT INTO AN ANTERIOR THREE-FIFTHS AND A POSTERIOR TWO-FIFTHS.

Characteristic Features of all Shoulder Dislocations.—(*a*) *Flattening.*—The roundness of the shoulder is very largely due to the presence of the humeral head in its normal position beneath the superimposed deltoid; hence, when the head leaves the glenoid cavity flattening ensues. This condition is undoubtedly increased by the stretching of the fibers of the deltoid muscle which follows luxations of the head.

(*b*) *Abduction of the Arm.*—When the head leaves the glenoid cavity it rests at some fixed point, and this point being the fulcrum, the tense deltoid moves the elbow away from the body; hence the characteristic feature of abduction.

(*c*) *In a normal condition of the joint the fingers can be placed upon the opposite shoulder and the elbow of the same side touch*

the thorax (Dugas). In a dislocation of the shoulder this is impossible and—"No other injury but a dislocation can produce this physical impossibility." This is explained by the fact that the thorax represents a curved line and the humerus a straight line. It is impossible for both ends of a straight line to touch the convexity of a curved line at the same time.

(*d*) The head of the bone will be found as a swelling in the location to which it has been displaced.

FIG. 129.—SUBGLENOID DISLOCATION OF THE SHOULDER.

(*e*) In all anterior dislocations the elbow is carried away from the body because of the tension of the deltoid.

In all posterior dislocations the elbow is carried forward and to the side of the body because of the action of the pectoralis major and coracobrachialis.

(*f*) Normally, a line drawn from the angle of the acromion to the epicondyle of the humerus passes through the greater tuberosity of the humerus. This relation is destroyed in dislocations of the shoulder and is a valuable guide in diagnosis.

Subglenoid Dislocations (Fig. 129).—In this variety the head of the humerus has made its escape through the anterior and lower part of the capsular ligament, usually between the tendon of the subscapularis and the triceps. The head is not directly under the glenoid rim, as the name suggests, because this position is an anatomic impossibility (see pages 251 and 252).

It rests at the lower anterior margin of the glenoid. The head can be felt in the axilla. The superior part of the capsule

is tightly stretched across the glenoid cavity and the tendon of the long head of the biceps may be torn.

The muscles attached to the tuberosities of the humerus are on a stretch or may be torn; thus the supraspinatus, the infraspinatus, and the subscapularis are in a state of tension. The deltoid is in a state of extreme tension and with the head of the humerus resting against the lower rim of the glenoid draws the elbow away from the body.

FIG. 130.—SUBCORACOID DISLOCATION OF THE SHOULDER.

Rotundity of the shoulder is lost and flatness is present. Since the head is displaced the acromion process becomes unduly prominent.

The circumflex nerve is liable to be injured and produce paralysis of the deltoid.

The axillary vein or artery may be injured and the brachial plexus may be stretched and cause a partial paralysis of the upper extremity.

This variety of dislocation and fracture of the surgical neck of the scapula are the only injuries about the shoulder in which the arm is lengthened.

Subcoracoid Dislocation (Fig. 130).—In the subcoracoid variety the head rests in the middle anterior position. The head escapes through the anterior part of the capsule and is lodged at the anterior surface of the neck of the scapula and beneath the conjoined tendon of the coracobrachialis, and the

FIG. 131.—SUBCLAVICULAR DISLOCATION OF SHOULDER.

short head of the biceps attached to the beak of the coracoid process. This is the *most frequent of all dislocations of the shoulder*. The flattening is not so marked nor the abduction so pronounced as in the former variety. The tension of the deltoid muscle is not so extreme.

Subclavicular Dislocation (Fig. 131).—The subclavicular position of the head represents the extreme excursion which it can make in anterior luxation. The head escapes through

a rent in the anterior part of the capsule and rests below the clavicle and against the chest beneath the pectoralis major and minor muscles.

With the head in this position the muscles about the joint must be either in extreme tension or torn. This will apply to

FIG. 132.—SUBACROMIAL DISLOCATION OF THE SHOULDER.

the deltoid, the subscapularis, the infraspinatus, and supraspinatus. The vessels and nerves of the axilla are carried forward with the head of the humerus and the stretching of the tissues, especially the nerves, causes extreme pain to accompany this dislocation.

The circumflex nerve is very likely to suffer injury and the long tendon of the biceps is often torn.

Subacromial Dislocation (Fig. 132).—The head escapes through a rent in the posterior and lower part of the capsule and rests under the posterior angle of the acromion. The tendon of the subscapularis is stretched across the surface of the glenoid fossa and sometimes torn. The supraspinatus is stretched or torn. The infraspinatus is relaxed.

FIG. 133.—SUBSPINOUS DISLOCATION OF THE SHOULDER.

Subspinous Dislocation (Fig. 133).—Here the excursion of the head from the glenoid cavity in a posterior direction is greater than the above. The head rests below the spine of the scapula and beneath the infraspinatus muscle. The shoulder-strap muscles are displaced in the same manner as in subacromial displacements, but the stretching and tearing is greater because of the greater distance the head of the bone has traveled from its normal position.

Anatomic Considerations in the Reduction of Shoulder Dislocations.—In general it is well to remember that *the cure of a dislocation is its reduction,* and that the reduction should be immediate, irrespective of pain, swelling, or inflammation. "Early reduction lessens subsequent disability." Furthermore, the fundamental principle in the reduction of a dislocation is: *the bone should be returned along the path by which it made its exit.*

In reducing shoulder dislocations keep in mind the arteries, veins, and nerves in this region, and avoid injury to them. If the artery be atheromatous the danger of rupture is greater. The axillary vein is most commonly injured and gangrene of the arm has followed this accident.

Obstacles to Reduction.—Chief among these are:

(*a*) The *tension of the untorn portion of the capsule,* preventing the head from approaching the socket.

(*b*) The *interposition of portions of the capsule,* the biceps tendon, and, less frequently, the tendon of the subscapularis muscle.

(*c*) The *shoulder-strap muscles* form a barrier to reduction by their rigid contraction; hence, the value of an anesthetic in overcoming this rigidity.

Anesthesia in Reducing Shoulder Dislocations.—Beside the evident value of anesthesia in facilitating reduction there is a good anatomic reason for choosing ether rather than chloroform. A number of deaths have followed the use of chloroform in reducing shoulder dislocations; with peculiar regularity they have occurred just as the head of the bone is replaced in its socket; in other words, co-incident with the reduction there occurred cardiac shock which resulted fatally.

The anatomic explanation of this phenomenon is the fact that the seventh and eighth cervical nerves, which enter into the formation of the cord supplying the shoulder-joint, also send filaments to the inferior cervical ganglion, which gives off the inferior cardiac nerve. The shock sent along the nerve tracks by the head of the bone suddenly regaining its socket depresses the heart to the point of danger when it is already under the depressing influence of chloroform. Ether, being a heart stimulant, counteracts the depressing effect which invariably follows reposition of the humeral head.

Ether, therefore, is the anesthetic of choice in the reduction of shoulder dislocations.

Methods of Reduction.—These may be considered under two heads:

(*a*) Traction and (*b*) manipulation.

In all methods of traction fixation of the scapula is essential. This may be obtained by the manipulation of an assistant; passing the arm through a canvas band, or pressure of the surgeon's hand or foot. The method of using the heel in the axilla is to be condemned, since it has caused serious injuries to the vessels and nerves of the axilla. One of the simplest and most effectual methods of traction is that devised by Stimson. The patient lies on his side on a canvas cot, the injured limb passing through a hole cut in the canvas. With the limb hanging vertically downward a weight of ten pounds is attached to the wrist and swings free of the floor. The author states that in a few minutes the dislocation is reduced quietly and without pain.

There have been many methods of manipulation devised. That advocated by Kocher is the best and most rational. A résumé of the author's description is as follows:

Position.—The surgeon faces the patient with one hand on the elbow and the other hand on the wrist; the elbow is flexed to a right angle and pressed against the patient's side.

First Movement.—The wrist is moved steadily outward until the resistance becomes considerable (extreme external rotation).

Second Movement.—Maintaining the arm in this position (external rotation and flexion at the elbow) the elbow is moved forward and inward until the arm is nearly horizontal.

Third Movement.—The arm is rotated inward and the hand brought to the opposite shoulder.

The bone may slip in place during the second movement. This method is applicable in anterior dislocations and especially effective in subcoracoid positions. Its author claims that it is not only successful in recent dislocations, but in those of three or four months' standing.

The Anatomic Basis of Kocher's Method.—In *anterior dislocations* we find three pathologic factors:

(*a*) A rent in the anterior part of the capsule.

(*b*) The posterior part of the capsule untorn.

(*c*) The posterior scapular muscles untorn and stretched across the glenoid fossa.

Reasons for the First Movement.—By external rotation you relieve the tension of the posterior scapular muscles and the rent in the capsule is opened.

Second Movement.—Causes relaxation of the tense but untorn

portion of the capsule, and the head of the humerus enters its socket.

Third Movement.—Brings the head of the humerus in contact with the glenoid fossa.

This method depends for its success upon the untorn portion of the capsule and will fail if the capsule be extensively torn.

Fracture of the Anatomic Neck of the Humerus (Fig. 134).—This must necessarily be a rare fracture when we consider the strength of the bone at this point. It occurs in elderly people in whom the bone is brittle. The break is

FIG. 134.—FRACTURE OF THE ANATOMIC NECK OF THE HUMERUS.

FIG. 135.—DIRECTION OF THE LINES OF LESION IN THE UPPER END OF THE HUMERUS.

A, *B*, Line of anatomic neck; *A*, *C*, *D*, line of upper epiphysis; *E*, *F*, line of surgical neck.

within the capsule. Sometimes there is an impacted condition, the head being driven into the lower fragment. The deformity is slight. The fracture is an obscure one and may be associated with anterior dislocation of the shoulder.

Separation of the Upper Epiphysis.—Since ossification of the epiphysis with the shaft takes place at the twentieth year, this lesion can take place only during the period prior to the time of ossification. Stimson attributes this injury to cross strain in forcibly carrying the limb beyond the normal limits of motion.

The upper epiphysis includes the head and tuberosities and is represented by a line which begins on the inner side of the head of the bone and runs transversely across, with a slight elevation in the center (Fig. 135).

In a separation the epiphysis becomes "unglued" from the shaft. The displacement is characteristic. The head of the bone is in place, but rotated outward by the action of the muscles attached to the greater tuberosity. The shaft is drawn forward and inward by the muscles attached to the bicipital groove. The upper end of the shaft can be felt at the front of the shoulder and is sometimes seen beneath the skin. This gives rise to an abrupt projection at the front of the joint a short distance below the coracoid process (Gray). When the arm is rotated crepitus is felt, but it is of a soft, cartilaginous character. The periosteum is not entirely torn across. Portions of it may fall between the fragments and prevent complete reduction. This injury sometimes brings about a premature ossification, and as the growth of the humerus in length is chiefly through the upper epiphysis, arrest of growth may follow.

Fracture of the Surgical Neck.—The surgical neck is the slender part of the humerus below the tuberosities and above the insertion of the pectoralis major. A fracture occurring within these limits may be considered a fracture of the surgical neck. The term surgical neck has been applied to this portion of the humerus because of the frequency of fracture in this region. *It is the most common fracture of the upper part of the humerus.* In Fig. 136 note the rôle which the muscles play in this fracture, and the displacement is readily understood.

The lower fragment is drawn *upward* by the biceps, triceps, deltoid, and coracobrachialis; *inward* by the pectoralis major, teres major, and latissimus dorsi.

This fracture resembles an anterior dislocation of the shoulder. The presence of the head in the glenoid cavity, the failure of the head to move when the elbow is rotated, and the false point of motion are differential points in diagnosing this condition.

The anatomic factors in this fracture suggest important points in the treatment. They are:

(*a*) The use of extreme abduction in reducing the fracture. The lower fragment may be drawn upward to such an extent that traction and extreme abduction may be necessary to coapt the two fragments.

(*b*) A well-fitting pad in the axilla to prevent the lower fragment from inward displacement.

(*c*) No inside splint is necessary. Its uselessness is obvious, since the fracture is high in the axilla above the upper margin of an inside splint.

(*d*) Never support the elbow by splint. Remember the tendency of the lower fragment to ride upward. Any support to the elbow increases this tendency. Where the overlapping is marked it may be necessary to suspend a weight from the elbow to counteract it.

FIG. 136.—FRACTURE OF THE SURGICAL NECK OF THE HUMERUS.

In considering these fractures near the shoulder-joint as a group, we should remember that—

Fracture of the anatomic neck occurs in the aged.

Separation of the upper epiphysis occurs in the young.

Fracture of the surgical neck is the most frequent, and occurs in middle life.

Prolonged immobilization of the shoulder-joint gives rise to ankylosis (Fig. 137), and passive movement should always be begun just as soon as it is not contraindicated by the treatment.

Excision of the shoulder essentially consists of a resection of the upper head of the humerus. A due regard should be given to the importance of preserving the circumflex nerve. The location of the incision should be at a point where:

(*a*) The circumflex nerve will suffer the least injury.

(*b*) The structures about the joint are easily exposed.

An incision along the anterior margin of the deltoid best conserves this purpose. Beginning at the acromion, the incision is carried downward for 4 inches. Rotation of the arm outward exposes the tendon of the subscapularis, which is detached from the lesser tuberosity. The joint capsule is opened opposite the bicipital groove and the biceps tendon raised from the groove and retracted inward over the lesser tuberosity. By rotating the arm inward the greater tuberosity is brought into view and the muscles detached. The head of the bone is thrust through the capsule and excised.

By a continuation of the same incision we may proceed to *amputation at the shoulder-joint.* Thus, in those cases where

FIG. 137.—ANKYLOSIS OF THE SHOULDER-JOINT.
Note that when the arm is in a horizontal position a right angle is formed with the scapula in the normal joint, an acute angle in the ankylosed joint.

the surgeon is in doubt whether the correct procedure is excision or amputation, he may first examine the head of the bone; if amputation be necessary the same incision is extended downward, the muscles are detached from the bicipital groove, and the head of the bone brought out through the wound. The principal vessels may now be ligated or compression made by the fingers of an assistant and the soft parts cut through. The incision is racket-shaped and leaves an excellent stump.

Tumors of the Shoulder.—The frequent sources of error in diagnosing serous collections of fluid about the shoulder have already been alluded to (p. 252). Sarcoma of the head of the humerus is not unusual and requires an interscapulothoracic amputation.

The deltoid muscle is frequently the seat of *lipomata* because of the comparative abundance of cellulo-adipose tissue which it contains.

The **axilla** or armpit is a pyramidal space between the arm and the upper and lateral part of the chest. Surgically, it is a passageway through which the large vessels and nerves are transmitted from the neck to the upper extremity.

This pyramid-like space is bounded in front by the pectoralis major and minor; behind by the subscapularis, teres major, and latissimus dorsi; on the inner side by the four upper ribs, the intercostal and serratus magnus muscles; and on the outer side by the humerus, the coracobrachialis, and biceps muscles. Its *apex is directed upward* toward the root of the neck and corresponds to an interval between the clavicle and first rib, through which the axillary vessels and nerves pass (Gray). Its *base* is formed by integument and deep fascia, which extends from the pectoralis major to the latissimus dorsi. Extending down to and blending with this fascia is the clavipectoral fascia, which forms the "suspensory ligament of the axilla" (see p. 243).

The skin is covered with hair and contains sebaceous and sweat-glands. These sebaceous glands are very liable to infection. They form subcutaneous abscesses which, on account of the fascia, cannot penetrate into the cavity of the axilla.

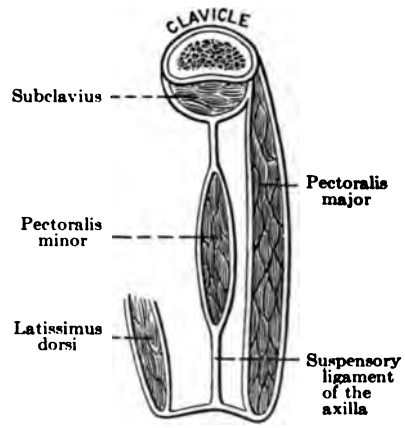

FIG. 138.—THE SUSPENSORY LIGAMENT OF THE AXILLA, SEEN IN SAGITTAL SECTION.

The arrangement of the axillary fascia plays an important rôle in the progress of pus in the axilla. Note the arrangement of the clavipectoral fascia forming the suspensory ligament of the axilla (Fig. 138). After leaving the clavicle and ensheathing the subclavius it runs to the upper border of the pectoralis minor, splits and encloses this muscle, then unites, and goes to the axillary fascia, to which it is attached.

Pus, therefore, may form either above or below this fascia, i. e., either between the pectoralis major and minor or below the

pectoralis minor. In the first instance pus between the two pectorals is of small consequence, since it would point either at the anterior border of the axillary fold or at the interval between the deltoid and pectoralis major. In the second instance pus below the pectoralis minor may lead to fatal consequences. It may burrow along the sheaths of the vessels into the neck and thence spread into the superior mediastinum.

In **opening** the *axilla for the drainage of pus remember* that—

(*a*) The most important structures lie along the outer wall of the space. *The outer side is the danger side.*

(*b*) The knife should enter midway between the anterior and posterior margins, and near the thoracic side, to avoid the vessels.

(*c*) The method of Hilton is the safest; *i. e.*, make the incision through the skin and fascia and follow by inserting an artery clamp, which is opened in the wound and withdrawn; thus, the opening is enlarged without endangering important structures.

Contents of Axilla.—The axillary space contains the axillary vessels and their branches, the brachial plexus, lymphatic glands, and cellular and adipose tissue.

General Considerations.—(*a*) The most important structures lie along the outer wall, near the humeral head, hence—

(*b*) When the humeral head is dislocated, compression of the vessels is apt to be a sequence.

(*c*) Rupture of the artery or its branches, following reduction, is more frequent than injury to the vein, because the artery is in contact with the capsule and the arterial walls are more susceptible to degeneration than veins.

(*d*) Along the inner wall are merely the intercostohumeral nerve, the long thoracic nerve, a few small arterial branches, and the lymphatics.

The **axillary artery** is a continuation of the subclavian; commencing at the outer border of the first rib it runs down to the lower margin of the teres major tendon.

The pectoralis minor crosses the artery and divides it into three parts: the part above, the part beneath, and the part below the pectoralis minor.

With the arm at right angles to the body the *course of the artery* is indicated by a line extending from the middle of the clavicle to the middle of the bend of the elbow.

The direction of the artery varies with the position of the limb. When the arm is at right angles to the body it is almost straight; when the arm is lying beside the chest it describes a curve with the convexity outward and upward.

At its commencement the artery is deeply placed; at its termination it is superficial, being covered only by skin and fascia; hence, *compression* may be effectually applied in the lower part of its course by pressing the artery from within outward against the humerus.

Its Relations.—To its inner side is the axillary vein, maintaining this position throughout its course. The vein overlaps the artery, is larger, and more superficial. It should be remembered that in extirpating the axillary glands the vein is liable to be wounded, especially as these glands are often adherent to the vessel, and when wounded air is liable to be sucked into the vein because it participates in the respiratory movements and is adherent to the costocoracoid membrane. Likewise, when the vein is wounded, it remains patulous and favors serious hemorrhage.

In the first part of its course the brachial plexus lies to the outer side of the artery; in the second portion (below the pectoralis minor) the artery is surrounded by the three cords of the plexus: the outer cord on the outer side, the inner cord on the inner side, and the posterior cord behind. In the third portion the branches of these cords surround the artery, the inner head of the median being in front, the median nerve being on the outer side, the ulnar nerve on the inner side, and the musculospiral nerve behind.

Ligation of Axillary Artery.—The artery may be ligated in the first and third part of its course. In its middle portion the artery is deeply placed and surrounded by large nervous trunks; hence, ligation of this portion is impractical. Ligations in the first part of its course are rarely done, as surgeons prefer to tie the subclavian.

Ligation in the third part is a simple procedure, as the artery here is superficial. *The coracobrachialis muscle is the guide to the axillary artery.*

With the arm supinated and at right angles to the body, beginning at the center of the axillary floor, an incision 3 inches long is made in the line of the artery; after incising the skin and fascia we come to the vein on the inner side and overlapping the artery. The vein is drawn to the inner side. On the outer side is the median nerve, which is retracted outward. The ulnar nerve between the artery and vein is carefully separated. The ligature is passed from the vein side, within outward.

It is well to remember that occasionally there is a muscular slip, derived from the latissimus dorsi, known as the *axillary*

arch, which crosses this portion of the artery and may mislead the surgeon. This muscular slip rises from the upper edge of the latissimus dorsi, crosses the axillary vessels, and joins the under surface of the pectoralis major.

After ligature of the third portion of the axillary, collateral circulation is established by the subscapular and circumflex arteries anastomosing with the superior profunda of the brachial.

FIG. 139.—LYMPHATICS OF THE BREAST AND AXILLA.

The **axillary lymph-glands** are of prime interest to the surgeon because—

(*a*) They drain the upper extremity.

(*b*) They receive the lymph from the breast and the front of the chest (Fig. 139).

They may be divided into three groups:

(1) The *external group* lie on the external wall of the axilla, alongside of the axillary vessels, and receive the lymph from the entire upper extremity. Thus, wounds of the fingers may be followed by enlarged glands in the axilla, or inflammatory lesion of the upper extremity may produce the same result because of this system of drainage.

(2) The *internal group* lies along the internal wall of the axilla or lower border of the pectoralis major. They drain the lymphatics from the breast and front of chest. In cancer of the breast they are the glands first involved.

(3) The *central group* is situated on the posterior wall of the axilla and communicates with the two preceding groups. This group also receives the lymph from the integument of the back.

There are two or three infraclavicular glands situated beneath the clavicle, through which the axillary and deep cervical glands communicate.

Surgical Considerations.—The axillary glands are of great surgical importance in connection with carcinoma of the breast. No operation for cancer of the breast is effective unless it include a thorough removal of the glands of the axilla and those of the infra- and supraclavicular fossæ, if they be involved.

Early involvement of the axillary glands follows mammary carcinoma.

It is not always possible for the surgeon to palpate these glands through the skin and fascia, although they may be involved; hence, the necessity of opening the axilla and removing the glands in every case where there is a suspicion of cancer. The operation of Halsted gives the best exposure for removing the axillary glands. He removes entirely the clavicular portion of the pectoralis major and divides the pectoralis minor. This gives the surgeon free access to the axillary vessels and permits a thorough dissection. The glands are sometimes so adherent to the wall of the axillary vein that dissection is impossible without opening the vessel; in such a case a ligature should be applied to the vein above and below the part involved, and the intermediate portion excised.

The **brachial plexus** is formed by the union of the anterior primary divisions of the fifth, sixth, seventh, and eighth cervical nerves, and the first dorsal (Fig. 140). The nerves emerge between the anterior and middle scaleni muscles. The upper limit of the plexus is represented by a point on the side of the neck opposite the cricoid cartilage. From the side of the neck

the plexus descends, beneath the clavicle, into the axilla, and opposite the coracoid process divides into the numerous branches which supply the upper extremity.

The primary formation of this plexus is constant, but the

FIG. 140.—PLAN OF THE BRACHIAL PLEXUS.

A, Fifth cervical; *B*, sixth cervical; *C*, seventh cervical; *D*, eighth cervical; *E*, first dorsal; *F*, post-thoracic; *G*, internal anterior thoracic; *H*, external anterior thoracic; *I*, middle subscapular; *J*, lower subscapular; *K*, levator anguli scapulæ; *L*, suprascapular; *M*, upper subscapular; *N*, circumflex; *O*, musculocutaneous; *P*, median; *Q*, musculospiral; *R*, ulnar; *S*, internal cutaneous; *T*, lesser internal cutaneous.

formation of the trunks and cords is subject to considerable variation. The following appears to be the most constant arrangement.

The plexus may be divided into five parts:

(1) The *individual primary nerves.*

(2) The nerves uniting to form *three trunks.*
(3) The trunks dividing into *anterior* and *posterior divisions.*
(4) The six divisions uniting to form *three cords.*
(5) The three cords breaking up into *terminal branches.*

Primary Nerves.—As before stated, the primary nerves are the fifth, sixth, seventh, and eighth cervical and the first dorsal. They lie in the lower part of the side of the neck, upon the scalenus medius muscle, the scalenus anticus being in front. The subclavian artery also lies between these muscles, lower down. *The plexus is, therefore, above the second portion of the subclavian artery.*

At the external border of the scalenus anticus muscles the six nerves unite to form *three trunks.* They lie in the posterior inferior triangle of the neck. The lower trunk is behind the third portion of the subclavian artery, the two other trunks are above the vessel.

Beneath the clavicle the trunks divide each into an anterior and posterior division, lying above and external to the first portion of the axillary artery.

These six divisions unite to form *three cords.*

The anterior divisions of the upper and middle trunk form the *outer cord.*

The anterior division of the lower trunk forms the *inner cord,* and the posterior divisions of all three trunks form the *posterior cord.* These three cords surround the second part of the axillary artery, the outer cord lying on the outer side, the inner cord lying on the inner side, and the posterior cord lying behind.

The brachial and cervical plexuses communicate by a branch connecting the fourth and the fifth nerve.

The brachial plexus communicates with the phrenic nerve by a branch from the fifth cervical, which joins the phrenic on the scalenus anticus muscle.

The branches given off above the clavicle are the muscular and communicating branches already mentioned.

The muscular branches are small twigs to the longus colli, scaleni, rhomboidei, and subclavius (this latter branch descends in front of the third part of the subclavian artery).

The practical value in the study of any nerve is a clear understanding of its function; origin and course are important, but function is essential. The primary knowledge of function will suggest the general course of the nerve. Remember that most of these nerves are mixed nerves transmitting both motion and sensation. Recall Hilton's law (p. 252) and

demonstrate its value in the upper extremity. Group the muscles and the cutaneous areas supplied by each nerve (Figs. 141 and 142). Let each movement of the upper extremity suggest the nerve path through which the impulse passes.

The **long thoracic** (external respiratory nerve of Bell) arises from the fifth and sixth cervical nerves in the scalenus medius muscle, passes down behind the brachial plexus and axillary vessels, and supplies the serratus magnus muscle. Paralysis of this nerve produces the deformity known as "winged scapula."

The **suprascapular nerve** arises from the trunk formed by the fifth and sixth nerves. It passes beneath the trapezius and through the suprascapular notch, supplies the supraspinatus and infraspinatus muscles, and sends a twig to the shoulder-joint.

Branches below the Clavicle.—The branches below the clavicle are the nerves derived from the three cords: From the outer cord—the external anterior thoracic, the musculocutaneous, the outer head of median.

FIG. 141.—CUTANEOUS NERVE AREAS OF THE UPPER EXTREMITY (ANTERIOR VIEW).

A, Circumflex; *C*, lesser internal cutaneous; *D*, internal cutaneous; *E*, musculospiral; *F*, musculocutaneous; *G*, ulnar; *H*, median.

From the inner cord—the internal anterior thoracic, the internal cutaneous, the lesser internal cutaneous, the ulnar, the inner head of median. From the posterior cord—the three subscapular nerves, the circumflex, the musculospiral.

External Anterior Thoracic Nerve.—*Function.*—Supplies the pectoralis major muscle. It is a branch of the outer cord, passes inward across the axillary artery, pierces the costocoracoid membrane, and is distributed to the under surface of the pectoralis major muscle.

Internal Anterior Thoracic Nerve.—*Function.*—Supplies the pectoralis minor muscle. Passes behind the first part of the axillary artery, then forward between the axillary artery and vein to the under surface of the pectoralis minor muscle.

The Three Subscapular Nerves.—*Function.*—The upper supplies the subscapularis muscle; the middle supplies the latissimus dorsi, and the lower supplies the teres major.

These nerves are branches of the posterior cord. The middle, or long scapular, accompanies the subscapular artery in its course.

The Circumflex Nerve.—*Function.*—Supplies the deltoid and teres minor, the shoulder-joint, and the skin over the deltoid.

It is a branch of the posterior cord. In company with the posterior circumflex artery it winds around the surgical neck of the humerus, passes through the quadrilateral space (see p. 246) to supply the structure above mentioned.

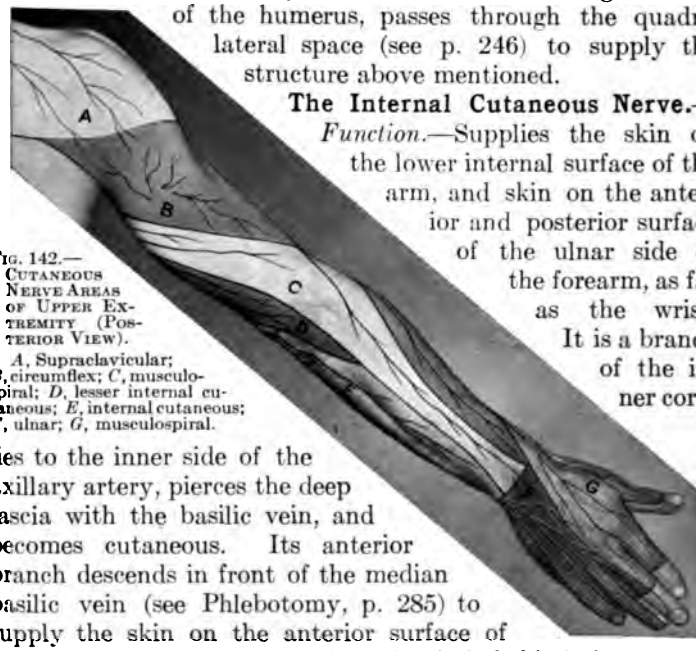

FIG. 142.—CUTANEOUS NERVE AREAS OF UPPER EXTREMITY (POSTERIOR VIEW).

A, Supraclavicular; *B*, circumflex; *C*, musculospiral; *D*, lesser internal cutaneous; *E*, internal cutaneous; *F*, ulnar; *G*, musculospiral.

The Internal Cutaneous Nerve.—*Function.*—Supplies the skin on the lower internal surface of the arm, and skin on the anterior and posterior surface of the ulnar side of the forearm, as far as the wrist. It is a branch of the inner cord, lies to the inner side of the axillary artery, pierces the deep fascia with the basilic vein, and becomes cutaneous. Its anterior branch descends in front of the median basilic vein (see Phlebotomy, p. 285) to supply the skin on the anterior surface of the forearm. The posterior branch winds behind the internal condyle to supply the skin on the back of the forearm.

The Lesser Internal Cutaneous Nerve (Nerve of Wrisberg).—*Function.*—Supplies the skin on the upper and inner aspect of the arm.

It is a branch of the inner cord. It lies on the inner side of the axillary vein and is joined in the axilla by the intercostohumeral (pain in the breast is reflected down the arm through this communication). Half-way down the arm it pierces the deep fascia to supply the skin as above.

The Musculocutaneous Nerve.—*Function.*—As its name indicates, it is muscular and cutaneous in function, supplying the muscles on the anterior surface of the arm and the elbow-joint and the skin on the anterior and posterior surface of the radial side of the forearm as far as the wrist. It is a branch of the outer cord. It passes obliquely through the coraco-brachialis, descends between the biceps and brachialis anticus, winds around the outer border of the tendon of the biceps, piercing the deep fascia. It lies beneath the median cephalic vein (see Phlebotomy, p. 285) and divides into anterior and posterior branches for its cutaneous distribution.

The Median Nerve.—*Function.*—Supplies all the flexors and pronators except the flexor carpi ulnaris and half the flexor profundus digitorum, the elbow-joint, the two radial lumbricales, the integument in the center of the palm, the palmar surface of the thumb, index, middle, and the radial half of the ring fingers. It arises by two heads, one from the outer, the other from the inner cord. These two heads unite in front of the third part of the axillary artery. In the upper part of the arm the nerve lies to the outer side of the artery; at the middle of the arm it is over the brachial artery, and near the elbow it lies on its inner side. At the elbow it is beneath the bicipital fascia and separated from the joint by the brachialis anticus muscle. In the forearm it passes between the two heads of the pronator radii teres, continues down the arm between the flexor sublimis and flexor profundus. Just above the wrist it lies in the middle line between the tendons of the flexor sublimis and flexor carpi radialis, beneath and to the radial side of the palmaris longus. It passes beneath the annular ligament and divides into digital branches which supply the thumb, first, second, and radial side of the ring fingers.

Paralysis of the Median.—In paralysis of the median the muscles on the front of the forearm are atrophied, there is marked wasting of the muscles of the ball of the thumb. Flexion of the wrist is accomplished only through the flexor carpi ulnaris. The hand, in consequence, is deflected toward the ulnar side. The pronators and flexors of the fingers are affected, except the inner half of the flexor profundus, which is supplied by the ulnar. There is loss of sensation on the palmar surface of the thumb, index, middle, and radial half of the ring fingers.

The Ulnar Nerve.—*Function.*—No branches supply the

arm. It sends branches to the elbow and wrist-joints. It supplies the flexor carpi ulnaris and half the flexor profundus digitorum, the skin of the hypothenar eminence, the palmar surface of the little finger and the ulnar half of the ring finger, the dorsal surface of the little finger, ring finger, and the ulnar half of the middle finger, the two ulnar lumbricales, and all the interossei.

The ulnar nerve arises from the inner cord, descends between the axillary artery and vein, and holds the same relation with the brachial artery to the middle of the arm. Here it runs obliquely down across the inner head of the triceps, pierces the internal muscular septum in company with the inferior profunda artery, and descends into the groove between the internal

FIG. 143.—CLAW-HAND DUE TO PARALYSIS OF ULNAR NERVE.

condyle and the olecranon process. In the forearm it passes between the two heads of the flexor carpi ulnaris, and, resting on the flexor profundus digitorum, it descends to the wrist lying on the ulnar side of the ulnar artery. It enters the hand by crossing the superficial surface of the anterior annular ligament, close to the radial border of the pisiform bone, and terminates by bifurcating into superficial and deep branches.

Paralysis of the ulnar nerve is shown by a wasting of the muscles forming the ball of the little finger, impaired power in ulnar flexion and adduction, inability to spread out the fingers, due to paralysis of the interossei; loss of sensation in the skin surface supplied by the nerve

Following paralysis of this nerve the hand assumes a characteristic deformity known as "*claw-hand*" (*main en griffe*) (Fig. 143), due to the fact, that when the two inner lumbricales and the interossei are paralyzed, the balance between the flexors and extensors is lost, in consequence of which the proximal phalanges are extended, the middle and distal phalanges flexed.

The Musculospiral Nerve.—*Function.*—Supplies the muscles in the back of the arm, all the supinators and extensors of the forearm, sends branches to the elbow and wrist-joints, supplies a strip of skin in the middle and back of the arm and forearm to the wrist, the dorsal surface of the thumb, index, and radial half of the middle fingers.

It is the largest branch of the brachial plexus, arises from the posterior cord, and descends behind the third part of the axillary artery and the upper portion of the brachial. It accompanies the superior profunda artery into the interval between the inner and outer heads of the triceps, winds around the musculospiral groove, descends between the supinator longus and brachialis anticus to the front of the external condyle, where it divides into the radial and posterior interosseous branches.

The **radial nerve** is cutaneous in function and descends under cover of the supinator longus. At the middle third of the forearm it joins company with the radial artery, running parallel and to the radial side of the vessel. About 3 inches above the wrist it passes beneath the tendon of the supinator longus, pierces the deep fascia at the back of the wrist, and divides into its terminal branches.

The **posterior interosseous nerve** descends, in company with the posterior interosseous artery, along the interosseous membrane to the back of the carpus, where it ends in a ganglion from enlargement.

Paralysis of the Musculospiral Nerve.—The musculospiral nerve, as it lies in the musculospiral groove, is in close relationship with the humerus. *It is, therefore, more frequently injured than any other nerve of the plexus.* Fractures of the humerus may lead to paralysis of the nerve by causing laceration of the nerve, or the nerve may become involved in the subsequent callus which is formed. It may be severed in wounds of the arm. Sleeping with the head pressing against the arm has been followed by paralysis.

Allowing the arm to hang over the edge of an operating table

while the patient is under anesthesia gives rise to *anesthesia paralysis.* A badly padded crutch pressing against the arm sometimes produces *crutch paralysis.*

Paralysis of this nerve is often a symptom of lead-poisoning. The typical deformity following paralysis of this nerve is known as "*wrist-drop*" (Fig. 144). The extensors being paralyzed, the hand drops flaccid at the wrist, and the fingers are flexed. The supinators and extensors cease to act, and there is loss of sensation in the region supplied by the radial nerve.

Surgical Considerations.—The brachial plexus may be over-stretched or ruptured by extreme traction on the limb, and complete paralysis follow. In subcoracoid dislocations

FIG. 144.—WRIST-DROP.

the head of the humerus may compress the nerve trunks against the ribs. In wounds of the axilla any of the nerves may be involved, but the median is most frequently affected, owing to its exposed position.

The circumflex nerve, as it winds around the surgical neck of the humerus, is exposed to injury in fractures of this part of the bone and in dislocations of the shoulder. Such injury is followed by paralysis of the deltoid.

Erb's paralysis is an obstetric paralysis of the arm occuring in infants, and is due to over-stretching of the plexus during delivery.

Where the brachial plexus has been torn, satisfactory results have followed suture of the plexus.

CHAPTER XV

THE ARM

THE **region of the arm** extends from the insertion of the pectoralis major tendon to a point three fingers'-breadth above the bend of the elbow.

On the anterior surface is the prominent muscular eminence formed by the biceps; on each side are the bicipital grooves, internal and external, corresponding to the inner and outer edges of the biceps muscle.

The **internal bicipital groove** lodges the basilic vein and brachial artery. The pulsations of the artery can be plainly felt, and the vessel compressed against the underlying humerus.

The **external bicipital groove** is not so well-marked as the internal. At the insertion of the deltoid it bifurcates into the anterior and posterior borders of the deltoid. It lodges the cephalic vein.

The skin and subcutaneous tissue of the arm are loose and easily rolled back, which facilitates the forming of a flap in amputations.

The brachial aponeurosis envelops the whole arm like a cuff. It is thicker behind than in front. At the border of the internal and external bicipital grooves are two expansions of this aponeurosis, which extend to the bone, forming an intermuscular septum.

The **internal intermuscular septum** separates the biceps and brachialis anticus above from the triceps below, and is attached to the internal surface of the humerus.

The **external intermuscular septum** extends between the brachialis anticus and the triceps, and is attached to the external border of the humerus. Thus, the arm is divided into two compartments, anterior and posterior.

The anterior compartment contains the biceps and brachialis anticus muscles, the brachial artery and venæ comites, and the median and musculocutaneous nerves.

The **biceps muscle** arises, by a *long head*, from the upper

margin of the glenoid cavity, the tendon of which arches over the head of the humerus and passing through an opening in the capsular ligament descends in the bicipital groove; by a *short head* from the apex of the coracoid process, in common with the coracobrachialis. It is *inserted* by a flattened tendon into the tuberosity of the radius.

Nerve.—The musculocutaneous.

Action.—It flexes the forearm and acts as a powerful supinator.

The **brachialis anticus** is beneath the biceps and rests upon the humerus, encircling its anterior portion. It is separated from the biceps by loose cellular tissue, in which lies the musculocutaneous nerve.

It *arises* from the lower half of the outer and inner surfaces of the shaft of the humerus below the deltoid, and the intermuscular septum. It is *inserted* into the coronoid process of the ulna.

Nerve.—The musculocutaneous.

Action.—Flexor of the forearm.

The **coracobrachialis,** situated at the upper and inner part of the arm, *arises* from the coracoid process and from the intermuscular septum. It is inserted into the shaft of the humerus at the middle of its inner surface. It is perforated by the musculocutaneous nerve.

Nerve.—The musculocutaneous.

Action.—Flexes and adducts the arm.

The **vascular sheath of the arm,** formed from the deep fascia, lies upon the internal intermuscular septum and corresponds to the internal bicipital groove; it is, therefore, just beneath the inner edge of the biceps. It contains the brachial artery, the venæ comites, and median nerve.

The **brachial artery** occupies the internal bicipital groove. It is a continuation of the axillary, and begins at the lower border of the tendon of the teres major, extending down the inner and anterior aspect of the arm, and terminating ½ inch below the bend of the elbow, where it divides into the radial and ulnar arteries.

The *course of the artery* may be represented by a line drawn from the anterior axillary fold along the internal bicipital groove to the middle of the bend of the elbow.

Relations of the Brachial Artery.—Above are the skin, superficial fascia, the basilic vein; at the bend of the elbow the median basilic vein, the deep fascia and the inner border of the biceps

muscle. The median nerve crosses the artery in the middle of its course.

Behind are the insertion of the coracobrachialis and the brachialis anticus. On the *outer* side are the shaft of the humerus, the coracobrachialis and biceps, and the median nerve in the upper part of its course.

On the *inner side* are the internal cutaneous and ulnar nerves and the median nerve in the lower part of its course.

One either side of the artery are the venæ comites.

The principal branches of the brachial artery are:

(*a*) The *superior profunda,* which arises from the upper part of the brachial and accompanies the musculospiral nerve as it winds about the humerus between the outer and inner heads of the triceps to the outer condyle. It passes through the external intermuscular septum and anastomoses with the radial recurrent.

(*b*) The *inferior profunda* is given off just below the middle of the arm and accompanies the ulnar nerve to the olecranon, where it anastomoses with the anastomotica magna, the superior profunda, and the posterior ulnar recurrent.

(*c*) The *anastomotica magna* branches from the brachial near the elbow and runs inward on the brachialis anticus, pierces the internal intermuscular septum, and winds around the back of the humerus. It anastomoses with every neighboring branch except the radial recurrent.

Anomalies.—The brachial artery is more frequently the subject of anomalies than all others. The bifurcation into radial and ulnar may take place anywhere between the armpit and elbow (Owen). The high bifurcation is not infrequent, a fact to be remembered in ligation of the artery.

The **median nerve** gives off no branches in the arm. It changes its relations to the brachial artery three times in the course of that vessel. Above, it lies to the outer side of the artery, in the middle it is on top, and below it is on the inner side. It, therefore, crosses the artery from without in. In the high division of the brachial artery the nerve runs between the two branches.

The *posterior compartment* contains the triceps, the branches of the brachial artery (described above), the ulnar, and musculospiral nerves.

The Triceps Muscle.—The *long head* arises from a depression immediately below the glenoid cavity, the *inner head* from the posterior surface of the shaft of the humerus below the

musculospiral groove, and the *outer head* from the posterior surface of the shaft above the musculospiral groove, the external border of the humerus, and the external intermuscular septum. These three heads unite and are inserted by a common tendon into the upper surface of the olecranon.

Nerve.—The musculospiral.

Action.—Extends the forearm.

The **ulnar nerve** gives off no branches in the arm. It lies internal to the brachial artery, but gradually bears away toward the internal condyle, and finally lodges in a groove between the internal condyle and the olecranon.

The **musculospiral nerve** at first lies behind the artery. It winds in the musculospiral groove in company with the superior profunda artery. After piercing the external septum it reaches the region of the elbow lying between the supinator longus and the brachialis anticus. In front of the external condyle it divides into the radial and posterior interosseous.

Surgical Considerations.—In the development of the humerus the upper end, although first to ossify, is the last to join the shaft (Gray). The length of the bone, therefore, depends mainly upon the growth from the upper epiphysis.

In amputation of the arm in young subjects the humerus may continue to grow and give rise to a conic stump, which may subsequently require the removal of several inches of bone.

Fracture of the Shaft of the Humerus.—It is more frequently fractured by muscular action than any other bone in the body. The usual site of this fracture is at the middle or lower third. The close proximity of the musculospiral to the shaft of the bone renders the nerve liable to injury, which may be primarily involved by contusion or laceration, or secondarily by involvement in the subsequent callus, in which case "wrist-drop" would occur, either immediately or after a lapse of several weeks.

In paralysis of the musculospiral following fracture it is better to wait for several weeks before attempting to operate—

(*a*) Because the paralysis may be due to contusion, in which case it will clear up after a few weeks.

(*b*) It is better to have the bone united before running the risk of an open wound.

This fracture is more likely to be followed by nonunion than any other bone in the body. The reason for this is (*a*) *defective immobilization.* The mistake is frequently made of immobil-

izing the elbow as well as the shaft; nothing contributes more toward nonunion than this procedure, since the rigid elbow-joint allows every movement of the hand and arm to be communicated to the seat of fracture.

(*b*) *Interposition of the Muscles.*—While this has been given as a cause for nonunion by many authors, it probably plays a minor rôle.

Fractures of the shaft of the humerus sometimes occur in the newborn during delivery.

Traumatic paralysis of the musculospiral nerve may occur from the use of an Esmarch bandage, or from allowing a patient's arm to hang over the sharp edge of the table while under anesthesia.

Compression of the brachial artery may be employed for temporary hemostasis in amputation of the arm or in hemorrhage of the hand or forearm. This may be accomplished at any part of the course of the artery. In the upper part the pressure should be directed from within out, in the lower part from before backward. The most favorable site is at the middle of the arm.

Above the elbow, compression may be made by forcibly flexing the forearm on the arm; the thick muscles of the forearm compress the artery as it lies on the brachialis anticus. This is an excellent temporary measure in severe hemorrhage from the palm of the hand.

Ligation of the Brachial Artery for Hemorrhage or Aneurysm.—The ligation of this artery is comparatively easy, because of its superficial situation and the landmarks which serve as guides in determining its position.

The chief landmarks are the pulsation of the artery and the groove along the inner side of the biceps. The artery should be approached with great care because of its superficial situation and its intimate connection with other important vessels and nerves. The arm should be abducted and supinated, and an incision made in the middle third of the arm along the course of the artery at the inner margin of the biceps.

In dividing the superficial fascia the basilic vein should be avoided and drawn to one side.

After dividing the deep fascia the inner border of the biceps is recognized and drawn aside. The median nerve is then seen lying on the artery. If the ligation be made in the upper third of the arm the nerve is to the outer side of the artery, if in the lower third the nerve is on the inner side.

The artery, being recognized, it should be carefully separated from the surrounding structures and the ligature passed from the side of the median nerve. The venæ comites should be avoided.

Possible Errors may obtain in:

(*a*) *High Division of the Brachial.*—This anomaly is of frequent occurrence (one in five). If there are two arteries present they usually run side by side, the median nerve crossing over between them. If on exposing the artery the median nerve is found crossing under instead of over, a high division should be suspected and search made for the second vessel. If two vessels are present the surgeon may discover the one communicating with the wound or aneurysm by alternately pressing on each vessel and applying the ligature accordingly. It may, however, be necessary to ligate both vessels to produce the desired results.

(*b*) In the middle of the arm the inferior profunda may be mistaken for the main vessel, especially if enlarged. This will be avoided by making the incision hug the margin of the biceps, and by noting the different relations with the structures surrounding the two vessels.

(*c*) *Inclusion of Nerve Trunks in the Ligature.*—The artery must be carefully separated from surrounding structures. It should be slightly lifted by the ligature and its pulsations demonstrated before the ligature is tied.

Collateral Circulation.—If the artery be ligated above the superior profunda, the circulation is carried on by an anastomosis between the superior profunda and the circumflex and subscapular arteries. If below the profunda, an anastomosis is established between the profunda and the recurrent radial, ulnar, and interosseous arteries.

CHAPTER XVI

THE REGION OF THE ELBOW

In the region of the elbow are found *three osseous projections:* the *external condyle* and *internal condyle* on the sides, and the *olecranon* behind (Fig. 145). The importance of their relation has already been referred to (pp. 235 and 236).

In front are three muscular eminences: the external, formed by the supinator longus and the extensor group of muscles; the internal, by the pronator radii teres and the flexor group. In the median line is the tendon of the biceps. These lateral muscular masses converge and form a V with the point downward. Between the two borders of the V is a deep depression, the *antecubital fossa,* in the middle of which is the tendon of the biceps.

Posteriorly and on each side of the olecranon is a groove. The internal groove lodges the ulnar nerve. In *synovitis of the elbow* these grooves are obliterated. *In puncture or incision the external groove is chosen in order to avoid the ulnar nerve.*

The skin over the anterior surface is very thin and transparent, and is marked by a transverse fold, which is accentuated when the forearm is flexed.

This transverse fold does not correspond to the articulation. It is about 3 cm. above and opposite the internal condyle. The subcutaneous tissue is quite abundant in women and in fleshy people and may render the operation of phlebotomy quite difficult.

In front of the elbow is situated the venous M (Fig. 146), which is important in the operation of blood-letting or infusion. It is formed on the anterior surface of the forearm by three veins, the radial, the median, and ulnar, situated as their names suggest. About 1½ inches below the elbow the median vein divides into median cephalic and median basilic. The median cephalic unites with the radial to form the cephalic. The median basilic unites with the ulnar to form the basilic. The median basilic vein crosses the brachial artery, from which it is separated by the bicipital fascia. In front lies the internal

cutaneous nerve. Behind the median cephalic vein lies the musculocutaneous nerve.

In former times when blood-letting was a common practice, the median basilic was usually chosen because it is larger than the median cephalic and easily found.

It has, however, these disadvantages: that just beneath it lies the brachial artery, separated only by the bicipital fascia, and above it runs the internal cutaneous nerve, and such accidents

FIG. 145.—RELATIONS OF THE THREE BONY POINTS OF THE ELBOW.

FIG. 146.—VEINS AT THE BEND OF THE ELBOW FORMING THE LETTER M.

as arteriovenous aneurysm and scar neuralgias were at one time frequent sequelæ.

Phlebotomy, as practised to-day, is seldom done for the purpose of abstracting blood, but for the purpose of transfusing either blood or salt solution into the circulation.

The more exact methods of modern operations render the accidents of former times well-nigh impossible.

The aponeurosis which encircles the arm like a cuff becomes

thinner as it approaches the elbow. There is given off from the biceps tendon a fibrous slip, the *bicipital fascia*, which passes downward and inward, and blends with the aponeurosis. It separates the median basilic vein from the brachial artery.

The **brachial artery,** at the bend of the elbow, lies on the brachialis anticus muscle and is covered by the bicipital fascia. It lies between the biceps tendon, externally, and the median nerve, internally. The relations from without-in are tendon, artery, nerve (*T-A-N*); ½ inch below the bend of the elbow the artery bifurcates into radial and ulnar.

The relations of the brachial artery to its venæ comites on each side and to the median basilic vein above render *arteriovenous aneurysm* a possible sequence of wounds in this region. Forcible flexion of the forearm will shut off the current of blood in the brachial artery. This is not only a useful procedure in palmar hemorrhages, but it has been utilized for the cure of arteriovenous aneurysm at the elbow.

The **biceps tendon** is immediately external to the artery. It passes deeply into the antecubital fossa and is attached to the tuberosity of the radius. Hence, the biceps is not only a flexor of the forearm, but also a powerful supinator. In resection of the elbow this tendon must be preserved. Between the biceps tendon and the bicipital tuberosity is a *bursa,* which may become cystic and enlarge, forming a tumefaction in the angle of the antecubital fossa. Treves cites a case where this bursa became chronically enlarged, and by pressing upon the median and posterior interosseous nerves produced paralysis of the forearm.

The **supra-epitrochlear gland** is the lowest gland in the upper extremity. It is situated just above the internal condyle and drains the lymph-vessels of the three inner fingers, the inner portion of the hand, and forearm. It is enlarged in secondary syphilis and in infections of the hand and forearm.

The Arterial Circle at the Elbow.—There is a complete arterial circle at the elbow which permits of ligation without subsequent gangrene. The anastomoses *in front* of the internal condyle are the anastomotica magna, the anterior ulnar recurrent, and the terminal branch of the inferior profunda; *behind,* the internal condyle, the anastomotica magna, the posterior ulnar recurrent, and the terminal branch of the inferior profunda; *in front* of the external condyle are the radial recurrent and the terminal branch of the superior profunda; *behind,* the external

condyle, the anastomotica magna, the interosseous recurrent, and the terminal branch of the superior profunda.

The brachialis anticus muscle covers the elbow-joint and serves as a protection to it. This muscle, with the biceps, are the only muscles which flex the forearm, and its tendon should be preserved in resecting the elbow. If it is necessary to go below the coronoid process we may detach a portion of the tendon, with its contiguous periosteum, without separating the two.

The **elbow-joint** is formed by the meeting of three bony extremities. It is essentially a hinge-joint, permitting only flexion and extension. The radius not only articulates with the humerus, but with the ulna, to which it is held by the orbicular ligament, forming a sling, in which the radial head rotates. This articulation permits of supination and pronation. When lateral movement exists, the ligaments have either been ruptured (in complete dislocation) or lengthened by distention (in tubercular disease of the joint).

This joint depends for its strength not alone upon the muscles and ligaments which surround it, but upon its bony conformation. The bones interlock, the greater sigmoid cavity of the olecranon hooking itself about the trochlear surface of the humerus.

The perfect coaptation of the articular surfaces of the elbow explains the *frequency of ankylosis* following contusion, fracture, and prolonged immobilization. In a lesion of the elbow requiring immobilization the best position is flexion of the forearm at an angle of 90°; should ankylosis follow, this position gives the most useful extremity.

The Ligaments of the Elbow-joint.—The anterior and posterior ligaments add practically no strength to the joint. The posterior is especially thin and loose, and readily distends with fluid in diseases of the joint.

The internal lateral ligament is a thick, triangular band, and is the strongest ligament about the joint. This ligament is involved most frequently in sprains of the elbow.

The external lateral ligament is a short, narrow band, and adds little strength to the joint.

The **interarticular line** is oblique from above down, and without in. The obliquity of the interarticular line causes a difference in the axes of the arm and forearm. Hence, the forearm, when in extension, is not in a line with the arm; an obtuse angle is formed open externally—the "*carrying angle*"—

which allows heavy weights to be carried with the forearm in full extension without interfering with the lower extremity. This angle is best observed when the forearm is extended and the arm held by the side of the body (Fig. 147). In fractures about the elbow the preservation of the "*carrying angle*" is important in attaining a perfect result.

In the *dimple behind the elbow* can be felt the head of the radius. Its rotation is manifest when the forearm is pronated and supinated. In injuries about the elbow the determination

FIG. 147.—CARRYING ANGLE OF ARM.

of the position of the radial head is of prime importance. On the posterior surface the olecranon forms the prominent bony point—the heel of the arm. The tip of the olecranon varies its position as the forearm is flexed or extended. In extension it is on a transverse line connecting the two condyles, and in the same vertical plane. In flexion it is situated below this line. *This relation is of great surgical importance in diagnosing injuries about the elbow-joint.*

The olecranon is between the two condyles, but does not occupy the middle portion. It is nearer the internal condyle,

the internal groove which lodges the ulnar nerve being smaller than the external groove.

The *triceps tendon* is inserted into the posterior surface of the olecranon.

The triceps is the only muscle extending the elbow. Hence, its preservation in resection of the joint is of the utmost importance.

The **olecranon bursa** is situated beneath the subcutaneous tissue covering the olecranon. It is very liable to become inflamed and distended in those whose occupations require constant pressure on the elbow. The fact that it occurs frequently among those engaged in mining has given rise to the name "*miner's elbow.*"

Surgical Considerations.—Loose cartilage may occur in the elbow-joint, but not so frequently as the knee, nor do they give rise to symptoms which require operative relief.

Tubercular disease very frequently attacks the elbow-joint and is usually manifest by a chronic synovitis. In this condition the grooves on each side of the olecranon are obliterated and distention is observed.

Abscesses usually point at one or the other borders of the triceps.

Resection of the Elbow.—The essential structures of the elbow-joint are situated in front of the articulation. The only important structure behind is the ulnar nerve, lying in the groove between the olecranon and the internal condyle. We, therefore, avoid the anterior region of the elbow and open the joint behind, where the bone is subcutaneous and easily accessible. The insertions of the three muscles which move the joint (the biceps, brachialis anticus, and triceps) should be preserved. This is best accomplished by detaching the tendon from its insertion and preserving the continuity of the tendon fibers with the periosteum.

The operation is performed through a posterior vertical incision, 4 inches long, cutting through the triceps down to the bone. The muscles should be detached subperiosteally, preserving the continuity of the periosteum with the utmost care. The greatest difficulty will be encountered in clearing the internal condyle. The ulnar nerve should be lifted from its bed and drawn aside. The ends of the bones having been cleared, the end of the humerus is sawn off at the base of the condyles, the ulna below the level of the lesser sigmoid cavity, and the radius below the level of the neck. Passive motion

should be begun early to get a movable joint. As a result of this operation the humerus throws out two malleoli on the sites of the normal condyles, and in the concavity between them the ulna and radius are received. Between the ulna and the humerus new ligaments form, and a new orbicular ligament for the radius is developed (Treves).

Resection is performed for tubercular arthritis, ankylosis, and the results of traumatism. The results of excision of the elbow are more favorable than in any other joint.

Points to remember in this operation are:

(*a*) Make no transverse cuts through the soft parts.

(*b*) Recognize the ulnar nerve early and guard it from injury.

(*c*) Detach the muscles by the subperiosteal method.

(*d*) Begin passive motion early.

The diagnosing of injuries about the elbow-joint is often attended with much difficulty. The complications which may arise, the possible impairment of the usefulness of the arm, and the patient's demand for a prognosis, place a heavy responsibility upon the surgeon. Every case should be given the benefit of an examination by an *x*-ray, and under anesthesia. The best interests of the patient are thus conserved and the surgeon protected.

In making a diagnosis the establishment of two anatomic relations is of the utmost importance:

(1) Is the head of the radius in proper relation with the external condyle?

(2) Is the tip of the olecranon in the same horizontal and vertical plane as the condyles?

Dislocations.—In order of frequency, dislocations of the elbow are next to those of the shoulder. They are more common in children, due to the fact that hyperextension of the joint is marked in children, but is wholly lost in adult life (Stimson).

The conformation of the elbow-joint throws considerable light upon the various luxations and their relative frequency.

Note the short anteroposterior diameter compared with the lateral. The breadth is out of proportion to the thickness. The normal movement of the joint is in the anteroposterior direction. The anteroposterior surface is not well supported either by ligaments or muscles. On the other hand, the lateral ligaments are strong and the muscles are grouped about the sides of the joint, hence—

(*a*) *Anteroposterior dislocations are more common than lateral.* Again, note the hook-like process of the olecranon, curving about the trochlear surface of the humerus. Except in certain favorable positions, this renders forward dislocations almost impossible, hence—

(*b*) *Backward dislocations are more frequent than forward.* On the other hand, the line of the articulation is oblique, inclining downward, from without in. The internal lateral ligament is much stronger than the external, hence—

(*c*) *Outward dislocation is more common than inward.* The radius is the "handle of the hand" and its intimate connection with the hand exposes it more frequently to indirect violence. The head of the radius has no connection with the humerus.

FIG. 148.—BACKWARD DISLOCATION OF THE ELBOW.

It articulates with the ulna and is held in place by the orbicular ligament, which is much weaker in front than behind, hence—

(*d*) *When a single bone is dislocated it is more commonly the radius—usually forward.* Dislocation of the ulna alone is always backward.

Backward dislocation of the elbow (Fig. 148) is usually caused by a fall upon the outstretched hand when the forearm is extended. The weight of the body causes a hyperextension and the tip of the olecranon acts as a fulcrum to pry the end of the humerus over the coronoid process, which is sometimes broken. The internal and external lateral ligaments are torn. The orbicular ligament remains intact. The biceps and brachialis anticus are stretched around the articular surface of

the humerus. The olecranon process stands out like a heel behind the elbow. The forearm is shortened. Flexion, extension, and rotation are possible only within very narrow limits. Stimson calls attention to the fact that the periosteum is sometimes stripped up and caps the head of the radius in its new position. This periosteum will produce new bone if the dislocation remains unreduced.

Reduction.—If we accept the fundamental principle in the reduction of all dislocations, that the bone should be returned along the path by which it made its exit, we must discard the old method of Cooper (thrusting the knee into the bend of the elbow and flexing the forearm round the knee) as unscientific. While successful results are obtained by this method, yet the result is secured only by a considerable amount of laceration. *This dislocation should always be reduced by traction upon the extended or even hyperextended arm.* After reduction the elbow should be kept flexed at a right angle to prevent recurrence, which is specially liable to occur if the coronoid process has been fractured.

Dislocation of the Radius Forward.—This dislocation is quite common. It may be produced by direct violence from behind, by traction upon the forearm with exaggerated pronation, and by falls upon the hand when the forearm is hyperextended. It may be a coincident of fracture of the shaft of the ulna. Malgaigne's dictum is worth remembering: "In any fracture of the ulna alone look for a dislocation of the radius."

Dislocation of the radius is very liable to occur in young children from a sudden pull on the arm in helping them up a step or in supporting them when they stumble. The head of the radius is dragged out of the orbicular ligament.

The characteristic symptoms of this lesion are absence of the radial head in the dimple behind the elbow and inability to flex the forearm because of the radial head impinging against the front of the humerus. The prominence of the radial head can be felt under the transverse fold. Combined traction upon the forearm with pressure upon the head will usually accomplish reduction. There is a marked tendency toward recurrence. This may be obviated by keeping the limb in a flexed position after reduction has been accomplished.

Fractures in the Vicinity of the Elbow-joint.—Fractures of the lower end of the humerus are more common than in any other part of the bone, and are specially liable to occur in

children, due to certain peculiar conditions in the development of the end of the bone.

The lower end of the humerus is made up of four epiphyses, one each for the condyles and one each for the trochlea and capitellum. The conjoined epiphyses unite with the shaft about the eighteenth year. The line of the lower epiphysis runs transversely across the bone just above the tips of the condyles. This line should be remembered in resecting the joint.

Separation of the Epiphysis.—This accident is liable to occur before puberty. It is usually caused by a fall on the elbow or by "jamming" the elbow in a door. The epiphysis is carried backward *with the upper ends of the radius and ulna*

FIG. 149.—SEPARATION OF THE EPIPHYSIS AT ELBOW.

(Fig. 149). It resembles a backward dislocation of the elbow. The points of difference are:

(*a*) "Muffled" crepitus.

(*b*) *The relation of the three bony points is not disturbed.*

(*c*) *Motion at the joint is not limited, as in dislocation.*

(*d*) Slight pressure brings the epiphysis into position. Fractures of the internal condyle, the external condyle, and fractures into the elbow-joint have many points in common, both in diagnosis and treatment. They are all marked by swelling, crepitus, increase in the breadth of the joint, disturbance in the relation of the three bony points, abnormal lateral mobility, and tendency of the fragments toward upward displacement.

Fracture of the internal condyle is more frequent in adults

than fracture of the external condyle, because of its prominence and exposed position. The tendency toward upward displacement is marked, and if not overcome will lead to gun-stock deformity (Fig. 150) by obliterating the "carrying angle." Fracture of the *internal epicondyle* is common in children. It may implicate the ulnar nerve.

Fig. 150.—Gunstock Deformity Caused by the Obliteration of the Carrying Angle.

In the treatment of these conditions there is now ample evidence, experimental and clinical, to confirm the wisdom of using the *postural* method for the above conditions—no splint is the best splint.

The *acutely flexed position* (Jones' position) not only reduces the fragments, but maintains them in position. If the dissected joint be examined it will be observed that the coronoid process in front, the hook-like process of the olecranon behind, and the strap-like tendon of the triceps posteriorly, all conspire to keep the fragment reduced and pressed firmly against the shaft of the humerus. This position is unquestionably the *anatomic* one. There may, however, be potent reasons for modifying the posture, according to the conditions present. *The best position is the position which holds the fragments in place.*

Supracondyloid fracture is marked by a characteristic deformity. The lower fragment is carried backward and causes a prominence at the elbow. The upper fragment projects anteriorly and causes a fulness at the elbow. In the low supracondyloid fractures of the young the tendency is toward displacement inward.

The three bony points remain in their normal relation.

In the treatment of this fracture proper immobilization is

of the utmost importance, as there is a marked tendency toward displacement of the fragments after reduction. This displacement takes the form of *overriding* in the adult and *lateral angular deviation* in children (Stimson), which ultimately results in the deformity called cubitus varus.

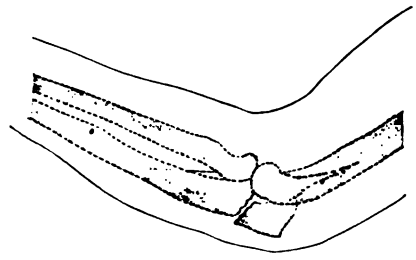

FIG. 151.—FRACTURE OF THE OLECRANON (FROM AN *X*-RAY TRACING).

To prevent the latter deformity Stimson recommends recumbency with the elbow at a right angle and the forearm vertical.

Fracture of the olecranon (Fig. 151) is due either to direct violence, falling on the flexed elbow, or to muscular action of the triceps. The usual symptoms of fracture are present; the pain, however, is apt to be more intense and of a spasmodic

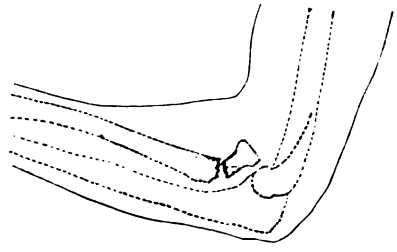

FIG. 152.—FRACTURE OF THE HEAD OF RADIUS (FROM AN *X*-RAY TRACING).

character, due to the action of the triceps upon the broken fragment.

Repair in this fracture takes place either by bony or fibrous union; fibrous union is the more common. If the fibrous band lengthens the process, there will be interference with the function of extension.

The anatomic position for the treatment of this fracture would naturally be that which relaxes the triceps tendon and affords the closest coaptation of the broken fragment, viz.:

the extended position. However, the dangers of ankylosis in this position cannot be ignored, and the discomfort of the patient must be considered. If the separation of the fragments is marked the extended position must be adopted. If there is little separation the arm may be flexed or semiflexed.

Fracture of the head of the radius is apt to be confused with dislocation of the radial head and fracture of the external condyle (Fig. 152).

The fragment may be palpated. The head does not show in the rotation of the shaft. The joint may be flexed without impingement. Pressure on the shaft of the radius causes pain at the site of fracture. It may be necessary to remove the head of the radius to secure a satisfactory result.

CHAPTER XVII

THE FOREARM

THE forearm is that portion of the upper extremity situated between the elbow and the wrist. It extends below to within two fingers'-breadth above the styloid process of the radius. It is encircled by an aponeurotic sheath, which is attached to the lateral surfaces of the radius and ulna. The bones are united by the interosseous membrane. The aponeurosis gives off intermuscular septa, which enclose the individual muscles.

The muscles of the forearm may be divided into two groups—

(*a*) The flexor and pronator muscles, occupying the inner and anterior aspect of the forearm.

(*b*) The extensor and supinator muscles, occupying the outer and posterior aspect. The bellies of the muscles occupy the upper two-thirds of the forearm, their tendons the lower one-third.

It will be observed that this division is not only a regional division, but a functional one, and as muscles having the same function ought naturally to have the same nerve supply we find that—

The **musculospiral nerve** supplies group (*e*), the extensors and supinators (see Fig. 115).

The **median nerve** supplies group (*f*), the flexors and pronators, with the exception of the flexor carpi ulnaris and half the the flexor profundus digitorum (see Fig. 115).

The **radial artery,** although smaller than the ulnar, is in its general course a direct continuation of the brachial. Its position in the forearm is represented by a line drawn from the middle of the bend of the elbow to the inner side of the styloid process of the radius. At the styloid process of the radius it winds around the back of the wrist and into the palm of the hand. Its satellite muscle is the *supinator longus,* the anterior border of which overlaps it.

In considering the course of this artery the frequent high division of the brachial must be kept in mind. In the forearm the artery seldom deviates. It has, however, occasionally

been found on the surface of the supinator longus instead of under its inner border.

The radial artery is frequently wounded in the lower third of its course, where it is superficial. Incised wounds, caused by driving the hand through a pane of glass or by sharp-edged tools, are common causes. Severe hemorrhage or traumatic aneurysm is a frequent sequence.

Ligation.—The artery may be exposed in any part of its course in the forearm without dividing the muscles.

In the upper part of the forearm an incision is made in the line of the artery, through the skin, superficial and deep fascia. The longitudinal fibers of the supinator longus are exposed and the edge of the muscle drawn outward. The artery will be found in the connective tissue accompanied by its venæ comites. The radial nerve in this region will be found gradually approaching the artery from the outer side. The ligature should, therefore, be passed from without in, to avoid the nerve.

In the middle of the forearm the artery is found between the supinator longus and the flexor carpi radialis. The nerve is close to the outer side.

The **radial nerve** lies at first beneath the supinator longus, a little to the outer side of the radial artery. In the middle third of the forearm it is in close relation with the outer side of the artery. About 3 inches above the wrist it leaves the artery and passes beneath the tendon of the supinator longus to the back of the wrist and hand. Its function is cutaneous, and its wounds, therefore, not of serious import.

Ulnar Artery.—The larger of the two divisions of the brachial takes a curved direction with the convexity inward to the middle and ulnar side of the forearm. From this point its course is straight down to the outer side of the pisiform bone; at its origin it is crossed by the median nerve.

Its satellite muscle is the flexor carpi ulnaris.

The course of the artery may be divided into (*a*), submuscular—the curved part of its course. Here the artery is deeply placed beneath the superficial flexors and pronators: (*b*) the subaponeurotic—the straight part of its course, where it is superficial and lies upon the flexor profundus and is placed between the flexor carpi ulnaris and the flexor sublimus digitorum. The ulnar nerve lies on its inner side.

In high bifurcation of the brachial this vessel is subject to greater deviation than the radial. It then is found taking

a superficial course to the flexor muscles of the forearm, lying either beneath the fascia or between the fascia and skin.

This artery is less exposed, and consequently is not wounded so frequently as the radial. The necessity for its ligation in case of hemorrhage or aneurysm is not common.

The largest branch of the ulnar artery is given off opposite the bicipital tuberosity, the *interosseous*, which speedily divides into *anterior* and *posterior interosseous*. The former passes down the forearm on the anterior surface of the interosseous membrane to the pronator quadratus, pierces the interosseous membrane, and passes to the back of the forearm, where it anastomoses with the posterior interosseous and the posterior carpal arteries. It furnishes an artery to the median nerve (the comes nervi mediana). The *posterior interosseous* descends on the posterior surface of the interosseous membrane between the adjacent borders of the supinator brevis and the extensor ossis metacarpi pollicis. Further down it courses between the superficial and deep layers of muscles. At the lower part of the forearm it anastomoses with the termination of the anterior interosseous artery.

Ligation.—The curved course of the upper part of the artery and the straight direction of its lower part render the line marking the course of the artery somewhat complicated.

The lower two-thirds of the artery is represented by the lower half of a line drawn from the front of the internal condyle to the outer side of the pisiform bone. The upper third of the artery is represented by a line drawn from the middle of the bend of the elbow to the center of the first line.

In the upper part of the forearm the artery is ligated by making an incision along the line drawn from the internal condyle to the pisiform bone, beginning about 2 inches below the condyle. After opening the deep fascia the *white line* marking the septum between the flexor carpi ulnaris and the flexor sublimis digitorum is sought for and incised. The ulnar nerve is found lying on the flexor profundus digitorum.

Below the nerve the artery is found accompanied by its venæ comites. The ligature should be passed from within out, to avoid the nerve.

In the middle or lower part of the forearm the artery is more superficial and easily found on the radial side of the flexor carpi ulnaris. The nerve lies on its inner side between the vessel and the tendon.

The **ulnar nerve** passes into the forearm between the two

heads of the flexor carpi ulnaris and takes a straight direction to the wrist. It lies upon the flexor profundus digitorum muscle. Its upper half is covered by the flexor carpi ulnaris muscle. Its lower half lies to the outer side of the muscle. In its upper third the ulnar artery is separated from the nerve. In the lower two-thirds the nerve lies to its inner side. It is liable to be injured in wounds of the forearm. Paralysis of the parts to which it is distributed follows, and *claw-hand* develops (see p. 45).

The **median nerve** at the elbow is posterior to the artery (tendon, artery, nerve, *T-A-N*) and crosses the ulnar artery at its origin; in the forearm it passes between the two heads of the pronator radii teres. It runs beneath the flexor sublimis digitorum, lying on the flexor profundus. About 2 inches above the wrist it becomes superficial, lying between the tendons of the flexor sublimis and flexor carpi radialis muscles under the tendon of the palmaris longus, which serves as a guide to the nerve. In the forearm it is accompanied by a branch of the anterior interosseous artery, the *comes nervi mediana.*

In incised wounds in the lower and anterior part of the forearm it is very liable to be injured. When paralyzed the flexors and pronators are involved with loss of sensation on the palmar surface of the thumb, index, middle, and outer half of the ring fingers (see p. 274).

The relation of the vessels and nerves on the anterior of the forearm is easily remembered when it is observed that the two arteries lie between the nerves: the radial artery between the radial and median nerves, and the ulnar artery between the ulnar and median nerves. The letters representing this relation would spell the letters *N-A-N-A-N* (Fig. 153).

Bones of the Forearm.—The two bones are connected by the *interosseous ligament*, which provides a more extensive surface for the attachment of the deep muscles and is a factor in preventing the bones from overriding in fractures.

The two bones are so placed that their thickened extremities occupy opposite poles.

The broad and strong articular end of the ulna is at the elbow, that of the radius is at the wrist; hence, the ulna may be considered the handle of the arm and the radius the handle of the hand. Forces transmitted through the arm or hand affect most powerfully the respective bones of the forearm to which they are most intimately attached.

In transverse section through the forearm it is seen that the bones throughout are nearer the posterior than the anterior

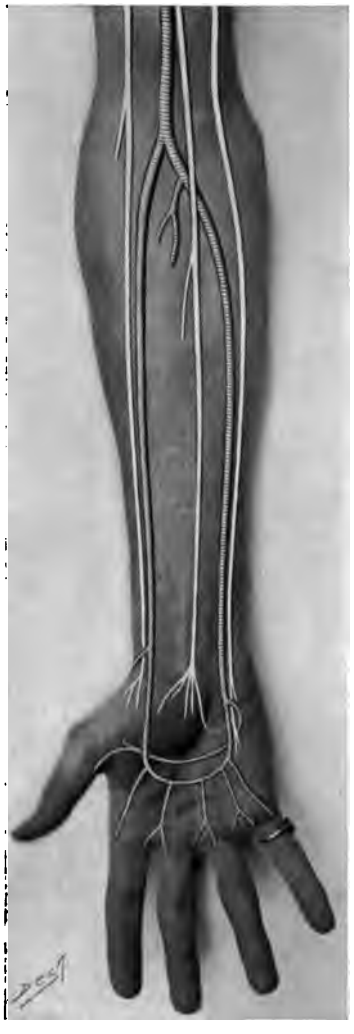

FIG. 153.—RELATIONS OF THE ARTERIES AND NERVES OF THE FOREARM.
The letters representing this relation spell the letters *N-A-N-A-N*.

FIG. 154.—FOREARM PRONATED, SHOWING THE BONES CROSSED.

surface; hence, in compound fractures of the forearm the wound is usually posterior.

The radius and ulna are so articulated that the radius rotates about the ulna, making possible the two important movements of the forearm—pronation and supination.

In pronation the palm is down and the bones crossed (Fig. 154).

In supination the palm is up and the bones parallel (Fig. 155).

These two positions are important to bear in mind in the treatment of fractures of the forearm. Treves shows that supination is more powerful than pronation by the illustration of the action of the screw-driver. The thread of the screw is so placed that the screw must be inserted by supination rather than pronation.

Fractures of the Forearm.—The two bones are most frequently broken together, usually by direct violence and in the lower half (Fig. 156).

Dangers.—1. *Gangrene.*—There is greater liability to gangrene from splint pressure than in any other part of the body. This is due (*a*) to the superficial position of the arteries in the lower part of the limb, rendering them easily affected by pressure.

(*b*) The flexed position of the forearm with the end of the splint jammed against the bend of the elbow may cut off the circulation.

(*c*) The application of a roller bandage directly to the forearm under the splint; or the use of soft splints which take the shape of the limb may produce the same direful results. Cases of total gangrene of the limb are reported without any warning symptoms.

2. *The "Ischemic Contraction" of Volkmann.*—This is due to a milder form of compression than the former condition. It is caused by a diminution in the blood supply, with consequent atrophy, increase and contraction of connective tissue, and shortening of the muscles. The fingers are permanently flexed.

3. *Union between the two bones,* as well as the fragments. The callus is not only thrown out between the ends of the fragments, but across the interosseous membrane, uniting the two bones and destroying or seriously modifying the movements of supination and pronation.

This unfortunate result is most liable to occur (*a*) when the interval between the bones is diminished in pronation, least likely when the bones are at their maximum distance from each other in supination.

(*b*) When there is marked displacement of the fragments.

FIG. 155.—ARM SUPINATED, SHOWING THE BONES PARALLEL.

FIG. 156.—FRACTURE OF BOTH BONES OF THE FOREARM.

(*c*) When there is excessive formation of callus, due to laceration of the interosseous membrane.

Treatment.—*The importance of accurate and complete reduction in fractures of the forearm cannot be too strongly emphasized.*

Angular displacement and overriding must be overcome by extension and counterextension, special care being exercised to avoid pressure on the bones near the site of the fracture. Reduction should be made while the hand is supinated to get the most accurate results.

Final Position of the Forearm.—The most comfortable and natural position for the forearm is midway between supination and pronation. Complete supination is a strained position, unless the patient be put to bed, when, with the arm abducted, this position may be maintained with comfort. Therefore, in simple cases where the reduction is complete and permanent the forearm may be fixed midway between pronation and supination, and the results be entirely satisfactory.

Where there is a tendency toward angular displacement, and danger of the bones uniting across the interosseous membrane, the patient should be put to bed and the forearm fixed in full supination.

The splints should be of an inflexible material and wider than the limb, to prevent lateral pressure. They should be long enough to include the hand. Immobilization of the wrist is essential.

The sling should support both the elbow and the wrist.

Fracture of the shaft of the ulna is more frequent than fracture of the radius, because the natural position of the arm in self-defense places the ulna in an exposed position. It is always the result of direct violence and is apt to be associated with dislocation of the radial head (see p. 292).

The limb should be immobilized, as in fracture of both bones.

Fracture of the shaft of the radius is usually the result of direct violence; angular displacement generally follows. In fracture of the upper third of the radius above the pronator the displacement is very great. The upper fragment is flexed and supinated by the biceps and supinator brevis. The lower fragment is pronated and drawn toward the ulna. The danger of bony union across the interosseous membrane is great. The angular displacement must be carefully reduced and the forearm immobilized in full supination.

Extensive phlegmonous inflammation frequently follows compound fractures of the forearm. Infection travels along the sheaths of the tendons and rapidly involves the entire limb unless prompt and efficient drainage be adopted.

CHAPTER XVIII

THE WRIST

THE **wrist**, *anatomically* considered, refers to the radiocarpal articulation.

Surgically, it refers to the inferior part of the forearm and the carpus.

The region of the wrist may be arbitrarily placed two fingers'-breadth above and below the interarticular line.

FIG. 157.—STRUCTURES ON THE ANTERIOR SIDE OF THE WRIST.

Anteriorly, the hand is separated from the wrist by the thenar and hypothenar eminences, above which is a well-marked depression, which forms a regular curve. In fracture of the lower end of the radius this regular curve is replaced by a more or less marked angular depression.

The *structures on the anterior side of the wrist*, from without in, are—

The supinator longus tendon, the radial artery and vein,

the flexor carpi radialis, palmaris longus, median nerve, tendons of the flexor sublimis and profundus, ulnar artery and veins, ulnar nerve, and flexor carpi ulnaris (Fig. 157).

All these structures lie upon the pronator quadratus, which stretches transversely across the two bones.

The radial artery, with its venæ comites, lies in a groove between the tendons of the supinator longus and the flexor carpi radialis.

The **radial nerve** does not accompany the artery at this point, but leaves it about 3 inches above the wrist, to pass beneath the tendon of the supinator longus. Hence, in ligating the artery at this point we do not find the nerve at the radial side of the vessel.

The artery is very superficial at this point, being covered only by skin and aponeurosis; hence, it is more frequently wounded, but hemorrhage is easily controlled.

Atheromatous changes are early recognized in this artery. At the apex of the styloid process the radial artery changes its direction to wind around the outer side of the carpus and penetrate the first interosseous space.

At the point where it changes its direction it gives off an important branch, the *superficialis volæ*, which crosses the short abduction of the thumb to anastomose with the ulnar and form the superficial palmar arch.

The **median nerve** lies between the tendons of the flexor carpi radialis and the flexor sublimis under the tendon of the palmaris longus.

The **ulnar artery** lies in a groove between the flexor carpi ulnaris and the flexor sublimis. It continues in a vertical direction in front of the annular ligament and is lodged in a groove on the external side of the pisiform bone, which is an important landmark in ligating the artery.

Its final anastomoses in the palm, with the superficialis volæ, forms the superficial palmar arch.

In incising collections of pus on the anterior surface of the wrist the incision should be a vertical one, placed midway between the center and ulnar side to avoid the median nerve.

Wounds of the anterior portion of the wrist assume an important aspect, because of the involvement of the tendons. Being superficially placed they are liable to be divided and *unless properly treated the function of the hand is lost.*

In all wounds about the wrist careful search should be made to ascertain whether any of the tendons are involved.

If a tendon has been divided it should be sutured, the ends being brought in contact, if possible; if not, they thould be placed near each other. The hand should be immobilized in a position of flexion.

The *posterior* or *dorsal surface of the wrist* presents less surgical interest than that of the anterior surface.

With the hand pronated the axis of the forearm, wrist, and hand are in the same vertical line; when the inferior extremity of the radius is fractured the wrist is carried outward and the line of the axis deviates sharply.

The bones are more accessible on the dorsal surface than in front, the head and styloid process of the radius being specially prominent.

The aponeurosis at this point is of special importance. It is reinforced a little above the articular surfaces of the radius and ulna by transverse fibers, and takes the name of the *posterior annular ligament.* It is not an independent ligament, but only a reinforced portion of the aponeurosis which is continuous above with the aponeurosis of the forearm and below with that of the metacarpus.

The function of the posterior annular ligament is to hold the extensor tendons close to the bone and prevent their luxation, which would necessarily be frequent without it.

The grooves in the radius and ulna are by means of this ligament, converted into osteofibrous canals which the tendons traverse.

There are three of these osteofibrous canals from without in. The first contains the tendons of the extensor communis digitorum and extensor indicis, the second the extensor minimi digiti, and the third the extensor carpi ulnaris.

Each of these grooves is covered by synovial membrane, and although susceptible to inflammation and serous effusion they are seldom affected. *Where the tendon is cut, retraction toward the forearm always follows, and the end cannot be recovered in the wound.* This is specially true of the tendons of the index and little fingers, which possess grooves independent of the other extensor tendons. When divided it is necessary to look for the divided end in the forearm. If not found, an anastomosis should be made with a neighboring tendon.

On the external portion of the wrist we find the tendons of the extensor ossis metacarpi pollicis, the extensor brevis pollicis, the extensor longus pollicis, and the radial artery and vein (in the anatomic snuff-box).

The osteofibrous grooves lodging the extensor tendons of the thumb are frequently the site of inflammation following excessive exercise. This may result in swelling along the course of the tendon, accompanied by a creaking sensation (tendon crepitus). This condition is apt to occur after wringing clothes—"*washerwoman's sprain.*"

Anatomic Snuff-box.—The depression between the long and short extensors of the thumb, well marked when the thumb is forcibly extended. At the bottom of the depression are the radial artery and veins just before they pierce the first metacarpal space.

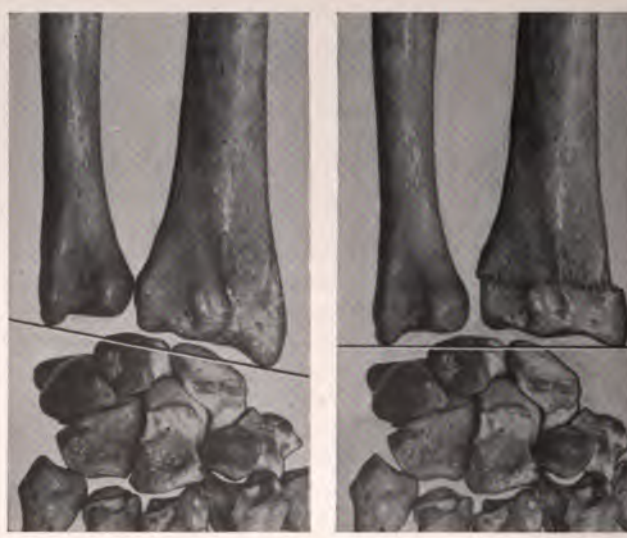

A *B*

FIG. 158.—(*A*) NORMAL RELATIONS OF RADIAL AND ULNAR STYLOIDS, AND (*B*) THE RELATION AFTER COLLES' FRACTURE.

Bones of the wrist are the radius, ulna, and bones of the carpus, which form three articulations:

(*a*) The inferior radio-ulnar.

(*b*) The radiocarpal.

(*c*) The mediocarpal.

The lower extremity of the radius is much larger than the body of the bone, and with the carpal bones forms the wrist-joint.

This extremity is composed of spongy tissue which offers but feeble resistance to pressure. The body of the bone is

composed of compact tissue; hence, it is readily understood how *in Colles' fracture the body of the bone is driven into the epiphysis* (impacted).

The epiphysis joins the body at the twentieth year, so that before the twentieth year we are more liable to observe separation of the epiphysis than fracture.

The head of the ulna has no part in the wrist-joint. It does not descend so low as the radial head. Its epiphysis joins the body about the same time as that of the radius.

The styloid processes of the radius and ulna form important landmarks in the surgery of the wrist. They are not on the same level, the radius being lower than the ulna. In Colles' fracture the impaction diminishes the length of the radius and the two styloids are then at the same level (Fig. 158).

The **inferior radio-ulnar joint** is formed by the head of the ulna and the sigmoid cavity on the internal surface of the lower end of the radius. Note that the mechanism here is just the reverse of that at the elbow (where the head of the radius is received into the lesser sigmoid cavity of the ulna). The two bones are united by two peripheral ligaments (anterior and posterior radio-ulnar), which are very weak, and by an interosseous ligament, the triangular fibrocartilage, which is very strong.

FIG. 159.—TRIANGULAR FIBROCARTILAGE.

The **triangular fibrocartilage**, as its name indicates, is triangular in form (Fig. 159). Its base is inserted into the internal border of the inferior extremity of the radius, its apex into the external surface of the styloid process of the ulna.

The functions of this ligament are to unite the radius and ulna and to take the place of the head of the ulna in the formation of the wrist-joint.

The Radiocarpal Articulation.—The articular surface of the radius and the under surface of the triangular fibrocartilage together form the cavity of reception, which articulates with the scaphoid, semilunar, and cuneiform bones. The inter-

articular line is curved, its highest point being about ½ inch above a transverse line uniting the tips of the styloid processes.

The radius is united to the carpus by two ligaments—the posterior, which is weak, and the anterior, which is very strong—two important factors in fractures and dislocations of this region.

The wrist-joint has all the movements except rotation, and this deficiency is compensated for by the movements of supination and pronation of the radius at the radio-ulnar joints.

The **mediocarpal joint** is the articulation between the two rows of carpal bones. The line of this articulation resembles an S placed horizontally.

The feature of this joint is the ball-and-socket character of its central portion, the os magnum and unciform being a condyle which fits into the cavity formed by the scaphoid, semilunar, and cuneiform. Flexion, extension, a slight amount of lateral motion, and a limited degree of rotation take place in this joint. Note the fact that at the wrist extension is freer than flexion, at the mediocarpal joint flexion is freer than extension.

Colles' Fracture ("Silver-fork Fracture").—This fracture is a very common one, ranking next in frequency to fracture of the clavicle. The mechanical factors which cause it, and the pathologic conditions present have been the prolific source of medical debate for nearly a century. Dr. Colles, of Dublin, was the first to give an accurate description of this lesion, and since his contribution fracture of the lower end of the radius has been known as Colles' fracture.

Velpeau, in observing the deformity, was impressed with its similarity to a silver fork, and it has also been called "silver-fork fracture."

There is no good reason why it should not retain the name of Colles, for, while it is a fracture of the lower end of the radius, it is more—it is a fracture of such distinctive characteristics that it is worthy of a distinctive name. It is no flight of fancy to observe the analogy between a Pott's and a Colles' fracture. They both have in common a characteristic cause, pathology, deformity, and symptomatology. Pott's fracture means more than a fracture of the lower end of the fibula, and Colles' fracture means more than a fracture of the lower end of the radius.

Colles' fracture is an impacted fracture of the lower end of the radius; occasionally the lower end of the fragment is comminuted, but impaction is the rule (Fig. 160).

The circumstances under which the fracture is received play an important rôle in its pathology. When a person falls it is the natural thing to throw the hand forward for protection; thus, the hand in the hyperextended position receives the force of the fall and the blow is transmitted from the carpus to the carpal end of the radius and fracture results.

The Anatomic Factors in Colles' Fracture.—(*a*) The radius is the "handle of the hand." The hand follows the radius.

(*b*) The lower extremity of the radius is composed of spongy tissue. About ¾ inch above its carpal end it joins the compact tissue of the shaft; hence, the weak spot at this point of juncture.

(*c*) Of the two ligaments which bind the lower end of the radius to the carpus the *anterior is thick and strong*, the *posterior is thin and weak.*

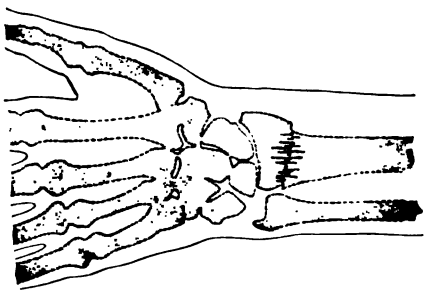

FIG. 160.—COLLES' FRACTURE (FROM AN *X*-RAY TRACING).

(*d*) It is a well-observed fact that spongy tissue of bone is often less resistant than the ligaments attached to it; hence, when the ligaments are strongly stretched they may pull away the fragment to which they are attached.

(*e*) The patient falls upon the hand when it is in extreme extension. Either one of two things must happen. (1) The anterior ligament must rupture and a radiocarpal dislocation take place, or (2) the ligament resist and tear off the lower end of the radius to which it is attached. The latter is precisely what occurs. The end of the radius is torn off at the weak spot mentioned above, because of the cross-strain imposed at this point (Fig. 161).

(*f*) As the spongy end of the radius is torn off, the weight of the body, transmitted through the compact shaft, thrusts the end of the shaft into the spongy fragment, and impaction occurs (sometimes comminution).

(*g*) As the lower fragment of the radius is displaced the triangular fibrocartilage is dislocated, causing an undue prominence of the ulna, a widening of the wrist as the radius and ulna are spread apart, and sometimes the styloid process of the ulna is torn off.

An appreciation of these anatomic factors readily explains the five well-marked deformities which make the *symptom-complex of Colles' fracture.*

(1) *Prominence of the Fragment at the Back of the Wrist.*—This dorsal prominence is caused by the fragment being displaced upward and backward and sometimes tilted on its own axis (action of untorn anterior ligament).

FIG. 161.—SECTION IN LONG AXIS OF RADIUS, SHOWING ACTION OF RADIOCARPAL LIGAMENTS AND POINT WHERE FRACTURE OCCURS.

(2) The *hand is thrown to the radial side,* giving the appearance of dislocation of the wrist. This is caused by the hand following the distal fragment to which it is attached by strong ligaments.

(3) *Prominence of the ulna* is caused by the lower end of the radius being torn away from the ulna. The fibrocartilage is dislocated and undue prominence of the ulna results.

(4) *Widening of the wrist,* caused by the same condition as in the foregoing paragraph.

(5) *Shortening of the Radius.*—The backward displacement and the impaction causes a shortening of the radius, and is shown by comparing the normal relation of the radial and ulnar styloid with the same in a Colles' fracture (see Fig. 158).

In the normal arm the radial styloid is about ½ inch lower than the ulna; in a Colles' fracture, the radial styloid is pushed upward so that the tips of the styloids will be on a level, or the radial may be on a higher level than the ulna.

A most *important peculiarity* is the absence in most cases of crepitus or abnormal mobility of the fractured fragment, due to impaction.

This condition is so constant that in reducing the fracture it is difficult to dislodge the fragment without great force, and reduction is seldom satisfactorily accomplished without anesthesia.

The **correct anatomic position in reducing Colles' fracture** is to place the hand in the opposite position to that in which the injury was sustained. At the time of injury the hand is hyperextended and pronated. By supinating and flexing the

FIG. 162.—CORRECT POSITION OF HAND AND FOREARM IN REDUCING COLLES' FRACTURE.

hand the reduction can be most easily accomplished. With the patient completely anesthetized the forearm is brought to a right angle and supinated. Traction is made upon the hand in the flexed position and counterpressure is made upon the upper fragment (Fig. 162).

Reasons for This Manipulation.—(1) The forearm is brought to a right angle and supinated, to relax the supinator longus muscle, attached to the displaced fragment.

(2) Traction is made upon the hand in the flexed position, because the strong anterior ligament which binds the displaced

fragment to the carpus will thus directly pull the fragment into its normal position.

The value of the strong anterior ligament connecting fragment and carpus has not been sufficiently emphasized. It is of immense importance in pulling the fragment into position if traction is made upon the flexed hand.

It is well to realize that in this fracture, even under the best treatment, perfect results cannot always be expected.

Dislocation of the Lower End of Ulna.—In pronation and supination the radius turns about the ulna. The radius carries with it the triangular ligament. In forced pronation the triangular ligament may be carried so far forward as to clear the end of the ulna entirely. This accident has been produced by engaging the hand in the spokes of a moving wheel, by wringing clothes, or by suddenly lifting a child by the hand to help it ascend a step. With the ulna thus dislocated there is a marked projection of its lower end on the back of the wrist; the hand is held in forced pronation and there is inability to return it to supination. The dislocation is reduced by forced supination.

In *arthritis* and *tuberculosis* there is relaxation of the radiocarpal ligaments and the joint is very movable.

The carpal bones are rarely fractured or dislocated singly. In cases of severe traumatism they may be so comminuted as to warrant resection or even amputation.

Fracture of the Scaphoid.—Since the introduction of the *x*-ray, what was formerly an obscure lesion has been shown to be a fracture of the scaphoid. It results from a fall on the hand in dorsal flexion. The usual site of fracture is the middle third of the bone accompanied at times by a dislocation of the fragment. The symptoms are stiffness of the wrist, radial abduction of the hand, and pain over the scaphoid and along the depression in the anatomic "snuff-box." The use of the *x*-ray confirms the diagnosis.

Ganglion of the wrist is a cyst formed by a hernial protrusion of the synovial lining of a tendon sheath. They may also be formed by diverticula from the carpal joints (Sutton).

They are usually found on the back of the carpus in the form of a rounded elastic swelling, which becomes tense when the wrist is flexed.

They may be treated by forcible pressure, sufficient to rupture the sac, or by careful dissection.

Tuberculosis of the wrist is rare in children, but frequent

in middle life. Beginning in a single bone, it spreads throughout the carpus. Its extension is facilitated by the numerous synovial cavities which surround the carpal bones. The proximity of the tendon sheaths render them liable to be invaded. The later stages of the disease are marked by sinuses which usually open upon the back of the wrist.

Excision of the Wrist.—The wrist is one of the most difficult joints to explore. The numerous tendons which cover both the anterior and posterior surfaces of the articulation; the invasion of synovial cavities; the difficulty of removing all the diseased tissue without sacrificing important organs; and the doubtful functional result render resection of the wrist a procedure of more doubtful value than that of the shoulder or elbow.

In exploring the wrist the landmarks are the styloid processes of the radius and ulna.

The tip of the styloid process of the ulna corresponds to the line of the wrist-joint. A line joining the two styloid processes would pass 1 cm. below the radiocarpal joint and 15 mm. above the carpometacarpal joint.

The inferior transverse fold in front of the wrist, if projected on the dorsal surface of the hand, would pass exactly over the neck of the os magnum (Tillaux). Various incisions have been advocated for excising the wrist-joint.

The simplest and most satisfactory is the dorsal incision between the extensor indicis and the extensor communis tendons. The hand is split between the second and third metacarpals, the trapezium and os magnum, and the scaphoid and semilunar bones.

The articular ends of the radius and ulna, the carpal bones, and the ends of the metacarpals are usually removed.

CHAPTER XIX

THE HAND

THE palm of the hand consists of a central, depressed portion, triangular in shape, with its apex directed upward, the "hollow of the hand," bounded externally by the thenar eminence, internally by the hypothenar eminence, and below by three small elevations at the roots of the fingers corresponding to the interdigital spaces.

The palm is crossed by three well-marked furrows (Fig. 165).

The *first* starts at the wrist, curves about the base of the thenar eminence, and ends at the outer border of the hand, at the base of the index finger. This crease is due to the movement of the thumb in opposition. It corresponds to the carpometacarpal joint of the thumb.

The *second* starts where the furrow of the thumb ends, and passes across the hand in an oblique and slightly upward direction, and is lost in the hypothenar eminence. The outer portion of this furrow is due to flexion of the index finger, the remainder to a secondary fold caused by flexion of the three inner fingers. The point where this furrow crosses the third metacarpal corresponds to the lowest part of the superficial palmar arch.

The *third* and lowest starts from the ulnar border of the hand and extends transversely across the palm, to end at the base of the first interdigital elevation. This crease is caused by the flexion of the three inner fingers. When the hand is strongly flexed, the second and third furrows are merged into one transverse palmar furrow, which corresponds to the metacarpophalangeal articulation of the fingers, and serves as a landmark in disarticulating the corresponding digits.

The palm of the hand is divided into three distinct regions corresponding to the thenar eminence, the hypothenar eminence, and the "hollow of the hand."

The **thenar eminence** occupies the radial side of the palm opposite the base of the thumb. It is composed of the short muscles of the thumb. The skin is finer and less adherent than that covering the hollow. It is circumscribed by aponeurosis,

which separates it from the hollow of the hand and forms a distinct region. Infection of this region is usually limited by the aponeurosis and prevented from spreading into the hollow of the hand.

The **hypothenar eminence** occupies the ulnar side of the palm, opposite the base of the little finger. It is composed of the short muscles of the little finger. The skin is thick and very adherent. It is also circumscribed by aponeurosis, which separates it from the hollow of the hand, converts it into a distinct region, and prevents pus from passing into the hollow.

The **hollow of the hand** is situated between the two eminences. It is triangular in shape, with the base below and the apex at the wrist. It is the *dangerous region of the hand* because of the important structures it contains and the fact that, above, it communicates with the flexor tendons of the forearm and below with the flexor tendons of the fingers.

The skin in this region is so thick and adherent that it is with difficulty that a skin flap is dissected from the palm. It contains no hair follicles or sebaceous glands; hence, we do not get furuncles here, as on the dorsal surface. There are, however, in the skin of the palm, more sweat-glands than in any other part of the body.

The skin of the palm is frequently the site of callosities, underneath which a bursa may sometimes form, becoming infected and resulting in superficial abscess. These abscesses should always be opened by vertical incisions, parallel with the principal structures, always keeping in mind the position of the palmar arch.

The subcutaneous tissue is very dense and serves as a cushion to facilitate the grasp of the hand and minimize the effect of pressure.

The superficial palmar fascia is thin and serves to closely connect the skin with the deep fascia by fibrous septa in which are lodged pellets of fat, just as we find it in the scalp and the sole of the foot.

It will be noted that the carpal bones are so articulated that they form a deep groove. Across this groove, like the string of a bow, is stretched the *anterior annular ligament*, converting the groove into a canal, beneath which pass the flexor tendons of the sublimis and profundus digitorum, the tendon of the flexor longus pollicis, and the median nerve. It is attached internally to the pisiform bone and the hook of the unciform, externally to the tuberosity of the scaphoid and anterior

surface of the trapezium. This ligament is continuous above with the deep fascia of the forearm, of which it is a thickened band, and below with the palmar fascia. Through this carpal canal the structures of the hand communicate with those of the forearm and constitute a region of great surgical importance.

The **deep palmar fascia** is dense and unyielding, and is well developed in the hands of mechanics, or those who handle tools. This fascia may be regarded as an expansion of the tendon of the palmaris longus which merges into the fascia at its central portion.

The palmar fascia may be divided into a central and two lateral portions. The central portion is the strongest, occupies the middle of the palm, and is triangular in shape. Its apex is above and continuous with the palmaris longus tendon, its base is below and corresponds to the heads of the four inner metacarpals; here it divides into four slips for the four fingers (sometimes there is a fifth going to the thumb—Keen).

If we forcibly extend the hand we note at the root of the fingers that there are four vertical depressions, between which are three elevations. The vertical depressions are due to the four fascial slips and the three elevations to the adipose tissue which bulges out between them.

Each of these four fascial slips divides to permit the flexor tendons of the finger to pass through, and the ends are inserted into the sides of the bases of the first phalanges and the transverse metacarpal ligament. Thus, the flexor tendons of the fingers are held in position by fascial rings. In the space between the four fascial slips pass the digital vessels and nerves, and the tendons of the lumbricales.

The palmar fascia is connected above with the skin by fibrous septa in which are lodged pellets of fat; below it is the great palmar bursa.

From either side of the central portion are given off fibrous partitions, which dip down into the palm and join the deep transverse fascia, which covers the metacarpals, the interossei muscles, and the deep palmar arch.

The two lateral portions of the palmar fascia are the external or thenar fascia, which covers the muscles of the thenar eminence, and the internal or hypothenar fascia, which covers the muscles of the hypothenar eminence. Thus, we find the palmar fascia divides the structures of the palm into three separate regions, corresponding each to the three portions of the palmar fascia.

The "hollow of the hand" is converted by the deep palmar fascia into a compartment closed on the sides but open at each end, so that it communicates at one end with the flexor muscles of the forearm and at the other with the flexor tendons of the fingers.

Pus beneath the deep palmar fascia never makes its way through this dense fascia; hence, we *never find the symptoms of inflammation in the palm.* The pus burrows in the line of least resistance, either along the flexors of the forearm, or those of the fingers. It may also penetrate the interosseous spaces and appear upon the dorsum of the hand.

FIG. 163.—DUPUYTREN'S CONTRACTION.

The cause of inflammatory symptoms on the back of the hand is frequently found in the palm.

In opening a palmar abscess great caution should be used to avoid the palmar arches. The direction which the pus may burrow should be kept in mind and counteropenings made accordingly. Even the anterior annular ligament may have to be divided to secure the proper drainage, although such a procedure would naturally result in weakening the power of the hand.

Dupuytren's contraction is characterized by a contraction of the palmar fascia, especially its digital slips (Fig. 163). The fascial bands gradually contract until the fingers are bent upon the palm. The ring finger is most frequently involved. It seems to develop in patients with a gouty diathesis. Subcutaneous division of the contracted band is not always successful, as relapse may occur. Complete excision of the contracted band gives the best results.

The **superficial palmar arch** lies immediately beneath the palmar fascia and rests upon the tendons of the flexor sublimis and the digital branches of the median and ulnar nerves. It is formed by the ulnar artery anastomosing with the superficialis volæ, a branch of the radial. The convexity of the arch is directed toward the fingers, from which are given off four digital branches. The position of this arch is shown by a transverse line drawn across the palm, from a point where the web of the abducted thumb joins the palm (Fig. 164).

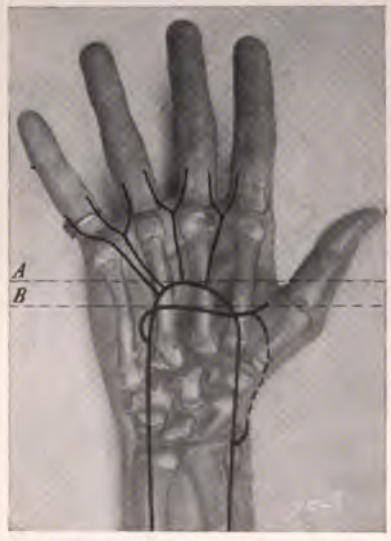

FIG. 164.—THE LINES OF (*A*) THE SUPERFICIAL AND (*B*) DEEP PALMAR ARCHES.

The *flexor tendons in the palm* form two superimposed layers, the four tendons of the sublimis in front, the four tendons of the profundus behind.

To the tendons of the deep flexors in the palm are attached the four lumbricales muscles, which pass to the radial side of the corresponding fingers and are inserted into the common extensor tendons opposite the metacarpophalangeal articulation. These muscles flex the first phalanx and extend the other two, and are much used by piano players. The two inner lumbricales are supplied by the ulnar nerve, the two outer by the median.

The **great palmar bursa** consists of two synovial sheaths which envelop the flexor tendons. The radial sheath invests the tendon of the flexor longus pollicis. The ulnar sheath invests the tendons of the flexor sublimis and profundus digitorum (Fig. 165). These bursæ extend into the forearm for about an inch above the annular ligament and are separated by the median nerve; below they extend down to the heads of the metacarpal bones, where they terminate in a blind diverticulum around each pair of tendons, with the exception of those of the thumb and little finger; in each of these two digits the diverticulum is carried on to the last phalanx. In the other three fingers the synovial sheath begins as a

blind pouch, without communication with the palmar bursa (Gray).

From this arrangement we observe that the thumb is provided with its own sheath, communicating with the radial portion of the palmar bursa. The little finger possesses a sheath which communicates with the ulnar portion of the palmar bursa. The three other fingers have a special sheath, which extends only to the metacarpophalangeal articulation and have no communication with the palmar bursa.

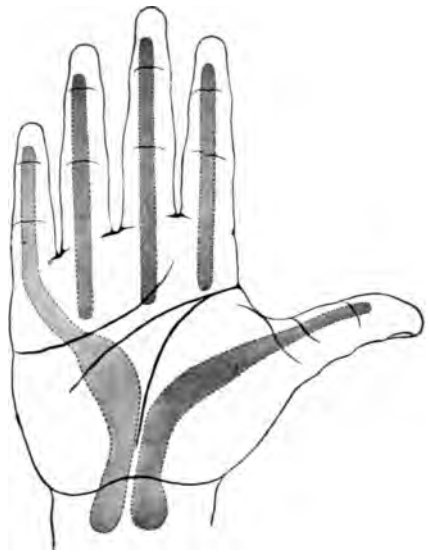

FIG. 165.—THE GREAT PALMAR BURSA.

The two palmar synovial sacs sometimes communicate. Hence, we observe that *infections of the thumb and little finger have graver possibilities than the other fingers.* Pus in the thumb or little finger may, by means of the palmar bursa, reach the forearm.

Amputations of the thumb and little finger are more dangerous than in the other fingers, because the palmar bursa is open to infection.

The two synovial sacs do not, as a rule, communicate at the wrist; exceptionally, however, they communicate with one another beneath the annular ligament. Tillaux has reported a case of infection of the thumb traveling to the forearm, and

thence to the little finger, the three other fingers being exempt. This could be explained by a communication between the two synovial sacs.

When the palmar bursa is distended with fluid or pus it assumes an hour-glass shape, the constriction being caused by the annular ligament.

Compound palmar ganglion is usually due to tubercular inflammation of the palmar bursa. It presents an hour-glass swelling in front of the wrist and the palm of the hand. These cysts contain fibrous concretions resembling melon seeds and give a sensation of crepitation to the examining finger. These ganglia should, if possible, be dissected out, since incision and drainage have been followed by grave complications.

The *deep transverse fascia* is a thin fibrous membrane which covers the metacarpal bones, the interossei muscles, and the deep palmar arch. It is not very resistant to pus, and abscess of the palm finds little opposition in making its way to the back of the hand.

Infections of the palm may be of two varieties:

1. Supra-aponeurotic.
2. Subaponeurotic.

The first usually clears up in a short time and leaves no sequelæ. It has no tendency to spread in the palm or back of the hand. Pain is localized and the fingers can be moved without causing pain. There is no accompanying swelling in the back of the hand.

The *second variety* is always serious. It usually leaves the function of the hand impaired; it may lead to amputation and even compromise the patient's life. The anatomic conditions explain the rapid and ravaging course of pus when it once gets beneath the palmar fascia and into the carpal canal.

It penetrates the interosseous spaces and reaches the back of the hand. *Swelling of the back of the hand is one of the characteristic features.*

The pus passes to the forearm, invades the sheaths, and destroys the tendons. The entire hand becomes immobile. Only large incisions in the palm and forearm and sometimes division of the annular ligament will be of service in arresting the progress of the infection.

The **deep palmar arch** is formed by an anastomosis of the radial artery with the deep branch of the ulnar. It is less curved and more voluminous than that of the superficial arch. It rests upon the interosseous spaces and muscles, and is

situated ½ inch nearer the wrist than the superficial arch (see Fig. 164).

It is much nearer the dorsal surface than the palmar, and is consequently more liable to be wounded by instruments introduced on the dorsal side.

Interossei muscles occupy the intervals between the metacarpal bones. They are divided into two sets, the dorsal and the palmar.

The dorsal interossei are four muscles, which arise by two heads from the adjacent sides of the metacarpal bones and are inserted into the bases of the first phalanges and the aponeurosis of the common extensor tendons.

The **palmar interossei** are three small muscles, the first of which arises from the ulnar side of the metacarpal bone of the index finger and is inserted into the base of the first phalanx and the extensor tendon of the same finger.

The second arises from the radial side of the metacarpal bone of the third finger and is inserted into the base of the first phalanx and extensor tendon of the same finger.

The third arises from the radial side of the fifth metacarpal bone and is inserted into the base of the first phalanx and extensor tendon of the same finger.

The palmar interossei are supplied by the ulnar nerve and their action is to adduct the fingers to which they are attached; that is, draw them toward the median line of the middle finger. They also flex the first phalanx and extend the second and third.

The dorsal interossei are supplied by the same nerve and abduct the fingers from the median line of the middle finger, as well as flex the first phalanx and extend the second and third.

Paralysis of the interossei produces the "claw-hand" or *main en griffe* (see p. 276).

The **dorsal surface of the hand** consists of the skin, subcutaneous tissue, the aponeurosis, and the extensor tendons. The skin is thin and contains hair-follicles and sebaceous glands; hence, the frequency of furuncles.

The subcutaneous tissue is loose and nearly devoid of fat. The laxity of the tissue explains the ease with which it becomes edematous, as compared with the palm where edema is never observed.

The subcutaneous tissue contains a large number of veins, lymphatics, and nerves. The extensor tendons are united by

the aponeurosis and are directly in relation with the dorsal surface of the metacarpal bones.

The **metacarpal bones** are five, numbered in order, starting from the thumb. They form a slight arch with the concavity on the palmar side. The most prominent part of this arch corresponds to the third metacarpal. They articulate above with the second row of carpal bones and below with the first phalanges.

Fractures of the metacarpal bones are not very common. They may be caused directly by a blow upon the back or palm of the hand, or by a crushing force; or, indirectly, by a fall upon the knuckles or a blow with the fist. The deformity is usually slight and the treatment simple, as the metacarpals are so placed that they act as a splint to each other. The third metacarpal is most frequently the site of fracture and it may be due to the fact that it forms the most prominent part of the metacarpal arch.

Dislocations of the metacarpal bones are rare. The most frequent is that of the thumb.

The metacarpal bone of the thumb assumes a place of first importance in the matter of dislocations, since it presents at its extremities two types of dislocations, one of which is easy to reduce, but difficult to retain; the other is very difficult to reduce but easy to retain.

Dislocation of the metacarpal bone backward on the trapezium is rare; it is easy to reduce, but difficult to retain, and recurrences are frequent, unless molded splints of plaster are used to compress the back of the joint.

Dislocation of the phalangeal extremity of the first metacarpal is more frequent. It is very difficult to reduce. but easily retained. Further discussion of this dislocation will be treated in connection with the thumb.

The **fingers** are composed of segments called phalanges. The thumb has two, the fingers three each. They are designated, beginning at the palm, first, second, and third, or proximal, middle, and distal.

The Anterior Surface.—Across the palmar surface of the fingers run transverse folds; the lowest and the middle transverse folds correspond to the interphalangeal joints: the highest transverse fold does not correspond to the metacarpophalangeal joint; it is ¾ inch below it.

Of the three transverse folds on the thumb, the lowest corresponds to the interphalangeal joint, the middle corresponds

to no joint, and the highest crosses the metacarpophalangeal joint obliquely.

These folds form a guide in disarticulating the phalanges.

The skin has the same characteristics as that of the palm. It is dense and vascular and contains no sebaceous glands or hair-follicles. It possesses a great number of sweat-glands and a network of lymphatics. It is endowed with a special sensibility (especially at the pulp)—the sense of touch.

The tactile corpuscles are more numerous and more highly developed than in any other part. The tips of the fingers are about thirty times more acute to the sense of touch than is the skin of the middle of the forearm. The most sensitive portion is the palmar surface of the third phalanx of the index finger, the least sensitive is the dorsum of the hand (Treves).

The subcutaneous cellular tissue is thick and compact and is arranged in compartments to support pressure. This layer contains the vessels and nerves. It is continuous with that of the dorsal surface, but the fascial partitions oppose the propagation of inflammation from one to the other.

The Fibrous Sheath of the Flexor Tendons.—The flexor tendons are enclosed in a fibrous sheath which is attached to the lateral margins of the phalanges, and forms with the bone an osteofibrous canal. In the index, middle, and ring fingers it begins at the metacarpophalangeal articulation and terminates at the base of the distal phalanx, where the tendon of the flexor profundus digitorum is attached. In the thumb and little finger it has the same termination, but below it communicates with the palmar bursa. The fibrous sheath is lined throughout by synovial membrane, which is reflected on the tendon and forms a synovial sac or theca. This sheath is thick opposite the body of the phalanges, but at the level of the joints it is thin and penetrated by vessels which supply the tendon; hence, by means of these openings in the sheath made by the vessels, the subcutaneous cellular tissue freely communicates with the interior of the osteofibrous sheath of the tendons, and inflammatory processes can easily pass from one to the other. The skin, cellular tissue, and fibrous sheath at the first and second phalanges, and the skin, cellular tissue, and periosteum of the third phalanx are so adherent that they practically form one layer.

Paronychia, whitlow, or **felon** are terms usually applied to phlegmon of the terminal phalanx. Phlegmon of the finger may, however, be used to include all infections of the fingers

which, because of the anatomic peculiarities of the part, present certain well-marked characteristics.

(*a*) They usually originate in the cellular tissue, very rarely in the osteofibrous sheath.

(*b*) At first there is little swelling, but intense pain, due to the adherence of the overlying parts, either to the sheath or periosteum.

(*c*) It is a process of peculiar gravity frequently followed by destruction of the tendons and loss of the finger.

(*d*) The entire hand and forearm may be infected, especially when the thumb or index finger is the starting-point.

In the treatment of phlegmon of the fingers early and ample incision is of prime importance. *To wait to find fluctuation is to wait to find the finger in a condition for amputation.*

Early incision relieves the intense pain by relaxing the tissues and diminishing the pressure on the nerves.

It arrests the progress of the infection and prevents involvement of the fibrous sheath or necrosis of the terminal phalanx.

The Flexor Tendons.—The osteofibrous canal is occupied by the superficial and deep tendons. Here they are not superimposed, as at their origin; the sublimis tendons divide at the base of the first phalanx to allow the corresponding profundus tendon to pass through; the two portions then unite to form a grooved channel for the deep tendons and again divide to be inserted into the sides of the second phalanx at about its middle. The deep tendon is inserted into the base of the terminal phalanx.

The tendons are lined with synovial membrane which permits them to act with great freedom.

Trigger finger is a condition of the finger in which flexion or extension is arrested at a certain point. When the obstacle which impedes the movement is overcome, the finger springs back with a jerk. Tillaux believes it is due either to inflammation which diminishes the caliber of the sheath at a certain point or a nodosity of the tendon which encroaches upon the sheath in flexion or extension.

The **dorsal surface of the fingers** consists of skin, cellular tissue, the extensor tendons, periosteum, and bone. The skin is fine and mobile, contains hair-follicles and sebaceous glands, and is, therefore, the site of furuncles. The cellular tissue is loose and devoid of fat, and contains the collateral vessels and nerves.

The main vessels and nerves of the finger run along the

lateral surface and are placed on the sides of the sheath of the flexor tendon.

The arteries rise from the radial for the thumb and radial side of index, and from the superficial palmar arch for the remaining fingers. The digital branches bifurcate at the level of the digital commissure to furnish a branch to the corresponding fingers. The digital arteries furnish branches anteriorly and posteriorly, and some penetrate the fibrous sheath to supply the tendons.

The pulp of the finger is one of the most vascular parts of the body, and cases are reported where the end of the finger, completely separated, has been successfully reunited.

The **extensor tendons** are spread out and form the posterior ligaments for the metacarpophalangeal and phalangeal joints. At the first phalanx they divide into three slips. The middle is inserted into the base of the second phalanx; the laterals pass on and are inserted into the dorsal surface of the last phalanx. A sharp blow on the hand may tear out the insertion of the extensor tendon in the terminal phalanx and result in permanent flexion of the phalanx. The tendon has been successfully reinserted.

The dorsal extremity of the finger is covered by the **nail,** the root of which is lodged in the matrix. The nail is an epithelial product and undergoes certain nutritive changes which vary with the individual's health. Thus the finger-nail may indicate to a certain extent the state of health. Inflammation at the root of the nail frequently follows a blow on the finger giving rise to a "*run-around.*" The matrix, as well as the nail, is usually involved and loss of the nail generally follows.

The Bones of the Fingers.—The three phalanges are articulated by the head of the proximal phalanx being received into the cavity of the distal. Hence, the prominence of the knuckle is made by the heads of the proximal bones, and the joint lies about ¼ inch below the most prominent point of the knuckle. This fact is important in performing amputation of the digits.

The ligaments which unite the phalanges are:

(*a*) The anterior or glenoid, a fibrocartilaginous ligament which serves to increase the receiving cavity and also to act as a means of union. Its palmar surface is grooved for the flexor tendons. Sometimes a sesamoid bone is developed in the ligaments of the index and middle finger. In the thumb

there are two which are constant and are connected with the base of the first phalanx and the head of the metacarpal bone.

(*b*) The *lateral ligaments* are strong bands placed on each side of the joint. They prevent lateral motion.

(*c*) The extensor tendons serve in place of a dorsal ligament.

Hence, it will be observed that disarticulation of the fingers is very simple. When the extensor tendon is cut the joint is opened.

Amputation of the Fingers.—Conservatism is the first consideration in treating crushed and lacerated fingers.

(*a*) See what nature will do first; amputate, if necessary, subsequently.

(*b*) Take the flap wherever you can find it with the least possible shortening of the finger. This applies with even greater force to the thumb. Since the thumb opposes all the other fingers its value in the rôle of prehension is vital. If the thumb be lost the hand is reduced to a hook.

(*c*) In the ideal amputation the flaps should be taken from the palmar side to preserve the sense of touch and to avoid a cicatrix on the anterior surface.

(*d*) Remember that the joint is ¼ inch below the prominence of the knuckle.

Fractures of the phalanges usually occur from direct violence or crushing injuries, consequently they are frequently compound and are apt to be followed by suppuration and necrosis of the fragment. In simple fracture the fragments are easily retained by a moulded palmar splint and the repair is prompt.

Dislocation of the fingers is quite frequent, and, as a rule, easily reduced. There is, however, one of these dislocations which is complicated and deserves special mention—**dislocation of the proximal phalanx of the thumb.** This phalanx is dislocated backward on the dorsum of its metacarpal bone, the head of which forms a prominence on the palmar surface. It is caused by forcing the thumb backward. This dislocation is very difficult to reduce and sometimes an operation is necessary before complete restoration can be obtained (Fig.166).

Anatomic Factors.—(*a*) The flexor brevis pollicis is attached to the base of the first phalanx of the thumb by two tendons, one is inserted into the outer side, the other into the inner side of the base. Moreover, these two tendons are reinforced on one side by the abductor and on the other by the adductor pollicis. When the dislocation takes place the head of the

metacarpal bone is thrust between the two tendons of the flexor brevis and held fast by the tension of these tendons. The more the surgeon pulls on the thumb the firmer will the tendons grasp the neck of the metacarpal bone.

(*b*) The anterior ligament is torn away from the metacarpal bone and accompanies the phalanx in its new position, sometimes interposing between the bones. The lateral ligaments may be torn, or not.

Reduction, if it is to be accomplished without opening the joint, must proceed according to a definite plan, since *the dislocation can never be reduced by pulling on the thumb.*

FIG. 166.—DISLOCATION OF PROXIMAL PHALANX OF THE THUMB.

First—the metacarpal bone should be pressed inward toward the palm, to slacken the tension of the flexor brevis and the abductor and adductor pollicis.

Second—the thumb should be hyperextended and the base of the phalanx pressed downward toward the head of the metacarpal. When the end of the bone is reached the phalanx should be flexed.

Tumors of the Hand.—Lipomata have been observed on the palm of the hand and the fingers. They are of subcutaneous origin; when they arise in the palm there may be some difficulty in diagnosis, since they simulate the compound palmar ganglia.

Cysts.—The palmar surfaces of the fingers are the site of cysts, the pathology of which has been explained by Sutton, who regards them as "sequestration dermoids," caused by the infolding of the skin from a lacerated wound. The contents of these dermoids are the same as the true variety.

Chondromata are found more frequently on the hands and fingers than in any other part of the body, and are usually multiple.

Epithelioma is sometimes found on the dorsum of the hand and is usually due to the degeneration of a wart or cicatrix.

Lymphatics of the upper extremity may be divided into the superficial and deep.

The *superficial lymphatics* begin in the integument of the fingers and palm of the hand and form a rich network which, with a lesser number from the back of the hand, unite to form trunklets which ascend the forearm in company with the superficial veins.

About 2 cm. above the internal condyle is situated the supratrochlear gland, which receives the lymph-vessels which accompany the ulnar vein.

The lymph-vessels which accompany the cephalic vein join the subclavian glands; all the other lymph-vessels pass directly to the axillary glands.

The *deep lymphatics* follow the course of the principal arteries, and finally terminate in the axillary glands.

PART IV

THE ABDOMEN AND PELVIS

CHAPTER XX

SURFACE ANATOMY

EXAMINE the external boundaries of the abdomen—the *ensiform cartilage* and the *costal arches* above, the *crest of the*

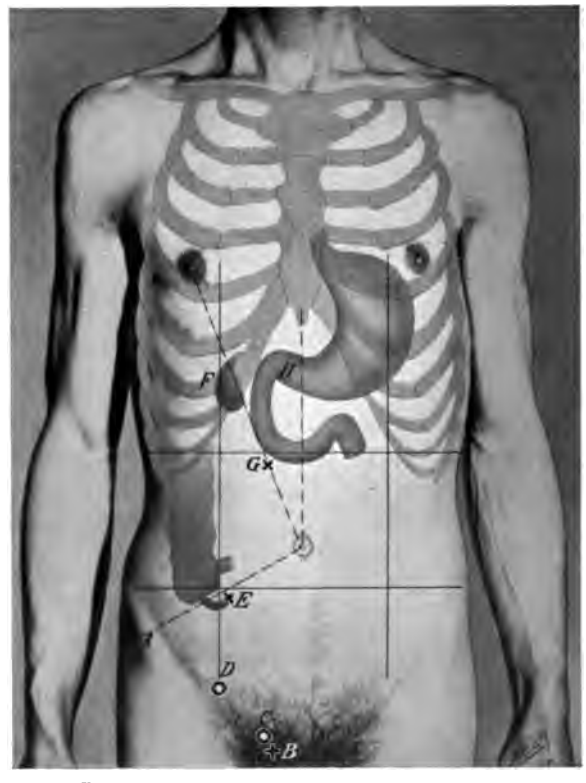

FIG. 167.—SURFACE MARKINGS OF THE ABDOMEN.

A, Anterior superior spine of ilium; *B*, pubic spine; *C*, position of external ring; *D*, position of internal ring; *E*, McBurney's point; *F*, position of gall-bladder; *G*, Robson's point; *H*, position of pylorus.

ilium, *Poupart's ligament*, and the *symphysis pubis* below (Fig. 167). Note that these boundaries are superficial and

give no correct idea of the extent of the cavity within, since the arching of the diaphragm extends the cavity upward beneath the ribs, behind which are lodged important abdominal viscera; downward, the cavity extends below the crest of the ilia into the iliac fossæ, and continues below into the pelvic cavity.

The *umbilicus* is situated below the midpoint of the abdomen, but its position varies with the laxity of the abdominal walls. It is approximately opposite the disc between the third and fourth lumbar vertebræ.

Palpate the *anterior superior spine of the ilium* (Fig. 167, *A*). It is an important landmark; it can always be distinguished even in the stoutest subject; it is the fixed point from which measurements of the lower extremity are made.

The **pubic spine** may be felt on either side of the symphysis pubis (Fig. 167, *B*); if the overlying fat prevents its recognition invaginate the scrotum and pass the finger along the cord and feel the spine to the inner side, or abduct the leg and follow to its termination the prominent tendon of the adductor longus muscle. The pubic spine is an important landmark in the differentiation of femoral and inguinal hernia. The former lies below and external to the spine, the latter above and internal.

Poupart's ligament extends from the anterior superior spine of the ilium to the spine of the pubis. In a general way it corresponds to the fold of the groin.

Palpate the **external abdominal ring** by invaginating the scrotum and passing the finger over the cord to a point above the crest of the pubis (Fig. 167, *C*). It normally admits the tip of the index finger, although a larger ring would not necessarily indicate an abnormal condition.

The **internal abdominal ring** is situated about ½ in. above the midpoint of Poupart's ligament (Fig. 167, *D*). Between the internal and external rings is the line of the inguinal canal.

The *linea alba* is the aponeurotic line of junction between the two recti muscles extending from the ensiform cartilage to the pubes; above the umbilicus it is marked by a distinct groove, below the umbilicus there is no surface marking. Through this line the abdomen may be opened without the division of muscle or the incising of any vessel of importance.

The **recti muscles** on each side the linea alba stand out prominently in well-developed subjects when thrown into action

The **linea semilunaris** marks the outer boundary of the

recti muscles, extending from the tip of the ninth costal cartilage to the pubic spine.

The **lineæ transversæ** are three transverse depressions crossing the recti muscles, one opposite the ensiform cartilage, one opposite the umbilicus, and the third between the two. The lowest of these lines is the most distinct.

The **abdomen** may be divided for the sake of convenience into a number of regions, but the topographic importance of these subdivisions in locating the abdominal viscera is of limited value. The surface of the abdomen is divided into nine regions by two vertical and two horizontal lines. The two vertical lines are erected from the midpoint of Poupart's ligament, the upper horizontal line is drawn between the lowest

FIG. 168.—*A*, THE TRIANGLE OF PETIT.

points of the costal arch, the lower horizontal line is drawn between the highest points of the iliac crest (see Fig. 167).

The subdivisions of the upper zone are the right hypochondriac, the epigastric, and the left hypochondriac regions; the middle zone—the right lumbar, the umbilical, and the left lumbar region; the lower zone—the right iliac, the hypogastric, and the left iliac regions. The general relations of the viscera to these regions may be seen in Fig. 167.

For practical purposes the following landmarks will prove useful.

The **position of the appendix** is at *McBurney's point*, located on the right side at the midpoint of a line drawn from the umbilicus to the anterior superior spine of the ilium (Fig. 167, *E*).

The **position of the gall-bladder** is located beneath the costal arch at a point where it is crossed by a line drawn from the right nipple to the umbilicus (Fig. 167, *F*).

Robson's point is the point of greatest tenderness in gall-bladder inflammation, and is opposite the junction of the middle and lower thirds of a line drawn from the right nipple to the umbilicus (Fig. 167, *G*).

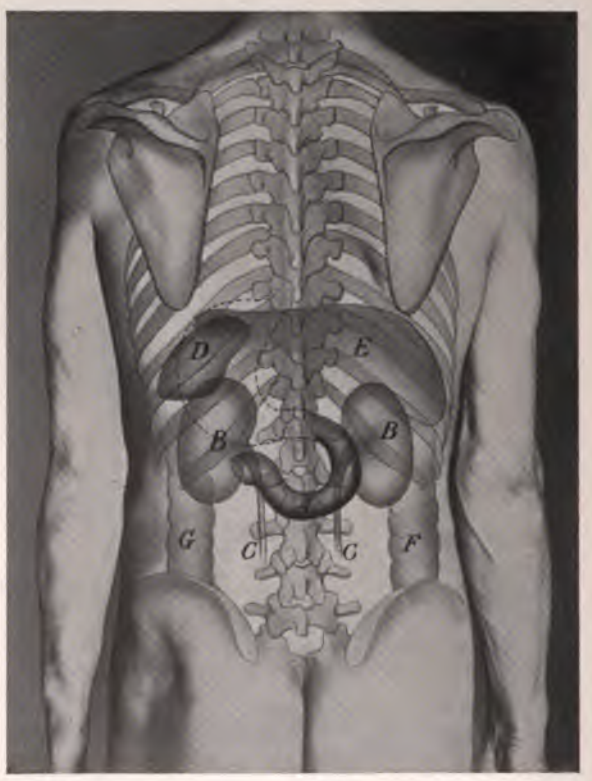

FIG. 169.—SURFACE MARKINGS OF THE POSTERIOR ABDOMINAL WALL.
A, Duodenum; *B*, *B*, kidneys; *C*, *C*, ureters; *D*, spleen; *E*, liver; *F*, ascending colon; *G*, descending colon.

The **position of the pylorus** is located opposite the junction of the upper and middle thirds of a line drawn from the ensiform cartilage to the umbilicus (Fig. 167, *H*).

Posteriorly will be felt the deep furrow in the middle line of the back, at the bottom of which may be palpated the spines of the lumbar vertebræ—on each side are the *erector spinæ*

muscles. Below can be felt the iliac crests terminating in the posterior superior spine. The highest point of the iliac crest corresponds to the fourth lumbar spine.

The **triangle of Petit** is situated immediately above the middle of the crest of the ilium and represents the interval between the external oblique and the latissimus dorsi muscles (Fig. 168).

The **kidneys** lie behind the twelfth rib, about one-third being below the rib. The right kidney is about ¾ in. lower than the left, and the lower pole extends to within 1½ in. of the crest of the ilium (Fig. 169). When the kidney is enlarged or displaced it may be replaced by making deep bimanual pressure in front and behind the costal arch.

The **colon,** both the ascending and descending portions, are in relation with the posterior abdominal wall and may be reached posteriorly through the lumbar region between the crest of the ilium and the last rib (Fig 169, *G* and *F*).

CHAPTER XXI

THE ABDOMEN AND ITS CONTENTS

THE abdomen varies in size and shape with age, sex, state of nutrition, pregnancy, and pathologic conditions affecting its contents.

Note in young children the protuberance of the upper abdomen, due to the relatively large size of the liver and the small size of the pelvis.

In the adult female the lower abdomen is larger, due to the width of the pelvis.

In fleshy people the prominence of the abdomen is due to the deposition of fat—

(*a*) In the omentum and the mesenteric folds.

(*b*) In the subcutaneous layer of the abdominal wall.

In pregnancy, ascites, and certain tumors the abdominal wall is greatly distended—to such an extent that when the distention is relieved there result scar-like lines on the skin, *lineæ albicantes*, due to overstretching of the integument. While these white lines are always observed after pregnancy, it should be remembered that they may occur after the subsidence of any excessive distention.

In wasting diseases the abdomen is retracted and "boat-shaped." In the upper abdomen the depression is most marked, the abdominal wall sinking in so abruptly as to form almost a right angle with the costal arch. In the median line the projecting spine can easily be felt and in some cases seen, forming a median prominence.

Boundaries.—The abdomen is closed above by the diaphragm, below by the pelvic floor, in front by a musculo-aponeurotic wall, and behind by the vertebral column, the lumbar muscles, and the iliac fossæ.

It is customary to divide this cavity into abdomen proper and pelvis, the line of division being the superior strait of the pelvis.

The overlapping of the thoracic and abdominal cavities has already been alluded to. The fact that the arching of the diaphragm causes many of the abdominal viscera to be under cover of the thoracic wall is obvious. The same may be observed in the overlapping of the abdominal and pelvic

cavities. Viscera that properly belong to the abdomen gravitate to the pelvis. Hence, the external boundaries of the abdomen give no adequate idea of its extent within.

The **anterior abdominal wall** is roughly lozenge-shaped, the superior angle at the ensiform cartilage, the inferior angle at the pelvis.

The thickness of the abdominal wall varies according to the subject and age.

The **skin** presents no special characteristics, except that it is loosely attached and capable of great distention, as seen in pregnancy, ascites, and intra-abdominal tumors.

The **superficial fascia** of the abdomen differs from that of other regions because in the lower half of the abdomen it can be *divided into two distinct layers*, between which are the superficial vessels, nerves, and lymphatic glands.

The *superficial layer* contains the subcutaneous fat and is *continuous with the superficial fascia of the thigh, scrotum, and perineum.*

The deep layer is attached to Poupart's ligament and the linea alba.

At the interval between the symphysis and the pubic spine it has no attachment, but passes down to become continuous with the deep fascia of the scrotum.

Note the clinical significance of this peculiar arrangement of the superficial fascia.

(*a*) *Extravasated urine*, upon reaching the scrotum, will pass through the unattached interval of the deep layer and *present upon the abdominal wall above Poupart's ligament*, limited to one side by the linea alba.

(*b*) *Emphysematous conditions* presenting in the abdominal wall after injuries to the chest are limited by the fold of the groin.

The Abdominal Muscles.—The abdominal wall is essentially composed of layers of muscles and their aponeuroses (Fig. 170). Note the fact that—

(*a*) The three lateral muscles (the external and internal oblique and transversalis) are placed so that their muscular bellies cross each other at different angles, an arrangement which gives the greatest amount of strength to the abdominal wall.

(*b*) The fleshy part of these muscles is placed toward the sides, the aponeurotic part in front, and the aponeuroses are so arranged as to form a sheath for the rectus muscle, which

extends on either side of the linea alba from sternum to os pubis.

Thus the anterior abdominal wall forms an elastic and contractile covering admirably adapted for maintaining an equitable pressure and protecting the abdominal contents. When the abdominal muscles lose their tonicity, and there is relaxation of the abdominal support, the viscera gradually sag downward toward the lower part of the abdomen and a condition of *visceroptosis* is produced. A notable example of this is seen in movable kidney.

The abdominal viscera are admirably protected from blows when the muscles are in a state of contraction; thus, when a blow on the abdomen is anticipated the muscles contract and form a firm elastic pad, and, while the abdominal wall may

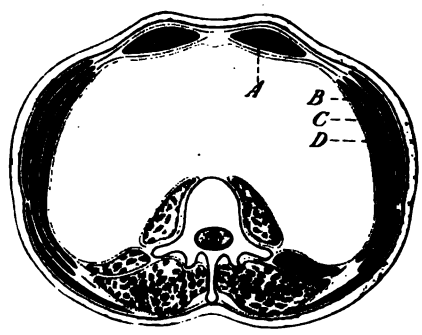

FIG. 170.—TRANSVERSE SECTION SHOWING ARRANGEMENT OF ABDOMINAL MUSCLES. *A*, Rectus; *B*, external oblique; *C*, internal oblique; *D*, transversalis.

be injured, the contents usually escape; when taken unawares, however, the viscera within may be injured, while the abdominal wall presents no sign of injury. *Hence, injuries to the abdomen, like injuries to the head, are to be judged not from the injury to the walls, but from the injury to the contents.*

The *external oblique muscle* consists of a fleshy and an aponeurotic portion—the latter is of special surgical interest. It arises from the outer surfaces of the eight lower ribs by muscular slips which interdigitate with the serratus magnus and latissimus dorsi muscles. Its upper fibers pass obliquely downward and forward and gradually merge into the aponeurotic portion, which passes in front and is inserted into the linea alba; the lower fibers pass from the last rib and are inserted into the outer lip of the ilium, the aponeurosis continuing on

to form Poupart's ligament is attached to the pubic spine and the front of the symphysis.

The **aponeurosis of the external oblique** presents many points of surgical interest:

(*a*) **Poupart's ligament** is formed by a reduplication of its lower border, extending from the anterior superior spine of the ilium to the spine of the pubis. Under this ligament pass the great vessels and nerves to the thigh.

(*b*) **Gimbernat's ligament** is that portion of the aponeurosis of the external oblique which is attached to the ileopectineal line, extending ¾ in. external to the pubic spine. It is a triangular septum with its base free, concave, directed outward, and forms the inner boundary of the femoral ring.

(*c*) The **triangular ligament of the abdominal wall (Colles' ligament)** is an extension of the aponeurosis of the external oblique from the ileopectineal line to the linea alba, where it joins its fellow of the opposite side. It is situated in front of the conjoined tendon, the rectus, and pyramidalis muscles (Deaver).

(*d*) The **external abdominal ring** is a triangular gap in the aponeurosis of the external oblique situated above and to the outer side of the crest of the os pubis. It is the outlet of the inguinal canal. It transmits the spermatic cord in the male and the round ligament in the female.

(*e*) This aponeurosis is of special concern to the surgeon, because it corresponds to that part of the abdomen which is opened most frequently in operations; hence in abdominal operations the first important layer which the surgeon meets after incising the skin is the white, glistening aponeurosis of the external oblique.

The **internal oblique muscle** arises from the outer half of Poupart's ligament, the anterior two-thirds of the middle lip of the crest of the ilium, and the lumbar fascia. The general direction of its fibers is upward and inward (directly opposite to those of the external oblique).

Make special note of the insertion of this muscle:

(*a*) The upper fibers are inserted into the lower borders of the last three ribs.

(*b*) The middle fibers, forming the larger portion of the muscle, merge into an aponeurosis which at the outer border of the rectus muscle splits into two layers; the anterior passes in front of the rectus with the aponeurosis of the external oblique, the posterior passes behind the rectus with the trans-

versalis fascia, and the two layers unite in the linea alba. Thus the two layers of the internal oblique aponeurosis form a sheath for the rectus muscle, *except at its lower fourth, where it is deficient posteriorly.* This is due to the fact that the aponeuroses of all the three muscles pass in front of the rectus at this point. The lower concave margin, where the posterior sheath ends, is known as the *semilunar fold of Douglas.*

(*c*) The fibers which arise from Poupart's ligament *arch over the spermatic cord* and, joining the tendon of the transversalis, form the *conjoined tendon,* which is inserted into the crest of the os pubis and the adjoining portion of the iliopectineal line.

(*d*) The lowest fibers of the internal oblique pass along the outer side of the spermatic cord and through the external ring, forming a series of muscular loops of different length in front of the cord, reaching as low as the testicle. These loops are united by areolar tissue and are inserted into the crest of the os pubis. They form the *cremaster muscle* and *fascia,* and its action may be observed in the retraction of the testicle when the skin of the scrotum is irritated.

The **transversalis muscle** forms the third and innermost layer of the abdominal muscles. It *arises* from the inner surface of the lower six ribs, where it interdigitates with the diaphragm, from the anterior three-fourths of the inner lip of the crest of the ilium, and from the outer third of Poupart's ligament. In front the muscle merges into a broad aponeurosis, the upper three-fourths of which passes behind the rectus with the posterior layer of the internal oblique; the lower fourth passes in front of the rectus. It is inserted with its fellow at the linea alba.

The lower fibers of this muscle, with the internal oblique, form the conjoined tendon, which is inserted into the crest of the os pubis and the pectineal line.

The **rectus abdominis** is a long, flat muscle situated in front of the abdomen on each side of the linea alba and enclosed in a sheath formed by the lateral abdominal muscles.

It *arises* by two tendons, the outer attached to the crest of the os pubis, the inner to the front of the symphysis. As it ascends it becomes broader and is inserted into the fifth, sixth, and seventh costal cartilages. Note the tendinous intersections which cross the muscle—*lineæ transversæ.* There are usually three of these, one at the umbilicus, another at the ensiform cartilage, and a third midway between the two.

These tendinous intersections are intimately adherent to the sheath of the muscle in front, but not behind; *hence, pus formed in front of the rectus would be limited by these intersections, pus behind the rectus might traverse its entire length.*

The **pyramidalis** is an inconstant muscle. It is triangular in shape, lying in front of the rectus and in the same sheath. It arises from the front of the os pubis, and is inserted into the linea alba midway between the os pubis and umbilicus.

The **transversalis fascia** is a thin membrane lying between the transversalis muscle and the properitoneal fat. Above the umbilicus it blends with the fascia on the under surface of the diaphragm, below it becomes quite thick and dense, supplying a posterior sheath to the rectus below the semilunar fold of Douglas. It is attached to the inner lip of the iliac crest and the outer half of Poupart's ligament, being continuous with the iliac and pelvic fasciæ. Beneath the inner half of Poupart's ligament it is continued into the thigh in front of the vessels to form the anterior wall of the femoral sheath.

The point at which the spermatic cord in the male and the round ligament in the female pass through this fascia is called the **internal abdominal ring,** which may be located ½ in. above the center of Poupart's ligament.

The thin funnel-shaped fascia, which is prolonged from the circumference of the ring into the inguinal canal, is known as the *infundibuliform fascia.*

The **subperitoneal connective tissue** is a layer of loose areolar tissue which connects the peritoneum with the walls of the abdomen. It presents several characteristics which are of practical importance:

(*a*) It varies in thickness in different regions. In the lumbar region it is plentiful where it provides an investment for the kidney (the perirenal fat). Along the linea alba it is thin, binding the peritoneum and transversalis fascia closely together.

(*b*) It descends along the inguinal canal and forms a delicate investment for the spermatic cord.

(*c*) It extends into the femoral canal, forming the *septum crurale.*

(*d*) It connects those viscera which have an incomplete peritoneal investment with the adjacent abdominal wall, such as the kidneys, liver, pancreas, and portions of the colon, rectum, and bladder.

(*e*) Note that between the blood-vessels of the above organs and the vessels of the adjacent abdominal walls there is an anastomosis established in the subperitoneal tissue, which explains the value of cupping and leeching in hepatic and renal congestion.

(*f*) The looseness of this tissue permits the peritoneum to be readily stripped up and makes possible extraperitoneal operations on the iliac vessels, the ureter, etc. It also favors the spread of abscess, which may burrow from one end of the abdomen to the other.

Arteries of the abdominal wall are derived from the internal mammary, the epigastric, the intercostals, the lumbar, and deep circumflex iliac arteries.

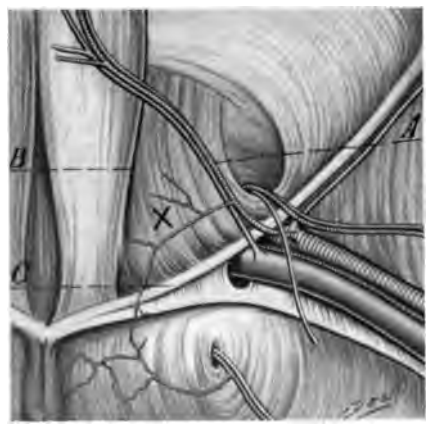

FIG. 171.—SHOWING HESSELBACH'S TRIANGLE (SEEN FROM WITHIN THE ABDOMEN). *X*, HESSELBACH'S TRIANGLE.
A, Deep epigastric artery; *B*, outer margin of rectus; *C*, Poupart's ligament.

The **deep epigastric artery** is clinically the most important artery of the abdominal wall. It arises from the external iliac just before this vessel passes under Poupart's ligament. It ascends obliquely inward *along the inner margin of the internal abdominal ring*, lying between the transversalis fascia and the peritoneum. It enters the sheath of the rectus muscle just below the semilunar fold of Douglass, and ascends on the posterior surface of the muscle to above the umbilicus, where it anastomoses with branches from the internal mammary.

Note the following points:

(*a*) *Its relation to the internal abdominal ring;* it passes along

the lower and inner side of the internal ring and is closely related to the posterior wall of the inguinal canal.

(*b*) The vas deferens in the male and the round ligament in the female cross the artery as it passes to the inner side of the internal ring.

(*c*) It forms one of the sides of *Hesselbach's triangle,* which is completed by the outer margin of the rectus muscle and the inner half of Poupart's ligament (Fig. 171). Through this triangular space a direct hernia protrudes.

(*d*) It forms an anastomosis with the internal mammary artery, the only anastomosis between the vessels of the upper and lower extremities.

This artery should be avoided in abdominal incisions. When operating in its vicinity it should be identified before opening the peritoneum and drawn to one side or divided between ligatures. Unless such precautions be observed profuse hemorrhage may result and the escape of blood into the abdominal cavity obscure the source of the hemorrhage.

The **veins** in the deeper layers follow the course of the arteries. The superficial veins are very numerous, anastomosing with the thoracic veins and undergoing considerable dilatation in the presence of an obstructed circulation, either in the portal or general venous systems.

In the *radical cure of ascites* arising from cirrhosis of the liver the operation is designed to relieve the obstructed portal system by suturing the omentum to the parietal peritoneum, with the hope of establishing adhesions containing new vessels through which an accessory circulation may be established between the portal and general venous systems.

The Lymphatics.—The superficial lymphatics originating above the umbilicus empty into the axillary ganglia, those from below the umbilicus into the ganglia of the groin. The deep lymphatics follow the course of the principal blood-vessels. In the lower half they are drained by the external iliac glands, above they are drained by the internal mammary glands.

The Nerves.—The abdominal wall is supplied by the six lower intercostal nerves and two branches of the lumbar plexus, the iliohypogastric and the ilio-inguinal. These nerves run between the internal oblique and the transversalis to the outer margin of the rectus muscle; they pierce its sheath and supply the rectus, terminating in the skin of the anterior abdominal wall. *Thus these nerves supply the muscles of the*

abdomen and the skin overlying the muscles. Furthermore, these nerves are intimately connected with the thoracic sympathetic ganglia from which the splanchnic nerves are derived, which go to the great plexuses that supply the abdominal viscera and the peritoneum which covers them. Hence, as Hilton observed, *the same nerves that supply the peritoneum supply the abdominal muscles and the skin overlying these muscles.*

Clinical Considerations of the Nerve Supply of the Abdominal Wall.—Keeping in mind the fact that the same nerves supply the abdominal skin, the abdominal muscles, and the abdominal viscera, and that six of these nerves are thoracic in origin, note the following practical points:

(*a*) "The sensitive skin acts the part of a sentinel." At the approach of danger the abdominal muscles rigidly contract to protect the underlying viscera. A cold hand placed upon the abdomen causes the muscles to contract. This fact should be remembered when palpating the abdomen.

(*b*) When the abdominal viscera are injured or peritonitis is present the abdominal muscles become rigid, the cutaneous nerves extremely sensitive, the respiration entirely thoracic, and thus nature attempts to put the injured or inflamed parts completely at rest.

(*c*) In spinal caries pressure on the nerve trunk produces pain at the periphery; thus *children with Pott's disease frequently complain of pain in the belly.*

(*d*) Diaphragmatic pleurisy is often accompanied by symptoms simulating the "acute abdomen" because of the reflected abdominal pain and muscular rigidity.

Congenital Defects of the Abdomen.—Imperfect development of the anterior abdominal wall may result in the absence of a portion of the wall, so that the viscera are exposed and unprotected; or a lack of union in the median line may be evidenced by a congenital hernia, which may vary from one of small size to a protrusion containing all the movable viscera.

Exstrophy of the bladder is due to an arrest of development of the lower part of the abdominal wall, resulting in an absence of the anterior wall of the bladder, so that the mucous membrane of the posterior wall is thrust forward on a level with the skin. This defect is usually associated with absence of the symphysis pubis, with epispadias in the male and a division of the clitoris in the female.

Injuries of the Abdominal Wall.—*Injuries of the abdomen, like injuries of the head, are important, not because of the injury*

to the walls of the cavity, but because of the injury to the contents of the cavity. Thus contusions of the abdomen may be complicated by rupture of the viscera and the latter may be present with no mark of injury on the abdominal wall.

No contusion of the abdomen is trivial until injury to the viscera has been excluded.

Wounds of the abdomen are important or not as they are penetrating or nonpenetrating.

No wound of the abdomen is trivial until injury to the viscera has been excluded.

Abscesses of the abdominal wall may be (*a*) *subcutaneous,* usually small and circumscribed, originating in a sebaceous gland.

(*b*) *Intermuscular.* The various muscular layers forming the abdominal wall are separated by cellular tissue, and infection introduced through a wound may easily spread between the muscular planes. Tubercular abscesses originating in spinal caries may take this course.

(*c*) *Subperitoneal,* usually due to inflammatory conditions of the abdominal viscera, such as a suppurative appendicitis, an adherent gall-bladder, pelvic cellulitis, etc. The subperitoneal tissue is extremely lax, and consequently suppuration may extend over a wide area.

The **umbilical region** consists of a central cicatrix (the umbilicus), which marks the site of the umbilical ring through which the placental vessels pass in intra-uterine life, and the abdominal wall immediately adjacent to the ring.

The umbilical cicatrix contains the remains of the two hypogastric arteries, the umbilical vein, the vitello-intestinal duct, and the urachus.

On the peritoneal surface may be seen the four cord-like remains of these structures, diverging as they leave the umbilicus.

The *umbilical vein,* forming the round ligament of the liver, passes upward.

The *urachus* passes downward in the median line.

The *two hypogastric arteries* pass obliquely downward toward the sides of the bladder.

The obliterated urachus and hypogastric arteries pull the umbilical scar downward and backward as the abdomen increases in height; thus the upper part of the ring is weakened, and becomes the most frequent site of umbilical hernia. Should the urachus remain patent an umbilical fistula results through

which urine is discharged. If the urachus be closed at its two extremities while the intermediate portion remain patent, a *cyst of the urachus* may result which may simulate an ovarian cyst. Should the vitello-intestinal duct fail to become obliterated it forms a process similar to the appendix, known as *Meckel's diverticulum*, which is attached to the ileum in the vicinity of the ileocecal valve, and may give rise to certain conditions of great practical interest to the surgeon. For example:

(*a*) It may remain patent and attached to the umbilicus, forming a fistula which discharges feces at the navel.

(*b*) It may be closed, but retain its connection with the umbilicus and become a source of danger by causing acute intestinal obstruction.

(*c*) Its distal extremity may become adherent to a neighboring part and form a loop through which a coil of intestine may become constricted (Taylor).

Umbilical Hernia.—In considering hernial protrusions through the umbilical cicatrix, the following primary facts should be recalled:

(*a*) Imperfect development of the abdominal wall may leave a median gap which may persist after birth.

(*b*) For a short time after birth the umbilical vessels correspond to the center of the ring, so that hernia (infantile) at this time penetrates the center of the cicatrix.

(*c*) Later on, the obliterated vessels no longer correspond to the center, but to the inferior border of the ring which is drawn inward; the superior border being free. Hence adult umbilical hernia protrudes through the superior portion of the ring.

(*d*) The skin and peritoneum are intimately adherent to the circumference of the ring; in the center the two structures are in contact; hence, the sac and skin are so intimately blended that they are practically inseparable.

Umbilical hernia may be divided into three distinct varieties:

(1) *Congenital umbilical hernia*, due to imperfect development of the abdominal wall. At birth a coil of intestine may work its way among the structures of the cord and be accidentally cut when the cord is divided. A *suspiciously bulky cord should suggest this possibility*, and never be divided near the abdominal wall until after the presence of the gut has been excluded.

(2) *Infantile umbilical hernia* usually occurs a few days or weeks after birth, before the cicatrix has firmly closed the

ring. This condition is due to excessive coughing, crying, straining imposed by constipation or phimosis. Its cure consists in its permanent reduction by the application of a proper pad until cicatricial contraction has finally closed the ring.

(3) *Acquired umbilical hernia* occurs at some period after the umbilical ring has closed. *Obesity is the chief etiologic factor.* The subperitoneal fat gradually distends the superior or weak portion of the ring and the intestine subsequently follows. It most commonly follows in women where the abdominal wall has been stretched and weakened by pregnancy or abdomi-

FIG. 172.—THE INGUINAL REGION.
A, The external ring; *B*, spermatic cord passing through external abdominal ring; *C*, inguinal canal; *D*, position of internal ring.

nal tumors. The layers of such a hernia are purely theoretic. As a practical fact, the tissues become so fused together that they constitute a single layer; hence, it must be kept in mind that the skin incision opens the sac, and due care should be exercised to protect its contents.

The **inguinal region** (Fig. 172) is one of intense interest to the surgeon because of the frequency of hernia, the necessity for its reduction, and the certainty of its radical cure by operative measures.

Furthermore, the radical cure of inguinal hernia consists in a readjustment of the parts composing the inguinal canal;

it is a procedure demanding mechanical reconstruction. Its success depends upon exact anatomic knowledge.

The **inguinal canal** is an oblique passageway traversing the abdominal wall immediately above and parallel to the inner half of Poupart's ligament. Its inlet is the *internal abdominal ring*, situated opposite a point ½ in. above the center of Poupart's ligament. Its outlet is the *external abdominal ring*, just above and to the outer side of the crest of the os pubis. It transmits the spermatic cord in the male and the round ligament in the female. No adequate conception of the inguinal canal is possible without reviewing the evolution of the testicle—its formation within the abdomen, its descent through the abdominal wall, and its final arrival in the scrotum.

Recall the following facts:

(*a*) In the early part of intra-uterine life the testicle lies in the abdominal cavity behind the peritoneum. From this position it migrates through the abdominal wall and eventually reaches the scrotum during the ninth month. This fundamental fact explains at once the rationale of the inguinal canal.

(*b*) Observe that the testicle in its passage through the abdominal wall must deal with each layer of the abdominal wall, and that the resulting inguinal canal which lodges the spermatic cord holds that permanent relation to each layer of the abdomen inagurated by the descent of the testes.

To make this clearer, take each layer of the abdomen from within out and observe what disposition is made as the testicle passes through.

(1) *The Peritoneum.*—The testicle is outside the peritoneum, it is developed behind it; therefore, it is not pushed before the testes. A tube-like process of peritoneum is formed, the *processus vaginalis*, which extends into the inguinal canal, and the testicle descends alongside the processus vaginalis into the scrotum. Subsequently the portion of the processus vaginalis in relation with the testicle becomes the *tunica vaginalis* of the testicle, its upper opening is closed, and the intermediate portion atrophies. In the female this tubular process of peritoneum is prolonged for a short distance into the inguinal canal, forming the *canal of Nuck*.

(2) *The Transversalis Fascia.*—The testicle and cord *pass through* this fascia, forming the *internal abdominal ring* (the inlet of the inguinal canal) which lies opposite a point ½ in. above the center of Poupart's ligament. This ring and the cord transmitted is covered by a funnel-shaped prolongation

of the transversalis fascia known as the *infundibuliform fascia.*

(3) *The Internal Oblique.*—The testicle and cord *pass beneath* the arching fibers of the internal oblique muscle, and the cord at this point is surrounded by the cremasteric fascia.

(4) *The External Oblique.*—The testicle and cord *pass through* the aponeurosis, forming the *external abdominal ring* (the outlet of the inguinal canal)—a triangular gap situated just above and to the outer side of the os pubis. The diverging fibers of the aponeurosis form its internal and external pillars. The *intercolumnar fascia* is attached to the margins of the pillars and closes the external abdominal ring.

With the descent of the testicle into the scrotum there was carried with it the spermatic vessels and vas deferens, which form the spermatic cord occupying the inguinal canal. In addition the inguinal canal transmits the *ilio-inguinal nerve,* which lies in front of the cord, and the *genital branch of the genitocrural* nerve, lying behind the cord.

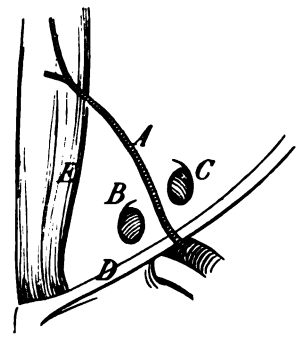

FIG. 173.—RELATIONS OF THE DEEP EPIGASTRIC ARTERY TO THE ABDOMINAL RINGS.

A, Deep epigastric artery; *B*, external ring; *C*, internal ring; *D*, Poupart's ligament; *E*, rectus muscle.

The formation of the inguinal canal being well understood, observe now its relations:

In front, the aponeurosis of the external oblique and in addition the internal oblique in its outer third.

Behind, the conjoined tendon and the transversalis fascia.

Above, the arched fibers of the internal oblique.

Below, the groove formed by the union of the transversalis fascia with Poupart's ligament.

The *relation of the deep epigastric vessels* is a matter of great importance to the surgeon. They traverse the subperitoneal tissue between the transversalis fascia and the peritoneum, passing behind the canal, immediately *internal to the internal abdominal ring* (Fig. 173).

The intimate relation of these vessels to a hernia traversing the internal ring is obvious.

The Peritoneal Fossæ.—When the anterior abdominal wall is viewed from within it will be observed that there are

certain depressions or fossæ which are bounded by well-marked ridges or folds of peritoneum; one of these folds descends in a vertical line from the umbilicus to the symphysis and represents the obliterated urachus. A second corresponds to the course of the deep epigastric artery, and a third between these two represents the obliterated hypogastric arteries. Two prominent fossæ are observed between these folds. One external to the deep epigastric artery and behind the internal ring, through which an oblique inguinal hernia makes its exit. The

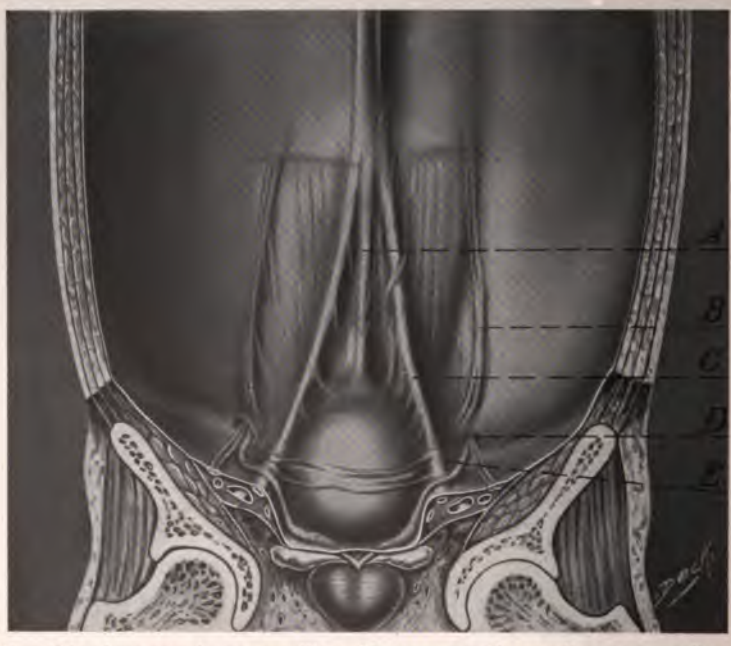

FIG. 174.—ANTERIOR ABDOMINAL WALL, VIEWED FROM BEHIND, SHOWING THE PERITONEAL FOSSÆ. (Adapted from Sobotta.)

A, Obliterated urachus; *B*, fold of deep epigastric artery; *C*, obliterated hypogastric arteries; *D*, fossa at the internal abdominal ring; *E*, fossa behind the external abdominal ring.

second fossa is internal to the deep epigastric artery and behind the external ring; through this fossa a direct inguinal hernia makes its exit (Fig. 174).

Inguinal Hernia.—From the foregoing description it will be readily understood that the inguinal canal not only weakens the abdominal wall, but provides a pathway along which a hernial protrusion may readily travel.

How does the hernia begin? Any excessive intra-abdominal pressure, as from coughing or lifting a weight, or straining at stool, in conjunction with relaxed abdominal walls, may cause the peritoneum to become indented at some weak point, as, for example, the peritoneum back of the internal ring. As the pressure continues the peritoneum is pushed like the finger of a glove through the internal ring and along the inguinal canal, the intestine or omentum filling the peritoneal protrusion. This process may continue until the hernia traverses the entire canal and finally exits through the external ring and into the scrotum. This, in general, is the progress of a hernia through the inguinal canal, and in its essential features is typical of all varieties.

FIG. 175.—COMMON SCROTAL HERNIA. *A*, Hernial sac; *B*, tunica vaginalis.

FIG. 176.—CONGENITAL HERNIA. *A*, Tunica vaginalis.

Observe that the herniated bowel is always contained in a "sac," which is formed of the peritoneum which the gut pushes before it in its descent.

In a congenital hernia, however, the sac already exists in the form of an unobliterated vaginal process communicating with the peritoneal cavity.

Varieties of Inguinal Hernia.—Inguinal hernia may be divided into two classes:

(1) **Oblique hernia** passes through the internal abdominal ring and traverses the inguinal canal. It is external to the deep epigastric artery.

Oblique hernia is incomplete when it does not pass beyond the inguinal canal, and the term bubonocele is then applied,

because of the swelling at the usual site of a bubo. It is *complete* when it passes through the inguinal canal and external ring.

Oblique hernia may be congenital or acquired.

Congenital inguinal hernia does not imply that the hernia exists from birth. It may occur at any period. It refers to a *congenital anatomic peculiarity*, viz., an *unobliterated vaginal process* communicating with the peritoneal cavity, into which a hernia may descend at any moment. It is frequently associated with undescended testicle.

Recall the anatomy of the vaginal process (page 348) and note the varieties of congenital hernia which may occur.

Take as the standard of comparison a common scrotal hernia, as shown in Fig. 175, and observe the points of difference in—

FIG. 177.—INFANTILE HERNIA. A, Hernial sac; B, tunica vaginalis.

(*a*) *Congenital Hernia.*—The vaginal process remains patent throughout and communicates directly with the peritoneal cavity. The vaginal process constitutes the sac into which the gut descends and the gut lies in contact with the testicle (Fig. 176).

(*b*) *Infantile Hernia.*—The upper end of the vaginal process is closed, the rest remains open. A hernia with its peritoneal sac descends behind the vaginal process; hence, there are three peritoneal coverings to this hernia, two of the vaginal process and one of the sac (Fig. 177).

(*c*) *Encysted Hernia.*—The upper end of the vaginal process is closed by a septum, the rest remains open. The gut pushes against the membrane of the septum, and gradually a sac is formed from the septum, which descends into the cavity of the vaginal process and forms a sac within a sac. Hence this hernia is covered by two peritoneal layers—the invaginated septum and the vaginal process (Fig. 178).

(*d*) *Funicular Hernia.*—The vaginal process is open above, but closed near the testicle. A hernia entering this funnel-shaped pouch occupies the upper portion of the vaginal process, which also forms its sac (Fig. 179).

Acquired oblique inguinal hernia is the most frequent variety

of inguinal hernia, and usually occurs during adult life (Fig. 180). It develops slowly and *follows the course of the inguinal*

FIG. 178.—ENCYSTED HERNIA.
A, Hernial sac; *B*, tunica vaginalis.

FIG. 179.—FUNICULAR HERNIA.
A, Hernial sac; *B*, tunica vaginalis.

canal; hence it passes through different stages in its progress toward the scrotum. When confined to the inguinal canal

FIG. 180.—AN OBLIQUE INGUINAL HERNIA.

it is an *incomplete hernia.* As it emerges from the external ring it forms a swelling just above the spine of the pubis termed

bubonocele; after it has descended into the scrotum it is a *complete* or *scrotal hernia.*

(2) **Direct inguinal hernia** passes directly through the abdominal wall and emerges at the external abdominal ring. It passes to the inner side of the deep epigastric artery and through *Hasselbach's triangle,* a space bounded below by Poupart's ligament, internally by the outer edge of the rectus muscle, and externally by the deep epigastric artery (see Fig. 171).

Notwithstanding the straight and short course of this hernia it is less common than oblique inguinal hernia, possibly due to the additional strength contributed by the conjoined tendon lying behind the external ring. It is always an acquired hernia, never congenital.

The **coverings of inguinal hernia** are valuable only as an academic anatomic exercise. They are of no practical interest to the surgeon, and their recognition is neither necessary nor possible.

In *oblique hernia* it is only necessary to recall the structures of the inguinal canal to enumerate the coverings. They are, from within out:

1. Peritoneum.....Forming the sac.
2. Subperitoneal fascia.
3. Infundibuliform fascia.....Covering the internal ring.
4. Cremasteric fascia.....Covering arched fibers of the internal oblique.
5. Intercolumnar fascia.....Covering the external ring.
6. Superficial fascia.
7. Skin.

In *direct hernia* they are, from within out:

1. Peritoneum.....Forming the sac.
2. Subperitoneal fascia.
3. Transversalis fascia.
4. Conjoined tendon.
5. Intercolumnar fascia.....Covering the external ring.
6. Superficial fascia.
7. Skin.

Reduction of hernia by taxis consists in manipulating the hernial mass in such a manner as to return its contents to the abdominal cavity.

Essentials to Successful Reduction.—(*a*) Complete relaxation of the muscles and aponeurosis of the abdominal wall. This is best obtained by laying the patient upon the back with the head and shoulders raised, the thigh of the affected side being flexed and adducted.

(*b*) Elevate the hips in order that the force of gravity may assist in the reduction.

Remember that the external abdominal ring is like a buttonhole; contraction of the external oblique muscle or tension of its aponeurosis approximates its edges; relaxation of the muscles on the other hand gives the ring its greatest width. Extension and abduction of the thigh close the ring; flexion and adduction open it. The patient having been placed in the most favorable position, gentle pressure is made upon the mass. In oblique hernia press in the direction of the inguinal canal; in direct hernia press directly backward. The final reduction of the protrusion is usually accompanied by a gurgling sound.

Herniotomy is performed for the relief of strangulation or for obtaining a radical cure.

In strangulated hernia the essential feature is the relief of the constriction; after this is accomplished it may be possible to effect a radical cure.

Where is the seat of stricture? In an oblique hernia it may be either at the external or internal abdominal ring or in the neck of the sac. In direct hernia it is usually at the external abdominal ring.

In what direction should the constriction be divided? The point here is how to avoid wounding the deep epigastric artery.

Recall the relationship of the two forms of hernia to the deep epigastric artery. Oblique hernia is external, direct hernia is internal to this artery. It is obvious that there are two distinct relationships established by the two forms of inguinal hernia.

Is it necessary, therefore, to distinguish between the two forms of hernia before incising the constriction?

It is neither necessary nor possible.

It is not possible, because in hernia of long standing the constant traction tends to approximate the abdominal rings until the canal looses its obliquity and leads directly backward into the abdominal cavity. In this process the deep epigastric must also be deflected from its normal course.

It is not necessary, because *there is just one direction in which to incise the constriction applicable to both forms of inguinal hernia: Make the incision parallel to the deep epigastric artery; i. e., oblique upward and inward.*

In relieving the constriction *a few small nicks is all that is necessary;* further dilatation may be done with the finger.

The **radical cure of inguinal hernia** is an operation which involves mechanical reconstruction of the inguinal canal. Its aim is to obliterate the old canal, to construct a new track for the cord, and to reduce the rings to a size just sufficient for the transmission of the cord. Its success depends upon accurate anatomic knowledge, exact coaptation of the parts, and complete asepsis. The operation which most satisfactorily meets the anatomic requirements is that devised by Bassini.

The Anatomic Features of Bassini's Operation.—(*a*) After the skin incision in the direction of the inguinal canal has exposed the aponeurosis of the external oblique muscle and the external ring. *The aponeurosis of the external oblique is divided, beginning at the external ring and extending to the level of the internal ring.*

(*b*) *Isolation of the hernial sac from the spermatic cord up to its point of exit from the internal ring.* The elements of the cord are usually spread over the posterior and lateral aspects of the sac.

(*c*) After reduction of its contents, *ligature and excision of the sac close to the internal ring.*

(*d*) Obliteration of the old canal by *suturing the lower margin of the internal oblique muscle to the shelving edge of Poupart's ligament* while the spermatic cord is held out of the wound.

(*e*) Construction of a new track by placing the cord upon the newly-constructed floor and *suturing over it the incised aponeurosis of the external oblique*, leaving an external ring sufficient to transmit the spermatic cord without constriction. The operation is completed by suturing the skin incision.

Inguinal hernia in the female is rather rare, since the inguinal canal in the female transmits a comparatively small structure, the round ligament.

The vaginal process of the male corresponds to the *canal of Nuck* in the female. Congenital inguinal hernia in the female, therefore, descends in the canal of Nuck.

The round ligament has the same relation to the hernial sac as the spermatic cord in the male.

Scrotal hernia in the male corresponds to labial hernia in the female. The coverings of the sac are the same as in the male, with the exception of the cremasteric fascia, which is absent.

The **inguinofemoral region,** or the region of the crural canal, is one of practical interest to the surgeon, principally because it is the site of femoral hernia.

To understand the mechanism of femoral hernia, it is necessary to recall the formation of Poupart's ligament and the structures that pass beneath it in their transit from the abdomen to the thigh.

(*a*) **Formation of the Crural Arch.**—The extension of Poupart's ligament from the anterior superior iliac spine to the spine of the os pubis over the bony concavity beneath forms the *crural arch* (Fig. 181), but further than this, at the pubic spine, the aponeurosis of the external oblique is continued on along the iliopectineal line for $\frac{3}{4}$ in., forming *Gimbernat's ligament.* Note that it is a triangular ligament which fills in and

FIG. 181.—THE CRURAL ARCH.

rounds off the inner angle of the crural arch by its concave outer margin (Fig. 182).

(*b*) **The Structures Beneath the Crural Arch.**—The crural arch is the line of demarcation between the abdomen and the thigh. Beneath the arch certain structures pass from the abdomen to the thigh.

Note that immediately under the outer half of the crural arch the structures are: the *iliopsoas muscle*, with the *external cutaneous nerve* at its outer border, and the *anterior crural nerve* at its inner border.

The structures immediately under the inner half are the crural branch of the genitocrural nerve, the femoral artery,

FIG. 182.—A, GIMBERNAT'S LIGAMENT.

femoral vein, and a *space occupied by a few lymphatics and areolar tissue.* This latter space is the *femoral ring* (Fig. 183).

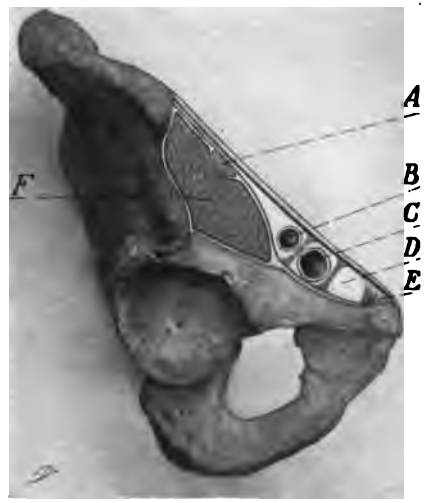

FIG. 183.—THE STRUCTURES BENEATH THE CRURAL ARCH.
A, Anterior crural nerve; *B*, femoral artery; *C*, femoral vein; *D*, femoral ring; *E*, Gimbernat's ligament; *F*, iliopsoas muscle.

(*c*) **The Femoral Sheath.**—The femoral vessels as they pass beneath the crural arch are enclosed in a funnel-shaped

membranous sheath formed by a prolongation of the transversalis fascia in front and of the iliac fascia behind, which passes down to join the pubic portion of the fascia lata, and *ends opposite the saphenous opening.*

The *femoral sheath is divided into three compartments* by anteroposterior fibrous septa; the outer is occupied by the femoral artery, the middle by the femoral vein; the inner is the crural canal (see Fig. 183).

(*d*) The **crural canal** is the narrow interval between the femoral vein and the inner wall of the femoral sheath, or *it is the narrow compartment of the femoral sheath*, about ½ in. in length, extending from the femoral ring to the margin of the saphenous opening. Unlike the inguinal canal, it is a potential canal, and exists only when a hernial protrusion has dissected it from the vein.

Its inlet is the *femoral ring* closed by subperitoneal connective tissue—the *septum crurale;* its outlet, the *saphenous opening*, closed by cribriform fascia; its direction is curved downward and forward (giving the peculiar course to a femoral hernia, forward and upward).

Note here the *relations of the femoral ring:* In front Poupart's ligament, behind the pubic bone, the pectineus, and the pubic portion of the fascia lata, internally by the sharp concave margin of Gimbernat's ligament, externally by the femoral vein.

Especially observe the unyielding character of the structures surrounding the ring; it has an important bearing upon the subject of femoral hernia.

Femoral Hernia.—If the preceding facts have been clearly understood it is obvious that a femoral hernia leaves the abdomen through the femoral ring—the point of least resistance beneath the crural arch—and pushes ahead of it a pouch of peritoneum which forms the hernial sac. After passing through the femoral ring it traverses the crural canal and, if complete, makes its exit through the saphenous opening.

Femoral hernia is always acquired; it is never congenital.

In the presence of a complete femoral hernia, the crural canal presents a very decided curve downward, forward, and upward. Hence, after the protrusion escapes from the saphenous opening, it *rolls upward over Poupart's ligament* in the direction of the anterior superior spine. Therefore, in a superficial examination, the cutaneous appearance of an

inguinal and femoral hernia may be very similar and difficult to differentiate.

Rule.—Find the pubic spine. The neck of a femoral hernia always lies external to the pubic spine.

It occurs more frequently in women than in men, probably due to the greater width of the pelvis, which implies a larger femoral ring. Pregnancy is also a predisposing factor in femoral hernia, due to the overstretching of the structures composing the abdominal walls.

The **coverings of femoral hernia,** while of no great practical importance, are easily appreciated by recalling the fact that the femoral ring is covered by the septum crurale, the saphenous opening by the cribriform fascia. Now follow the course of the hernia from within out, and observe that the coverings acquired are in order:

(*a*) Peritoneum.....The sac.
(*b*) Septum crurale.....Covering of femoral ring.
(*c*) Crural sheath.....Anterior wall of crural sheath.
(*d*) Cribriform fascia.....Covering of saphenous opening.
(*e*) Superficial fascia.
(*f*) Skin.

The Use of Taxis in Femoral Hernia.—If the hernia is recent and soft, taxis may be used with a fair assurance of success. If the hernia is of long standing and tense, taxis is useless and contra-indicated. Remember the unyielding character of the structures surrounding the femoral ring. It explains why taxis is of less value in femoral than inguinal hernia, and why strangulation is more frequent.

Essentials to Successful Taxis.—Position must be such as will completely relax the structures about the femoral ring. Hence, *flex and rotate the thigh inward.*

Direction: In applying taxis recall the direction of the crural canal—it is curved downward and forward—hence taxis should be applied in the reverse direction, *backward* and *upward,* to accomplish reduction.

Herniotomy for Strangulation.—The essential feature for this operation is the relief of the constriction.

Where is the seat of stricture? Gimbernat's ligament with its sharp edge at the inner side of the femoral ring is usually the site of constriction.

In what direction should the constriction be divided? The important structure here to remember is the femoral vein, lying to the outer side of the femoral ring; therefore, *incise*

the constriction inward. The incision is to consist of a *few small nicks* in the sharp edge of Gimbernat's ligament; further dilatation may be done with the finger.

What is to be done in the presence of an anomalous obturator artery passing along the inner border of the femoral ring? (Fig. 184). *The recognition of an anomalous obturator artery is neither possible nor necessary,* and its importance has been much exaggerated.

It is not possible, because the anomalous obturator artery is situated on the posterior surface of Gimbernat's ligament.

It is not necessary if the operator strictly and invariably adheres to the rule of making a few small nicks in the edge of

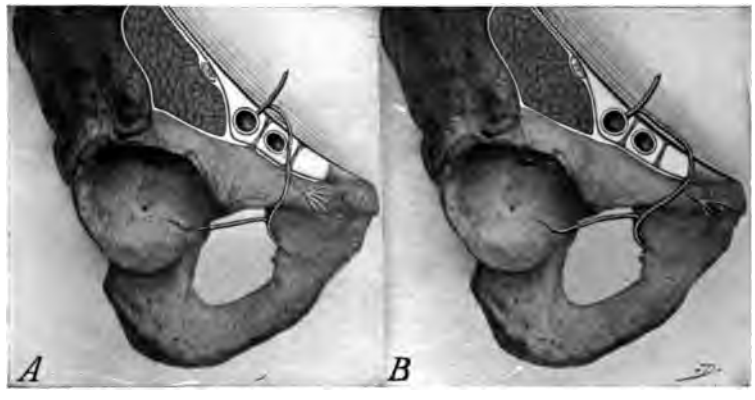

FIG. 184.—VARIATIONS IN THE ORIGIN AND COURSE OF THE OBTURATOR ARTERY. *A*, The obturator artery, external to the femoral ring; *B*, the obturator artery, internal to the femoral ring.

Gimbernat's ligament and then dilating further with the finger. This procedure subjects an anomalous obturator artery to the minimum amount of danger.

Herniotomy for the radical cure of femoral hernia involves (*a*) *obliteration of the hernial sac.* After the sac has been isolated and its contents reduced it is ligated close to the femoral ring and excised.

(*b*) *Closure of the femoral ring* is difficult because of the unyielding character of the surrounding structures. The simplest procedure is to suture the inner end of Poupart's ligament to the pectineal fascia behind. As a matter of experience, if the hernial sac be obliterated any of the various methods for closing the femoral ring will result in a radical cure.

Mechanical reconstruction of the canal plays no part here as in inguinal hernia.

The **posterior abdominal wall** is formed by the iliac fossæ, the lower vertebræ, and the lumbar muscles, which fill the space between the iliac crest and the last rib.

The **iliac fossæ** are bounded by the crest of the ilium, the pelvic outlet, and Poupart's ligament. The right fossa lodges the cecum and appendix, the left the sigmoid flexure. They are lined with peritoneum, which is continuous with that of the anterior abdominal wall. Beneath the peritoneum is the loose *subperitoneal connective tissue* which is continuous with that of the anterior abdominal wall. The looseness and low vital resistance of this tissue favors the spread of abscess, which very frequently originates on the right side in the appendix or may spread from contiguous structures, as seen in pelvic cellulitis.

The arrangement of this layer explains the course which pus in the iliac fossa may take:

(*a*) It may find its way and present upon the anterior abdominal wall.

(*b*) It may diffuse along the sheaths of the vessels, and leave the pelvis by the femoral ring and present on the internal surface of the root of the thigh.

Structures traversing the subperitoneal layer are the external iliac artery and vein, the ovarian or spermatic vessels, the ureter, and the vas deferens. The looseness of this layer permits the peritoneum to be stripped up, and makes possible extraperitoneal operations upon these structures.

The **iliac fascia** is a strong aponeurosis which covers the posterior portion of the abdominal cavity and converts the iliac fossa into an osteofibrous space for the lodgment of the iliopsoas muscle. Its boundary is practically the boundary of this muscle. It is attached above to the internal arcuate ligament, internally to the vertebral column and brim of the pelvis, below to the iliac crest and the outer half of Poupart's ligament. Immediately to the outer side of the femoral vessels the iliac fascia dips down behind them to form the posterior wall of the femoral sheath. It follows the iliopsoas muscle as far as its insertion, where it becomes continuous with the iliac portion of the fascia lata. Behind the iliac fascia is a layer of loose connective tissue which favors the spread of abscess, and the *anterior crural* and *external cutaneous nerves* lying just beneath Poupart's ligament, the former at

a point opposite the center, the latter beneath the outer end of Poupart's ligament.

The **psoas** and **iliacus muscles** fill the osteofibrous space formed by the iliac fascia. Above they are distinct, the psoas arising from the bodies and transverse processes of the last dorsal and lumbar vertebræ and the intervening disks; the *iliacus*, a fan-shaped muscle, arises from the iliac fossa, the crest of the ilium, the iliolumbar ligament, base of sacrum, and anterior superior iliac spine; below, a few fibers come from the anterior inferior spine and the notch between. The fibers converge to be inserted into the outer side of the tendon of the psoas, some of them being attached to the shaft of the femur below the lesser trochanter, its outermost fibers being inserted into the hip-joint (iliocapsularis muscle). The tendon of the psoas passes beneath the crural arch, glides over the capsule of the hip, from which it is separated by a large bursa and is inserted into the lesser trochanter. Thus the action of these two muscles is similar, and they are often called the *iliopsoas*.

The combined *action* of these muscles from above is to flex the thigh on the pelvis; acting from below they assist in raising the body from the recumbent position. They also assist in maintaining the erect position.

The psoas muscle contains within its substance the lumbar plexus; the obturator nerve lies along its inner border; the anterior crural lies between it and the iliacus.

Psoitis is an inflammation of the psoas muscle, to which it is specially prone. Patients suffering from psoitis assume a peculiar and characteristic attitude—the limb is flexed, abducted and rotated outward, and any movement aiming at correction of this position is extremely painful.

Psoas abscess is an abscess within the sheath of the psoas muscle, usually due to tubercular disease of the spine (*Pott's disease*). In caries of the lumbar vertebræ the infection is transmitted directly to the sheath of the psoas; in caries of the dorsal vertebræ the infection travels down in front of the bodies of the vertebræ, and passing beneath the internal arcuate ligament enters the sheath of this muscle.

When pus has formed within the osteo-aponeurotic sheath it descends to the iliac fossa, and thence by a narrow opening it passes beneath Poupart's ligament and reaches the thigh just below the groin, to the outer side of the femoral vessels (Fig. 185).

Tubercular abscess of the spine does not, however, always follow the course of the psoas muscle. It may pass behind the psoas and, traveling backward, point in the lumbar region (lumbar abscess). It may descend into the pelvis and pass through the great sacrosciatic foramen and point on the back of the thigh (Fig. 185). It may pass along the inguinal canal and reach the scrotum.

The **lumbar region** is situated on each side of the vertebral column, in the interval between the last rib and the crest of the ilium.

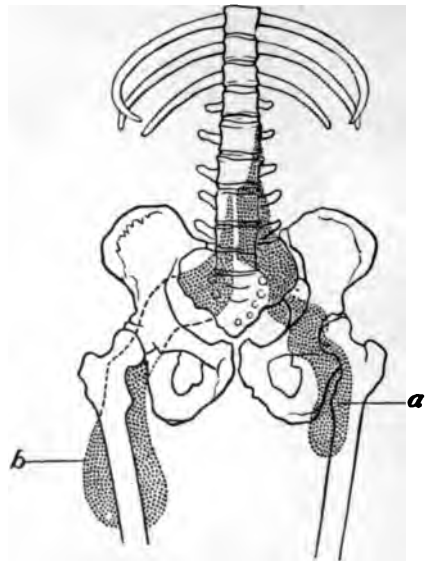

FIG. 185.—SHOWING THE COURSE OF A SPINAL ABSCESS. (After Testut.)
a, Abscess following the course of the psoas muscle and pointing below the groin; *b*, abscess passing through the great sacrosciatic foramen and pointing on the back of the thigh.

The lumbar vertebræ normally form a slight concavity behind. In *hip-joint disease*, when the joint is flexed and fixed, any effort to extend the thigh will markedly increase this concavity and produce *lordosis*. This is due to an attempt to compensate for the fixed flexion by tilting the pelvis, and hence it is a *valuable diagnostic sign of hip disease*.

Lumbar puncture is practised for the purpose of withdrawing cerebrospinal fluid or for producing *spinal anesthesia* by the injection of cocain.

Anatomic Points.—The point selected is the interspace between the third and fourth lumbar vertebræ; the spinal cord terminates at the top of the second lumbar vertebræ, and below this point are the nerves forming the cauda equina.

To find the proper interspace, draw a line connecting the highest points of the iliac crests; it passes through the spine of the fourth lumbar vertebræ (see Fig. 186). Insert the needle into the first interspace above the horizontal line, a little to the side of the median line, and point it slightly upward and inward. When the subarachnoid space is reached the cerebrospinal fluid will begin to flow from the needle.

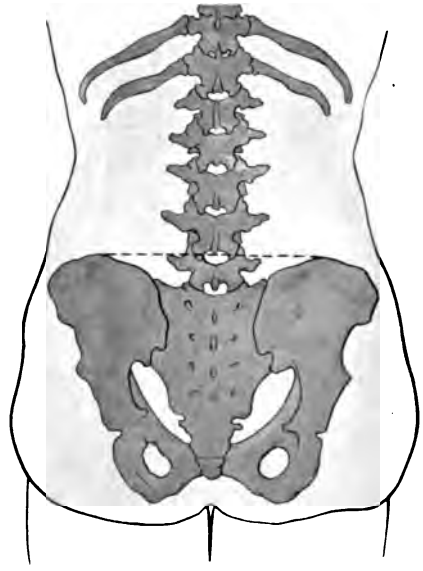

Fig. 186.—Line Between Iliac Crests Indicating Point for Lumbar Puncture.

The Muscles.—Superficially the lumbar region is covered by the latissimus dorsi and external oblique muscles, both of which are attached to the outer lip of the crest of the ilium. While these muscles overlap above, they are separated below by a small triangular interval just above the middle of the iliac crest.

This interval is known as the *triangle of Petit* (see Fig. 168), and represents a weak place in the posterior abdominal wall through which a hernia may present (*lumbar hernia*). Such a hernia

is rare and is easily reduced. Lumbar abscess may also present through this triangle.

The **lumbar fascia** is a dense fascia extending between the last rib and the iliac crest. It is practically the posterior aponeurosis of the transversalis muscle. At the level of the external border of the quadratus lumborum it divides into three layers—the anterior layer extends to the body, the middle layer to the transverse process, and the posterior layer to the spinous process of the vertebræ (Fig. 187). These layers form an osteofibrous sheath for the quadratus lumborum in front and the erector spinæ behind.

The **erector spinæ muscles** occupy the vertebral groove on each side of the spine, presenting a marked prominence on each side of the median line, and thus forming the median

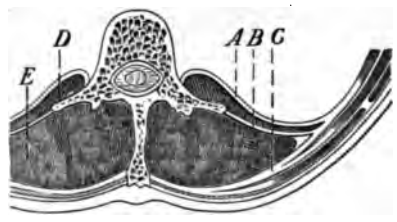

FIG. 187.—THE THREE LAYERS OF THE LUMBAR FASCIA.
A, Anterior layer; *B*, middle layer; *C*, posterior layer; *D*, quadratus lumborum; *E*, erector spinæ.

furrow. Its outer border is well-marked and forms an important landmark in operative procedures in this region. In injuries to the spine spasm of the erector spinæ muscle is often elicited by deep pressure and forms an important objective symptom in obscure spinal lesions incident to railroad accidents.

The **quadratus lumborum** is a thin quadrilateral muscle lying in front of the erector spinæ and extending beyond it laterally for about one-third of its width. Its outer border below corresponds to the middle of the iliac crest, and gradually inclines inward; as it ascends anteriorly it is in relation with the colon, the kidney, the psoas muscle, and the diaphragm.

Lumbago is a painful affection involving the lumbar muscles. It is essentially a myositis due to traumatism from overstraining the muscles, or to the toxemias of faulty metabolism. It must not be confounded with lumbar pain due to affections of the spinal column or the cord, or to renal colic and certain urethral strictures.

In operating through the lumbar region it is well to remember the obliquely transverse direction of the vessels and nerves, and make incisions parallel to the course of the vessels. Such incisions will not only conserve important structures, but will give the best exposure to the viscera beneath. The incision should begin at the external border of the erector spinæ, just below the *twelfth rib*. There is danger of wounding the pleura if the incision is carried higher than this. The lumbar route is used in perinephritic abscess, fixation of movable kidney, exploration and excision of the kidney, and occasionally colotomy.

Its advantage is obvious, since it forms the extraperitoneal approach to these organs.

THE ABDOMINAL CAVITY

The **abdominal cavity** is much more extensive than its exterior boundaries would indicate. This is due to the dome-like arch of the diaphragm which causes the abdominal and thoracic cavities to overlap, and to the continuation of the pelvic cavity below.

The long axis of the abdominal cavity is directed downward and to the right, because of the obliquity of the diaphragm which rises to a higher level on the right side. Pressure from the abdominal wall is, therefore, exerted in this direction, and explains the greater frequency of hernia on the right side. It also accounts for the tendency of extravasated blood to gravitate to the right iliac fossa.

Nearly all of the organs of digestion and a part of the urinary apparatus are contained in the abdominal cavity. The viscera within the abdominal cavity are either wholly or partly covered by a serous membrane, the peritoneum.

Upon the degree of peritoneal investment depends the range of motion of each viscus.

Note, for example, the ileum with its great mobility completely invested with peritoneum; the ascending and descending colon with a much more limited range of motion are only partially covered by it, while the kidney, which has a relatively fixed position, lies altogether behind it.

Wherever motion is a part of function there nature provides a joint with its serous membrane and its lubricating secretion, whether it be between two contiguous bony surfaces with its synovial membrane, between the constantly moving lung and

the thoracic wall with its pleura, or between the abdominal cavity and the viscera with its peritoneum.

Thus the abdominal cavity has been called the "abdominal joint," and the peritoneum in form and function is admirably adapted for the purpose of allowing the viscera to move, one against the other, without friction.

THE PERITONEUM

The **peritoneum** is the serous membrane which *lines the abdominal cavity*, and *invests* to a greater or less extent, the viscera. To thoroughly comprehend the complex reflections of the peritoneum the student must understand the changes which take place during the development of the alimentary

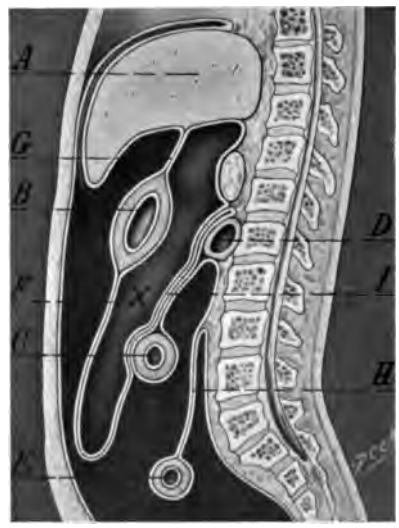

FIG. 188.—DIAGRAMMATIC REPRESENTATION OF THE PERITONEAL REFLECTIONS.
A, Liver; *B*, stomach; *C*, transverse colon; *D*, duodenum; *E*, small intestines; *F*, great omentum; *G*, small omentum; *H*, mesentery; *I*, transverse mesocolon; *X*, lesser cavity of the peritoneum.

canal, and a consideration of the peritoneum should be preceded by a study of the embryology of this region.

The peritoneum is similar to the synovial membrane of a joint or the pleura—*they all line a cavity and invest whatever encroaches upon the cavity.*

Consider for a moment that the abdominal cavity has been emptied of its viscera and that the empty cavity is lined with peritoneum. It is now obvious that—

(*a*) *The peritoneum is a closed sac.* Starting with the empty abdominal cavity lined with peritoneum, imagine the various viscera developing from the posterior abdominal wall behind the peritoneum and, as they develop, pushing the peritoneum in front of them until in the process of growth they have become like the finger in a glove, invested with peritoneum (Fig. 188).

The second fact is obvious, namely: (*b*) *The viscera are all outside the peritoneal sac.*

Peritoneum is either *parietal*, when it lines the abdominal walls, or *visceral*, when it is reflected over the contained viscera.

It has been stated that the peritoneum is a closed sac; this is not strictly true in the female, since the external extremity of the Fallopian tube communicates with the peritoneum.

Note that this is the only instance in which a serous membrane is continuous with a mucous membrane. It explains a number of pathologic conditions arising in the female pelvis.

The *parietal peritoneum*, which lines the walls of the abdominal and pelvic cavities, varies in thickness at different points. It is very thin and adherent at the umbilicus and along the linea alba; it is thick and opaque in the lumbar region and iliac fossæ.

Recall the fact that the subperitoneal connective tissue permits of a gliding movement of the peritoneum, and that it varies in thickness, being most abundant in the lumbar region and at the margin of the pelvis. Thus the parietal peritoneum is very movable at certain parts and readily displaced, as is observed in the formation of a hernial sac. The protruding mass first displaces and then distends the peritoneum in front of it, until a pouch of peritoneum is formed which constitutes the sac of the hernia.

The *visceral peritoneum* completely or partially invests the viscera. It is much thinner than the parietal layer, and so transparent that the color of the organs can be seen beneath. It does not adhere to the organ which it covers, but is separated by a thin cellular layer which is *very elastic*. This characteristic is observed in the enormous distentions which are possible, and the size attained by the pregnant uterus without apparent damage to the investing membrane.

The Peritoneal Folds.—The peritoneum not only forms a closed sac which lines the abdominal walls and is reflected upon the contained viscera, but by its folds and reflections it forms *omenta, mesenteries, ligaments,* and an infundibulum or

lesser peritoneal cavity which communicates with the larger cavity through a constricted orifice—the *foramen of Winslow.* These peritoneal folds assume different names, according to their functions.

The **omentum** is a fold of peritoneum extending from one viscus to another; for example, the great omentum attached to the stomach and transverse colon.

The **mesentery** is a fold of peritoneum extending from the abdominal wall to some segment of the digestive tube; for example, the mesentery which suspends the small intestine from the back of the abdomen.

The *ligaments* are folds of peritoneum attached to the viscera, not a part of the digestive tube; for example, the suspensory ligament of the liver extending from the diaphragm to the upper surface of the liver.

These various peritoneal folds contain more or less connective tissue in which are the vessels and nerves which supply the viscera. Note, therefore, that their function is twofold—namely, *fixation* and *nutrition.*

The **great omentum** is a voluminous fold of peritoneum extending from the greater curvature of the stomach and the free border of the transverse colon. It is spread over the small intestines like an apron, as far down as the pelvis, and separates them from the anterior abdominal wall.

The great omentum consists of two descending layers of peritoneum which proceed from the lower border of the stomach as far as the pelvis, where they ascend to enclose the transverse colon (see Fig. 188). Between the layers of the omentum is situated a part of the lesser peritoneal cavity which forms the omental bursa; in the adult, however, this portion of the lesser peritoneal cavity is apt to be obliterated by adhesions. The great omentum varies in length and thickness. In children it is thin, transparent, and short. In the adult it is thick and usually extends as far as the pelvis; there is, however, much variation in length. In the obese it is loaded with fat, and contributes in a large measure to the size of the abdomen.

The omentum plays an important part in hernia. Its position in front of the intestines, and immediately behind the anterior abdominal wall, explains why it is commonly met with in the umbilical hernia of adults. When the omentum is long it may form the constituent part of either an inguinal or femoral hernia (epiplocele). Note in these cases the vomiting and epigastric pain explained by the traction of the omentum.

Furthermore, the great omentum inclines a little more to the left than the right in the abdominal cavity, which accounts for the greater frequency of epiplocele on the left side.

Intestinal obstruction may be caused by a loop of intestine finding its way through a rent in the great omentum; therefore, any slit or tear in the omentum should be closed by suture.

The Functions of the Great Omentum.—When its situation, its vascularity, and its behavior in intra-abdominal accidents and infections are considered it is obviously an *organ of protection.* It has been called the "abdominal policeman," and the analogy is not far fetched when its propensity to attach itself to wounded areas and to wall off infectious processes is considered. Its functions may be summarized as follows:

(*a*) In wounds of the intestine or perforations from disease the omentum may attach itself to the wounded area and prevent escape of intestinal contents.

(*b*) In infectious processes the omentum may wall off the inflammatory focus and prevent its spread from one region of the abdomen to another.

(*c*) An ovarian cyst with a twisted pedicle may be rescued from gangrene by forming omental adhesions and receiving nourishment through the omental vessels.

(*d*) Ascites from obstructed portal circulation is sometimes relieved by forming adhesions between the omentum and anterior abdominal wall (epiplopexy), and thus forming an accessory anastomosis between the portal and general circulation.

(*e*) The omentum is sometimes useful as an omental graft by attaching it over an intestinal suture to give additional strength to the line of union.

(*f*) Before closing an abdominal incision the omentum should be spread over the intestines to prevent adhesions between the bowel and cicatrix.

In addition to its function of protection it undoubtedly plays an important part in regulating the abdominal blood distribution. Witzel estimates that one-quarter of the visceral blood supply of the abdomen can be contained in the omental vessels.

It must be remembered that omental adhesions, while they often serve a useful purpose, may likewise form bands beneath which a loop of intestine may become strangulated.

The **lesser omentum** is a double fold of peritoneum extending between the transverse fissure of the liver and the lesser

curvature of the stomach. The right border of this fold is free, and forms the anterior margin of the foramen of Winslow. Between the folds and near the free border are the common bile duct, the portal vein, and the hepatic artery. Thus, when the finger is passed through the foramen of Winslow, the structures in front of the finger are the common bile-duct

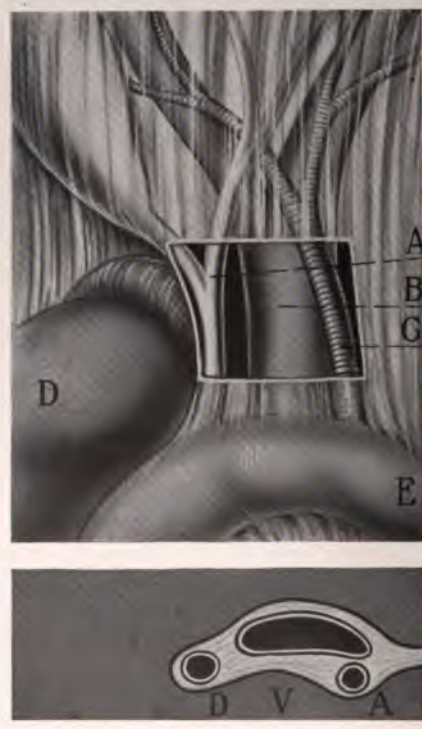

FIG. 189.—THE LESSER OMENTUM, SHOWING THE STRUCTURES BETWEEN ITS FOLDS AFTER REMOVAL OF PORTION OF ANTERIOR PERITONEAL LAYER, AND TRANSVERSE SECTION BELOW, SHOWING RELATION OF STRUCTURES.

A, Common duct; *B*, portal vein; *C*, hepatic artery; *D*, right kidney; *E*, duodenum.

to the right, the hepatic artery to the left, and the portal vein behind and between them (Fig. 189).

The **gastrosplenic omentum** is a fold of peritoneum extending between the fundus of the stomach and the spleen. Between the folds pass the vasa brevia from the splenic artery to the fundus of the stomach.

The **mesentery** is the fold of peritoneum forming the suspensory ligament and vascular pedicle of all the small intestine,

except the duodenum. It is fan-shaped, its attached root being about 6 in. long and extending from the left side of the second lumbar vertebra obliquely across the spine to the right sacro-iliac synchondrosis (Fig. 190). Its intestinal border is folded irregularly like a ruffle, and is about 22 ft. in length, enclosing the small intestine from the beginning of the jejunum to the end of the ileum. The average length of the mesentery, from root to the intestinal border, is about

FIG. 190.—THE ROOT OF THE MESENTERY.
A, *A*, Shows its oblique direction across the spine from left to right.

8 in. The longest part is that which goes to the coils of intestine that lie between a point 6 ft. from the duodenum and a point 11 ft. from the duodenum; the mesentery here may reach the length of 10 in. (Treves). Between the folds of the mesentery are the mesenteric vessels, nerves, glands, and lymphatics. The blood-vessels are the superior mesenteric artery and vein; the lymphatic vessels are the lacteals which carry the chyle from the intestine to the receptaculum chyli; the nerves are branches of the superior mesenteric plexus.

In the obese there is a great deposition of fat between the mesenteric folds, which has a tendency to lengthen the mesentery and predisposes to hernia.

Note the following points:

(*a*) The mesentery permits of great mobility of the small intestine, which seems to float about in the abdominal cavity. When the mesentery is abnormally long it plays an important part in predisposing to hernia. It has been proven that with a normal mesentery it is impossible for a loop of intestine to pass through the inguinal or femoral canal; hence, elongation of the mesentery must precede either of these forms of hernia.

(*b*) As observed above, the root of the mesentery is obliquely attached from above downward, and from left to right; hence, it forms a longitudinal partition which divides the abdominal cavity into two parts. When extravasated blood occurs to the right of the mesentery it is directed toward the right iliac fossa; when it occurs to the left of the mesentery it is directed into the pelvis. This fact explains the greater frequency of bloody extravasations into the right rather than the left iliac fossa.

(*c*) The mesentery may contain certain holes, either slit-like, due to injury, or round, due to congenital defect. Treves has shown that the latter are found in the mesentery of the lower ileum, where the peritoneum is very thin, owing to the absence of fat, vessels, and glands, and that they are a constant source of danger because of the liability of a coil of intestine to slip through and become strangulated.

(*d*) The **mesenteric glands** are commonly enlarged in almost all acute abdominal affections. In tubercular infections, and when accompanied by tubercular peritonitis, there may be associated adhesions and contractions sufficient to cause intestinal obstruction.

(*e*) **Mesenteric cysts (chyle cysts),** are cystic formations within the mesentery which contain a fluid resembling chyle, and occasionally attain a size large enough to simulate an ovarian cyst.

Intestinal Localization.—While in the majority of abdominal operations the only concern which the surgeon has regarding the small intestines is to keep them away from the field of operation, yet in those operations in which the intestine itself is the seat of operation, such as intestinal obstruction or intestinal anastomosis, there are two points which the surgeon

is called upon to determine in considering any particular loop of intestine:

(*a*) The *position* of the intestinal loop in reference to the rest of the intestine.

FIG. 191.—A LOOP OF INTESTINE 3 FT. FROM THE END OF THE DUODENUM. (Monks.) Note that the mesenteric loops are primary and the vasa recta large and regular in distribution. The translucent spaces between the vessels are extensive.

(*b*) The *direction* of the loop—which end points toward the duodenum and which to the ileocecal valve.

Monks has shown that the direction of an intestinal loop can be determined with accuracy. Its position can be localized approximately by the definite and characteristic arrangement

FIG. 192.—A LOOP OF INTESTINE AT 6 FT. (Monks.) Note that the secondary loops are prominent, the vasa recta are smaller, and the translucent spaces have diminished in size.

of the mesenteric vessels, which form loops of varying size and number, according to the part of the intestine which they supply.

The author has verified the conclusions of Monks on the living subject as well as on the cadaver, and finds them of practical value within certain limits.

The following is a summary of Monks' views:

To determine the direction of an intestinal loop hold the intestine taut and follow the mesentery down to its root, and arrange the loop of gut parallel to the direction of the root; the end of the loop downward is nearest the ileocecal valve (see Fig. 190).

FIG. 193.—A LOOP OF INTESTINE AT 12 FT. (Monks.)
Note that the primary loops are lost in fat, the vasa recta are short and irregular.

To determine the position of an intestinal loop, note the size and number of loops formed by the mesenteric vessels, as follows:

FIG. 194.—A LOOP OF INTESTINE AT 17 FT. (Monks.)
Note that the mesentery is opaque. The vessels are represented by a complicated network.

The main branches of the superior mesenteric artery unite with each other to form loops which may be primary, secondary, or tertiary, and from these loops the vasa recta run to the bowel.

In the upper part of the bowel the loops are primary, large, and regular, and the translucent spaces between the vessels are extensive (Fig. 191).

Further down, at about the sixth foot, secondary loops are a prominent feature, the vasa recta are smaller, and the translucent spaces have diminished in size (Fig. 192).

Still further down, the secondary loops become more numerous and even tertiary loops appear, the primary loops becoming smaller. The translucent spaces have disappeared (Fig. 193).

At the lower part of the gut the mesentery is opaque, and small tabs of fat begin to appear along the mesenteric border of the gut; the vessels are represented by a complicated network. Sometimes the vessels are seen with difficulty and are represented by mere grooves in the fat (Figs. 194 and 195).

FIG. 195.—A LOOP OF INTESTINE AT 20 FT. (Monks.)
Note that the mesentery is fatty and opaque. The vessels are complicated and seen with difficulty.

The **lesser peritoneal cavity** is simply a diverticulum of the general peritoneal cavity, situated behind the stomach, so that when the abdomen is opened it cannot be seen. Some one has compared the greater cavity to a bag, of which the lesser cavity is a pocket. The two cavities communicate through the *foramen of Winslow*, a narrow circular opening situated behind the right border of the lesser omentum.

The lesser cavity is bounded in front by the lesser omentum, the stomach, and the descending layers of the great omentum; behind by the ascending layers of the great omentum, the colon, and the upper layer of the transverse mesocolon; above by the liver, and below by the turn of the great omentum.

If the foramen of Winslow be abnormally large, it may provide an opening through which a hernia may occur.

The peritoneal ligaments and the mesentery of the cecum, colon, and rectum will be described with the respective viscera.

The Peritoneal Vessels.—The peritoneum, like other serous

membranes, does not possess an arterial and venous circulation of its own, but is supplied by the vessels of the different organs which it covers.

The Lymphatics.—The peritoneum possesses distinct lymphatic vessels which have, according to Byron Robinson, three modes of origin:

(*a*) By stomata between endothelial cells, which are in direct communication with lymph-vessels.

(*b*) By interstitial spaces in the subperitoneal tissue.

(*c*) By a plexiform origin similar to interstitial spaces. In fact, the peritoneum is a lymph sac in which the absorption is rapid. It has been estimated that 8 per cent. of the body-weight may be absorbed in an hour. Thus is explained the rapid absorption of infections and the overwhelming toxemia which accompanies a general septic peritonitis. Absorption takes place most rapidly in the region of the diaphragm, and slowest in the pelvis.

The Nerves.—The parietal peritoneum is supplied from the nerves of the abdominal wall; the visceral peritoneum from branches of the solar plexus. The latter in a normal state possesses very little sensation; when irritated, however, they may give rise to grave reflexes, such as cardiac and respiratory collapse, intestinal paralysis, and anuria. These phenomena are observed not only in peritonitis, but in the course of intra-abdominal operations of long duration.

Clinical Considerations of the Peritoneum.—The two chief characteristics of the peritoneum are:

(*a*) Its power of absorption.

(*b*) Its power to form adhesions.

The peritoneum must be regarded as a large lymph sac, where absorption takes place with great rapidity. Hence, in septic peritonitis the danger is from fatal toxemia due to the rapid absorption, which is most rapid at the diaphragm, slowest in the pelvis. This fact has been utilized by Fowler in suggesting that the head of the bed be raised after abdominal operations in infected cases, in order that the drainage may be directed toward the pelvis, where absorption is less rapid and consequently less liable to produce grave toxic effects. On the contrary, if after an abdominal operation salt solution is left in the abdomen because of shock or hemorrhage, the foot of the bed should be raised, in order that the fluid may be directed toward the diaphragm, where more rapid absorption takes place.

The peritoneum normally secretes sufficient serum to lubricate its surface, but when irritated or infected it produces a plastic exudate which establishes adhesions between contiguous peritoneal surfaces.

It is this property of the peritoneum which forms the foundation of all operative surgery of the abdominal cavity.

Observe its practical application in—(*a*) ***Repair*** of a visceral incision: Anastomosis between the ends of a divided intestine is obtained by approximating the serous surfaces, and union is obtained in a few hours by means of the plastic exudate (peritoneal glue).

(*b*) *As a protective agent* in peritoneal infection, the plastic exudate forms a wall of adhesions about the infecting focus, isolates it from the general cavity, and thus prevents a general peritonitis.

(*c*) This remarkable property of the peritoneum to form adhesions, while beneficent in many ways, may also be the cause of conditions more or less grave by preventing the normal mobility of the viscera and becoming the source of intestinal obstruction.

THE STOMACH

The **stomach** is the dilated portion of the intestinal tube. It constitutes a large musculomembranous pouch placed between the esophagus and the duodenum. It occupies *almost exclusively* the left hypochondrium; the greater curvature of the stomach is turned to the left, the lesser curvature to the right, and the long axis of the stomach is almost vertical (slightly oblique from above downward, and from left to right). *Note that the two orifices, cardiac and pyloric, are placed in the direction of an almost vertical line, and not horizontally*, as is so frequently represented (Fig. 196).

Relations of the Stomach.—The stomach is placed in the gastric fossa, beneath the vault of the diaphragm, on the left side. *Above* is the vault of the diaphrgam and the liver; *below*, the transverse mesocolon; *externally* it is in relation with the lateral portion of the diaphragm. *Posteriorly*, it rests on the pancreas, the aorta, and the two crura of the diaphragm. *Anteriorly*, its superior segment is related to the diaphragm and liver; its inferior segment is related to that portion of the abdominal wall represented by the *gastric triangle*—a triangular area bounded on the left by the eighth and ninth

costal cartilages, on the right by the free margin of the liver, and below by the transverse colon (Fig. 197). This triangle

FIG. 196.—SHOWING THAT THE LONG AXIS OF THE STOMACH IS VERTICAL; THE TWO ORIFICES ARE PLACED IN AN ALMOST VERTICAL LINE.
A, Position of cardiac orifice; *B*, position of pyloric orifice.

represents the area where the stomach is in contact with the abdominal wall, and through which the stomach may be reached in operative procedures.

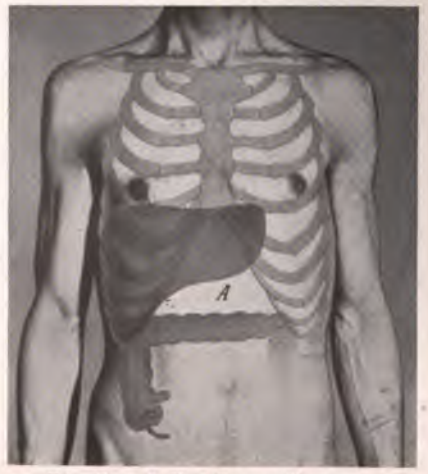

FIG. 197.—*A*, THE GASTRIC TRIANGLE.

Means of Fixation.—The stomach is held in position *above* by its continuity with the esophagus, which is firmly fixed to

the diaphragmatic ring, and below by its continuity with the duodenum. The latter, however, while it supports the stomach, is not a means of fixation, since the pylorus, as we know clinically, is displaced with the greatest facility. In addition, the stomach is supported by the *gastrophrenic ligament,* which connects it with the diaphragm, the gastrohepatic or lesser omentum, which connects the lesser curvature of the stomach with the liver, and the gastrosplenic omentum, which connects the cardiac end of the stomach with the hilum of the spleen. It will thus be observed that the fixed portion of the stomach is the lesser curvature; hence, when the stomach is distended it rotates upon its fixed axis, the lesser curvature; the anterior surface is turned upward, the posterior downward, and the greater curvature is carried forward against the anterior abdominal wall. Note, therefore, that the full stomach, from its position, is much more exposed to injury than when empty.

The **cardia** is the point where the esophagus joins the stomach. The opening is called the cardiac orifice. It is situated to the left of the spine, opposite the tenth or eleventh dorsal vertebra, from which it is separated by the aorta. It is the most fixed part of the stomach, and is deeply placed, being about 4 in. from the anterior abdominal wall, and corresponding to a point on the surface at the seventh left chondrosternal articulation. Note that this portion of the stomach is fixed and deeply placed; hence, it is difficult of access. It may be reached through an opening in the stomach (gastrotomy), and cicatricial strictures of its cardiac end dilated, or foreign bodies arrested at the lower end of the esophagus removed. When the cardiac orifice is totally obstructed by a cicatricial or cancerous stricture, it is necessary to make a permanent opening in the stomach (gastric fistula) through which the patient can be fed.

The **pylorus** is the point of junction of the stomach with the duodenum, the outer surface of which is marked by a circular constriction (Fig. 198).

Its situation varies with the distention of the stomach. When the stomach is empty the pylorus lies just to the right of the median line, at the level of the twelfth dorsal vertebra, corresponding on the surface, to a point 1 in. below the tip of the ensiform cartilage. When the stomach is distended, the pylorus may be displaced 2 or 3 in. to the right of the median line. As a landmark, it may be said that the cardiac orifice

corresponds to the left border of the sternum, whereas the pylorus is situated upon a line corresponding to a prolongation of the right border of the sternum; hence, *the pylorus is most accessible through a median abdominal incision.*

The pyloric orifice is guarded by the *pyloric valve,* which is formed by a strong muscular ring which gives special prominence to the thickened mucous membrane at this point (see Fig. 198). The pyloric opening is about ½ in. in diameter, and is the narrowest part of the alimentary tube. The function of the pyloric valve is evidently to regulate the alimentary current in passing from the stomach into the duodenum. On the other hand, it does not prevent the regurgitation of bile and fecal matter into the stomach in case of intestinal obstruction.

FIG. 198.—THE PYLORUS.
Observe the circular constriction marking the site of the pyloric valve. *A*, Circular constriction; *B*, pyloric sphincter.

It is worthy of notice that cancer of the stomach seldom passes the pylorus and invades the duodenum.

The **relations of the pylorus** are, in front, with the inferior surface of the liver; behind, with the portal vein and hepatic artery; above, with the lesser omentum; and below, with the head of the pancreas. These relations suggest the difficulty and gravity of *resection of the pylorus* (pylorectomy), especially the dangers to the portal vein and hepatic artery.

Stenosis of the pylorus may be spasmodic, cicatricial, or cancerous. From whatever cause, it produces a mechanical obstruction which gives rise first, to stasis (retention of stomach contents), and secondly, to dilatation, more or less pronounced. In this condition the patient suffers from inability to discharge

the stomach contents into the duodenum, and unless relieved will die of inanition. If a radical operation on the pylorus is contra-indicated the palliative procedure of excluding the pylorus by a gastro-enterostomy may be used (Fig. 199). In this operation the lowest part of the stomach is anastomosed with the highest part of the jejunum, whereby the pylorus is isolated and the food passes directly from the stomach into the intestine.

The Curvatures.—The **greater curvature** is much longer than the lesser curvature. It starts from the cardia, forming a sharp angle with the esophagus, and forms a pronounced convexity which arches up and to the left, the highest point reaching to the level of the costal cartilage of the sixth rib

FIG. 199.—GASTRO-ENTEROSTOMY, SHOWING THE ISOLATION OF THE PYLORUS BY THE DEFLECTION OF THE GASTRIC CURRENT INTO (*A*) ARTIFICIAL OPENING.

on the left. It then descends directly downward and turns to the right, to end in the pylorus. The lowest point of the greater curvature is about 1½ in. above the umbilicus (Gray). It gives attachment to the anterior layers of the great omentum, and is encircled by the arterial anastomosis between the *right* and *left gastro-epiploic arteries.*

The **lesser curvature** forms the right border of the stomach and extends from the cardia to the pylorus. Its direction is slightly oblique from above downward and from left to right. It is in relation with the celiac axis, the left lobe of the liver, and the solar plexus. It gives attachment to the gastrohepatic omentum, between the layers of which is found the arterial anastomosis between the *pyloric* and *gastric arteries.*

The Lymphatics of the Stomach.—The principal chains of lymphatics are:

(*a*) Those situated along the lesser curvature. There are from three to ten glands situated along the course of the gastric artery. They drain the lymph from the cardia, the body of the stomach, and the pyloric end. Two-thirds of the stomach is drained by these glands (Fig. 200).

(*b*) Those situated along the greater curvature. There are from three to six glands situated beneath the pyloric portion of the stomach in the folds of the great omentum, and two or three glands on the posterior surface of the pylorus near the head of the stomach. These lymphatics drain about one-third of the stomach (see Fig. 200).

FIG. 200.—THE LYMPHATICS OF THE STOMACH AND LINE OF INCISION FOR GASTRECTOMY.

(*c*) Those trunks which come from the fundus of the stomach and terminate in the glands situated near the tail of the spleen; these latter are not important in the surgery of the stomach.

The practical importance of these lymphatic groups is evident in cancer of the stomach, since no operation for cancer is justifiable which does not include extirpation of the neighboring lymphatics. It will be observed that the lymphatic centers of the stomach include the entire lesser curvature and the pyloric third of the greater curvature, while, as Mayo has observed, the dome of the stomach is practically free. Hence, in operating for pyloric cancer, the entire lesser curvature and the pyloric third of the greater curvature must be

removed with the mass, making the resection on a line, as indicated in Fig. 200.

The **nerves** are derived from the right and left pneumogastric and from the solar plexus of the sympathetic. They form in the walls of the stomach an intramuscular plexus—*Auerbach's plexus*, and a submucous plexus—*Meissner's plexus*. The latter ramifies in the submucous coat and sends branches to the gastric glands.

Hyperchlorhydria is said to be due to functional disturbance of the nerve filaments which are distributed to the gastric glands.

Clinical Considerations.—(*a*) Note the close relationship of the stomach to the vault of the diaphragm on the left side, and its *proximity* to the *heart* and *lungs*. It explains the dyspnea and palpitation which follows pressure from a distended stomach. This intimate relation between heart and stomach must be ever in mind in interpreting symptoms associated with either organ. The well-known aphorism: "If a patient complains of his stomach suspect the heart, if he complains of his heart suspect the stomach," has an anatomic basis.

Vertigo or apoplexy after a hearty meal is caused by the distended stomach pushing the heart upward and to the right, retarding its action, impeding the flow of blood through the heart, causing flushed face, cerebral congestion, and distention of the cerebral capillaries with venous blood.

(*b*) The relations of the stomach to the anterior abdominal wall when full and empty.

When the stomach is empty it is deeply placed and not in immediate contact with the abdominal wall; when moderately distended it is in contact with the abdominal wall over a small area represented by the gastric triangle (see p. 379).

When further distention takes place the stomach rotates on its axis and the greater curvature is thrown forward against the anterior abdominal wall. Thus *the distended stomach from its exposed position is more liable to injury*, and wounds of the stomach, when full, are more liable to be fatal because of the escape of the gastric contents into the peritoneal cavity and subsequent septic peritonitis.

(*c*) **Gastric Dilatation.**—The stomach normally distends and contracts within certain physiologic limits. When, however, its outlet, the pylorus, is obstructed it is capable of enormous dilatation and may even fill the greater part of the abdominal cavity.

Stenosis of the pylorus, either cicatricial or cancerous, is a gradual process, and the partial obstruction first produces *stasis*—inability of the stomach to completely empty itself. After unsuccessful efforts on the part of the stomach in this direction, dilatation gradually takes place and, as noted above, may reach enormous proportions.

Acute dilatation of the stomach may be a sequela of either operation or injury in parts even remote from the stomach. It is usually a postoperative condition of great gravity and often terminates fatally. It is essentially a gastric paresis, probably due to some obscure disturbance of the intramuscular gastric plexus of the sympathetic (Auerbach's plexus).

Operations on the Stomach.—In operations upon the stomach the following anatomic points should be remembered:

(*a*) The stomach is in contact with the anterior abdominal wall only within a small area represented by the gastric triangle (see p. 379). In operations upon the anterior wall of the stomach the incision should be made in this area.

(*b*) The guide to the stomach is the left lobe of the liver, beneath which it lies and with which it is connected by the lesser omentum.

(*c*) Incisions through the wall of the stomach should be made at right angles to its long axis, or, in other words, parallel to the vessels which supply its walls.

(*d*) In all drainage operations upon the stomach (gastroenterostomy) the opening in the stomach should be made at its most dependent portion—in the lower third of the greater curvature. This prevents the formation of the "vicious circle" (the passing of the contents of the stomach into the duodenum, where they accumulate and are regurgitated into the stomach and vomited) by providing an exit to which the stomach contents naturally gravitate.

Gastrotomy consists in opening the stomach for the purpose of removing a foreign body, exploring its orifices, dilating a nonmalignant stricture with the fingers (Loreta's operation), or treating a stricture of the esophagus by retrograde dilatation.

Gastrostomy is the establishment of a more or less permanent fistulous opening through which the patient may be fed in case of stricture of the esophagus. The main point here is to provide an opening through which food may be introduced and from which it will not escape. The problem, therefore, is to form an opening which will be above the level of the stomach. This is easily accomplished by forming a sub-

cutaneous esophagus from the stomach wall. A cone of the stomach wall is drawn out of the wound, and after its base is sutured to the parietal peritoneum it is drawn over the costal margin under a bridge of skin and anchored in position. The orifice is made through the apex of the cone, and a tube introduced, by means of which the patient is fed.

Gastro-enterostomy is performed for the purpose of establishing a communication between the stomach and the upper part of the small intestine. It changes the direction of the alimentary current through the pylorus, and practically puts at rest the pyloric portion of the stomach (see Fig. 199). Hence, it is obviously indicated in pyloric obstruction and in gastric ulcer which is usually situated at the pyloric end.

Anatomic Points.—The most satisfactory gastro-enterostomy is that which anastomoses the lowest part of the stomach with the highest part of the jejunum.

Recall the relations of the stomach and upper portion of the jejunum—they are separated by a horizontal partition formed by the transverse mesocolon. Above this partition lies the stomach, below the jejunum, covered in front by the pendulous omentum. Evidently then, the highest part of the jejunum (near the duodenojejunal flexure) is found by turning up the omentum and transverse colon. The duodenojejunal flexure is found on the left side of the spine, in the angle between the root of the mesentery and the transverse mesocolon (duodenojejunal fossa). It is obvious that the most dependent part of the posterior wall of the stomach normally lies in front of the highest part of the jejunum, separated only by the transverse mesocolon. Therefore, by making an aperture in the transverse mesocolon and anastomosing the posterior wall of the stomach and the jejunum without disturbing their normal relationship, the most ideal gastro-enterostomy is obtained (*posterior gastro-enterostomy*).

If the posterior route is not feasible, a portion of the jejunum is selected about 12 in. from the duodenojejunal flexure, brought up over the great omentum in front of the transverse colon and joined to the anterior wall of the stomach. This latter procedure is by no means as satisfactory as the first, because of the dangers of intestinal obstruction and the possibility of establishing the "vicious circle."

Gastrectomy.—Usually partial; in very rare instances complete. Partial gastrectomy has superseded pylorectomy

for pyloric cancer, since no operation for cancer is effective unless it includes extirpation of the neighboring lymphatics.

Recall the course of the gastric lymphatics, and it is evident that in operating for pyloric cancer the entire lesser curvature and the lower third of the greater curvature must be removed. After removal of the diseased area the continuity of the intestinal tract is restored by a gastro-enterostomy. Total gas-

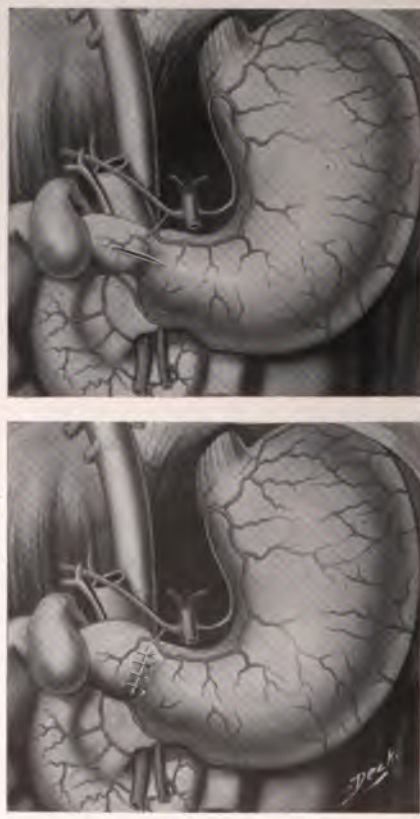

FIG. 201.—PYLOROPLASTY.

trectomy is done when the entire stomach is cancerous and the viscus is still movable.

Pyloroplasty.—An operation designed to increase the size of the pyloric outlet in cases of nonmalignant stricture. It consists in making an incision through the stricture, which is directed in the long axis of the pyloric canal. Traction is

made on the edges of the incision so as to give it a direction perpendicular to the pyloric axis, and sutures are applied in this position (Fig. 201).

THE SMALL INTESTINES

The **small intestines** constitute that portion of the intestinal canal situated between the stomach and the cecum. Note that at either end of this canal there is a valve—the pyloric valve at the stomach, the iliocecal valve at the cecum. The average length of the small intestine is 20 ft., subject to individual variation, the extremes being 30 ft. and 15 ft.

Note the following characteristics: (*a*) The diameter of the small intestine decreases from its commencement to its termination. At the duodenum it is 2 in., at the lower part of the ileum it is 1 in.

(*b*) Its thickness decreases as it descends.

(*c*) Its vascularity decreases as it descends.

The small intestine may be divided into two portions, the duodenum and the jejuno-ileum. Observe that there is no line of demarcation between the jejunum and ileum. They should be considered as one continuous canal.

The **duodenum** forms the first 12 in. of the small intestine. It is characterized by its deep situation, its fixed position, and its connection with the common bile-duct and the pancreatic duct.

FIG. 202.—THE DUODENUM. Note that in outline it resembles the letter U.

In shape it resembles the letter U (Fig. 202), within the concavity of which is embraced the head of the pancreas.

Beginning at the pyloric end of the stomach the first portion of the duodenum is nearly horizontal. It passes slightly upward and backward for about 2 in. to the neck of the gall-bladder. It is the most movable portion of the duodenum and is covered by peritoneum. Behind it pass the common duct, the portal vein, and the hepatic artery; the head of the pancreas lies below it. The second portion descends in front of the right kidney to its lower pole and is covered by peritoneum only in front. The common bile-duct descends to the inner side of this portion of the duodenum and, with the pancreatic duct, opens into the duodenum by a common orifice on the

summit of a papilla (*papilla of Vater*), located about 4 in. from the pylorus. The third portion crosses the spine at the level of the fourth lumbar vertebra, covered only in front by peritoneum. The fourth portion ascends along the left side of the spine to the root of the transverse mesocolon, where it turns abruptly forward to become the jejunum, forming the *duodenojejunal flexure*. It is covered in front and partly on the *sides* by peritoneum; the superior mesenteric artery and vein pass in front of it.

Duodenojejunal fossa (fossa of Treitz) is situated just below the duodenojejunal flexure. It is an oval pouch large enough to admit the tip of the finger, and is formed by a fold of peritoneum passing from the anterior wall of the terminal portion of the duodenum, curving around to the left in the form of a horseshoe, and blending with the parietal peritoneum. The orifice of the fossa is directed upward (Fig. 203). Its

FIG. 203.—*A*, THE DUODENOJEJUNAL FOSSA (FOSSA OF TREITZ).

chief interest is the fact that it is a cause of *retroperitoneal hernia*. The gradual stretching of this fossa may ultimately result in the formation of a retroperitoneal sac large enough, as reported in one case, to lodge nearly the whole of the small intestine.

Clinical Considerations.—(*a*) Note that the duodenum is covered by peritoneum only in front; hence it may be wounded from behind without opening the peritoneal cavity.

(*b*) Traumatic rupture of the duodenum may occur after

severe crushing injuries. Taylor states that they are usually situated to the right of the spine, in front and to the inner side of the right kidney; hence the most direct access to the injured part is obtained by a lumbar incision made as if to reach the right kidney.

(*c*) **Perforating ulcer of the duodenum** usually occurs in the vicinity of the pylorus and on the anterior wall. Its association with extensive burns of the skin has been overemphasized since it is a very rare sequela. Ulcer of the duodenum is not unlike gastric ulcer, and perforation may terminate fatally from hemorrhage or infection. Cicatrization of a duodenal ulcer may lead to stenosis of the bowel, the common bile-duct, or the pancreatic duct.

FIG. 204.—THE MESENTERY.
Note that it forms the suspensory ligament and vascular pedicle of the intestine.

(*d*) Note the relation of the gall-bladder to the duodenum. It explains how gall-stones may ulcerate through the gall-bladder and pass into the duodenum. It also suggests the possibility of establishing a communication between the gall-bladder and the duodenum (*cholecystoduodenostomy*) in case of inoperable obstruction of the common bile-duct.

The **jejuno-ileum** properly constitutes the small intestine. There is no line of demarcation between the jejunum and ileum, and no reason for describing separately similar segments of the one intestinal canal. It will be referred to as the small intestine.

The small intestine proper commences at the duodenojejunal flexure, just to the left of the second lumbar vertebra, and terminates in the right iliac fossa by joining the ascending colon at a right angle.

It is characterized by its great length, about 20 ft., its numerous folds, and its great mobility. It is called by Testut the floating portion of the small intestine. It is suspended from the posterior abdominal wall by the mesentery, which forms its suspensory ligament and vascular pedicle (Fig. 204). Note that the course of the large intestine is such that it forms a hollow square, deficient only on one side, the pelvic. The small intestine fills this hollow square, the transverse colon situated above, the ascending and descending colon on the sides, and the pelvis below (Fig. 205). The great omentum,

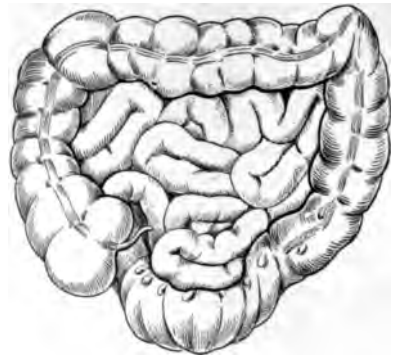

FIG. 205.—COILS OF SMALL INTESTINE LYING IN THE HOLLOW SQUARE FORMED BY THE LARGE INTESTINE.

like an apron, covers the intestinal coils in front and separates them from the anterior abdominal wall. Thus the small intestine occupies the greater part of the abdominal cavity, and is *the most exposed of all the viscera to abdominal injuries,* being protected only by the abdominal wall and the great omentum. While it is impossible to definitely outline the course of the intestinal loops, it may be stated that they follow the general direction of the mesentery, *i. e.*, their position is irregularly from left to right. Fewer intestinal loops, however, are interposed between the anterior and posterior abdominal walls than between the lateral walls. Hence, this practical observation in gunshot or penetrating wounds of the abdomen: *the number of intestinal loops wounded varies with the direction of the vulnerant agent.* In anteroposterior wounds a lesser number of coils are injured than in an oblique or transverse wound.

Meckel's Diverticulum.—There is sometimes found in

the lower portion of the ileum a blind diverticulum or tube, one end of which communicates with the bowel, the other end usually being free. It represents the remains of the vitello-intestinal duct and is analagous to the vermiform appendix. In fact, it may from foreign bodies or intestinal infection become the site of an acute inflammation (*diverticulitis*) and resembles appendicitis in its symptomatology (Testut). The rôle which it plays in intestinal obstruction has already been described on p. 346.

The Mesenteric Attachment of the Intestine.—The two layers of the mesentery, as they approach the bowel, diverge so as to enclose the bowel and form its peritoneal coat. Hence, there is a triangular space at the mesenteric border of the intestine, $\frac{5}{16}$ in. in width, which is uncovered by peritoneum.

It is at this point that leakage is apt to occur in an intestinal anastomosis; hence, it has been called "the deadly mesenteric line" (Fig. 206).

FIG. 206.—*A*, DEADLY MESENTERIC LINE OR TRIANGULAR SPACE UNCOVERED BY PERITONEUM.

The **intestinal wall** is composed of four layers, a serous, muscular, submucous, and mucous.

The *serous coat* is very thin, so that the muscular fibers beneath can be seen shining through it. It completely invests the bowel, except at the mesenteric border, where there is a small triangular interval corresponding to the separation of the two mesenteric layers as they pass on to the bowel (see Fig. 206).

The *muscular coat* consists of two layers, one thin and superficial, composed of longitudinal fibers, the other deeper and thicker, made up of circular fibers. The thickness and strength

of the circular fibers explains why *longitudinal wounds gape more than transverse ones.* The muscular layer produces the vermicular movements of the intestine known as *peristalsis,* which is normally in the direction of the cecum. In intestinal obstruction peristalsis may be reversed and the contents forced toward the stomach.

The *submucous coat* is essentially a cellular layer loosely connecting the muscular and mucous coats. It may become considerably thickened as the result of chronic inflammation of the mucosa, as seen in certain rectal lesions.

The *mucous coat* is characterized by the presence of a large number of folds on its inner surface, which are not obliterated by distention, as those in the stomach. They are known as *valvulæ conniventes.* They begin in the duodenum, and are very numerous as far as the middle of the small intestine, where they begin to diminish, and disappear almost completely near the ileocecal valve.

The mucosa is covered with *villi*—slender projections of mucous membrane which gives it the "velvety" appearance. They are most numerous in the upper part of the intestine and gradually diminish toward the cecum. The villi are concerned in absorbing the products of digestion, while the folds of the valvulæ conniventes increase the extent of the absorbing and secreting surface of the bowel.

The **glands of the mucosa** consist of: (*a*) The *glands of Lieberkühn,* tubular glands found along the entire length of the small intestine and continued into the large intestine. They secrete mucus.

(*b*) *Brunner's glands,* found only in the duodenum. They are small racemose glands which discharge a serous secretion. Abscess of these glands may produce a perforating ulcer of the duodenum (Deaver).

(*c*) The *solitary glands* consist of a number of lymph follicles scattered throughout the small and large intestine.

Peyer's patches are whitish patches of lymphoid tissue occupying principally the lower two-thirds of the ileum, being especially numerous toward the end of the small intestine. They are usually situated at a point opposite the mesenteric attachment of the bowel. They have no secretory function. They are well developed in the young and atrophy as age advances. They are the site of typhoid and tubercular ulcer. In typhoid fever the ulceration may progress and cause serious hemorrhage or perforation of the bowel.

The Blood-vessels.—The small intestine receives its supply from the superior mesenteric artery, which ramifies between the layers of the mesentery, forming a series of arterial arches from which small straight vessels arise, which pass transversely around the intestine.

The arteries are accompanied by corresponding veins and by lymphatics. Wounds at the mesenteric border of the intestine involve the blood supply of the intestine, and are usually followed by gangrene of that portion of the intestine supplied by the damaged vessels. Hence, in these lesions resection of that portion of the intestine supplied by the injured vessels is indicated.

Thrombosis of the mesenteric artery presents a clinical picture almost exactly like that of acute intestinal obstruction, and it is impossible to diagnose the condition prior to operation.

The arrangement of the vascular supply explains the fact that in hernia of an entire coil the vascular supply is preserved; in hernia of an incomplete coil the supply is cut off. Hence, *gangrene occurs more frequently in small than in large intestinal hernias.*

The **veins** accompany the arteries and terminate in the superior mesenteric vein, which, with the inferior mesenteric and splenic veins, form the trunk of the portal vein.

The **lymphatics** originate in a plexus in the submucous coat and another in the muscular coat. They communicate freely, and empty into the lacteal vessels which lie between the two layers of the mesentery, pass through the chain of mesenteric glands, and finally unite to form the intestinal lymphatic trunk which empties into the receptaculum chyli. Lesions of the intestine, particularly typhoid, cancer, and tuberculosis, are evidenced by enlarged mesenteric glands.

The **nerves** come from the solar plexus. They ramify between the folds of the mesentery, and in the wall of the intestine form a motor plexus situated in the muscular coat (Auerbach's plexus) and a sensory plexus situated in the submucous coat (Meissner's plexus).

Surgical Considerations.—The small intestine is the most exposed of all the viscera to abdominal injuries. *Note that contusion of the abdomen may be complicated by rupture of the intestine, and the latter may be present with no mark of injury on the abdominal wall.*

Wounds of the intestine, when small and punctured, are not as a rule serious, since the mucosa at once plugs the orifice and

prevents the escape of intestinal contents. Hence, in an excessively distended intestine a fine puncture may be made for the escape of the gas. It is always safe to close even these small wounds with a silk suture.

As already noted, a longitudinal wound gapes more than a transverse one, owing to the stronger action of the circular muscular fibers.

In closing a wound of the intestine the peritoneal surface must be brought in contact. This is accomplished by means of a Lembert suture (Fig. 207).

Enterotomy consists in making an opening in the bowel for the purpose of removing an impacted foreign body, or making an artificial anus above the point of obstruction after suturing the bowel to the edges of the wound.

A *B*

FIG. 207.—THE LEMBERT SUTURE.
A, Incorrect form; *B*, correct form.

Strangulation of the small intestine is common, because of its extreme mobility. It may become twisted upon itself (volvulus), form intussusceptions, or pass through normal or abnormal openings underneath bands of adhesions or diverticula. The termination of strangulation is gangrene of the incarcerated intestinal loop.

Enterectomy consists in the resection of a segment of the gut for gangrene, extensive injury, benign or malignant growths.

Anatomic Points.—(*a*) The intestine is nourished through its mesenteric attachment. Hence, any piece of intestine projecting beyond the section in the mesentery will slough.

Rule.—Divide the intestine somewhat obliquely, so that the attached mesenteric border will be a trifle more extensive than the free border.

(*b*) It will, as a rule, not be necessary to remove a V-shaped piece of the mesentery; the redundant fold may be lapped and stitched.

(*c*) Approximate the peritoneal surfaces by means of Lembert sutures, which include the entire thickness of the bowel except the mucosa, and remember the "deadly mesenteric line," where the most careful approximation must be made.

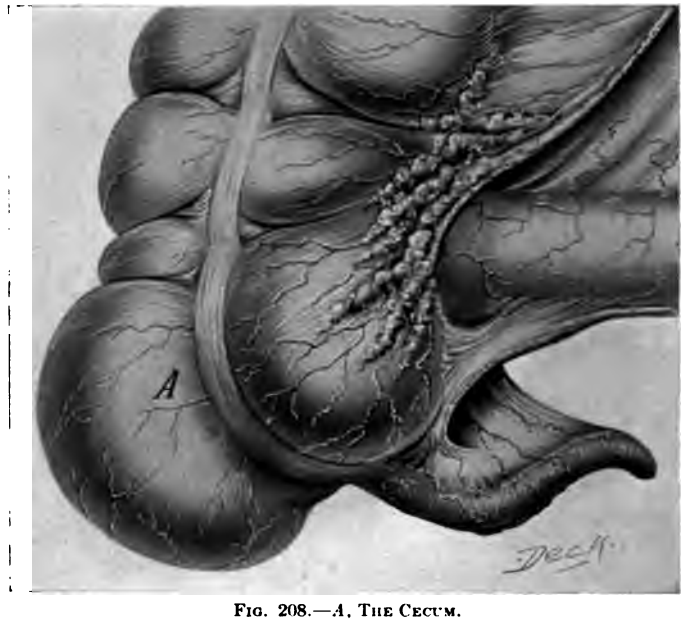

FIG. 208.—*A*, THE CECUM.

(*d*) The loop of the suture should correspond to the long axis of the gut in order to increase the resistance against the traction of the circular muscular fibers (see Fig. 207).

(*e*) End-to-end anastomosis is preferable, if feasible. Lateral anastomosis between the coils above and below a lesion may be done as a palliative measure when resection of the diseased part is not practical.

THE CECUM

To appreciate the cecum recall the fact that the small intestine joins the large intestine at a right angle about 2½ in. above its closed extremity, thus forming a blind pouch or cul-de-sac below the ileocecal valve (Fig. 208). It is lodged in the

right iliac fossa and lies beneath that part of the anterior abdominal wall which corresponds to the outer half of Poupart's ligament. From the lower extremity of the cecum is given off the vermiform appendix, which represents the lower undeveloped portion of the primitive cecum.

As a rule, the cecum is surrounded on all sides by peritoneum. In 6 per cent. of cases, according to Berry, the peritoneal covering is not complete on its posterior surface, and this

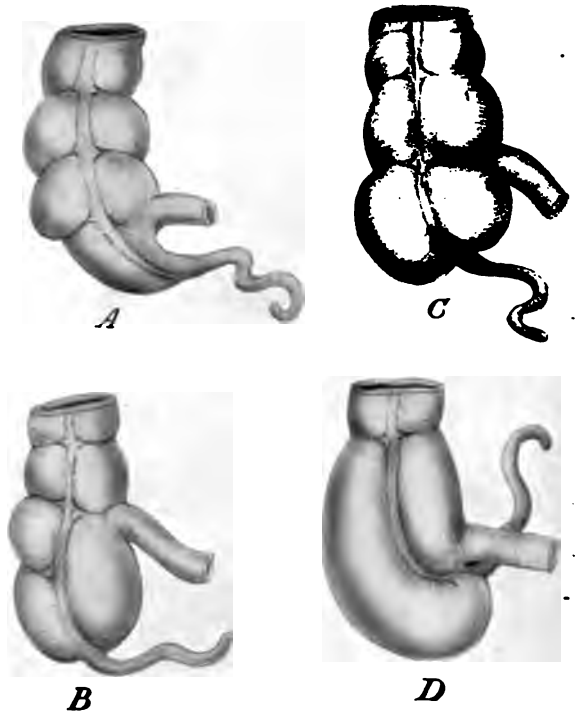

Fig. 209.—The Four Types of Cecum.

uncovered portion is connected to the iliac fascia by connective tissue.

The cecum has all the exterior characteristics of the large intestine—its sacculated form and its three longitudinal bands, which originate at the base of the appendix and thence diverge. The anterior longitudinal band is largest and most important. Practically, it forms an important landmark in finding the appendix.

The cecum is held in position above by the mesocolon, and this permits of a certain amount of mobility. Thus, in appendectomy it is usually possible to pull the cecum out through the abdominal incision to facilitate operative work. In like manner the cecum may find its way into an inguinal or femoral hernia.

Types of Cecum.—According to Deaver the cecum is found to be one of four types:

(*a*) *The Infantile Cecum.*—In this type the cecum is cone-shaped, the apex of the cone being continued into the appendix (Fig. 209, *A*) (2 per cent. of cases).

(*b*) The cecum consists of two equally large sacculi on either side of the longitudinal band. The appendix arises from between them (see Fig. 209, *B*) (3 per cent. of cases).

(*c*) *The Normal Cecum.*—The cecum consists of two sacculi, but of unequal size. The external is the largest; hence the base of the appendix is pushed over toward the ileocecal junction (Fig. 209, *C*).

(*d*) An exaggeration of *C*. The external sacculus remains, but the internal sacculus has disappeared. The appendix is attached posteriorly behind the ileocecal junction (Fig. 209, *D*) (4 per cent. of cases).

It will be noted that the position of the appendix varies with the type of the cecum.

Abnormal position of the cecum is of great practical interest to the surgeon because of the unusual location of symptoms in cases of appendicitis.

FIG. 210.—*A*, THE ILEOCECAL VALVE.

Recall the fact that the cecum originally lies on the left side of the abdominal cavity, and in the course of development migrates to the right iliac fossa. It may, therefore, be arrested in any part of its course; it may be found under the liver, behind the umbilicus, and in front of the right kidney. An extremely mobile cecum may occupy the pelvis.

The Ileocecal Valve.—The opening of the ileum into the cecum is guarded by a valve to prevent regurgitation from the colon to the ileum. The valve is formed like a button-

hole and consists of two segments or lips, an upper and lower segment, which project into the lumen of the large intestine (Fig. 210). When the cecum is full the lips of the valve are drawn together and the ileum shut off. When the cecum is emptied the lips of the valve are relaxed and the ileum opened. Thus the ileocecal valve works automatically according to the state of the cecum.

Note that the ileocecal valve is formed by an invagination of the ileum into the cecum. This anatomic formation explains the frequency of intussusception at this point.

Intussusception is the telescoping or invagination of one segment of bowel into the lower adjoining segment (Fig. 211). It may take place in any part of the small intestine, but *the ileocecal region is the most frequent site.* Note the reason for this as stated above—*the normal ileocecal junction is in the form of an invagination* (see Fig. 210). The usual form of intussusception is that in which the ileum with the cecum, is prolapsed into the colon, the ileocecal valve forming the apex of the protrusion. This form of intussusception may be so extensive that the ileocecal valve may reach the rectum and protrude through the anus.

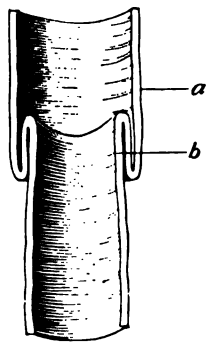

FIG. 211.—INTUSSUSCEPTION IN VERTICAL SECTION.
a, Intussuscipiens; *b*, intussusceptum.

Note the mechanics of an intussusception in a vertical section (see Fig. 211). It consists of three layers of bowel. The two inner layers—the *intussusceptum*, belong to the prolapsed portion; the outer layer—the *intussuscipiens*, the receiving portion.

Again, the two prolapsed layers have their peritoneal surfaces in contact; hence, the probability of them becoming adherent. The receiving portion and the prolapsed portion have their mucous surfaces in contact.

Observe the following facts: (*a*) Mechanical intussusception in itself does not produce intestinal obstruction. The obstruction is due to the subsequent swelling of the parts and the accumulation of feces.

(*b*) The prolapsed bowel carries along its vascular pedicle—the mesentery—and circulatory disturbances arise, such as

venous congestion, giving rise to bleeding within the bowel; arterial constriction producing gangrene of the prolapsed bowel, which may be sloughed off and spontaneous cure result, provided adhesions have previously been formed at the neck of the intussusception.

The clinical considerations of the cecum are chiefly those complications secondary to inflammation of the appendix. Ulcer and cancer of the cecum occur, but are much less frequent than in other parts of the intestinal tract. In intestinal obstruction the state of the cecum is an excellent guide to the site of the obstruction.

Rule.—If the cecum is markedly distended the obstruction is in the large intestine; if not, the obstruction is in the small intestine.

Foreign bodies which have been swallowed, if they pass the pylorus, are apt to lodge in the cecum and give rise to ulceration and perforation.

The cecum may be the site of fecal impaction which simulates an intra-abdominal neoplasm. These impactions may cause stercoral ulcers and even perforation.

THE VERMIFORM APPENDIX

The **vermiform appendix** is the undeveloped distal portion of the primitive cecum. In the fetus the distal portion of

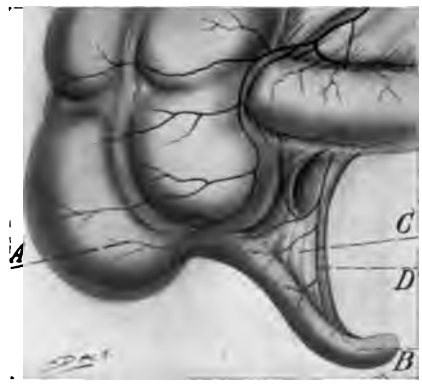

FIG. 212.—THE VERMIFORM APPENDIX (SEMI-DIAGRAMMATIC).
A, Cecum; *B*, vermiform appendix; *C*, meso-appendix; *D*, appendicular artery.

the cecum ceases to grow while the upper portion increases in size; hence, at birth there results a narrow tube, the appendix, hanging from the end of the cecum (Fig. 212).

This process of development is beautifully shown in the

infantile type of cecum, where the conical cecum gradually blends with the base of the appendix and persists through life in about 2 per cent. of cases (see Fig. 209). In studying the appendix this basic fact must be kept in mind.

The vermiform appendix is a long, narrow, musculomembranous tube attached to the lower end of the cecum, usually at a point corresponding to its inner and posterior wall. It lies, therefore, in the right iliac fossa opposite *McBurney's point*, which corresponds to the midpoint of a line drawn from the umbilicus to the anterior superior spine of the ilium. It attains its full development in early adult life and atrophies in old age.

Its *length* is, on an average, 3½. in. It may vary from 1 to 6 in., and extremes of 9 in. are reported. Its *diameter* is that of a goose-quill, or about ¼ in. Its *structure* resembles that of the large intestine.

Its *mucous membrane* contains a number of solitary glands and the glands of Lieberkühn. Just above the appendiceal orifice is a semilunar fold or reduplication of mucous membrane, the **valve of Gerlach**; this fold is not a true valve, but acts like a valve under certain conditions—viz., when the mucosa is inflamed and swollen, during muscular contraction of the appendix, and when the appendix forms an acute angle of junction with the cecum.

The *submucosa* is composed of areolar tissue and contains a large quantity of lymphoid tissue, most pronounced in the distal part of the appendix. This tissue is well developed in young adults and atrophies with age.

The preponderance of lymphoid tissue is a special characteristic of the appendix. For this reason it has been called the "*abdominal tonsil*," or an extensive Peyer's patch, and explains the susceptibility of the appendix to inflammatory processes.

The *muscular coat*, as in the small intestine, consists of an inner layer of circular fibers and an outer layer of longitudinal fibers. The circular layer is somewhat thicker than the longitudinal layer.

The *peritoneal coat* of the appendix is similar in arrangement to that of the small intestine. As a rule, it is entirely surrounded by peritoneum, the peritoneum meeting at its attached border to form the two layers of its mesentery or meso-appendix, which attaches the appendix to the cecum and the terminal portion of the mesentery.

The **meso-appendix** is the double layer of peritoneum derived

from the mesentery, which supports the appendix and forms its vascular pedicle. It presents a triangular outline, its base being formed by its free border, its sides by the appendix below and the cecum and ileum above (Fig. 213). It contains the appendicular artery, vein, lymphatics, nerves, and fat. The meso-appendix presents marked variations as to width, thickness, and extent of attachment. In children it is thin and transparent; in the adult it is thick, opaque, and more or less filled with fat. It may be attached the entire length of the appendix, but more frequently it is attached only about two-thirds of the distance, leaving the tip free. Sometimes it is entirely absent.

The length of the meso-appendix not only determines the mobility of the appendix, but modifies its general outline; thus,

FIG. 213.—THE MESO-APPENDIX AND VESSELS.

if the meso-appendix is short, it may produce an irregularly curved or cork-screw appendix. It may contain a congenital opening through which a loop of intestine may become strangulated, and O. A. Gordon has reported a case in which the appendix itself became strangulated through an aperture of its meso-appendix.

The Appendiculo-ovarian Ligament (Clado's Ligament).—In the female the meso-appendix is sometimes prolonged to the broad ligament by a fold of peritoneum which passes to the right ovary, containing the appendiculo-ovarian artery, which forms an anastomosis between the appendicular and ovarian vessels, and thus confers a greater vascularity upon the female appendix—a suggestive reason for its greater immunity against appendicitis.

In this fold the lymphatics of the appendix and ovary blend; this explains the reciprocal infection which may travel from one organ to the other when either is diseased.

The Blood-vessels of the Appendix.—The appendix is supplied by the appendicular artery (see Fig. 213), arising either from the ileocolic artery direct or from the posterior ileocecal artery. It passes between the two layers of the meso-appendix, coursing along its free border to the tip of the appendix, and gives off four or five secondary branches, which go directly to the appendix. Sometimes the artery extends only two-thirds of the length of the appendix, leaving the tip with a meager blood supply, and consequently less able to resist infection. When the meso-appendix is absent the artery courses along the appendix beneath the peritoneum, from base to tip. Remember the additional blood supply in the female appendix through the appendiculo-ovarian artery in Clado's ligament.

Variations.—Occasionally the appendix is supplied by more than one artery; its distal portion being supplied by one branch, its base by another. The surgeon sometimes finds a practical illustration of this when, after ligating the meso-appendix and, cutting it away, he finds in separating the base an unexpected hemorrhage; it is due to the presence of a secondary appendicular artery.

The **veins** of the appendix arise from a submucous and subperitoneal plexus which join through gaps in the muscular coat and pass into the meso-appendix, where they correspond to the arteries and enter into the formation of the portal system.

The **lymphatics** of the appendix are highly developed and play an important rôle in the pathology of this region. They consist of capillaries in the submucous and peritoneal coats, which freely communicate through gaps in the muscularis. These capillaries form collecting trunks, which run between the layers of the meso-appendix and accompany the appendicular artery (see Fig. 213).

They terminate: (*a*) Into the ileocecal glandular group, which is continuous with the mesenteric glands.

(*b*) Into the ceco-appendicular group, which occupy the angle formed by the internal aspect of the cecum and the root of the appendix. It becomes continuous above and behind the cecum with the retrocolic ganglia.

(*c*) Recall the fact that the lymphatics of the appendix and right ovary communicate through Clado's ligament.

Thus, as Tixier and Viannay pointed out, the appendix is an

organ of double insertion—cecal by its root, ileal by its mesentery, and similarly divides its lymphatic circulation into two main currents, one directed toward the cecum and mesocolic glands, the other toward the ileum and mesenteric glands. Hence, the ramifications of the appendiceal lymphatics are extensive, either in the direction of the mesentery or the ascending colon.

Note that they may extend even to the pleura, since the lymphatics of the peritoneum communicate with those of the pleura through the diaphragm. Indeed, some observers believe that the peritoneal lesions observed during the course of appendicitis are not always due to a perforation of the

FIG. 214.—THE PERICECAL FOSSÆ.
A, Ileocolic fossa; *B*, ileocecal fossa; *C*, subcecal fossa.

appendix, but frequently to a lymphatic infection of the peritoneum.

The **nerves** of the appendix come from the superior mesenteric plexus, which also supplies the small intestines; hence, the pain in appendicitis may be general in character, or referred to various parts of the abdomen before localizing in the appendicular region.

The **pericecal fossæ** are pouches formed in the ileocecal region by certain peritoneal folds. These fossæ are of practical importance to the surgeon, because the appendix may occupy any one of them and constitute either a retroperitoneal hernia or be so concealed within the fossæ that the organ may be thought to be absent.

When the appendix cannot be found suspect the pericecal fossæ, and remember they are three in number and well defined.

(*a*) The **ileocolic fossa** lies above the ileocolic junction. It is formed by a fold of peritoneum passing across the ileocolic angle (Fig. 214, *A*). Its opening is directed downward toward the appendix, but it is situated too far from the appendix to assume an important rôle in appendicitis.

(*b*) The **ileocecal fossa** is situated behind a peritoneal fold, at the angle of junction of the ileum and cecum (Fig. 214, *B*). This fossa is constant and large enough to admit two fingers. Its depth varies; at times it may extend upward behind the ascending colon as far as the right kidney and duodenum (Deaver). This fossa is of great practical importance, since it is frequently occupied by the appendix.

When the appendix cannot readily be found investigate this fossa first.

(*c*) The **subcecal fossa** is situated behind the cecum and ascending colon, and may be demonstrated by raising the cecum (Fig. 214, *C*). Its position is such that it does not play an important rôle in appendicitis.

Variations in the Position of the Appendix.—While the appendix normally lies in the right iliac fossa, it must be remembered that *the appendix may occupy any position in the abdominal cavity from the liver to the pelvis.*

These variations are of two kinds: (*a*) The appendix may vary in its relation to the abdominal cavity, due to arrested fetal development of the cecum. Recall the fact that the cecum in migrating from the left side of the abdominal cavity to the right iliac fossa may be arrested in any part of its course—under the liver, behind the umbilicus, or in front of the right kidney. If the cecum is extremely mobile it may occupy the pelvis. The appendix follows the cecum; hence, the practical value of these facts in the symptomatology of appendicitis.

(*b*) The appendix may vary in its relation to the cecum, as it normally lies in the right iliac fossa. This variation depends upon the type of cecum (see p. 399) and the length of the meso-appendix.

While the appendix may point in any direction, the most frequent positions of the appendix are well summarized by Kelly, as follows:

(*a*) The appendix is most frequently given off by the cecum

at a point corresponding to its inner and posterior wall, and lies hidden behind the ileocecal junction.

Appendices in this position are found in about 40 per cent. of the cases.

(*b*) The second most frequent position of the appendix is that ascending vertically behind or lateral to the cecum and ascending colon, and attached to the dorsal wall of the large intestine. This position is found in 30 per cent. of the cases, and is associated with an absence of the meso-appendix. If the colon is adherent to the posterior abdominal wall the appendix occupies an extraperitoneal position. Kelly suggests that the frequent occurrence of appendicitis in appendices lying in this position is due to the abnormal degree of friction to which they are subjected by the contraction of the psoas muscle.

(*c*) The third most common position of the appendix is the pelvic, which occurs in about 20 per cent. of cases. It is due to a low position of the cecum and a long mesentery.

In addition to the above positions, a long mesentery may give the cecum a wide range of motion and account for the appendix being found in an umbilical, inguinal, or femoral hernia on either side.

Clinical Considerations.—The relative insignificance of the appendix as an abdominal organ, and the important rôle which it plays in abdominal pathology has led to much speculation concerning the cause which confers upon this small organ such pathologic importance.

The answer is found in its anatomic location, conformation, and structure.

The etiologic factors in appendicitis may be grouped under three heads:

Defective drainage.

Defective structure.

Defective blood supply.

Defective drainage is the most important of the etiologic factors in causing appendicitis, because it is basic. Consider first the excessive length, compared with the lumen of the appendix. It is a long, narrow tube. Again, the tube is not only long and narrow, but it is blind at one extremity, while at the other it communicates with the cecum, a very center of infectious material. The tube is not only blind at its distal extremity, but is guarded by a valve at its cecal orifice (the valve of Gerlach). If, therefore, the appendix is joined to the cecum at an acute angle, or if the mucosa in the neighbor-

hood of the valve be swollen, there results a tube with both extremities sealed and all drainage eliminated. The meso-appendix also, if it be too short, will cause a curling or twisting of the appendix and contribute an additional obstruction to free drainage. All these factors operating singly or in conjunction are significant factors in appendiceal inflammations.

Defective Structure.—Recall the relatively large amount of lymphoid tissue which the appendix contains (the "abdominal tonsil"). This tissue is of low vital resistance, specially prone to bacterial invasion. It is most fully developed in the young adult, a period when appendicitis is frequent, and atrophies with age, a period when appendical lesions diminish. It is most abundant at the distal end—the very site of the maximum lesion in appendicitis. Not only this, but we have here a particularly susceptible tissue contiguous to a particularly infectious center. All these facts suggest that the appendix is histologically prone to inflammatory processes.

Defective Blood Supply.—The appendicular artery is usually a terminal artery, and does not anastomose with the vessels of the cecum. A twist of the meso-appendix, a thrombosis of the vessel, is compensated by no anastomotic aid, obstruction means appendicular gangrene, either partial or complete. Again, note how frequently the appendicular artery courses along the appendix for only two-thirds of its length, leaving the tip of the appendix with a meager blood supply; may this not account for the tip being the site of the maximum lesion in appendicitis?

Note the additional blood supply in the female, through the ligament of Clado. Does this not suggest the cause of the greater immunity against appendicitis which the female possesses?

The appendix may become the *cause of intestinal obstruction* by its tip becoming adherent to a neighboring peritoneal surface, and form a band beneath which a loop of intestine may become strangulated.

Appendicostomy.—Through the ingenious suggestion of Weir the appendix has been utilized in colitis as a means of irrigating the colon. The appendix is brought up and fastened in the abdominal wound and an opening made in its tip.

THE COLON

The large intestine extends from the cecum to the rectum, and presents marked differences from the small intestine in its length (about one-fifth), its fixed position, *its sacculated form, its longitudinal bands, its appendices epiploicæ,* and its direction.

It begins in the right iliac fossa in the cul-de-sac constituting the cecum, and ascends vertically to the lower border of the liver, where it bends to the left, forming the *hepatic flexure.* It then passes transversely across from right to left to the lower surface of the spleen, where it forms another bend, the *splenic flexure,* and descends vertically to the left iliac fossa, where it forms a convoluted loop, the *sigmoid flexure.* It finally enters the pelvis on the left side of the sacrum and forms the rectum. Thus, the large intestine forms an incomplete hollow square in which lies the mobile small intestine (Fig. 215).

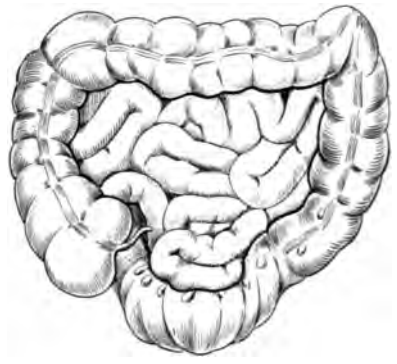

FIG. 215.—SHOWING THE HOLLOW SQUARE FORMED BY THE LARGE INTESTINE, WITHIN WHICH ARE THE COILS OF SMALL INTESTINE.

The large intestine, from the cecum to the beginning of the mesorectum opposite the third sacral vertebra, is about 5 ft. in length. Its diameter decreases from above downward, the cecum measuring about 3 in., the sigmoid 1½ in. The large intestine is not nearly so movable as the small intestine, and consequently is rarely met with in hernia. It is composed of the same coats as the small intestine, but their arrangement presents certain special characteristics.

(*a*) The peritoneum does not furnish as complete a covering to the large as to the small intestine; hence, its fixed position compared with the mobility of the small intestine.

(*b*) The muscular layer, as in the small intestine, presents two kinds of fibers, the superficial longitudinal and the deep circular. The former, however, instead of being regularly distributed around the intestine, are arranged in three longitudinal bands, which present a ligamentous aspect. They start from the root of the vermiform appendix, the anterior being the largest and most prominent. They are about half as long as the actual length of the large intestine; hence, they tend to pucker up the intervening intestinal walls into three rows of sacculi (Woolsey) (Fig. 216). From the sigmoid flexure onward the longitudinal bands cease and the longitudinal fibers surround the entire circumference of the intestine. These longitudinal bands form a valuable landmark in differentiating the large and small intestine and in locating the appendix, since they inevitably lead to its base.

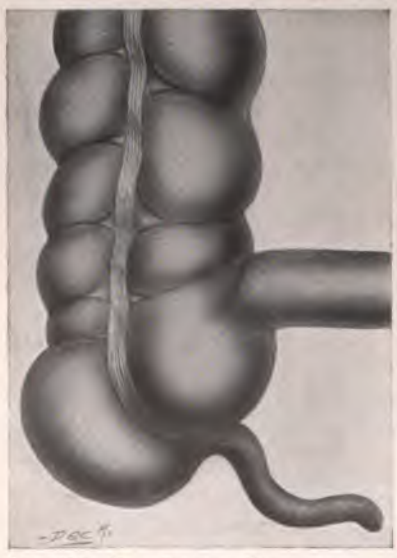

FIG. 216.—THE SACCULI FORMED BY THE LONGITUDINAL BANDS OF THE LARGE INTESTINE.

(*c*) The *appendices epiploicæ* are small tassels of peritoneum, containing fat attached at irregular intervals to the entire large intestine except the rectum. They are very numerous along the anterior longitudinal band.

Differential Landmarks in the Large Intestine.—During the course of an operation it is often essential to distinguish at a glance a loop of intestine which presents in the wound. The differences between the large and small intestine are well marked and unmistakable.

The three differential characteristics of the large intestine are:

(*a*) *Its longitudinal bands.*

(*b*) *Its sacculated form and transverse furrows.*

(*c*) *Its appendices epiploicæ (tassels of fat).*

Capacity of the Colon.—According to Woolsey, the colon of an infant six months old holds one pint, that of a

child two or three years old two or three pints, that of an adult nine pints. Irrigation of the colon is a procedure of great value in many conditions, not only for its local effect, but because of the active peristalsis which it excites in the small intestine. Its capacity should be borne in mind when irrigation is used.

The *mucous membrane* of the large intestine possesses neither villi nor valvulæ conniventes. The glands of Lieberkühn are distributed throughout its entire length, and solitary follicles are arranged in patches, as in the small intestine.

The **blood-vessels** of the large intestine come from branches of the superior mesenteric and inferior mesenteric arteries. The veins follow the course of the arteries, and form the radicals of the portal system.

The **nerves** and **lymphatics** of the large intestine differ in no important respect from those of the small intestine.

The **ascending colon** is very short, occupying only the space between the iliac crest and the under surface of the liver. Commencing at the cecum, the ascending colon passes upward, occupying the right lumbar fossa, and reaches the under surface of the liver and gall-bladder where it makes a rectangular bend to the left, forming the *hepatic flexure*.

In 75 per cent. of cases the ascending colon is covered by peritoneum only on its anterior and lateral surfaces, its posterior surface being connected by loose areolar tissue to the back of the abdomen and the front of the right kidney. In 25 per cent. of cases it is entirely invested by peritoneum, and possesses a distinct mesocolon from 1 to 3 in. in length.

When the ascending colon is empty it is covered by the coils of small intestine, but when distended by gas or feces it is in contact with the anterior abdominal wall. It passes directly in front of the right kidney; hence, abscesses of the kidney may discharge into the colon. Likewise in tumor of the kidney, adhesions may be contracted and the colon wounded in nephrectomy. Adhesions between the gall-bladder and hepatic flexure have frequently been noted, and gall-stones have ulcerated through the colon and been thus discharged per rectum.

Note how easily tumors of the hepatic flexure may be mistaken for tumors of the liver or gall-bladder.

The **transverse colon** commences at the hepatic flexure and passes from right to left across the abdominal cavity, just above the umbilicus. At the lower border of the spleen

it makes a sharp bend downward, forming the splenic flexure. Its direction is not exactly horizontal, but is inclined obliquely upward, so that its splenic angle is higher than its hepatic angle (Fig. 217). Likewise in its course it describes an arch, the concavity of which is directed backward, so that the apex of the curve is in contact with the anterior abdominal wall, while its extremities, the flexures, are deeply situated. Anteriorly, as already noted, are attached the anterior layers of the great omentum.

The transverse colon is the most movable portion of the colon, being completely invested by peritoneum and connected to the back of the abdomen by the transverse mesocolon, which practically forms a partition separating the stomach and spleen from the small intestines.

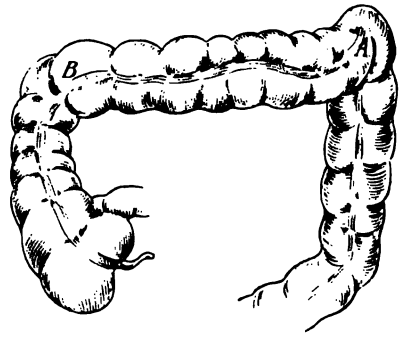

FIG. 217.—THE TRANSVERSE COLON.
Note the higher position and more acute angle of (*A*) the splenic flexure, as compared with (*B*) the hepatic flexure.

The position of the transverse colon is subject to great variations. In some cases it may reach an abnormally low level, the central portion forming a V- or U-shaped bend, the summit of which may reach as far as the pelvis. Causes which contribute to this condition are chronic constipation, tight lacing, and general *enteroptosis*. It is worthy of note that these displacements of the transverse colon are three times as frequent in women as in men.

According to Taylor, a pendulous colon may acquire adhesions, within the female pelvis, to the uterus, ovaries, and Fallopian tubes, and cause a kinking of the gut sufficient to produce obstruction of its contents.

An abnormally long transverse colon may occupy the sac of an umbilical, inguinal, or femoral hernia.

The **descending colon** extends from the splenic flexure through the left lumbar region, along the outer border of the left kidney, to the crest of the ilium, where it terminates in the sigmoid flexure. According to Treves, there is no descending mesocolon in 64 per cent. of cases, the peritoneum covering the front and sides, only leaving the posterior portion uncovered and connected with the back of the abdomen by areolar tissue, while a descending mesocolon may be expected in 36 per cent. of all cases.

At its beginning it is attached to the diaphragm by a fold of peritoneum, the *phrenocolic ligament.* Furthermore, the splenic flexure forms an acute angle, which is rendered more or

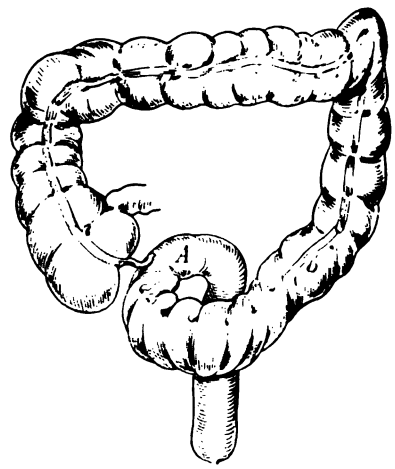

FIG. 218.—*A*, THE SIGMOID FLEXURE (SEMIDIAGRAMMATIC).

less inflexible by the presence of the phrenocolic ligament. Hence, this angle constitutes an actual obstacle to the passage of feces in intestinal obstruction, due to retention, and likewise explains the cause of *pain in the left scapular region, due to chronic constipation.* Observe that traction of a distended colon on the phrenocolic ligament causes sensory disturbance along the left phrenic nerve, which is transmitted to the fifth and sixth cervical nerves and thence to the suprascapular nerve.

The **sigmoid flexure** or, better, the sigmoid loop, extends from the left iliac crest to the third sacral vertebra, where it becomes continuous with the rectum (Fig. 218). It forms an

omega-shaped loop about 17 in. long, the extremities of which are fixed and are only from 3 to 4 in. apart. Owing to the length of its mesocolon, the sigmoid is very mobile and for the most part occupies the pelvis. In appearance it differs from the rest of the large intestine in two respects:

(*a*) The sacculi disappear and consequently it presents a smoother appearance.

(*b*) The longitudinal bands disappear, but their fibers are spread uniformly over its surface.

The Intersigmoid Fossa.—When the sigmoid is lifted up and the mesosigmoid made taut, a funnel-shaped pouch is seen at the parietal border in the left wall of the mesosigmoid. The opening looks downward and to the left, and is situated over the bifurcation of the iliac vessels. This fossa is the site of a rare form of hernia, *sigmoid hernia*, of which 3 cases have been reported, all terminating in death.

The anatomic peculiarities of the sigmoid naturally predispose it to variations in position, enormous dilatation from fecal accumulations, and to a form of intestinal obstruction known as *volvulus*, which is discussed in detail on the next page.

Surgical Considerations.—Wounds of the large intestine are not as grave as those of the small intestine, for the reason that the consistency of the fecal material is such that it does not immediately pour out and infect the peritoneal cavity.

Obstruction of the large intestine may be due to neighboring tumors pressing on the bowel, or to fecal accumulations and cicatricial and malignant stricture.

Fecal accumulations are most liable to occur at the splenic flexure, where the colon is bent at an acute and fixed angle; or in the sigmoid flexure, which may, under these circumstances, resemble a *mobile cyst attached to the posterior abdominal wall*, or with an obstruction in the rectum it may become a fecal reservoir, so distended as to occupy the greater part of the abdominal cavity.

When distention occurs from obstruction low down, the large intestine can be defined on the surface of the abdomen throughout its entire course, except at the flexures, which are deeply placed. The distention is specially marked in the flanks and just above the umbilicus.

Malignant stricture occurs most frequently at the flexures, and obstruction is manifest more rapidly than in the small intestine, owing to the solid character of the feces. This con-

dition is usually preceded by symptoms of chronic obstruction, although an acute obstruction may at any moment be precipitated.

Colostomy is the establishment of an artificial anus by providing an opening in some part of the colon. The indications for this operation are chronic and irremovable obstruction, imperforate anus, and ulcerative conditions of the colon which require rest from fecal contamination.

Two forms of colostomy are possible:

(*a*) *Lumbar Colostomy.*—The colon is opened in the lumbar region through its posterior surface, where it is uncovered by peritoneum; hence, the operation can be performed without opening the peritoneum. This latter was a potent consideration in pre-antiseptic days, but in modern surgery it has no place, since a lumbar colostomy is both unsatisfactory and unnecessary.

(*b*) *Inguinal colostomy* may be performed either upon the right or left sides, depending upon the location of the obstruction. It is much more frequently performed upon the left side, since the site of obstruction is much more common, either at the distal end of the colon or in the rectum.

The following anatomic points should be remembered:

(*a*) The incision is made on the left, similar to that which is made on the right side for the removal of the appendix.

(*b*) The abdominal muscles should be split, and not divided, in order that subsequently there may be a modified sphincteric control over the artificial anus.

(*c*) The highest point of the sigmoid is selected and fixed in the wound. This portion of the sigmoid is chosen because it is the stationary portion, and the tendency to prolapse is thus abolished.

(*d*) A dislocated transverse colon may be mistaken for the sigmoid, unless the characteristics of the latter be kept in mind (see page 414).

Volvulus refers to a form of intestinal obstruction caused by a twisting of the bowel. It is more commonly met with in the sigmoid flexure than in any other part of the canal. Recall the anatomy of the sigmoid, and the reason for this is apparent. It is an omega-shaped loop, very mobile, with its extremities not more than 3 in. apart and fixed. Hence, this pendulous loop with its fixed pedicle is anatomically predisposed to become twisted. Now exaggerate these conditions by chronic constipation until the sigmoid loop is two

or three times as long as normal and heavy with accumulated feces, and the mechanics of volvulus becomes plain.

Volvulus shows a decided tendency to recur, and simply untwisting the bowel does not remove the cause. To prevent a recurrence various procedures have been suggested, such as stitching the loop to the anterior abdominal wall, or even excising the implicated loop (Moynihan).

THE LIVER

The **liver** is the largest and most important gland of the body. It is situated in the upper right portion of the abdominal cavity, occupying the entire right hypochondrium, a portion of the epigastrium, and reaching as far as the left hypochondrium, about 1½ in. beyond the left margin of the sternum.

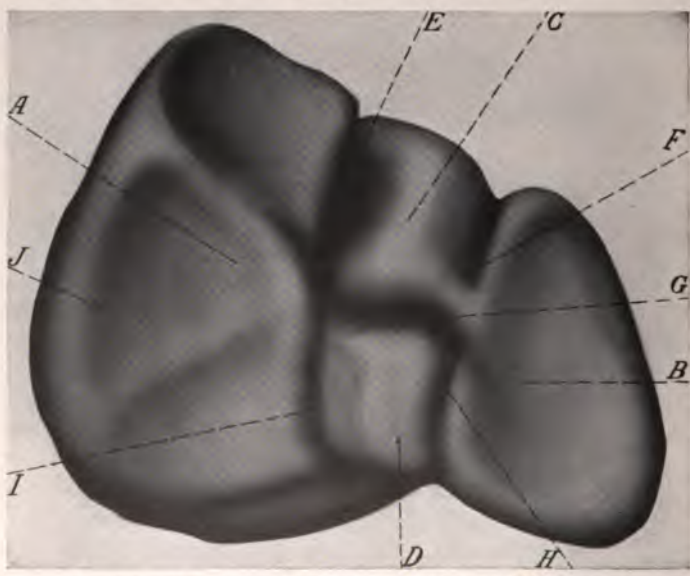

FIG. 219.—THE FISSURES OF THE LIVER, FORMING THE LETTER H.
A, Right lobe; *B*, left lobe; *C*, quadrate lobe; *D*, Spigelian lobe; *E*, fissure of the gall-bladder; *F*, umbilical fissure; *G*, transverse fissure; *H*, fissure of the ductus venosus; *I*, fissure of the vena cava; *J*, longitudinal fissure.

Its upper convex surface is moulded to the arch of the diaphragm, which separates it from the pleura, the lungs, the pericardium, and heart. Its lower or visceral surface is in contact with the right kidney, the suprarenal capsule, the hepatic flexure, the duodenum, and stomach.

On the under surface of the liver may be seen the **fissures of the liver,** so arranged as to form the letter H, and dividing the liver into its various lobes (Fig. 219). They are the *longitudinal fissure* and the *fissure of the ductus venosus*, the *transverse fissure*, the *fissure for the gall-bladder*, and the *fissure for the inferior vena cava.*

Note that the under surface of the liver presents certain depressions by which it is moulded to the various viscera with which it is in contact; thus, on the left lobe is the *gastric impression*, where it is moulded to the anterior surface of the stomach. On the right lobe are four depressions; the anterior is the *colic impression*, produced by the hepatic flexure of the colon. The middle is the *renal impression*, occupied by the upper end of the right kidney. The posterior is the *suprarenal*

A *B*

FIG. 220.—THE SURFACE MARKINGS OF THE LIVER.
A, Anterior view; *B*, posterior view.

impression, devoid of peritoneum, which lodges the right suprarenal capsule and is placed between the liver and the diaphragm. Internal to the renal impression is a slight depression, the *duodenal impression*, to which is moulded the second portion of the duodenum.

These relationships are all of practical importance, and will be referred to in the clinical considerations of the liver.

Surface Markings (Fig. 220).—The normal surface anatomy of the liver should be accurately known, in order that its variations from the normal may be determined by palpation and percussion.

Note that the liver occupies that portion of the abdominal cavity which is overlapped by the thoracic cavity; hence, its surface outlines are mainly on the lower part of the right

thorax. Remember that in the infant the liver is relatively much larger than in the adult, extending below the costal margin, and to the left as far as the spleen.

The *upper margin of the liver in front* is represented by a line drawn from the upper margin of the fifth rib on the right (½ in. below the nipple). This line should curve downward at its midpoint to the base of the ensiform cartilage.

On the *side* the upper limit corresponds to the seventh intercostal space in the midaxillary line; *behind* to the ninth intercostal space in the scapular line.

The *lower margin of the liver* follows the border of the right costal arch as far as the ninth costal cartilage, where it crosses the epigastrium obliquely to the eighth costal cartilage in the left and joins the left extremity of the upper margin (1 in. below the left nipple). In the median line the lower border of the liver is about a hand's-breadth below the base of the ensiform cartilage. The left lobe lies to the left of the median line and the interlobular notch is opposite the median line.

Note that the normal liver is in contact with the anterior abdominal wall only over a triangular area formed by the subcostal angle and the line representing its lower margin. Hence, this is the most accessible portion of the liver. Note also that the upper portion of the liver is overlapped by the lung, the lower portion being separated from the ribs by the *costophrenic sinus;* hence, only the pleura and diaphragm separate the liver from the chest wall at this point. This fact must be remembered in percussing the liver, since the interposition of the lung gives an area of *relative liver dulness,* whereas over the portion which is in direct parietal contact there is *absolute liver dulness.* Again, the lower margin of the liver rises and falls with respiration; hence, *tumors of the liver follow the respiratory movements.*

The position of the liver varies with the condition of the neighboring organs. In emphysema of the lung or collections of fluid in the right pleural cavity the diaphragm is at a lower level and the liver is, therefore, pushed down. In phthisis the diaphragm ascends and the liver is on a higher level. The liver rises or falls, according as the stomach and intestines are distended or empty. When the thorax is constricted by tight lacing the liver may be displaced to a considerable extent.

Ligaments of the Liver.—The liver is almost completely invested by peritoneum, which at certain points gives off reflections to form ligaments.

The **falciform** or **suspensory ligament** is a vertical fold of peritoneum passing anteroposteriorly. It is attached to the convex surface of the liver, the under surface of the diaphragm, and the posterior sheath of the right rectus muscle, to within 1 in. of the umbilicus. It divides the convex surface of the liver into two unequal lobes, the right being much larger than the left. Thus the space between the convex surface of the liver and the diaphragm, the *subphrenic space,* is divided by the suspensory ligament into two parts, a right and a left, each corresponding to the right and left lobes of the liver. *Subphrenic abscess* may develop in this space, and, as a rule, is usually secondary to gastric ulcer.

The **coronary ligament** is a transverse fold of peritoneum which connects the posterior border of the liver to the diaphragm. Note that the two layers of peritoneum which form this ligament are separated at the liver junction to the extent of 4 to 5 cm., leaving a large triangular area uncovered by peritoneum and connected to the diaphragm by areolar tissue. On the sides the layers of the coronary ligament approach each other and form the *right* and *left lateral ligaments.* The suspensory and coronary ligaments may be absent. This condition accounts for certain cases of congenital mobility of the liver.

Additional Supports to the Liver.—(*a*) The *inferior vena cava* is undoubtedly an important factor in giving support to the liver, because it is firmly attached to the diaphragm as it passes through, and is intimately connected with the liver by the subhepatic veins, which leave the substance of the liver and open into the vena cava. Sometimes when the ligaments are relaxed the vena cava is dragged from its normal position by the weight of the liver (Faure).

(*b*) *Intra-abdominal pressure* is another important if not the chief factor in maintaining the liver in position. The abdominal muscles by their contraction push the viscera up beneath the liver, and form for it an elastic and adjustable cushion which exactly adapts itself to the physiologic mobility of the liver.

The Blood-vessels.—The circulation of the liver, like that of the lung, is distinctive, in that it possesses two blood systems—a *nutritive circulation,* formed by the hepatic artery and the hepatic veins; and a *functional circulation,* formed by the portal vein.

The **vascular pedicle** of the liver is formed by the gastrohepatic omentum, which, as already shown, forms the anterior

border of the foramen of Winslow and contains the common bile duct, the portal vein, and the hepatic artery in the order named, from right to left. Note the accessibility of this vascular pedicle and how easily it may be compressed, should necessity require it during the course of an operation upon the liver.

The **hepatic artery,** a branch of the celiac axis, ascends between layers of the gastrohepatic omentum, accompanied by the portal vein and the bile duct. It enters the transverse fissure of the liver and furnishes branches to all the constituent elements of the gland.

The **hepatic veins** begin in the substance of the liver and unite to form three veins which empty into that portion of the inferior vena cava which lies in a groove on the posterior aspect of the liver. These veins are surrounded by very

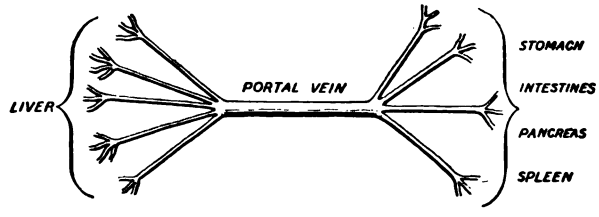

FIG. 221.—THE PORTAL VEIN.
Begins and ends in a capillary system.

little connective tissue and possess no valves; hence, when sectioned, they lie open.

They are distinguished from the branches of the portal vein by the fact that the latter are always accompanied by an artery and duct, and always collapse when cut.

The Portal System.—The distinguishing feature of the portal circulation is the fact that it begins and ends in a capillary system, as follows (Fig. 221):

(*a*) The capillaries of the stomach, intestine, pancreas, and spleen unite to form the superior mesenteric and splenic veins, which in turn join behind the head of the pancreas to form the portal vein.

(*b*) The *portal vein*, about 4 in. in length, passes upward behind the first portion of the duodenum between the layers of the gastrohepatic omentum, the common bile duct lying to the right, the hepatic artery to the left. At the transverse fissure of the liver it divides into a right and left branch, which enter the respective lobes of the liver.

(*c*) It breaks up into capillaries within the liver and accom-

panies the ramifications of the hepatic artery and duct throughout the substance of the liver. The capillaries of the portal vein finally anastomose with those of the hepatic vein, by which the blood is carried to the inferior vena cava.

There are certain *accessory portal veins* which form a communication between the portal and systemic venous systems. They are found in the peritoneal folds which unite the liver to the abdominal wall and the diaphragm. These veins are normally small and unimportant, but in case of obstruction to the portal vein they enlarge and assume considerable importance in establishing a collateral circulation.

The principal anastomoses are:

(*a*) Between the superior hemorrhoidal vein and the branches of the middle and inferior hemorrhoidal veins.

(*b*) Between the branches of the gastric and the esophageal vein.

(*c*) Between the portal vein and the superficial veins of the abdominal wall.

Note, in this connection, how in the radical cure of ascites an accessory anastomosis is established between the portal and general circulation by forming adhesions between the omentum and anterior abdominal wall (epiplopexy, see p. 371). Bearing in mind the intermediary relation which the portal vein holds between these two systems of capillaries, it is not difficult to understand the remote effects of obstruction to the portal circulation; for example—

Cirrhosis of the Liver.—Here the increase of fibrous tissue within the portal canals gradually contracts, narrowing the lumen and compressing the portal branches; the circulation is not so free, a back pressure is established, the vessels forming the portal vein (stomach, intestine, pancreas, and spleen) are overdistended, transudation of serous fluid into the abdominal cavity takes place and *ascites* results, or into the lumen of the bowel and diarrhea results. Note also *enlargement of the spleen* in cirrhosis of the liver (due to venous engorgement), as well as dilatation of the gastric veins, sometimes resulting in hemorrhage and hemoptysis.

In *valvular disease of the heart* note how the obstructed circulation causes back pressure in the inferior vena cava, the hepatic veins, and portal capillaries. This chronic engorgement terminates in structural changes, known as *nutmeg liver*. No less notable are the effects of pressure upon the portal vein by neighboring tumors.

The **lymphatics** of the liver are divided into a superficial set, which arise from the peripheral lobules and course beneath the peritoneum, and a deep set, which start from the lobules and emerge from the liver in company with the portal and hepatic veins.

According to Poirier, these lymphatics terminate in five glandular groups:

(1) The glands of the hilum.

(2) The intrathoracic glands around the terminal segment of the inferior vena cava.

(3) The supraxiphoid glands.

(4) The peri-esophageal glands, which are continuous with the gastric coronary chain group.

(5) The glands placed round the celiac axis.

The **nerves** of the liver are from three sources—the left pneumogastric, the solar plexus, and the right phrenic. *Pain over the right shoulder is significant of liver disease.* Note how it is reflected along the right phrenic to the fourth cervical nerve, and thence to the supra-acromial nerve.

Clinical Considerations.—In practically applying the anatomic facts to the clinical manifestations it is necessary to keep well in mind four facts concerning the liver: its extensive relationship, its fixed position, its great friability of structure, and its great vascularity.

Wounds of the Liver.—Although the liver is well protected by the overlying ribs it is more frequently ruptured from contusion than any other abdominal viscus. This is undoubtedly due to its fixed position and friable structure (Treves). Such injuries are followed by grave hemorrhage and death. The gravity of the hemorrhage is due to the fact that the torn veins possess no valves and are adherent to the liver tissue, and, therefore, neither retract nor collapse. Note that rupture of the liver may occur without involving the peritoneal coat, but is not usually fatal. Penetrating wounds of the liver through the chest wall involve the pleura, the lung, the diaphragm, and peritoneum; a fractured rib may penetrate the diaphragm and injure the liver.

In wounds of the liver with active hemorrhage remember that the hemorrhage may be temporarily stopped by introducing the finger into the foramen of Winslow and compressing the gastrohepatic omentum—the vascular pedicle of the liver containing the hepatic artery and portal vein.

The friability of the liver precludes the use of hemostatic

forceps and ligature. Suture ligatures, applied with the greatest care, the actual cautery, or iodoform gauze packing are measures best adapted to the conditions.

Abscess of the liver is of two varieties: (*a*) Multiple or pyemic abscess.

(*b*) Single or tropical abscess.

The former cannot be benefited by surgical treatment. The latter are of great surgical interest because of their com-

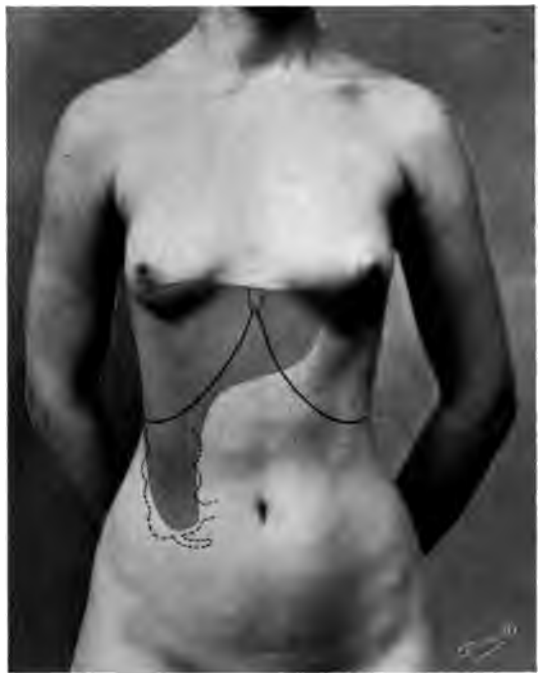

FIG. 222.—RIEDEL'S LOBE (case of Bates).
Tongue-like lobe of liver. Shaded portion "liver." Broken line "ascending colon." Black line indicates line of ribs.

plicated symptomatology and their curability through surgical intervention.

Recall the relations of the liver and note the possible consequences of an abscess. If it makes its way to the convex surface of the liver it may ulcerate through the diaphragm, form adhesions, and perforate the lung, to be evacuated by the bronchi. Hence there may be symptoms of pleuropulmonary irritation, and errors in diagnosis are liable to occur.

If, on the other hand, it makes its way downward, it may open into the peritoneal cavity, or by forming adhesions with the abdominal wall find its way to the surface, or with a neighboring viscus open into the stomach, duodenum, or colon.

Hydatid cysts are more frequently found in the liver than in any other of the viscera. They attain a large size and may evacuate their contents along the same paths as an hepatic abscess.

Riedel's lobe is a tongue-like process of liver continuous with the right lobe, sometimes extending as far down as the right iliac fossa (Fig. 222). While the cause is not definitely known, it is a fact that tongue-shaped lobes are much more frequent in women, and the probable explanation may be found in tight lacing and cholelithiasis. The latter cause is substantiated by Terrier and Auvray, who assert that in seven cases where the morbid condition of the gall-bladder was treated the tongue-like lobe disappeared.

Many errors in diagnosis may arise, since Riedel's lobe appears as an abdominal tumor on the right side of the abdomen, descending with the liver on respiration, and sometimes tender on pressure. When it reaches as far as the right iliac fossa it may simulate appendicitis. If it is connected with the liver only by a pedicle it may appear as a movable tumor and simulate a floating kidney.

THE GALL-TRACT

The **gall-tract** consists of the gall-bladder, the cystic duct, the hepatic duct, and the common duct (Fig. 223).

The **gall-bladder** is pear-shaped and is divided into a fundus, body, and neck. It is attached in its long diameter to the lower dome-shaped surface of the liver by connective tissue and covered by peritoneum.

Sometimes this attachment assumes the form of a mesentery and allows a certain range of movement on the part of the gall-bladder. In one of the author's dissections a gall-bladder was found filled with stones, having a distinct mesentery long enough to produce a condition of ptosis of the bladder and angulation of the cystic duct.

The only part of the gall-bladder in contact with the abdominal wall is the fundus, which slightly projects beyond the anterior margin of the liver at a point opposite the intersection of the costal margin and the outer border of the right rectus muscle (Fig. 224).

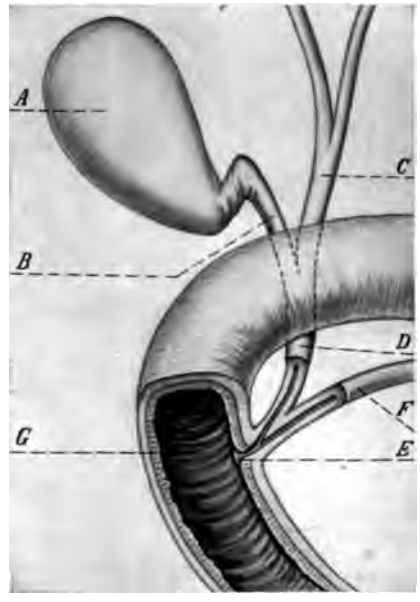

FIG. 223.—THE GALL-BLADDER AND BILE-DUCTS.
A, Gall-bladder; *B*, cystic duct; *C*, hepatic duct; *D*, common duct; *E*, ampulla of Vater; *F*, pancreatic duct; *G*, duodenum.

FIG. 224.—SAGITTAL SECTION OF GALL-BLADDER AND DUCTS.
Note (*A*) the fundus is in contact with the abdominal wall.

To define the point on the surface of the body *draw a line from the right nipple to the umbilicus. At the point where this*

line crosses the costal margin is found the contact point of the fundus of the gall-bladder with the anterior abdominal wall (see Fig. 167).

The length of the gall-bladder is about 3 in.; its widest diameter about 1½ in.; its capacity about 1½ oz.

The long diameter of the body of the gall-bladder is directed upward, backward, and to the left. As it approaches the neck there is a distinct S-shaped curve, gradually narrowing until it ends in the cystic duct.

The walls of the gall-bladder are composed of three coats, the outer or peritoneal, the middle fibromuscular, which makes it very tough and capable of great distention, and the inner, or mucous coat.

The arrangement of the mucous membrane is worthy of consideration. It is thrown into folds which become more pronounced as the neck and cystic duct are approached. These folds are known as the *valves of Heister* and prevent the passing of a sound into the normal cystic duct.

Relations.—The gall-bladder is in relation with the under surface of the liver above and with the second part of the duodenum and the transverse colon below, the fundus being in contact with the anterior abdominal wall. Thus it is possible to anastomose the gall-bladder with the duodenum or colon to deflect the flow of bile when obstruction exists in the common duct.

The **blood supply** of the gall-bladder is from the cystic artery, a branch of the hepatic. It courses along the cystic duct to the neck of the gall-bladder, where it divides into two branches which run on either side of the gall-bladder to the fundus.

The **nerves** of the gall-bladder come from the celiac plexus of the sympathetic.

The **cystic duct,** about ⅛ in. in diameter, extends from the neck of the gall-bladder obliquely downward about 1½ in., and joins the hepatic duct (see Fig. 223). Just at this point of junction is a lymphatic gland which, if enlarged, may be mistaken for calculus.

The **hepatic duct** is formed by two trunks which come from the transverse fissure of the liver, one each from the right and left lobes respectively, and uniting form the common hepatic duct. It passes downward for about 2 in. between the layers of the gastrohepatic omentum and is joined by the cystic

duct. The confluence of these two ducts forms the common duct (see Fig. 223).

The **common bile-duct** is formed by the junction of the cystic and hepatic ducts. It is about 3 in. long and ¼ in. in diameter. It descends between the layers of the gastrohepatic omentum to the right of the hepatic artery, the portal vein lying behind. It passes behind the first portion of the duodenum and in front of the head of the pancreas, and traverses the wall of the second portion of the duodenum, into which it empties.

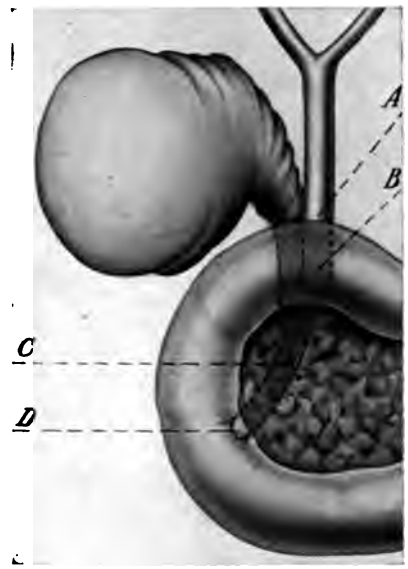

FIG. 225.—RELATIONS OF THE COMMON BILE-DUCTS.

A, Supraduodenal portion; *B*, retroduodenal portion; *C*, pancreatic portion; *D*, intraparietal portion.

The course of the common bile-duct may be divided into four parts, the names of which indicate their situations (Fig. 225).

(*a*) The *supraduodenal portion* is very short. It occupies the free border of the gastrohepatic omentum, and may be explored by introducing the finger in the foramen of Winslow. Robson calls attention to the three or four lymphatic glands which lie in contact with this portion of the duct, and which, when enlarged, may be mistaken for gall-stones.

(*b*) The *retroduodenal* portion lies behind the first portion of the duodenum, but not adherent to it, so that it may be uncovered and examined.

(*c*) The *pancreatic portion* includes the portion of the duct which extends from the inferior border of the first part of the duodenum to the point where the duct penetrates the wall of the second part of the duodenum. It is in intimate relation with the head of the pancreas, passing either between the pancreas and descending portion of the duodenum or through the head of the pancreas. This portion is in close relation with the inferior vena cava behind.

(*d*) The *intraparietal portion* is that portion of the duct which traverses the thickness of the duodenal wall. It passes obliquely through the muscular wall, and beneath the mucosa it is joined by the pancreatic duct, which together form a conical cavity, the *ampulla of Vater*. The apex of this cavity opens into the duodenum upon a papilla situated upon one of the mucous folds, and known as the *papilla of Vater*. Oddi contends that the ampulla of Vater is surrounded by muscular tissue which forms a veritable sphincter.

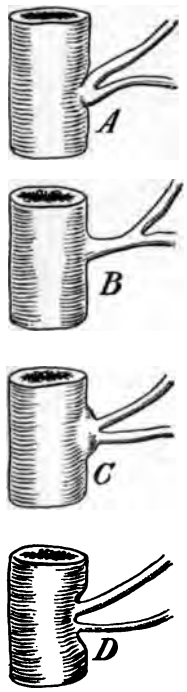

FIG. 226.—THE VARIATIONS IN THE FORMATION OF THE AMPULLA OF VATER.

Remember that this ampulla, into which the two ducts converge, is larger than any portion of the common duct. The orifice in the papilla, upon which it opens into the duodenum, is much smaller than any portion of the duct. A clear understanding of how the common duct and pancreatic duct join, the conical cavity into which they empty, and the relatively small size of the opening of this cavity into the duodenum is absolutely essential for a clear understanding of the various pathologic conditions which this anatomic arrangement invites.

Variations in the formation of the ampulla of Vater and the termination of the common and pancreatic ducts. Robson describes four types, as follows:

First type: the normal, described above (Fig. 226, *A*).

Second type: the pancreatic and common duct, joined a little distance before entering the duodenum; the ampulla of Vater is absent and the opening into the duodenum is by a flat orifice (Fig. 226, *B*).

Third type: the two ducts open into a small fossa in the wall of the duodenum. The papilla and ampulla of Vater are both absent (Fig. 226, *C*).

Fourth type: the papilla is present, but the ampulla of Vater is absent, and the two ducts open side by side at the apex of the papilla (Fig. 226, *D*).

Abnormal Position of the Gall-bladder.—The possible

displacements of the gall-bladder are interesting from a clinical standpoint. They are dependent upon—

(*a*) Changes in the form and size of the liver. In cirrhosis of the liver the gall-bladder is carried up under the ribs. In enlargement of the liver it is displaced downward—with "Riedel's lobe" it may reach as far as the cecum.

(*b*) Adhesions between the gall-bladder and intestines, causing the gall-bladder to be dragged out of position.

(*c*) Presence of a distinct mesentery, which may gradually lengthen when the gall-bladder is filled with stones, until a condition of ptosis of the bladder is established.

(*d*) Changes within the gall-bladder itself, chiefly that of distention. It is well to remember that the gall-bladder may vary in size from that of a cherry to the proportions of an abdominal tumor, extending as far as the symphysis pubis.

Note Vincent's case, cited by Moynihan, that of a girl eight and a half years of age presenting an abdominal tumor extending from the right hypochondriac to the left iliac region and to within three fingers'-breadth of the symphysis pubis. One hundred and sixty centimeters of bile was aspirated. Autopsy showed this to be a tremendously dilated gall-bladder.

The gall-bladder may be *congenitally absent*, or it may be *hour-glass shaped*—the latter condition, however, is more frequently due to the contraction of an old ulcer.

Clinical Considerations.—From a mechanical and functional standpoint the least important part of the gall-tract is the gall-bladder. It is the only part of the gall-tract that is not essential. Apparently the bodily functions are carried on as well when it is absent as present. Like the vermiform appendix, to which it has often been compared, its function is speculative and not apparent. The gall-bladder is a diverticulum of the bile-duct, as the vermiform appendix is a diverticulum of the cecum. Although functionally of no importance, surgically it is a center of great interest, and next to the appendix demands more attention than the remaining abdominal viscera.

To understand clearly the mechanics of the gall-tract keep three points well in mind.

(*a*) The *purpose of the gall-tract*—to convey the bile from the liver to the intestine.

(*b*) The *subsidiary position of the gall-bladder*. While it is a part of the gall-tract, *it is not a necessary part*, and the function of the bile-tract is in no wise compromised by its absence.

(*c*) The *relation of the pancreatic duct to the gall-tract.* Since the diseases of the gall-tract are the diseases of obstruction, the surgery of the gall-tract is largely concerned with the removal of obstructions to the free flow of bile, or the treatment of remote effects of obstruction. The principal cause of obstruction is the formation of gall-stones, to which the gall-tract is predisposed. A consideration of the mechanical effects of gall-stones in the different parts of the gall-tract rationally explains the symptomatology and suggests the logical treatment.

Stones in the gall-bladder may remain for years quiescent without producing any symptoms. In the author's dissections he found stones in the gall-bladder in about 75 per cent. of the subjects dying from other diseases. This is easily understood when it is recalled that the gall-bladder is merely a diverticulum of the gall-duct, and the stones lodged there in no way impede the free flow of bile into the intestine. Stones in the gall-bladder may, however, cause inflammation of the mucous coat which may extend to the peritoneal coat; hence, there are frequently seen adhesions between the gall-bladder and neighboring structures—the stomach, duodenum, colon, and anterior abdominal wall. Furthermore, gall-stones may ulcerate through the gall-bladder and be discharged into the intestinal tube; in fact, gall-stones have been found impacted in the intestine, causing acute intestinal obstruction.

Stone in the Cystic Duct.—Here, again, there is no impediment to the free flow of bile into the intestine; hence, there is no jaundice symptom. The natural secretion of the gall-bladder, however, is dammed back, and there is produced either a hydrops of the gall-bladder or, if infection occurs, an empyema of the gall-bladder. Obstruction in the cystic duct is the cause of the enormously distended gall-bladders which simulate other abdominal tumors, to which allusion has already been made.

Stone in the main bile-duct, either the hepatic or common duct, impedes the flow of bile and produces jaundice. A peculiarity of stone in the common duct is its tendency to produce intermittent jaundice. This has been explained by Fenger, as follows: A stone in the common duct has a ball-valve action because the common duct is an attenuated funnel in its caliber, being largest above and gradually tapering down to the ampulla, where it is smallest: hence, the stone acts like a ball valve; at one time it is completely obstructing

the duct and producing jaundice, at another, changed conditions dislodge it upward, and the bile flow is re-established and the jaundice cleared up.

Stone in the Ampulla.—Here is found another mechanical factor, for stone impacted here will not only dam back the bile, but also the pancreatic secretion; hence the influence of gall-stones in producing acute pancreatitis and pancreatic cysts.

Carcinoma of the Head of the Pancreas.—Recall the fact that the common duct runs between the head of the pancreas and the intestinal wall and sometimes through the head of the pancreas. A growth in the head of the pancreas would, therefore, produce—

(*a*) Obstruction in the common duct—hence jaundice.
(*b*) Obstruction in the pancreatic duct—hence pancreatitis.
(*c*) Pressure upon the portal vein—hence ascites.

Operations for the Relief of Obstruction in the Gall-tract.—Since the fundus of the gall-bladder is opposite the point where the external border of the right rectus muscle joins the costal arch, an incision along the external border of the right rectus downward will generally give a satisfactory exposure of the parts. Exploration of the bile-tract is much facilitated by placing a cushion under the patient's back and thereby throwing the parts nearer the surface.

The gall-bladder, if distended by stones or fluid, is easily found; on the other hand, it may be retracted beneath the liver and hidden by adhesions. The ducts are examined by tracing the cystic duct down from the neck of the gall-bladder or by inserting the index finger into the foramen of Winslow. The common duct lies anterior to the foramen and at the free border of the gastrohepatic omentum.

In palpating the common duct remember the three or four lymphatic glands which lie in front of the common duct. *When enlarged they simulate calculi.*

The removal of gall-stones from the gall-bladder or cystic duct is usually a simple procedure. In operating upon this part of the gall-tract the surgeon has great latitude, since the parts may be removed without essentially affecting the function of the bile-tract.

In removing a calculus from the common duct the procedure is more difficult, depending largely in what segment of the duct the stone is impacted. Before opening the duct an attempt should be made to "milk" the stone into the duodenum or crush it *in situ*. If the upper segment is to be opened,

the duct is drawn well forward with the gastrohepatic omentum and an incision made in its long axis over the site of the calculus (choledochotomy). If the calculus is lodged in the intraparietal segment or the ampulla it is best reached by opening the duodenum and cutting down upon the stone from within (duodenocholedochotomy). Should it be found impractical to remove a stone from the common duct, relief may be afforded by connecting the gall-bladder with the intestinal canal, preferably the duodenum (cholecystenterostomy) (Fig. 227). The sounding of the bile-ducts by passing a flexible

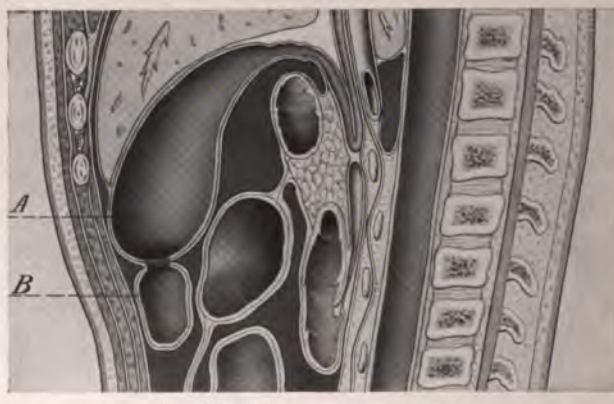

FIG. 227.—CHOLECYSTENTEROSTOMY.
(*A*) The fundus of the gall-bladder anastomosing with (*B*) the small intestine.

catheter through an opening in the gall-bladder is rarely possible through a normal cystic duct because of the valves of Heister and its tortuous course. When a cystic duct can be sounded it is the sign of a previous inflammatory process.

THE SPLEEN

The **spleen** is the largest of the so-called ductless glands. The products which it elaborates pass directly into the blood or lymph channels. Unlike other glands with an internal secretion its extirpation is not followed by any ill effects. In form it is like a flattened oblong, 5 in. long, 3 in. wide, and 1½ in. thick. Its average weight is 7 oz. It is subject to great physiologic and pathologic variations.

Situation.—It is deeply placed in the posterior portion of the left hypochondrium, between the fundus of the stomach and the diaphragm.

Surface Markings.—It occupies an area covering the ninth, tenth, and eleventh ribs, bounded by two vertical lines, which continue the anterior and posterior folds of the left axilla (Fig. 228).

Relations.—The spleen presents three surfaces—gastric, renal, and phrenic, related as their names indicate. The external or phrenic surface is smooth and convex and related to the under surface of the diaphragm; hence, between the spleen and the ribs is the diaphragm, the pleural cavity, and

FIG. 228.—SURFACE MARKINGS OF THE SPLEEN.

the lower margin of the left lung. Note the difficulty of outlining the limits of the spleen by percussion. The internal or gastric surface is concave and in relation with the fundus of the stomach. On this surface is a longitudinal depression, the *hilum of the spleen*, which marks the points of entrance of the splenic vessels.

The posterior or renal surface is long and narrow, and is in relation with the convex border of the left kidney. The anterior border of the spleen is thin and sharp and *notched*.

This is the border which emerges from beneath the ribs when the spleen is enlarged, and its characteristics are of great clinical importance in differential diagnosis.

Ligaments.—The spleen is surrounded by peritoneum except at the hilum, and is held in place by peritoneal folds which act as ligaments. It is attached to the diaphragm by the *phrenosplenic ligament.* The splenic flexure of the colon, held in place by the *phrenocolic ligament,* supports the spleen below like a sling.

The gastrosplenic omentum contributes no support to the spleen. It is simply a fold of peritoneum which connects the hilum of the spleen to the cul-de-sac of the stomach.

Wandering Spleen.—While the spleen is mobile within certain physiologic limits, due to the influence of respiration and digestion, it may become displaced because of increased weight when enlarged, and the consequent relaxation of its ligaments. A wandering spleen may be found in any region of the abdomen, even as far down as the pelvis. It has been found in the sac of an inguinal hernia (Testut). When a spleen is displaced it may be treated by reposition and fixation by mechanical support (elastic belt), or by operation and fixation with sutures (splenopexy), or it may be necessary to remove it (splenectomy).

Blood-vessels.—The **splenic artery** is the largest branch of the celiac axis. It runs from right to left along the superior border of the pancreas, and, after furnishing branches to the pancreas and stomach, it divides into six or eight branches, which enter the hilum and ramify throughout the spleen.

Characteristics.—(*a*) The large size of the vessel in proportion to the size of the organ; hence, the great vascularity of the latter.

(*b*) The branches of the splenic artery are terminal branches (they do not anastomose); hence obstruction by embolus is followed by a wedge-shaped area of necrosis (infarction).

The **splenic vein** is formed by several branches which exit from the hilum of the spleen. It runs in a straight course below the artery and unites with the superior mesenteric vein behind the head of the pancreas to form the portal vein.

The **nerves** are from the solar plexus and enter the spleen with the vessels.

Clinical Considerations.—The two characteristics of the spleen, its brittleness and its vascularity, suggest the seriousness of splenic injuries.

Wounds of the Spleen.—While the spleen, because of its protected position, is not so liable to injury as the liver, it may be ruptured by direct or indirect violence, lacerated by a fractured rib, or injured by a penetrating wound. When the spleen is enlarged liability to injury increases in proportion. Wounds of the spleen are serious, first, because of hemorrhage; secondly, because they are frequently complicated by wounds of the neighboring viscera. Wounds of the spleen demand prompt intervention. Small wounds may be sutured, larger wounds demand splenectomy. No other methods of controlling splenic hemorrhage are satisfactory.

Splenectomy is indicated in wounds, wandering spleen, simple hypertrophy, and in Banti's disease (splenic leukemia with cirrhosis of the liver). While this operation is a simple procedure in wandering spleen where the pedicle has become elongated, it is a difficult operation in a spleen normally situated. The best exposure is obtained by making an incision either along the outer border of the left rectus muscle or parallel with the left costal arch. The organ is isolated from its attachments and *the vascular pedicle ligated as close to the hilum as possible and with the least amount of traction*, because—

(*a*) Traction on the pedicle may tear the splenic vein.

(*b*) It may produce profound shock through the solar plexus reflex.

(*c*) Ligation close to the hilum is essential to avoid injury to the tail of the pancreas, which Herczel has shown to be the cause of fever following splenectomy. According to this author, injury to the pancreas sets free the fat-splitting ferments which produce fat necrosis and the consequent peculiar fever.

In splenic abscess and echinococcus cysts incision and drainage are indicated.

THE PANCREAS

The **pancreas** is the "abdominal salivary gland." It differs, however, from other salivary glands in that it not only possesses an *external secretion*, which plays an important part in digestion, but also an *internal secretion*, which is essential to normal metabolism. Experimentation has shown that total extirpation of the pancreas is followed by diabetes and rapid emaciation; if, on the other hand, any portion of the gland is left, diabetes does not occur. Symptoms of diabetes with rapid emaciation

is indicative of a grave lesion of the pancreas, and is an absolute contra-indication to operative interference (Testut).

The pancreas is an elongated glandular organ lying behind the stomach and extending across the posterior abdominal wall at the level of the second lumbar vertebra. The line of the pancreas corresponds to a point about 3 in. above the umbilicus. It is about 6 in. long, 1½ in. wide, and 1 in. thick. For purposes of description it is divided into head, neck, body, and tail (Fig. 229).

The **head** is the expanded right extremity which lies in the concavity of the duodenum. It bends downward and lies below the general level of the gland. At its point of contact

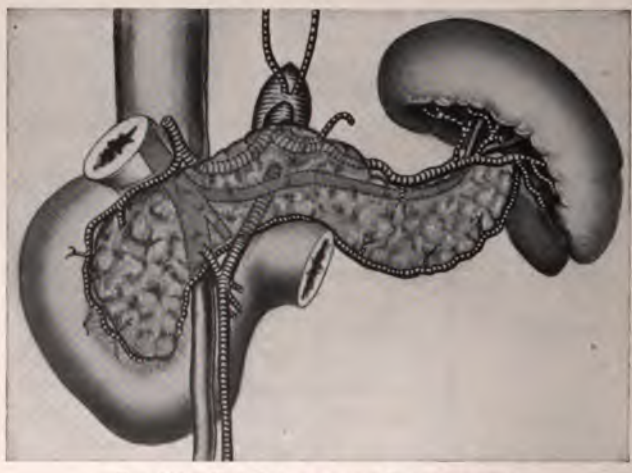

FIG. 229.—THE PANCREAS AND BLOOD-VESSELS.

with the duodenum the head is embraced by a vascular loop formed by the superior and inferior pancreaticoduodenal vessels. It is worth noting that the head may form a complete ring around the descending portion of the duodenum, which may constrict the gut and produce dilatation of the stomach by obstructing the passage of the food. Note also that tumors of this portion of the gland (especially carcinoma) may produce symptoms of intestinal obstruction (Testut). Behind, the head of the pancreas is related to the inferior vena cava, the left renal vein, and the aorta. Compression of these vessels frequently follows tumors of the head of the pancreas, and we note edema of the lower extremities from

compression of the inferior vena cava, or ascites from compression of the portal vein. The left and anterior border presents a notch, the **incisura pancreatis,** in which lie the superior mesenteric vessels.

The common bile-duct passes between the duodenum and the head of the pancreas, or through the substance of the gland itself; hence, in cancer of the head of the pancreas or in chronic pancreatitis the duct is compressed and symptoms of biliary retention and obstructive jaundice ensue.

The **neck** is the narrow portion of the gland lying between the notch formed by the first portion of the duodenum above and the notch made by the superior mesenteric vessels below. On its posterior surface is a sulcus in which lies the portal vein.

The **body** in passing transversely across the posterior abdominal wall at the level of the second lumbar vertebra is separated by the aorta, the pillars of the diaphragm, the splenic vein, the left kidney and its vessels, and the suprarenal capsule. Its anterior surface is covered by the peritoneum of the lesser sac and partly by the stomach.

The **tail,** or left extremity of the pancreas, is in contact with the internal surface of the spleen.

Its inferior surface rests upon the duodenojejunal flexure and its left extremity upon the splenic flexure of the colon. The upper border of the pancreas is in relation with the celiac axis, which gives off the hepatic and splenic arteries, running along its upper border to the right and left, respectively. In general, the pancreas presents two surfaces:

(*a*) A posterior or lumbar surface, which is extraperitoneal and inaccessible, and

(*b*) An anterior or abdominal surface, which is intraperitoneal, and may be reached through an abdominal incision.

The Ducts.—The principal pancreatic duct is the **canal of Wirsung,** which courses through the pancreas from tail to head, and unites with the common bile-duct to form the ampulla of Vater, which opens on the internal surface of the second portion of the duodenum (see variations in the ampulla of Vater, p. 428). The **duct of Santorini** is a smaller and accessory duct, which is given off from the main duct at the neck of the gland and empties into the duodenum about 1 in. above the orifice of the ampulla of Vater. As a rule, the accessory duct is able to take the place of the main duct in case the latter is obstructed. It is subject, however, to great variations from the normal type.

Blood-vessels.—The pancreas has an abundant blood supply, which is derived from three large trunks—the splenic, the hepatic, and the superior mesenteric. These arteries and their branches form a complete anastomotic circle about the gland (see Fig. 229).

The **veins** of the pancreas accompany the arteries and go to form the radicles of the portal system.

The **lymphatics** of the pancreas terminate in glands scattered along the splenic vessels, the commencement of the superior mesenteric vessels, and the vascular arch formed by the pancreaticoduodenal arteries about the head of the pancreas.

The *nerves* come from the solar plexus.

Accessory Pancreas.—Small isolated masses of pancreatic tissue are found chiefly in four positions—in the wall of the stomach, the duodenum, the jejunum, and the ileum (Robson).

Surgical Considerations.—The pancreas is so deeply placed that it is impossible to palpate it except in very thin subjects, where the abdominal wall may be depressed sufficiently to reach the vertebral column. Recall the fact that the level of the pancreas is opposite a point 3 in. above the umbilicus.

The difficulties and dangers which beset the operator in the surgery of this gland are readily appreciated when we recall its deep situation, its intimate relation to important vascular structures—the aorta, the inferior vena cava, the portal vein, and the vessels which supply it directly—the common bile-duct between the head of the pancreas and the duodenum or included in the head of the pancreas, and its own main duct, terminating at the same point.

Modes of Access.—The abdomen having been opened in the median line above the umbilicus, the gland may be approached by three routes:

(*a*) Above the lesser curvature of the stomach, by making an opening through the gastrohepatic omentum. The lesser peritoneal sac is opened and the gland found behind the peritoneum which covers its anterior surface.

(*b*) The transverse colon and its mesentery are turned upward and the small intestine depressed. An opening is made through the transverse mesocolon.

(*c*) Through an incision in the great omentum a few inches below the greater curvature of the stomach. The stomach is retracted upward and the transverse colon downward, and

the entire gland exposed lying behind its peritoneal covering. *This is by far the most satisfactory exposure that can be obtained.*

Injuries of the pancreas are rare because of its deep position and the protection which it receives from the neighboring viscera. In fact, a wound of the pancreas is scarcely possible without involving other adjoining viscera.

Tumors of the Pancreas.—Carcinoma, sarcoma, adenoma, gumma, and tuberculosis may affect this gland, but carcinoma is by far the most frequent neoplasm found in the pancreas. It attacks the head of the gland six times more frequently than the tail (Sutton). The secondary effects of carcinoma of the head are obvious in its pressure on surrounding parts, notably the common bile-duct, causing obstruction of the bile current and consequent jaundice; the portal vein, causing ascites; the duodenum, causing obstruction and dilatation of the stomach. When the growth involves a considerable part of the gland diabetes may develop.

Pancreatic cysts are usually due to an obstruction of the main duct, either by a calculus in the ampulla of Vater, cicatricial stenosis, or pressure upon the duct from without. They vary in size from a pea to one which may reach into the pelvis. When small they give no symptoms, and may be recognized accidentally during operation for other causes. As it increases in size, it presents between the greater curvature of the stomach and the transverse colon. The extirpation of these cysts is neither necessary nor possible. They are best treated by incision and drainage, the margins of the cysts being sutured to the abdominal wall.

Pancreatitis.—Inflammation of the pancreas is usually the result of infection from one of two sources—from the intestine into which its main duct empties, or from the biliary passages with which its main duct joins.

Movable Pancreas.—While the pancreas is normally a fixed organ, it may be partly displaced under the influence of a wandering spleen. It has been found in the contents of a diaphragmatic hernia and an umbilical hernia.

THE KIDNEYS

The **kidneys** are placed symmetrically on either side of the last dorsal and first three lumbar vertebræ, against the posterior abdominal wall and behind the peritoneum. Note that they lie not only retroperitoneally, but are entirely indepen-

dent of the peritoneum, which merely passes in front of them without being adherent. Their convex border is directed outward. The inner border is concave and at the middle presents a notch, the *hilum*, through which pass the vessels, nerves, and excretory duct, and together form the *pedicle of the kidney*.

In the normal state each kidney measures 4 in. in length, 2½ in. in breadth, and 1½ in. in thickness. The left kidney

FIG. 230.—THE POSITION OF THE KIDNEYS.
Note the obliquity of their long axes and (*XX*) relation of the pleura to the twelfth rib.

is a little larger than the right. The kidneys are so placed that their long axis is directed obliquely from above down and from within out (Fig. 230); *i. e.*, their upper extremities are separated by a distance of 2½ in., their lower extremities by a distance of 4 in. The hilum of the left kidney is 2 in. from

the aorta and the hilum of the right kidney about $1\frac{3}{4}$ in. from the vena cava (Morris).

Surface Anatomy.—In front, the lower pole of the kidney corresponds to a horizontal line drawn through the umbilicus. A vertical line, extended upward from the middle of Poupart's ligament to the costal arch, has one-third of the kidney to its outer side and two-thirds to its inner side (Fig. 231). Behind, Morris indicates the position of the kidney by four lines arranged

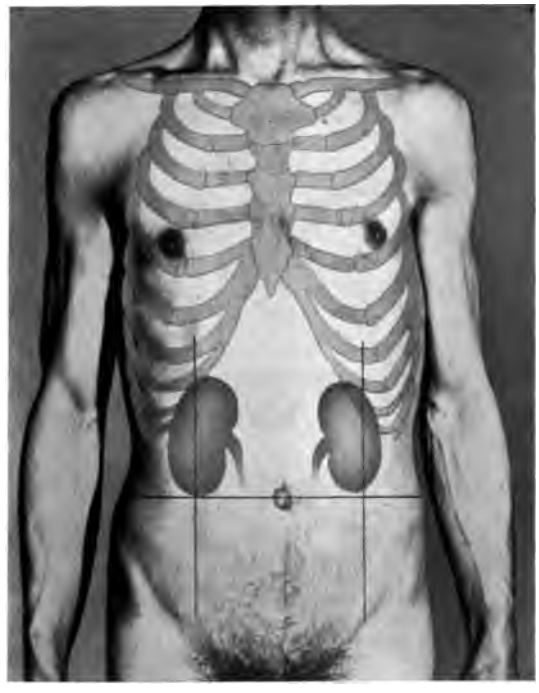

FIG. 231.—RELATION OF KIDNEY TO ANTERIOR SURFACE OF ABDOMEN.

in the form of a rectangle—the two horizontal lines are on a level with the spinous process of the eleventh dorsal and third lumbar vertebræ; the vertical are 1 and 3 in., respectively, from the vertebral spines and parallel. The hilum of the kidney corresponds to the level of the first lumbar spine (Fig. 232). The lower poles of the kidneys are separated from the iliac crests by a distance of $1\frac{1}{2}$ to 2 in., the right kidney being on a slightly lower level than the left because of the situation of the liver on the right side.

The *relation of the twelfth rib* to the kidney is a landmark of great practical importance because—

(*a*) It crosses obliquely behind the kidney at the junction of its upper and middle thirds (Fig. 232).

(*b*) The lower limit of the pleura normally corresponds to the inner half of the twelfth rib. The outer half is extrapleural (see Fig. 230).

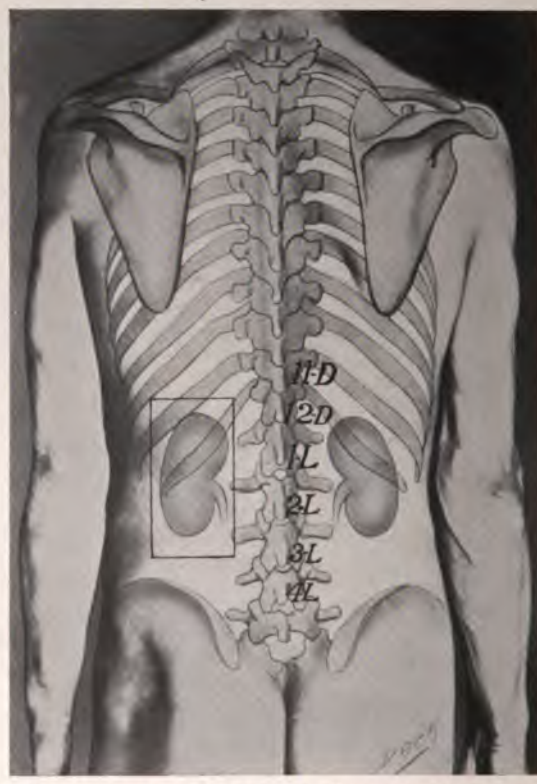

FIG. 232.—RELATION OF THE KIDNEY TO THE POSTERIOR SURFACE OF ABDOMEN.

(*c*) The twelfth rib is sometimes rudimentary, but *this does not affect the lower limit of the pleura.*

Therefore, (*a*) always count the ribs before making the incision for lumbar nephrectomy, to be sure of a normal twelfth rib.

(*b*) Keep away from the vertebral half of the twelfth rib.

Investments and Means of Fixation.—The kidney is

invested by three capsules: (*a*) The *fibrous capsule proper*, which is thin and smooth and connected to the gland by loose connective tissue. It can be easily stripped from the underlying tissue.

(*b*) The *fatty capsule* is an envelop of cellulo-adipose tissue which appears about the tenth year and varies in quantity according to the condition of the individual. It is thicker behind and along the borders than in front. It reaches its maximum thickness below the inferior end of the kidney, where it forms a veritable fatty cushion upon which the kidney rests.

(*c*) The *perirenal fascia* (*Gerota's capsule*) is an extension of the subperitoneal fascia, which in the region of the kidneys thickens and splits into two layers, enclosing the kidneys with

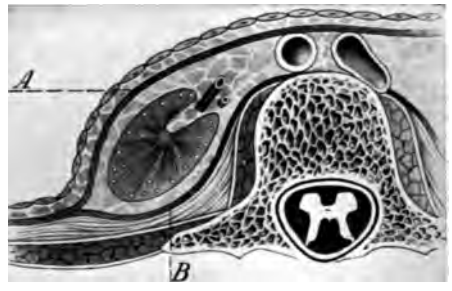

FIG. 233.—THE PERIRENAL FASCIA.
Horizontal section showing (*A*) anterior and (*B*) posterior layers.

its fatty capsule, the suprarenal capsules, the renal vessels, and the commencement of the ureters (Fig. 233).

The anterior layer passes in front of the kidney and fuses with the same layer of the opposite side; above, it joins the posterior layer and is attached to the diaphragm.

The posterior layer passes behind the kidney, lining the quadratus lumborum and psoas muscles, and is attached to the front of the spine. The two layers join at the external border of the kidney.

Thus, the *perirenal fascia forms an incomplete investment* of the kidney and its fatty capsule; for observe that, while it is closed above and along the outer border, it is open below and along the inner border (Fig. 234). Internally, it communicates with the renal fossa of the opposite side, but the great vessels in front of the vertebral column form a formidable barrier between the two fossæ.

Below it communicates with the subperitoneal tissue of the iliac fossa, and there is nothing to prevent the kidney from gravitating downward when its means of fixation are relaxed. In addition to its fatty and fibrous investments the kidney is held in position by its vascular pedicle and by intra-abdominal pressure.

Fig. 234.—*A*, *A*, The Perirenal Fascia (Sagittal Section).

Movable Kidney.—In order to avoid confusion of terms movable kidney is here used in its anatomic definition, viz.: one which moves abnormally free behind the peritoneum, in contradistinction to "*floating*" *kidney*, which is completely invested with peritoneum and thus possesses a *mesonephron* which allows it to hang in the peritoneal cavity like the small intestine. The former condition is acquired, the latter congenital.

The mechanics of movable kidney are not difficult to understand when its position and natural means of support are considered. First, the kidney is movable within certain physiologic limits. It ascends and descends with respiration, and its natural range of motion varies with the sex and individual peculiarities. Second, it has no special ligaments which retain it in place; it depends for support upon its fatty cushion, its vascular pedicle, and intra-abdominal pressure. If rapid emaciation occurs, it loses the support of its fatty cushion and displacement is facilitated. If the abdominal wall becomes relaxed by multiple pregnancies or other causes intra-abdominal pressure is diminished and conditions established which favor displacement.

The right kidney is more frequently affected than the left, due to its intimate relation to the liver and the greater length of the right vascular pedicle. Movable kidney occurs more frequently in the female, because the renal fossæ are narrower above and wider below than they are in men, and because of the relaxation of the abdominal walls following repeated pregnancies and the mechanical effects of the corset. Beside

the displacement of the kidney itself the remote effects of movable kidney must not be forgotten, such as kinking of the ureter, causing renal retention and hydronephrosis; tortion of the renal vessels, causing renal engorgement; traction on the duodenum, causing gastric dilatation or obstruction of the bile-ducts and transient attacks of jaundice. The majority of cases of movable kidney give no symptoms, and may be maintained in place by an appropriate bandage. This method failing, and symptoms demanding it, *nephropexy* may be performed, in which the kidney is replaced and anchored by sutures through a lumbar incision.

Relations of the Kidneys.—*Posteriorly*, the relations are the same on the two sides and consist of a thoracic and lumbar

FIG. 235.—PERITONEAL RELATIONS OF THE KIDNEYS.
A, Hepatic area (peritoneal); *B*, colic area (nonperitoneal); *C*, mesocolic area; *D*, duodenal area (nonperitoneal); *E*, gastric area (peritoneal); *F*, pancreatic area (nonperitoneal); *G*, mesocolic area; *H*, colic area (nonperitoneal).

portion. The upper or thoracic portion rests against the diaphragm, which separates it from the pleura as it dips down to form the phrenicocostal sinus; the lower or lumbar portion rests upon the fascia covering the psoas and quadratus lumborum muscles. The twelfth dorsal, the iliohypogastric, and the ilio-inguinal nerves pass obliquely outward behind the lower half of each kidney.

Anteriorly, the kidneys have important relations with certain organs within the abdominal cavity, and it should be noted that while the kidneys lie behind the posterior parietal peritoneum, yet certain of these organs intervene between the kidney and the peritoneum (Fig. 235). The relations to these organs vary upon the two sides.

The **right kidney** is related from above downward with the

liver, the colon, and the peritoneum. Along its inner margin it is overlapped by the second portion of the duodenum which crosses at a right angle the hilum, the renal vessels, and ureter. Note that the colic and duodenal areas are nonperitoneal.

In front of the **left kidney** are the stomach, the splenic vessels and pancreas, and the colon. Along the upper half of the outer border it is overlapped by the spleen. Note that the pancreatic and colic areas are nonperitoneal.

Structures at the Hilum of the Kidney.—The internal concave border of the kidney rests almost directly upon the transverse processes of the first and second lumbar vertebræ, which in case of contusion in this region are important factors in producing rupture of the kidney.

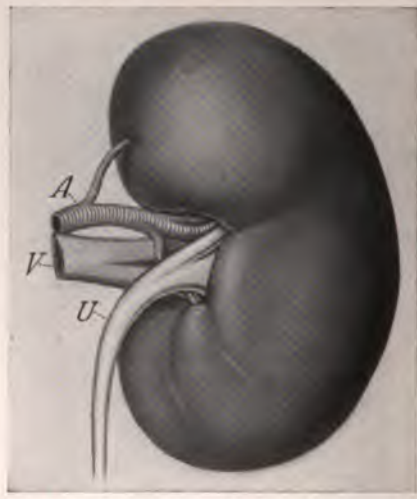

FIG. 236.—RELATION OF THE STRUCTURES AT THE HILUM.
A, Artery; *V*, vein; *U*, ureter.

At the middle of the internal border is the *hilum*, separated from the aorta on the left and the inferior vena cava on the right by a distance of 3 cm. *This important relation should be remembered in performing nephrectomy*, especially when adhesions are present. Through the hilum enter or emerge the various structures which form the pedicle of the kidney, as follows: the vein in front, the artery in the middle, and the ureter behind (Fig. 236). It is obvious that a wound in the region of the hilum is most grave. Note also that the pelvis of the ureter is most accessible from behind.

The Vessels and Nerves.—The **renal arteries** are large in proportion to the organs which they supply. They arise from the abdominal aorta a little below the superior mesenteric artery. The right is a little longer than the left, and crosses behind the inferior vena cava. Before reaching the hilum of the kidney the arteries divide into three or four branches, which occupy the middle portion of the pedicle and are distributed to the kidney substance. One of the branches at the hilum passes posterior to the pelvis of the kidney, and should be avoided in opening the pelvis for the enucleation of calculi. It is well to remember that the branches of the renal artery, like those in the brain and spleen, are terminal arteries; that is, they do not anastomose, so that an obstruction of one of the branches is followed by a wedge-shaped area of necrosis (infarction).

The renal arteries are subject to great variation in number and point of entrance. Most important of these is an *accessory renal artery*, given off from the abdominal aorta and passing to the inferior pole of the kidney. The presence of such a branch might be the source of great danger in nephrectomy, and Testut cites a case where an accessory artery passing in front of the ureter exerted sufficient pressure to produce hydronephrosis.

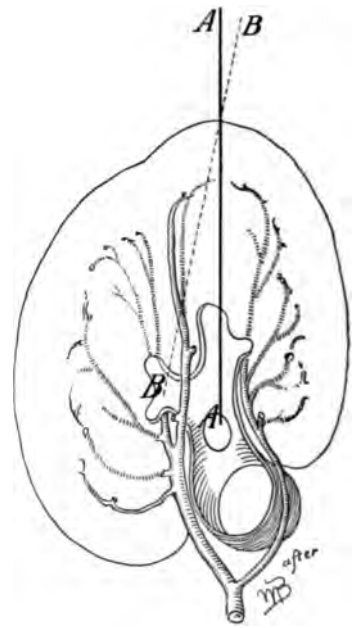

FIG. 237.—THE RENAL ARTERY AND THE DISTRIBUTION OF ITS BRANCHES.
A, *A*, Correct incision; *B*, *B*, incorrect incision.

A most important fact regarding the renal circulation was first suggested by Hyrtle, who pointed out that the pelvis of the kidney separates two arterial systems, the renal artery giving off a branch which supplies the dorsal portion of the kidney, and a branch which supplies the ventral portion, and that between these two vascular systems is a nonvascular zone. Brödel has further developed this suggestion and shown that the kidney is not only vascularized by two arterial

systems separated by the renal pelvis, but that there is a major system which supplies three-fourths of the blood to the anterior and a part of the posterior half of the kidney, and a minor system which supplies one-fourth of the blood to the remaining posterior portion (Fig. 237). These two systems do not anastomose with each other, and between them is a non-vascular zone, along which an incision may be made through the substance of the kidney and into the pelvis with a minimum amount of hemorrhage.

"Brödel's white line" is a longitudinal white line found on the anterior surface near the convex border; it is formed by the fusion of the whitish lines representing the columns of Bertini (Fig. 238, *AA*). *Remember that while the line is superficially white, below it is the most vascular region of the kidney.*

FIG. 238.—*A*, *A*, "BRÖDEL'S WHITE LINE"; *B*, *B*, LINE OF BEST INCISION FOR SPLITTING THE KIDNEY.

Correct Incision for Splitting the Kidney.—A longitudinal incision parallel to "Brödel's white line," about 1 cm. toward the posterior surface (Fig. 238, *BB*). The incision should be directed parallel to the posterior surface and not inclined toward the center of the kidney (see Fig. 237); thus there is left three-fifths of the kidney anterior and two-fifths posterior to the incision.

The **renal veins** follow the general course of the arteries. The branches unite and leave the hilum as a single trunk, which is *situated in front of the artery.* They take a horizontal course, the left longer than the right, which passes in front of the aorta, and empty into the inferior vena cava. The left renal vein is joined by the left spermatic vein, and both veins receive tributaries from the fatty capsule, the suprarenal capsule, and the parietal veins of the lumbar region. Note

in this latter fact the *reason for cupping or counterirritation in the loins for the relief of congestion of the kidney.*

The **nerves** are derived from the solar and aortic plexuses and the lesser splanchnic nerves which form the *renal plexus.* There is a communication between the renal and spermatic plexuses.

This nerve supply explains the many reflex symptoms connected with kidney lesions—pain in the testicle, nausea and vomiting, and vesical tenesmus. Pain may also radiate along the upper lumbar nerves, and caries of the upper lumbar vertebræ be mistaken for renal calculus (Woolsey).

The Lymphatics.—The superficial lymphatics lie beneath the capsule and are connected with the deep lymphatics which enter the kidney substance and with the lymphatics of the fatty capsule. The terminal lymphatic glands lie along the vena cava and the abdominal aorta. Hence, *in cancer of the kidney it is necessary to remove the fatty capsule as well as the gland itself.*

Abnormalities.—There are certain congenital variations in the position and number of the kidneys which are of great

FIG. 239.—HORSESHOE KIDNEY.

practical importance to the surgeon. The kidney is not always situated in its normal position, for it must be remembered that in early fetal life the kidney occupies the pelvis and subsequently migrates to its permanent position. Thus in defective migration it may occupy any position from the pelvis to the renal fossæ. Congenital displacements may be distinguished from acquired displacements by the pedicle. In the former the pedicle is short and is connected with the large trunks at

the level of the displacement; in the latter the pedicle is found elongated (Taylor).

Horseshoe kidney is a condition in which the lower poles have become fused, a connective strip of kidney tissue extending across the median line (Fig. 239). The two kidneys may also be fused into one renal mass with two ureters. Morris observes that fusion of the two kidneys is always accompanied by displacement, and the mass is usually situated at a lower level and nearer the median line.

There may be congenital absence of a kidney or atrophy of a kidney. The remaining kidney is then much larger than normal, so as to meet the functional needs. A supernumerary kidney has been observed, sometimes fused with the normal kidney, and at other times independent.

The **fetal kidney** is distinctly lobulated, a condition which may be retained in adult life.

It will be observed that the above variations and abnormalities have a distinct significance in the diagnosis of abdominal tumors, since misplaced kidneys are often malformed kidneys, and a supposed abdominal tumor might easily pass unsuspected of its renal function. Again, when nephrectomy is contemplated, the absence of a kidney or a fusion of the kidneys is a matter of grave concern.

Clinical Considerations.—Two routes are available for the exposure of the kidney—through a lumbar or an abdominal incision. The former is always preferable, because the operation is extraperitoneal and satisfactory drainage is insured. Indeed, as the technique of the lumbar route has been perfected, it is with few exceptions the only justifiable procedure.

The Lumbar Route.—The most advantageous incision is an oblique one, starting at the outer edge of the erector spinæ muscle, about a finger's breadth below the twelfth rib, and continued obliquely downward toward the anterior superior iliac spine. The length of the incision depends on the stoutness of the individual and the condition for which the operation is to be performed. If further room is needed above, the lower rib or ribs may be excised by stripping off the periosteum and pushing the soft parts aside so that the pleura may not be wounded. When room is required below, the incision may be carried forward parallel and 1 in. above Poupart's ligament. Access to the ureter may be had by stripping up the peritoneum without opening the peritoneal cavity.

The Abdominal Route.—The incision is made along the outer edge of the rectus muscle and the peritoneum incised behind and to the outer side of the colon so as to avoid gangrene of the bowel.

The kidney may be exposed for exploration or drainage (*nephrotomy*). It may be split for the removal of stones (*nephrolithotomy*). When movable it may be anchored in position by sutures (*nephropexy*), or it may be removed (*nephrectomy*). In dealing with the pedicle it is well to remember that the vessels are directed inward toward the aorta and vena cava, while the ureter is directed downward toward the bladder; hence, the vessels and ureter should be ligated separately, when possible, to insure the safest stump. When the kidney is bound down by adhesions the result of perinephritic inflammation there may be great danger in attempting to separate it from the adjoining peritoneum and great vessels. A subcapsular nephrectomy is then the safest procedure, and is performed by separating the kidney from its fibrous capsule as far as the hilum, where the pedicle can be secured.

In performing nephrectomy the irregularity in the distribution of the renal vessels (see p. 447) should be kept in mind.

Rupture of the kidney is not so serious an injury as a like lesion in the liver or spleen. Because of its extraperitoneal position extravasation of blood and urine do not infect the peritoneal cavity.

Perinephritic abscess is a collection of pus in the fatty capsule surrounding the kidney. It may be due to disease of the kidney itself, or to the extension of inflammation from neighboring parts. When the relations of the renal fossæ are recalled the progress of such an abscess is readily understood. It may burrow upward and make its way through the diaphragm into the pleural cavity; it may point externally in the loin, usually at the triangle of Petit; it may burrow downward into the iliac fossa and open into the colon or bladder. Rarely does it perforate the peritoneum. Likewise a perinephritic abscess may be propagated from an appendicitis, or an empyema making its way through the diaphragm.

Renal tumors in general are distinguished by their position, they do not move with respiration, and by the zone of resonance in front caused by the overlying colon. Sarcoma is by far the most common form of malignant tumor which attacks the kidney, and is most frequently seen in children. In tubercular and hydatid cysts the kidney may attain an extremely large size.

The **ureters** are the excretory ducts which extend from the kidneys to the base of the bladder. They are about 14 in. long, the average width of a goose-quill, and lie entirely behind the peritoneum.

The ureter arises at the level of the hilum of the kidney by a swelling known as the renal pelvis, which lies behind

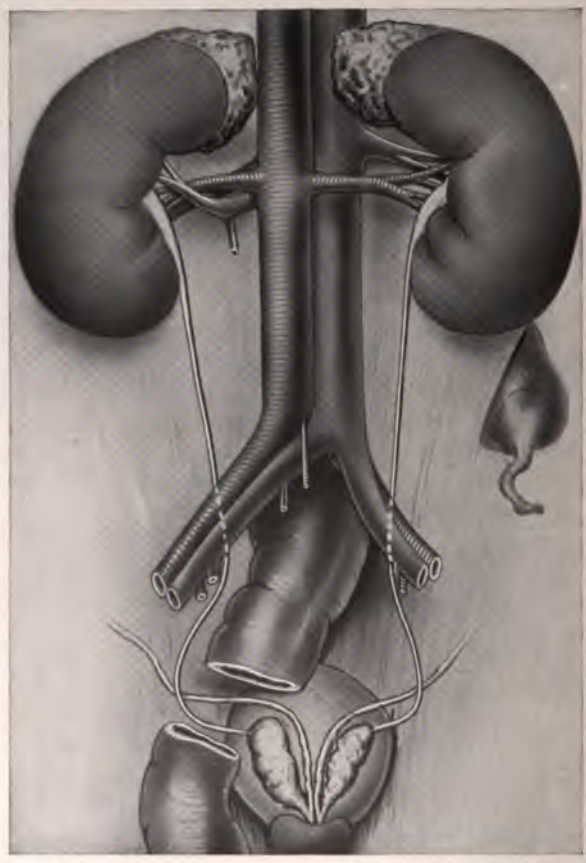

FIG. 240.—COURSE AND RELATIONS OF THE URETERS, SEEN FROM BEHIND.

the vessels, and is directed obliquely downward and inward, lying upon the psoas muscle, to the pelvic brim, where it crosses the common iliac artery at the level of its bifurcation. It then dips into the pelvic cavity, following its curvature, and terminates in the base of the bladder, after having passed

for nearly 1 in. obliquely between its muscular and mucous coats (Fig. 240).

The *diameter* of the ureter is not uniform; it presents three points of constriction and two intermediate fusiform dilatations (Fig. 241). The first constriction is situated a little below its origin and is about 3.2 mm., the narrowest part of the ureter. The second constriction is at the brim of the pelvis where the diameter is 4 mm., and the third constriction is at its termination in the bladder.

The abdominal dilatation has a diameter of 8 mm., the pelvic dilatation about the same, but somewhat irregular. Note the effect of these constricted points upon a calculus passing down the ureter. *They are the points at which the calculus is most liable to become impacted; they are the points at which a stricture from cicatrization of an ulcer is generally located.*

The walls of the ureter are composed chiefly of muscular and fibrous tissue and are thin like those of a vein, with which it may be confounded, but they possess great elasticity, so that they are capable of dilating to such an extent that they may form abdominal tumors which may be felt and seen. Again, its elasticity permits a certain portion of it to be excised and the ends anastomosed.



FIG. 241.—SCHEMATIC REPRESENTATION OF THE URETER, SHOWING POINTS OF CONSTRICTION AND INTERMEDIATE DILATATIONS.

A, Constriction at pelvis of kidney; *B*, iliac constriction; *C*, vesical constriction.

The ureter is loosely imbedded in the subperitoneal connective tissue, so that it is not only flexible, but mobile. When, therefore, a kidney is displaced there may be a sudden kinking of the duct which arrests the passage of urine and gives rise to a *hydronephrosis*. When the bend in the ureter subsides the hydronephrosis disappears, to reappear when like conditions are repeated; such is the mechanism of *intermittent hydronephrosis*.

Course and Relations.—At the hilum the pelvis of the

ureter lies behind the renal vessels, although branches of the vein and artery may sometimes be found overlying its deep aspect. Just below the renal pelvis the ureters are about 4 in. apart. They descend behind the peritoneum, lying upon the psoas muscle, which separates them from the transverse processes of the vertebræ, the proximity of which may contribute to their laceration in certain abdominal contusions.

Internally, the right ureter is closely related to the inferior vena cava; the left to the aorta and the inferior mesenteric vessels.

Externally, it courses along the side of the ascending colon on the right, the descending colon on the left.

In front, the ureter is covered by peritoneum, to which it adheres, except at its upper portion on the right side, where the third part of the duodenum intervenes.

In the lower portion on both sides it is separated from the peritoneum by the spermatic vessels in the male, the ovarian vessels in the female, and crossed by branches of the mesenteric arteries distributed to the ascending and descending colon. The peritoneum separates the ureter from the coils of small intestine, and if the appendix has an inward or upward direction it may lie across the right ureter. From the above relations it will be observed that, while the posterior surface of the ureter has no important vascular relations, its anterior surface is in contact with numerous vessels which interdict the use of the abdominal route for ureteral intervention. At the pelvic brim the distance between the ureters is about 3 in. They cross the iliac vessels, either the common or the external iliac artery and vein, lying behind the termination of the ileum on the right side, and the intersigmoid fossa of the sigmoid flexure on the left. Note the importance of these relations in ligating the iliac arteries. It is well to remember that at this point the ureters approach nearest to the anterior abdominal wall, and hence may be here the more readily palpated.

Halle's point is the landmark on the surface of the abdomen which corresponds to the point where the ureter crosses the pelvic brim. It is located by the intersection of two lines, one horizontal, connecting the two anterior superior iliac spines, the other a vertical line, projected upward from the pubic spine.

In the pelvis the ureter may be divided into a descending and a transverse portion. It has, however, important relations which differ in the two sexes, and hence must be considered separately.

In the male the descending or parietal portion, after crossing the brim of the pelvis, descends along the lateral wall of the pelvis and the inner side of the internal iliac vessels to a point about 1 to 1½ in. in front of the spine of the ischium (Morris). At this point it bends inward and takes a transverse direction.

The *transverse* or *visceral portion* lies between the posterior surface of the bladder and the anterolateral surface of the rectum. It crosses behind the vas deferens and enters the bladder wall in front of the upper end of the corresponding seminal vesicle. At this point the ureters are situated about 2 in. apart. Note the fact that the ureter passes through the bladder wall in an oblique direction for nearly 1 in., so that the mucous fold within the bladder acts as a valve, closing the ureteral orifice and preventing a back-flow during intravesical pressure. Again, the vesical orifice of the ureter is surrounded by a sphincter. These two facts play an important rôle in protecting the kidney against ascending infection from the bladder.

In the female the pelvic ureter differs from the male in its transverse or visceral portion. It traverses the base of the broad ligament in company with the uterine vessels. At this point *it is ¾ in. from the base of the cervix. The ureter crosses behind the uterine artery* and descends obliquely along the lateral fornix of the vagina to the vesicovaginal space, where it enters the base of the bladder at a point about 1 in. below the level of the external os.

Abnormalities of the ureter are quite frequent, and consist of a double renal pelvis uniting to form a single ureter; a double ureter usually only on one side; and abnormal terminations of the ureter. Sometimes the ureter may empty into some part of the urethra, the seminal passages, the vagina, or even the rectum (Morris).

Clinical Considerations.—It is obvious that the ureter plays an important rôle in surgical pathology because of the obstructions which may occur from within (calculus), or by pressure from without, especially in pelvic tumors. In abdominal and pelvic operations wounds of the ureter should be carefully guarded against, more especially in operations on the lower part of the uterus. When the ureter is wounded during the course of an operation immediate suture of the divided ends is indicated, or the implantation of its upper end into the bladder or intestine.

The observation of Barker that ligature of the ureter sometimes produces a marked effect upon the pulse is worthy of note.

The **suprarenal glands** (**adrenals**) belong to the class of ductless glands. Although the function of these glands is not definitely known, it is evident that their destruction, either by disease or experimentally, is not compatible with life. Furthermore, an extract has been made from the suprarenal gland, *adrenalin*, which has a marked vasoconstrictive action, and is commonly used as a hemostatic. From this

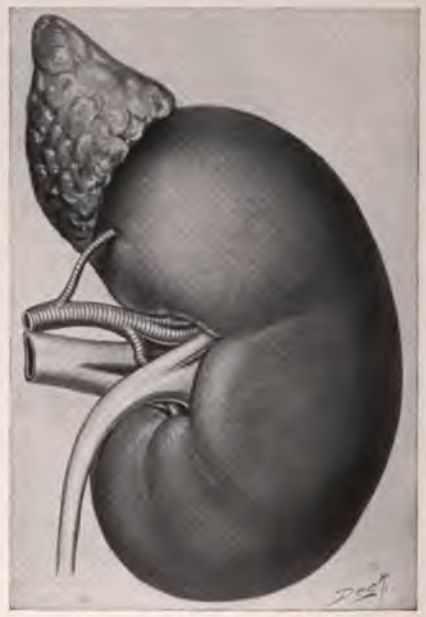

FIG. 242.—RELATION OF THE SUPRARENAL GLAND TO THE KIDNEY.

fact it has been thought that the secretion of the suprarenal plays an important part in the regulation of the blood-pressure. The suprarenals are much larger in the child than in the adult and atrophy with age. These glands do not occupy the upper pole of the kidney, as is generally stated. They are situated at the internal border of the kidney, above the vascular pedicle (Fig. 242). They resemble in shape a quadrangular pyramid with the base below and concave, to conform to the convexity of the kidney, with which they are connected by loose subperitoneal fascia. They average about 1½ in. in length and

2 in. in breadth at their base. They are loosely attached to the kidney, but are firmly attached to the neighboring organs by distinct ligaments—one goes from the anterior surface of the gland to the inferior vena cava, another from the inferior surface to the liver, and a third, the most resistant, from its superior angle to the diaphragm. Thus it will be observed that while the suprarenals are held firmly in position they are comparatively independent of the kidney, so that changes in position of the kidney do not affect the suprarenal, and extirpation of the kidney leaves this gland undisturbed. On the other hand, while extirpation of the suprarenal gland is a surgical possibility the diagnosis of its affections cannot be made until surgical intervention is futile.

Vessels and Nerves.—The suprarenals possess a specially rich vascular and nerve supply out of all proportion to their size. They are each supplied by no less than three arteries, branches from the aorta, inferior phrenic, and the renal.

The veins unite to form one large central vein, which empties into the renal vein on the left and the inferior vena cava on the right.

The **nerves** are especially numerous and are derived from the solar and renal plexuses.

Addison's disease is due to tuberculosis of the suprarenal capsules and demonstrates by its strange phenomena the derangement of metabolism following the loss of this internal secretion. It is marked by a peculiar pigmentation or bronzing of the skin accompanied by profound constitutional disturbances.

Apoplexy into the suprarenals is a cause of death in the newborn.

VESSELS AND NERVES OF THE ABDOMEN

Behind the peritoneum and in front of the vertebral column lie the aorta, the inferior vena cava, the thoracic duct, and the great sympathetic nerve.

The **abdominal aorta** extends from the aortic opening of the diaphragm, and descending along the vertebral column a little to the left it terminates at the fourth lumbar vertebra, where it divides into three branches.

Relations.—Behind, the vertebral column; in front, the lesser omentum and stomach, the third portion of the duodenum, the mesentery and aortic plexus; on the right side, the inferior vena cava, the vena azygos, thoracic duct, and right semilunar

ganglion. If the abdominal walls are thin the pulsations of the aorta can be readily felt in front of the vertebral column, and efficient compression may be made near its bifurcation (just above the umbilicus) where it approaches nearest the surface. Note also that direct compression of the aorta is practical during operative procedures when the emergency demands it, especially in the female pelvis.

Aneurysm of the abdominal aorta occurs most frequently at the celiac axis, which, because of the sudden deviation in the course of the circulation, is subjected to greater strain. Note the pressure symptoms produced by such an aneurysm—on the diaphragm, dyspnea; on the esophagus and stomach, dysphagia; on the biliary ducts, jaundice; on the renal veins, albuminuria; on the ureters, hydronephrosis; on the inferior vena cava, edema of the legs; and on the nerves, visceral and lumbar pains.

Ligation of the abdominal aorta has been performed a number of times, but in every instance death has occurred from a few hours to forty-three days after operation. Theoretically, it is possible to ligate the abdominal aorta at its lower two inches; that is, below the origin of the inferior mesenteric artery, so that a collateral circulation may be established favorable to the pelvic organs and the lower extremities.

The **inferior vena cava** is a much larger trunk than the aorta. It occupies the right side of the vertebral column and is placed to the right of the artery. It is formed at the level of the intervetebral disk which separates the fourth and fifth lumbar vertebræ, by the union of the common iliac veins. It passes upward to the under surface of the liver, the posterior surface of which it grooves, and traverses the central tendon of the diaphragm to terminate in the lower and back part of the right auricle.

Relations.—Behind, the vertebral column, the great sympathetic, the right renal and lumbar arteries, the right crus of the diaphragm; in front, the mesentery, right spermatic artery, third portion of the duodenum, the head of the pancreas, portal vein, posterior surface of the liver, which sometimes completely surrounds it. On the left side with the aorta, on the right side with the psoas muscle, the abdominal ureter, the internal border of the right kidney, the right suprarenal gland. The relations of the inferior vena cava are of special importance in the surgery of the kidney. In the course of a nephrectomy, especially for adherent tumors of the right

kidney, the vena cava has been wounded in many instances. In case of a linear wound, suture of the vein has been performed with success. If the wound is too large for suture the vena cava should be ligated above and below the wound. Circulation is re-established through the lumbar and spinal veins, and the vena azygos major.

The **lymphatic ganglia of the abdomen** consist of a chain of retroperitoneal lymph-nodes grouped about the great vessels and communicating above with lymphatics of the mediastinum, below with those of the pelvis. All the viscera of the abdomen and pelvis are drained by these lymph chains, which in turn are drained by the *receptaculum chyli.* These lymph-nodes may be the site of tubercular and cancerous degeneration as well as subperitoneal abscess.

The **thoracic duct** is the main trunk of the lymphatic system and drains all the lymphatic vessels of the body below the diaphragm, and, as a rule, the lymph from the left side of the body above the diaphragm. (The remaining lymph-vessels are drained by the right lymphatic duct.) It begins in a dilatation—the *receptaculum chyli,* situated in front of the second lumbar vertebra to the right and behind the aorta. It ascends and passes through the aortic opening in the diaphragm, traversing the whole extent of the posterior mediastinum, passing behind the arch of the aorta on the left of the esophagus, and at the level of the seventh cervical vertebra curves outward and downward in front of the scalenus anticus muscle, forming an arch over the subclavian artery, where it terminates in the left subclavian vein at its angle of junction with the left internal jugular vein. It is not rare to find the canal opening by many separate trunks into the jugular and subclavian veins (Tillaux). The danger of wounding the thoracic duct in operations at the root of the neck on the left side has already been alluded to (see page 173).

Chylous ascites may occur because of tumor, injury to, or pressure on the thoracic duct.

The **nerves of the abdominal viscera** are derived from plexuses formed by the sympathetic and branches of the pneumogastric and phrenic nerves.

The **solar plexus** is the great abdominal plexus, and is composed of the two semilunar ganglia which surround the trunks of the celiac axis, the superior mesenteric, and renal arteries. It is situated in front of the aorta, the crura of the diaphragm, and internal to the suprarenal capsules, extend-

ing downward as far as the pancreas. From this main plexus branch plexuses are derived which accompany the arteries to the various viscera.

Observe that the solar plexus communicates with the thoracic and spinal nerves, with the phrenic and pneumogastric nerves; that it supplies the viscera within the abdominal cavity, and communicates with the nerves which supply the walls of the cavity; that its distribution is both visceral and vascular, since the branches to the various viscera accompany the arteries in their minutest ramifications. Thus the solar plexus has been called the "*abdominal brain,*" because of its physiologic importance and the profound effects which follow its disturbance.

Shock is chiefly solar plexus depression, resulting in relaxation of the abdominal vasomotors, a retention of a large portion of the circulating blood in the abdominal vessels, and a consequent brain anemia. A blow on the abdomen over the solar plexus may cause instant death without evidence of external violence. Note the effects of peritonitis and prolonged operative interference in their grave reflex action on the heart, the respiration, and the kidneys.

The various reflex pains connected with diseases of the abdominal viscera have been mentioned in their appropriate chapters. They are anatomically interesting; they are diagnostically important in the correct interpretation of abdominal lesions.

CHAPTER XXII

THE PELVIS AND ITS CONTENTS

THE pelvis is a bony basin situated at the lowest portion of the trunk. Its purpose is twofold—it effectually protects the pelvic viscera, and it transmits the weight of the body to the lower extremities. It is open above and continuous with the abdominal cavity; it is closed below by muscular and fascial structures which form its floor and convert it into a cup-shaped cavity.

The pelvic basin is composed of four bones—the two innominate bones which bound it on the sides and in front, and the sacrum and the coccyx which complete it behind.

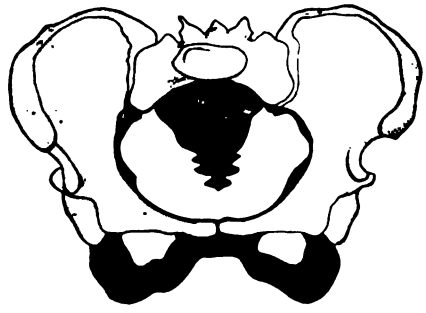

FIG. 243.—THE BONY PELVIS.
The shaded portion is the true pelvis and the outline the false pelvis.

It will be noted that this bony basin is naturally divided into two parts by the iliopectineal line (Fig. 243).

(*a*) The *false pelvis*—corresponding to the iliac fossæ above.

(*b*) The *true pelvis*—that part of the pelvic cavity below the iliopectineal line which is closed below by the perineum.

The female pelvis differs from the male in its greater breadth and capacity. Its depth is less, the sacrovertebral angle is less pronounced, the inlet is more circular, the pubic arch is wider, the bones are thinner, and the muscular impressions not so strongly marked. In its general conformation it is adapted to the act of parturition.

The **inlet of the true pelvis** (**pelvic brim**) is its superior circumference, formed by the iliopectineal line on the sides, the crest of the pubes in front, and the base of the sacrum behind.

Its **diameters** are the anteroposterior (conjugate), the transverse, and the oblique (Fig. 244).

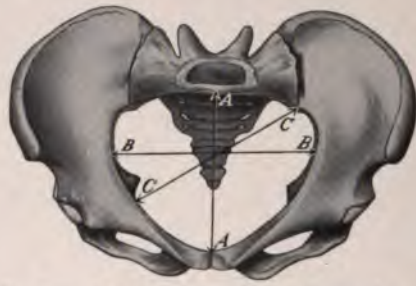

FIG. 244.—THE DIAMETERS OF THE PELVIC INLET.
A, *A*, Anteroposterior diameter; *B*, *B*, transverse diameter; *C*, *C*, oblique diameter.

The *anteroposterior* or *conjugate diameter* extends from the symphysis pubis to the sacrovertebral angle. Its average measurement is 4 in. in the male and $4\frac{3}{5}$ in. in the female.

The *transverse diameter* extends across the greatest width of the inlet, from the middle of the brim on one side to the same

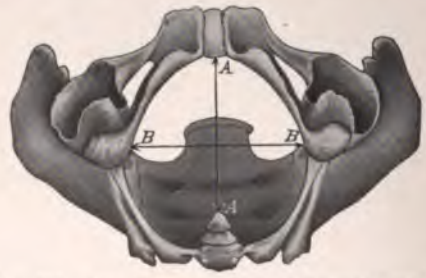

FIG. 245.—THE DIAMETERS OF THE PELVIC OUTLET.
A, *A*, The anteroposterior diameter; *B*, *B*, the transverse diameter.

point on the opposite side. Its average measurement is 5 in. in the male and $5\frac{1}{4}$ in. in the female.

The *oblique diameter* extends from the iliopectineal eminence on one side to the sacro-iliac symphysis on the other. Its average measurement is $4\frac{1}{4}$ in. in the male and 5 in. in the female (Gray).

The **outlet** of the pelvis is bounded by three bony eminences separated by three notches. The bony eminences are the tuberosities of the ischium, on each side, and the tip of the coccyx behind. The three notches are situated—one in front, the pubic arch, which is covered in by the soft parts of the anterior perineum and traversed by the genito-urinary organs; and one on each side—the sacrosciatic notches, which are converted into foramina by the lesser and greater sacrosciatic ligaments, and through which inflammations of the pelvis may communicate with the buttock. The diameters of the outlet are the anteroposterior and the transverse (Fig. 245).

FIG. 246.—VERTICAL SECTION SHOWING THE AXIS OF THE PELVIS.

The *anteroposterior diameter of the outlet* extends from the tip of the coccyx to the lower part of the symphysis pubis and measures 3¾ in. in the male and 4½ in. in the female.

The *transverse diameter of the outlet* extends from the posterior part of one ischiatic tuberosity to the other, and averages 3½ in. in the male and 4¾ in. in the female (Gray).

Position of the Pelvis.—In the erect attitude the pelvis occupies an oblique position. This obliquity varies in different subjects and is greater in the female. The pelvic inclination forms with a horizontal plane an angle of about 60°, so that

the base of the sacrum (in the female) is about 4 in. above the upper border of the symphysis pubis, and the tip of the coccyx about ½ in. above its lower border.

The Pelvic Axis.—It will be noted that the pelvic cavity is curved and that this curve corresponds to the concavity of the sacrum and coccyx; hence the axis of the pelvis is curved (Fig. 246). Its general direction corresponds to a line drawn from the anus to the umbilicus. The curve and general direction of the pelvic axis is a point of great practical importance in explaining the course of the fetus during parturition, and as a guide to the surgeon in properly directing instruments during operations on the pelvic viscera.

The Sacro-iliac Joint.—The wedge-like sacrum articulates on each side with the iliac bones, and thus forms the keystone of the pelvic arch. The joint thus formed has no appreciable movement except in hyperflexion or hyperextension of the thighs, when there is a slight rotation on its transverse axis. Note the fact that since this joint supports the entire weight of the upper part of the body, and is normally immobile, it must be evident that it is subject to considerable strain and materially assists in modifying the effects of shocks.

Sacrocoxalgia is an inflammation of the sacro-iliac joint, which appears most frequently after the age of twenty and is usually of tubercular origin. When abscess forms it may follow the course of the psoas muscle, or pass through the sciatic notch and appear below the glutei muscles, or through the obturator foramen and appear at the inner side of the thigh. Note the nerve supply of this joint and *the location of pain in sacrocoxalgia.* It is supplied by the superior gluteal, branches from the lumbosacral cord, the upper sacral nerves, and sometimes twigs from the obturator. Hence there is not only local pain in standing or sitting, but *reflected pain* over the sacral region and in the buttock (sacral and gluteal nerves), and sometimes pain in the calf and thigh (lumbosacral cord).

The Symphysis Pubis.—The two pubic bones unite in the median line to form an amphiarthroidal joint. In addition to the peripheral ligaments which surround it, its principal means of union is the interarticular fibrocartilage, which bears a strong analogy to the intervertebral disks. This ligament presents a central spongy portion and a compact periphery. In the adult it contains a cavity of variable dimensions, larger in the female than in the male. This ligament is said to undergo certain modifications toward the end

of pregnancy which contribute a certain amount of laxity to the articulation, favorable to the passage of the fetus.

Symphyseotomy.—In certain cases of contracted pelvis it has been proposed to divide the symphysis pubis as a substitute for Cesarean section. Since, however, a separation of the symphysis of 2½ in. increases the anteroposterior diameter only ½ in., and this separation is often attended by laceration of the sacro-iliac ligaments and damage to the attachments of the pelvic viscera, the value of this procedure is doubtful.

Fractures of the Pelvis.—Recall the fact that the pelvis represents a complete basin, but not of equal resistance at all points; the pubic segment is the weakest. Tillaux has shown that the pubic segment is fractured by *direct violence* when the pelvis is compressed in an anteroposterior direction, and by *indirect violence* when it is compressed transversely. At whatever point the pelvic ring is compressed the lesion is the same, fracture of the pubic segment. In addition to compression injuries, the pelvis is sometimes fractured by falls from a height when the patient alights upon the feet or ischial tuberosities; here, again, the pelvic segment usually gives way, though in rare cases the head of the femur may be driven through the acetabulum. *Fractures of the pelvis are serious, not because of the bony injury, but because of injury to the pelvic viscera.* Rupture of the bladder, urethra, or bowel may complicate fractures of the pelvis and make the prognosis extremely grave.

Pelvic deformities are of two classes—those due to faulty development and those the result of disease. The contracted pelvis of arrested development and those anomalous conditions due to rachitis, osteomalacia, new growths, and fractures are of importance to the obstetrician. The voluminous data connected with this subject must be left to the special works on obstetrics.

The Pelvic Diaphragm.—If the abdominal and pelvic cavities be considered as one it will be observed that the cavity is limited above and below by a diaphragm—above, the *roof*, formed by the dome-like thoracic diaphragm, its concavity directed downward; below, the *floor* formed by the cup-like pelvic diaphragm, its concavity pointing upward.

To clearly understand the formation of the pelvic diaphragm, imagine that the pelvic viscera have been removed, that the sides of the pelvis are lined by the thick obturator internus muscles, and the back of the pelvis on either side of the sacrum is padded

by the pyriformes muscles. Now in this cavity suspend a cup-shaped musculomembranous diaphragm, and it is evident that this diaphragm acts as a partition which separates the pelvic cavity above from the perineum and ischiorectal fossæ below. Observe that the largest and most important factor in this diaphragm is the levator ani muscle. It is true that the coccygeus completes the diaphragm posteriorly and that the triangular ligament of the urethra fills in a small space just beneath the symphysis pubis, but the *levator ani constitutes the major portion of the pelvic diaphragm* (Fig. 247).

FIG. 247.—THE PELVIC DIAPHRAGM, FORMED BY THE LEVATOR ANI MUSCLE.

The **levator ani muscle** arises from two bony points and an intermediate thickened line of fascia:

(*a*) From the posterior surface of the body of the pubis, about 10 mm. external to the symphysis.

(*b*) From the tendinous arch or "white line" which marks the thickened line of fascia extending from the posterior surface of the pubis to the spine of the ischium.

(*c*) From the spine of the ischium.

The general course of all the fibers is downward and backward, and their insertion may be divided into three sets:

(*a*) The anterior fibers cross (without being inserted) the lateral surface of the prostate in the male and the vagina in the female, and unite with those of the opposite side in the space between the anterior surface of the rectum and the posterior surface of the prostate or vagina.

(*b*) The middle fibers fuse with the longitudinal fibers of the rectum and the external sphincter ani.

(*c*) The posterior fibers terminate behind the rectum, some being inserted into the tip of the coccyx, others uniting with those of the opposite side in the space which separates the anus from the coccyx.

Nerve Supply.—Branches from the fourth sacral and pudic nerves.

Action.—Since the levator ani uniting with the muscle of the opposite side is the principal factor in forming the pelvic diaphragm it must be a passive agent in maintaining the pelvic organs in position and preventing their prolapse. Furthermore, when it is recalled that its points of insertion

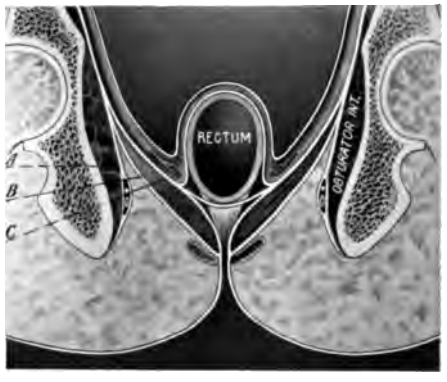

FIG. 248.—THE PELVIC FASCIA.
A, The obturator fascia; *B*, the ischiorectal fascia; *C*, rectovesical fascia.

are all at a lower level than any part of its origin, and that the direction of its fibers is downward and backward, it must be an active agent in lifting the pelvic floor upward and forward. Thus in the act of defecation it facilitates the expulsion of the fecal mass by pulling the rectum upward and drawing the anal segment forward, and so co-operating with the action of the diaphragm and abdominal muscles. Some of the fibers uniting with those of the opposite side pass behind the rectum and vagina and act as constrictors. In the latter organ when this action is exaggerated *vaginismus* may be produced (Testut).

The **pelvic fascia** is a continuation of the transversalis fascia in front and of the iliac fascia on the sides. Above, it is attached to the posterior surface of the os pubis and to the

brim of the pelvis. Posteriorly, it covers the pyriformis muscle, and is gradually thinned out on the front of the sacrum. Beginning, then, at the brim of the pelvis it descends over the obturator internus muscle to the tendinous arch, or "white line," which marks the thickened line of fascia extending from the posterior surface of the body of the pubis to the spine of the ischium and also provides for the fascial attachment of the levator ani muscle. At the "white line" the fascia divides into two layers, an outer (the obturator fascia), and an inner (the rectovesical fascia) (Fig. 248).

The **obturator fascia** descends on the inner surface of the obturator internus and forms a sheath for the pudic vessels and nerves. It is attached below to the tuberosity of the ischium, the great sacrosciatic ligament, and the pubic arch, where it blends with the corresponding layer of the opposite side, and thus forms the posterior layer of the triangular ligament. It gives off the *ischiorectal fascia* which lines the under surface of the levator ani muscle.

The **rectovesical fascia** extends downward and inward over the upper surface of the levator ani and invests the bladder, prostate, and rectum. In front, the fascia passes from the lower part of the pubic bone and is reflected over the prostate and neck of the bladder, forming the *anterior true ligaments of the bladder*. From the sides of the pelvis it is reflected over the lateral surface of the bladder and forms the *lateral true ligaments of the bladder*. It also forms the *capsule of the prostate*, and covers the seminal vesicles and ducts. The fascia from the two sides meet in front of the rectum and complete the partition between the perineum and the pelvic cavity.

It is evident from this arrangement of the pelvic fascia that suppurative processes are, as a rule, well limited, either above the fascia to the pelvic cavity, or below to the ischiorectal fossa and perineum. Likewise, certain portions of the pelvic viscera are excluded from the pelvic cavity, and may be wounded without invading the cavity, notably the prostate, seminal vesicles, the neck of the bladder, and the lower portion of the rectum.

Wounds of the perineum are serious if they involve the pelvic fascia and open up the pelvic cellular tissue where inflammation rapidly extends.

The Pelvic Cellular Tissue.—Between the pelvic fascia and the pelvic peritoneum is a layer of loose cellular tissue in which

are contained the iliac vessels and their branches, the pelvic lymph-glands, the ureters, vas deferens in the male, and the round ligaments in the female.

Characteristics.—It is most abundant in certain locations; viz., between the anterior wall of the bladder and the pubis, about the base and neck of the bladder, between the bladder and rectum; in the female, between the layers of the broad ligament and about the lower part of the uterus and upper part of the vagina (Treves). It communicates with the subperitoneal fascia of the iliac fossæ; through the obturator foramen with the connective tissue on the sides of the pelvis; through the great sacrosciatic foramen with the connective tissue of the gluteal region. Hence, when this tissue is the seat of infection (*pelvic cellulitis*), the site and subsequent course of purulent collections are a matter of great clinical interest, and will be alluded to in connection with the pelvic viscera.

THE PELVIC VISCERA

THE RECTUM

The **rectum** is the terminal segment of the large intestine. It begins in front of the body of the third sacral vertebra and follows the curve of the sacrum and coccyx to a point about 1 in. in front of the tip of the coccyx, where it takes a sharp bend backward and ends at the anal orifice (Fig. 249). Note the fact that the rectum presents two distinct curves—above, the concavity is in front and follows the sacrum and coccyx; below, the concavity is behind and very short, so that the anal segment of the rectum is almost at right angles to the rectum proper. *This double curve is of great practical importance* in introducing the rectal tube or speculum. *Remember that the direction of the canal is upward and forward for* 1½ *in., then upward and backward.*

It will thus be seen that the rectum may be divided into two portions, the superior or pelvic portion and the inferior or anal canal. Note that this division is by no means an arbitrary one for purposes of convenient description; it is a division based on structural, developmental, and pathologic differences which have important surgical significance.

The **pelvic portion** measures from 4 to 6 in. in length and is situated within the pelvic cavity. The caliber of this segment is subject to great variations. In its upper third

it is comparatively narrow, at its lower two-thirds it expands and forms the *rectal ampulla*, and contracts again at its junction with the anal segment. This portion of the rectum is capable of great distention, as demonstrated by the large fecal accumulations and the strange foreign bodies which have been found (bottles, glass tumblers, etc.). By gradual dilatation the entire hand may be introduced into the rectum, and has been

FIG. 249.—THE RECTUM.
Note that (*A*) the anal portion is almost at right angles to (*B*) the rectum proper.

advocated for purposes of examining the abdominal contents. The procedure, however, has been abandoned because of the laceration to the parts and the cramped position of the hand.

Peritoneal Reflections.—The upper part of the rectum is covered in front and on the sides by peritoneum, but not posteriorly. Beginning opposite the third sacral vertebra the peritoneum is reflected on the sides of the rectum in an oblique line descending from behind forward, and finally

leaves the front of the bowel about 1 in. above the prostate, and is reflected onto the posterior wall of the bladder in the male and the upper fifth of the posterior wall of the vagina in the female, forming between the rectum and bladder or vagina a sort of cul-de-sac, the *cul-de-sac of Douglas* (recto-vesical or rectovaginal pouch) (see Fig. 249).

The lower level of the rectal peritoneum is subject to variation according to sex and condition of the bladder and rectum. It is on a higher level in the male than in the female, in the adult than in the child, and when the bladder or rectum are distended. On an average, it is about 3 in. from the anus in the male and 2¼ in. in the female. When the bladder or rectum is full the distance may be increased by 1 in. or over. It is well to remember that Douglas's cul-de-sac reaches a greater depth in the infant, and that occasionally this cul-de-sac is continued on in the adult. Marchand shows that this anatomic peculiarity explains those rare conditions in which the intestine engages in an abnormal Douglas cul-de-sac, gradually distends it and, in turn, the perineum, until finally there is produced a *perineal hernia;* or if the perineum is resistant, it may gradually distend the anterior rectal wall until the sac of the hernia appears through the anal orifice. In treating prolapse of the rectum this rare condition is worth remembering.

Extraperitoneal Relations.—*In front* are the vasa deferentia, the seminal vesicles on either side of the median line, leaving a triangular space corresponding to the base of the bladder, and further down the posterior surface of the prostate (see Fig. 249). Note that these organs are not in immediate contact with the rectum, but that a thin layer of pelvic fascia intervenes. *Posteriorly*, the rectum is in relation with the sacrum and coccyx, but separated by the *retrorectal space*, which is filled with loose cellular tissue. This latter relationship has a practical bearing as a means of access in resecting the rectum. *Laterally*, below the peritoneal reflection, are the lateral fibers of the levator ani muscle, and in the lateroretal space the vessels, nerves, and ureters.

Rectal Examination.—The foregoing relations emphasize the value of digital exploration per rectum. The seminal vesicles, the base of the bladder, the lower portion of the ureters, and the prostate are all accessible to the rectal touch, while in the female the retroverted uterus, prolapsed ovary, many neoplasms, and inflammatory changes may be readily detected. The functional derangements of the rectum

in cystitis, prostatitis, and vesiculitis, and likewise the effects of stricture and cancer of the rectum on these organs are readily appreciated.

The **anal canal** or terminal segment of the rectum is a short and narrow passage about 1½ in. in length, surrounded by the sphincters and the levator ani muscles. Its direction is downward and backward, forming with the pelvic rectum almost a right angle. The tonic action of the sphincters maintains the anal walls in contact except during defecation; when these muscles are paralyzed incontinence of feces results.

Hilton's "white line" is the white line seen at the junction of the skin and mucous membrane which corresponds to the line of junction of the internal and external sphincters of the anus.

Relations.—*In front* the *recto-urethral triangle* (of which the perineum forms the base, the membranous urethra the anterior wall, the rectum the posterior wall, the apex being directed upward toward the prostate). This triangle is the usual route for reaching the posterior urethra and prostate.

In the female a similar triangular area of tissue separates the anal canal from the posterior vaginal wall.

Laterally, it is related to the right and left ischiorectal fossæ.

Behind are the posterior fibers of the levator ani muscle.

Structure of the Rectum.—Its muscular coat, like the rest of the intestine, is composed of a superficial layer of longitudinal fibers and a deep layer of circular fibers. The longitudinal fibers are not arranged in three bands, as noted in the large intestine, but are spread out evenly. The circular fibers increase in number as the termination of the rectum is approached, and at the anal canal abruptly thicken to form the *internal sphincter*.

The *submucous coat* of the rectum contains the vessels and nerves which supply the bowel. It is particularly loose, so that the mucous membrane can easily slide over the underlying muscular coat. This is even *more pronounced in infants and children;* hence *prolapsus of the rectum* may follow habitual straining at stool. It may be partial, involving only a portion of the mucous membrane, or total, in which all the layers of the bowel are involved. For the reason noted above this condition is more frequent in infants and children and is secondary to phimosis, rectal polypi, and conditions which incite straining at stool.

The *mucous membrane* of the rectum is thick, vascular, and

loosely connected with the underlying muscularis. It contains a large number of solitary and tubular glands, the latter supplying mucus.

The mucous membrane of the rectum proper forms three or more transverse folds placed on the front and sides of the bowel—*Houston's valves.* These folds are permanent and are not effaced by distention of the rectum. In the introduction of a bougie or rectal tube these valves may impede its progress. Tuttle believes that these valves support the fecal mass and give it a rotary motion as it descends.

FIG. 250.—THE COLUMNS (*A*) AND VALVES (*B*) OF MORGAGNI.
Note transverse fold above, forming Houston's valve.

The mucous membrane of the anal canal forms longitudinal folds, the *columns of Morgagni;* between the lower ends of these columns are formed semilunar valves, the *valves of Morgagni* or *anal valves,* a series of little pockets well marked posteriorly (Fig. 250).

In general, remember that the *mucous membrane of the rectum proper is absolutely different from that of the anal canal.* The latter is a transitional structure between skin and mucous membrane proper. The epithelium of the anus is squamous, that of the rectum is columnar; hence the type of cancer differs in the two segments.

Vessels and Nerves.—The arteries of the rectum are derived from three sources—the *superior hemorrhoidal*, a branch of the inferior mesenteric; the *middle hemorrhoidal*, a branch of the internal iliac; and the *inferior hemorrhoidal*, from the pudic artery. The branches of the superior hemorrhoidal artery traverse the submucous coat in a longitudinal direction and at the level of the internal sphincter join with the branches of the middle and inferior hemorrhoidals, forming a series of anastomotic loops about the anus.

The **veins** of the rectum begin in a rich plexus, the *hemorrhoidal plexus*, situated in the submucous coat and surrounding its lower extremity. From this plexus ascending branches are given off, which pierce the muscular coat about 5 in. above the anus, and unite to form the superior hemorrhoidal vein, which empties into the inferior mesenteric branch of the portal vein. A smaller portion of the blood is carried by the middle and inferior hemorrhoidal veins to the internal iliac and internal pudic veins. *Observe that while the hemorrhoidal plexus is a connecting link between the systemic and portal systems of veins, most of the blood is returned by way of the portal system.* Another fact of practical importance is the observation of Testut, that normally there are small saccular dilatations of the hemorrhoidal vessels about the size of a pea situated near the semilunar valves of Morgagni, placed irregularly around the bowel just above the anal margin, and that they are the miniatures of what may subsequently develop into *hemorrhoids* or *piles*.

The Nerves.—The rectum proper is supplied by sympathetic branches from the mesenteric, sacral, and hypogastric plexuses and branches from the third, fourth, and fifth sacral nerves. The anal portion is supplied by branches from the sympathetic plexuses and by the inferior hemorrhoidal branch of the pudic nerve which supplies the external sphincter and the skin of the anus. As already observed, there are marked structural differences between the pelvic rectum and the anal canal. This fact is strikingly emphasized by the nerve supply. The rectum possesses little sensibility; the anal canal is exquisitely sensitive. Affections of the rectum proper (cancer, etc.) are comparatively painless, whereas those of the anal canal cause extreme pain. Observe, further, that the anal canal and the neck of the bladder are intimately associated through their nerve supply (the fourth sacral). Painful affections of the anus are frequently accompanied by cystalgia, frequent

desire to urinate and retention of urine, and reciprocally, lesions of the bladder are associated with rectal tenesmus. As a general proposition, which will receive constant confirmation as the separate organs are studied, the pelvic viscera, the thigh and leg, and the perineum and external genitals are intimately associated through the nerves of the sacral plexus.

The **lymphatics** of the rectum may be divided, according to Poirier, into three groups. The upper portion of the rectum is drained by lymphatics which pass first through the rectal glands situated in the retrorectal space and terminate in the glands of the mesosigmoid. The lower portion of the rectum is drained by lymphatics which follow the middle hemorrhoidal vessels and terminate in the iliac glands. The skin of the margin of the anus is drained by the superficial inguinal glands.

The arrangement of the rectal lymphatics suggests a clinical fact of great importance. Extirpation of high rectal cancer is followed by better results than cancer in the lower segment, because the lymph stream from the upper rectum is interrupted by a number of glands closely associated with the rectum, which are easily removed with the growth; the lymph stream from the lower rectum passes directly to the iliac glands, which are not accessible; hence, operations for cancer of the lower rectum are necessarily incomplete.

Clinical Considerations.—Suppurations about the rectum, unless relieved by early incision, have a tendency to discharge in two directions:

(*a*) Through the skin in the vicinity of the anus.

(*b*) Through the rectal wall of the anal canal, thus leaving a fistulous tract, which, as a rule, has both a mucous and cutaneous opening—*fistula in ano.*

Fistula in ano may consist of a simple suppurating tract leading from the cutaneous to the mucous opening, or there may be a number of external openings with the tract partially encircling the anus—*horseshoe fistula.* Either the cutaneous or mucous opening may heal—*blind fistula.* If the abscess is of anal origin the internal opening is usually between the two sphincters; when it follows an ischiorectal abscess the opening in the rectum is at a higher level. Whatever the length of the fistulous tract, a cure can be obtained only by dividing the bridge of tissue between the two openings.

Hemorrhoids or **piles** are the result of a varicosed condition of the hemorrhoidal veins within the anal canal (*internal*

hemorrhoids), or around the anal orifice (*external hemorrhoids*). Their etiology is suggested by the anatomic conditions.

Note (*a*) that the hemorrhoidal veins course in a longitudinal direction in loose cellular tissue which affords no support.

(*b*) The absence of valves.

(*c*) The exit of the veins through slit-like openings act like constrictors if the gut is subjected to abnormal muscular contraction.

(*d*) The connection of the hemorrhoidal veins with the portal system and the effects of portal obstruction.

(*e*) The effects of chronic constipation in obstructing venous return by the pressure of fecal masses.

(*f*) The normal dilatations of the hemorrhoidal veins found between the semilunar valves of Morgagni, which are the miniatures of what may subsequently develop into hemorrhoids.

Fissure of the anus, or ulcer within the anal folds, is characterized by intense spasm of the sphincter and violent pain. The symptoms are out of all proportion to the lesion; their anatomic explanation is interesting. Hilton has called attention to the fact that the *same nerves which supply the mucous membrane supply the muscular apparatus acting upon that membrane.* Observe how this law is corroborated in fissure of the anus. The exposure of the sensory nerve filaments on the ulcer surface causes reflex spasmodic contraction of the sphincter. As the sphincter contracts, it squeezes the sensitive edges of the ulcer; in course of time the sphincter hypertrophies and the symptoms which at first appeared for a short time after stool are later prolonged from one stool to another. The cause of the symptoms also suggests the rational treatment—forcible dilatation of the sphincter or division of the muscle to secure physiologic rest.

Strictures of the rectum may be cicatricial or malignant. *Cicatricial stricture* is the result of injury or ulceration following inflammation. Its most common cause is syphilis. *Syphilitic strictures* usually occupy the same position at the upper level of the internal sphincter and involve the entire circumference of the bowel (*annular stricture*). All strictures of the rectum are followed by chronic intestinal obstruction, the intestine dilates above the retracted point, and important alterations in the mucosa are produced.

Malignant stricture is the result of cancer originating in the columnar epithelium of the rectum or in the squamous epithelium of the anal canal. In addition to the local mechanical

effects of obstruction there is regional extension to the prostate, bladder, and seminal vesicles; in the female the uterus and vagina may be involved. The regional lymphatics and their important distribution have already been alluded to (see p. 475). Attention must here be called to the communication of the hemorrhoidal veins with the portal system; thus cancerous emboli are directly carried to the liver, where secondary growths are developed.

Excision of the Rectum.—It is evident from the anatomic relations that the rectum may be approached by three routes:

(*a*) The perineal.

(*b*) The sacral.

(*c*) The abdominal, combined with the perineal.

The first route must necessarily be confined to lesions situated low down, and because of limited room cannot be utilized for cancerous lesions where extensive removal is the only hope of cure.

The sacral route, as devised by Kraske, gives an excellent exposure of the rectum. Beginning below the level of the third posterior sacral foramen (to avoid paralysis of the sphincters of the rectum and bladder—third and fourth sacral nerves), the lateral mass of the sacrum is chiseled away, the diseased portion removed, and the divided ends of the gut approximated by suture. The upper line of bone section may be determined by measuring two fingers'-breadth above the lower extremity of the sacrum, the coccyx having been disarticulated (Taylor). If more room is required, a transverse section of the sacrum may be made, as suggested by Bardenheuer. In cancer high up the combined abdominal and perineal route is the most satisfactory, because it permits of the most extensive removal. By this route the gut is divided at the sigmoid flexure, the upper end being sutured in the left inguinal region (artificial anus). The divided portion is freed from its attachments as far in a downward direction as possible, and removed through the perineal route.

Imperforate Anus.—There are many curious developmental defects of the rectum and anus, such as absence of the rectum or anus, or both; and again the opening of the rectum at some unusual point, such as the bladder, deep urethra, and vagina. The most common congenital defect of the rectum is *imperforate anus*, occurring most frequently at the anorectal junction. The reason for this defect is apparent. The rectum and anal canal are developed independently of each other. The rectum

is developed from the terminal extremity of the hind-gut, the anal canal by an invagination at the site of the anus, the septum between the two is normally absorbed, and a continuous canal formed. Failure of this partition to absorb results in imperforate anus. The occlusion may consist of thin membrane which is readily incised, or it may attain considerable thickness, requiring inguinal colostomy for immediate relief and subsequent plastic operation for establishing a permanent canal.

THE BLADDER

The **bladder** is a musculomembranous reservoir receiving the urine conveyed by the ureters and expelling the same through the urethra. This intermediate position of the bladder, between the ureters and urethra, explains in a large measure the sources of its infection—descending from the ureters, ascending from the urethra.

The function of the bladder is to collect the urine and void it at regular intervals; any irregularity of this function is suggestive of some disorder; hence, *disorders of micturition are diagnostically significant.*

The bladder is situated within the pelvic cavity behind the symphysis pubis. When filled it rises to the height of the pubis, when distended it ascends out of the pelvis, rests directly against the abdominal wall, and may rise to the umbilicus. The capacity of the bladder varies in different individuals, according to habit and constitutional peculiarities. Normally it holds about a pint before the necessity for urination is felt. The normal capacity of the bladder is modified by disease; for example, it is reduced in cystitis, when the sensitive mucous membrane will tolerate only a small quantity; it is increased in those affections where there is some obstacle to its free expulsion, as in stricture of the urethra and hypertrophied prostate.

The **relations** of the bladder to the neighboring organs and structures are very important, and it must be noted that they vary according as the bladder is full or empty (Fig. 251). When empty it is completely hidden behind the pubis, from which it is separated by a triangular space filled with loose cellular tissue, **Retzius' space,** or the **prevesical space.** The loose cellular tissue is continuous with the subperitoneal fascia of the neighboring regions; hence, in an inguinal or crural hernia it is readily seen how this tissue may engage in

the canal and drag along with it a segment of the bladder. Again, inflammations of the prevesical cellular tissue may invade the subperitoneal tissue of the pelvis and abdomen, and likewise subperitoneal phlegmon of the abdomen may burrow into Retzius' space. Urine extravasated into the prevesical space would naturally follow the same course. Retzius' space is a most important means of access to the bladder; a correct understanding of its relations is, therefore, essential. Keep in mind the fact that the bladder is normally devoid of peritoneum on its anterior surface; the peritoneum covers the anterior abdominal wall as far as the symphysis

FIG. 251.—RELATIONS OF THE BLADDER TO THE ABDOMINAL WALL WHEN FULL AND WHEN EMPTY.
A, Retzius' space.

pubis, where it is reflected on to the superior surface of the bladder (Fig. 251). Therefore, *when the bladder is below the superior border of the pubis there is no fold of peritoneum in front.* When the bladder is distended above the pubis its direction is obliquely upward and forward toward the anterior abdominal wall, the peritoneum on its superior surface is pushed in the same direction, and so the upper anterior surface of the distended bladder is thus covered by a fold of peritoneum (see Fig. 251). The lower anterior surface of the distended bladder in contact with the anterior abdominal wall is devoid of peritoneum for a distance of 2 in. above the pubis. This fact is of great practical importance, since by distending the

bladder with air (Bristow's method) its anterior surface is placed in direct contact with the anterior abdominal wall, without the intervention of the peritoneum, for a distance of 2 in. above the pubis. Thus through this area the bladder may be safely tapped or opened by incision and drained.

The **posterior surface** is convex and is moulded to the concavity of the rectum. It is covered by peritoneum, which here forms a fold as it returns to cover the anterior surface of the rectum. This rectovesical fold of peritoneum, dipping down between the rectum and bladder, is the cul-de-sac of Douglas (see p. 471).

The **lateral surfaces** are in relation with the levator ani and obturator internus muscles. They are partly covered by peritoneum—the upper half. The lower half of the lateral surface is in relation with the loose cellular tissue above the perineal fascia. The posterior part of this surface is crossed by the vas deferens, which passes between the ureter and the bladder.

The **base** of the bladder has a number of important relations which are of great clinical value (see Fig. 251):

(*a*) The *neck of the bladder* is the point at which the urethra joins the bladder. It must be remembered that it is not a neck in the sense of a tapering portion of the bladder, nor must it be confounded with the trigone. *It is a point of junction rather than a surface area*, and represents a point of constriction at the outlet of the bladder. It is surrounded by the prostate gland in the male, by which it is held firmly in position. When the individual is in the erect position its direction is downward and it is situated about 1 in. behind the center of the symphysis. The neck of the bladder is surrounded by a sphincter muscle, which opposes the constant exit of urine by closing the internal orifice of the urethra. It opens when the pressure of the urine stimulates the action of the deep muscular fibers of the body of the bladder. Normal micturition is, therefore, an equilibrium between the action of the body and the neck (Tillaux). When the sphincter of the bladder is abnormally contracted, retention of urine occurs; when it is relaxed (paralysis of the sphincter) incontinence results.

(*b*) The *intervesicular triangle* represents that portion of the base in relation with the rectum. It is bounded behind by the rectovesical fold of peritoneum, and on the sides by the seminal vesicles and vasa deferentia, the apex extending forward to

the prostate (Fig. 252). At the two posterior angles of this triangle the ureters cross the vasa deferentia and enter the bladder wall. Thus it will be observed that this external triangular area corresponds to the trigone on the internal surface of the bladder.

Practically it suggests the feasibility of exploring the bladder by the rectal touch, and a means of access to the bladder without puncturing the peritoneum, though the latter procedure is rarely practised because of the persistence of recto-vesical fistula and the possibility of wounding important structures.

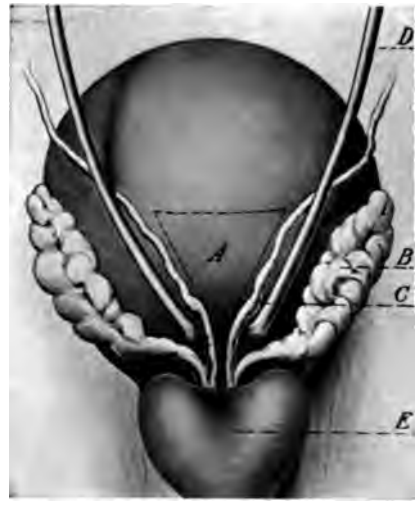

FIG. 252.—THE INTERVESICULAR TRIANGLE: THE PORTION OF THE BLADDER IN RELATION TO THE RECTUM.
A, Intervesicular triangle; *B*, seminal vesicles; *C*, vas deferens; *D*, ureters; *E*, prostate.

The bladder wall is composed of four coats: serous, muscular, submucous, and mucous. When empty it measures about ½ in. in thickness, when moderately distended about ⅛ in. The internal surface of the bladder is lined with mucous membrane which is loosely connected with the subjacent structures to allow the viscus to accommodate itself to the constantly varying size. This arrangement is seen in the empty bladder in the numerous folds into which the mucous membrane is thrown.

Note, however, an important exception to this arrangement of the mucous membrane. Over the surface of the trigone the

mucosa is closely adherent and rugæ are never present. This area of the bladder is one of special interest because of its clinical importance.

The **vesical trigone** is a triangular area on the internal surface of the base of the bladder, at each angle of which is an orifice: the urethral orifice below and in front, the two ureteral orifices above and behind (Fig. 253). The base is formed by a prominent ridge which extends from one ureteral orifice to the other; the apex corresponds to the urethral orifice. Thus the three orifices represent the three angles of an equilateral triangle measuring about 1½ in. on the sides.

FIG. 253.—THE INTERIOR OF THE BLADDER, SHOWING THE VESICAL TRIGONE (*A*).

This triangular area is the **pathologic triangle of the bladder;** at its angles are the three gateways of bladder infection; its sides bound an area within which the pathologic lesions of the bladder predominate. Recall the fact that the ureters traverse the bladder wall obliquely for ½ in., so that the mucosa forms a valve which closes the ureteral orifices as the bladder becomes distended. *Hence the urine is never forced back into the ureters, whatever the degree of distention.*

The **fundus** of the bladder is the portion situated behind the trigone. Up to a certain age the fundus and trigone are on the same level, but as age increases and the prostate hypertrophies, the trigone is elevated and the fundus sinks below the level of the trigone. In the aged it may form a diverticulum

in which calculi may lodge or urine may be retained. In enlarged prostate the bladder never completely empties itself because of the depressed fundus which retains the residual urine.

Vessels and Nerves.—The bladder possesses a rich vascular supply.

The **arteries** are the superior, middle, and inferior vesical—all branches of the internal iliac artery. In the female additional branches are received from the uterine and vaginal arteries.

The **veins** accompany the arteries, the larger branches being directed toward the base of the bladder, where they form a complicated plexus which anastomoses with the prostatic plexus and opens in the internal iliac vein.

When the great vascularity of the bladder is considered it is readily seen why *hematuria is a symptom of most bladder affections.*

Again, it will be noted that the vascular area centers at the base. The largest vessels are situated on either side of the median line; hence in entering the bladder by the subpubic route, by following the exact median line the least hemorrhage will be encountered.

The **nerves** are derived from—

(*a*) The pelvic plexus of the sympathetic.

(*b*) Branches from the third and fourth sacral nerves.

The bladder is, therefore, innervated by two systems, the cerebrospinal and the sympathetic. The mucosa has, normally, little sensibility, as shown in the passage of a catheter or sound; when inflamed, however, it is extremely sensitive, especially in the region of the trigone and neck. Attention is again called to the intimate relation of the nerve supply of the pelvic organs and the various reflexes noted in affections of the bladder; for example, pain in the bladder and rectal tenesmus, affections of the rectum and retention of urine, and pain at the end of the penis in stone of the bladder.

The **lymphatics** of the bladder terminate in the glands situated along the internal and external iliac vessels. The mucous membrane of the bladder contains no lymphatics. There are small lymphatic glands situated in the prevesical space in which prevesical abscess may originate.

The **female bladder** in a general way resembles that of the male. It occupies the same position and has the same structure.

Points of Difference.—Because of the absence of the prostate the neck is very distensible. This is a fact of practical utility which may be applied in dilating the urethra for the purpose of exploring the bladder or for the extraction of stones and other foreign bodies. The bladder is related posteriorly to the uterus, being separated by a fold of peritoneum —the intervesical pouch. Below this fold the bladder is in contact with the cervix uteri and the upper half of the vagina. The loose connective tissue between the bladder and uterus allows it to be easily separated in extirpation of the latter organ. The relations of the bladder to the uterus and vagina explains the occurrence of vesico-uterine and vesicovaginal fistula which sometimes follows difficult and protracted labors. It also suggests the possibility of exploring the bladder by the vaginal touch and entering the bladder through a vaginal incision (see Fig. 258).

In the female bladder there is not found the deep depression behind the trigone which is usual in the male; on the contrary there is frequently a median prominence formed by the neck of the uterus, on each side of which are two depressions in which a stone or foreign body is apt to lodge.

The ureters course between the bladder and the anterior wall of the vagina and open into the bladder about 1 in. below the level of the cervix. Hence in vaginal hysterectomy and amputations of the cervix the location of the ureters should be kept in mind and avoided by directing the knife close to the anterior surface of the uterus.

Clinical Considerations.—The position of the bladder within the pelvic cavity and behind the symphysis pubis gives it a certain protection against injury.

Wounds of the bladder, however, may be brought about by the sharp fragments of a fractured pelvis penetrating its walls; the distended bladder may be ruptured by a blow applied to the abdominal wall, without fracture of the pelvis or evidence of external injury. Penetrating wounds of the perineum, rectum, or great sacrosciatic foramen may involve the bladder. The danger attending wounds of the bladder is the extravasations of urine into the surrounding tissues (intraperitoneal or extraperitoneal). In extraperitoneal extravasation of urine the loose cellular tissue between the bladder and the pelvic wall is rapidly invaded and even the subperitoneal tissue of the abdominal wall may be involved.

Extroversion of the bladder is due to a congenital defect

in which the lower part of the abdominal wall and the anterior wall of the bladder are wanting, so that the posterior wall of the bladder with its ureteral orifices may be seen protruding through the abdominal defect. The treatment of this condition is most difficult, since implantation of the ureters into the intestine is usually followed by stricture of the ureteral orifices and ascending infection of the kidney.

Malpositions.—As already noted, the bladder may be found in an inguinal or femoral hernia. In the female the adherence of the bladder to the anterior vaginal wall may cause a displacement of the bladder downward (*vaginal cystocele*) after the vaginal wall has been weakened by the overdistention of parturition.

Hypertrophy of the bladder wall may follow those conditions which give rise to chronic obstruction to the flow of urine (stricture and hypertrophied prostate). The muscular fibers of the bladder are overexercised in their effort to overcome the obstruction and stand out prominently in the wall of the bladder, producing an appearance known as "*fasciculated bladder*." Between these muscular bundles the wall is thin and easily distended, and as a result sacculi are formed in which urine may lodge or calculi develop. A sacculus may form which in time may become as large as the bladder itself.

The Pathologic Triangle.—Attention is again called to the triangular area at the base of the bladder which corresponds to the trigone, the three orifices at the three angles forming the three avenues of infection. This area is the center of vesical pathology; cystitis, tuberculosis, and papilloma are usually found at this point.

Access to the bladder may be gained for purposes of examination—

(*a*) By way of the urethra in sounding for stone, or in making a cystoscopic examination of the bladder wall. In the female the shortness and dilatability of the urethra suggest the feasibility of removing stones or other foreign bodies by this route.

(*b*) By way of the rectum the trigone may be palpated and calculi in the lower ends of the ureters can be recognized. Opening the bladder through the rectum has been abandoned because of the important structures at the base of the bladder and the certainty of infection from the rectum.

The bladder is opened by two routes:

(*a*) The *suprapubic route* is preferable and is the one usually

selected. The bladder is opened just above the symphysis, through the prevesical space, after inflation with air to increase the anterior surface of the bladder uncovered by peritoneum. Through this space the bladder may be tapped in cases of retention by the aid of a trocar.

(*b*) The *perineal route* is much less frequently used than formerly, because of the limited room and the inadequate exposure. It is used only in connection with obstructive lesions in which bladder drainage is desirable.

THE PROSTATE

The **prostate** is a glandular organ connected with the generative function. It envelops the neck of the bladder and is traversed by the first or prostatic portion of the urethra (Fig. 254). It secretes a viscid fluid which mixes with the sperm and exercises a beneficial influence on the vitality of the spermatozoids.

FIG. 254.—THE PROSTATE.
A, Anterior view; *B*, posterior view.

Its **form** has been compared to a horse chestnut, or, better, to a cone flattened from above down; its base is above and in contact with the bladder; its apex below in contact with the deep layer of the triangular ligament. Although the prostate seems to completely encircle the prostatic portion of the urethra, Spalteholz has shown that this organ does not completely surround it, that it is really in the form of a broad clasp, open in front, and that the interval is closed by the *prostatic muscle*,

continuous with the muscular fibers which close the urethral orifice (Fig. 255).

The prostate is surrounded by a fibrous sheath derived from the rectovesical fascia, which covers it, except at the apex and at the junction of its base with the neck of the bladder. Its *true capsule*, distinct from the sheath, is composed of fibrous tissue which is continuous with the stroma of the gland, and forms a complete investment. Fibrous prolongations pass between the sheath and the capsule, which hold the prostate firmly in its place, and in this compartment also lies the prostatic plexus of veins, situated chiefly on the anterior and lateral aspects of the gland. Thus it will be observed that the prostate is enveloped, first by its true capsule, secondly by its venous plexus, and thirdly by its sheath.

FIG. 255.—SECTION OF THE PROSTATE. Note that it does not completely surround the urethra.

Its **volume** varies according to age; in the child it is small, at puberty it suddenly increases in size like the other genital organs, and attains complete development at the age of twenty-five. After the age of fifty-five, unlike the other genital organs which undergo more or less atrophy, it increases in size, three or four times its normal volume (*hypertrophied prostate*), giving rise to a train of symptoms which follow a gradual obstruction to the vesical outlet. In the normal state the prostate measures about 1¼ in. in length, 1½ in. in breadth, and weighs 6 drams.

Relations.—The *anterior* or *pubic surface* is shorter and less thick than the posterior surface. It is covered by the prostatic muscle, and lies about ¾ in. behind the symphysis pubis, from which it is separated by a plexus of veins (the *plexus of Santorini*).

The *posterior* or *rectal surface* rests directly on the anterior wall of the rectum, being separated only by loose cellular tissue and the fibrous sheath. Because of this cellular interval the gland is easily separated from the anterior surface of the rectum in extirpation of the prostate.

The prostate can be easily palpated by rectal examination, and

prostatic abscess may be opened through the rectum. The distance of the prostate from the anus is about 1½ in. Laterally, the prostate is covered by the aponeurosis of the levator ani muscles, from which it is separated by a plexus of veins.

The *base* or superior surface is in contact with the base of the bladder, being attached to the muscular coat of the wall of the bladder.

FIG. 256.—SHOWING THE STRUCTURES IN THE FLOOR OF THE PROSTATIC URETHRA. *A*, Orifice of the ejaculatory ducts; *B*, verumontanum; *C*, the utricle; *D*, prostatic ducts; *E*, duct of Cowper's gland.

The *apex* is directed downward and is in contact with the deep layer of the triangular ligament. It corresponds to the apex of the *recto-urethral triangle*, just at the point where the rectum bends downward and backward toward the anus.

Internally, the prostate is tunneled by the prostatic urethra, which is situated much nearer the anterior than the posterior surface, and measures about 1¼ in. in length. The floor of the

prostatic urethra contains a number of orifices which are of great clinical importance (Fig. 256):

(*a*) The *orifices of the ejaculatory ducts*—two small orifices situated on the margins of the *verumontanum*, a narrow longitudinal ridge of mucous membrane which occupies the middle of the floor of the urethra. Between the orifices of the ejaculatory ducts is a small blind pouch about ½ in. in length, extending backward under the verumontanum into the substance of the prostate, called the *prostatic utricle*. It is the homologue of the vagina in the female.

(*b*) The *orifices of the prostatic ducts* which carry the prostatic secretion open on each side of the verumontanum in a little furrow called the *prostatic sinus*. It will be observed that the prostatic urethra is a region of great clinical importance because of the many ducts which are open to infection. Thus, a posterior urethritis may invade the prostatic ducts and give rise to prostatic abscess; it may travel along the ejaculatory ducts and infect the seminal vesicles or, further along, produce an epididymitis. Inflammation of the verumontanum may produce stricture or even obliteration of the orifices of the ejaculatory ducts.

The Lateral Lobes.—On the anterior and posterior surfaces of the prostate in the median line is a vertical furrow which indicates the line of division between the two lateral lobes. The prostate is, therefore, a bilobed organ, and the so-called "*middle lobe*" is only a pathologic condition—an enlargement of that portion of the prostate situated behind the urethra, between the orifices of the ejaculatory ducts and the internal orifices of the urethra, where the glandular structure is especially well-developed.

The **structure** of the prostate is musculoglandular; *i. e.*, it is a glandular organ with a muscular stroma. It contains forty or fifty glands of the tubular variety, the ducts from which unite to form fifteen to twenty larger ducts, which open into the prostatic urethra on the sides of the verumontanum.

Vessels.—The **arteries** of the prostate are derived from the inferior vesical, the middle hemorrhoidal, and the internal pudic. They are small and have no surgical significance.

The **veins** are very numerous and important. They form a plexus which lies chiefly on the anterior and lateral aspect of the prostate, between the fibrous sheath and the true capsule (see page 487). They communicate with the veins of the urethra, the veins of the bladder, and the hemorrhoidal

veins. Testut observes that simple congestion of these veins may give rise to dysuria or even retention of urine. Wounding these veins during the course of an operation may produce serious hemorrhage or infective thrombophlebitis. These accidents are best avoided in prostatectomy by performing a subcapsular enucleation of the gland.

The **lymphatics** of the prostate are both intraglandular and periglandular. They form a rich network about the gland and their collecting trunks pass to the external and internal iliac glands. A few trunks are received by the sacral glands. On the posterior surface of the prostate are two or three lymphatic glands which play an important part in the pathology of periprostatic abscess.

The **nerves** of the prostate are derived from the hypogastric plexus of the sympathetic.

Clinical Considerations.—The ease with which the prostate may be examined by the rectal touch, and its form and consistency noted, has already been alluded to.

Abscess of the prostate is usually secondary to gonorrhea, the infection being conveyed along the prostatic ducts to the substance of the gland. Prostatic abscess may burrow into the pelvic cellular tissue and become diffused, or it may discharge into the urethra or rectum, or both. In the latter case a *urethrorectal* fistula is established which heals with difficulty.

Hypertrophied Prostate.—While true tumors, such as myomata, adenomata, and cancer, are found at times in the prostate, the most frequent affection of the prostate is a general glandular enlargement, which usually occurs after the age of fifty-five, and is known as hypertrophied prostate. So common is this affection in the latter part of life that it is recognized as the infirmity of old men.

The Anatomic Effects of Enlarged Prostate.—In this connection recall the relations of the prostate at the base of the bladder and the fact that it is tunneled by the urethra from base to apex.

(*a*) *Increase in the Length of the Prostatic Urethra.*—As the prostate enlarges, the urethra elongates and may reach two or three times its normal length; hence, the need of a longer catheter to enter the bladder when the prostate is enlarged.

(*b*) *Change in the Direction of the Urethra.*—The vesical orifice is raised so that the outlet is no longer at the most dependent part of the bladder. The prostatic urethra may be elevated in the center so that its anterior and posterior seg-

ments form a right angle. If there is an unequal enlargement of the two lateral lobes there may be a lateral deviation of the urethra. If an enlargement exists just back of the vesical orifice a Y-shaped channel may be produced (Deaver). All these changes in the direction of the urethra suggest the necessity for special catheters in reaching the prostatic bladder and the special manipulation which they require.

(*c*) *Effects on Micturition.*—The gradual obstruction of the vesical outlet first leads to *difficulty of urination*, which must naturally lead to hypertrophy of the bladder in its extra effort required to counteract the obstruction; later atrophy and dilatation follow, resulting in feeble power of expulsion, so that the last portion of the urine is voided in driblets. In the event of a pedunculated enlargement of the "middle lobe" an obstruction is formed at the vesical outlet which acts like a ball-valve; the greater the effort to urinate, the tighter is the outlet closed; passing a catheter is the only means of relief in these conditions.

Frequency of urination is the result of congestion at the neck of the bladder or a secondary cystitis. These changes produce reflex disturbances in the kidneys which increase the quantity of urine, and thus, as Deaver observes, a vicious circle is established.

Access to the prostate may be obtained by three routes:

(*a*) *The Suprapubic Route.*—By means of a suprapubic cystotomy the bladder is opened and the prostate reached through an incision in the mucous membrane at the neck of the bladder.

(*b*) *The Perineal Route.*—Through a perineal incision in front of the anus traversing the recto-urethral triangle, the apex of which is formed by the apex of the prostate (see pages 472 to 488). The manifest advantages of this route in the accessibility of the prostate, the avoidance of an extensive wound of the floor of the bladder, and the excellent drainage which it affords, render it the route of choice in total extirpation of the prostate.

(*c*) The *rectal route* is used only in opening prostatic and periprostatic abscesses.

THE SEMINAL VESICLES AND DUCTS

In studying the seminal vesicles and ducts note their analogy to the gall-bladder and ducts—the vas deferens carries the secretion from the testicle and the semen is stored in the seminal

vesicles as the bile in the gall-bladder; the seminal vesicles terminate in a narrow duct (the excretory duct) which joins the vas deferens to form the ejaculatory duct, not unlike the common bile-duct. The semen is finally deposited in the prostatic urethra, which again corresponds to the deposition of bile in the duodenum.

The **seminal vesicles** are two musculomembranous reservoirs situated between the base of the bladder and the rectum (Fig. 257). Their function is to collect the semen and add to its bulk before it is projected in the act of ejaculation. The seminal vesicles are pear-shaped organs; their bases, about ½ in. in width, are above and separated by an interval; their lower ends are narrow and converge to join the vasa deferentia, opposite the base of the prostate. They are about 2½ in. in length and ¼ in. in thickness. In front they are in

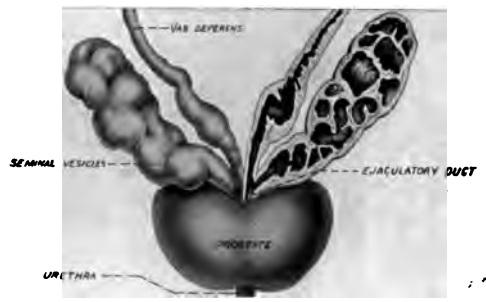

Fig. 257.—The Seminal Vesicles and Ducts.

contact with the base of the bladder, being separated above by the terminal portion of the ureters; behind is the anterior surface of the rectum with the intervening rectovesical fascia; below they meet at the base of the prostate; on the inner side of each seminal vesicle runs the enlarged and convoluted vas deferens. Above, the rectovesical fold of peritoneum (cul-de-sac of Douglas) descends and partially invests their bases. The seminal vesicles are invested by a fibrous sheath, derived from the rectovesical fascia, from which they may be readily shelled out.

The **intervesicular triangle** is formed by the converging vasa deferentia and seminal vesicles, and represents the triangular area of the bladder in contact with the rectum. It also corresponds to the vesical trigone (see Fig. 252).

The **vas deferens** is the excretory duct of the testicle,

characterized by its thick walls and small caliber. It is about 2 ft. in length and extends from the globus minor to the base of the prostate, where it joins the excretory duct of the seminal vesicle to form the ejaculatory duct.

Its Course.—From the epididymis it ascends along the back of the spermatic cord to the external ring, through the inguinal canal and internal ring. It curves around the deep epigastric vessels, crosses the external iliac vessels, and descends into the pelvis on the side of the bladder. It passes between the bladder and terminal portion of the ureter, runs along the inner side of the seminal vesicles, where it becomes dilated and forms the ampulla; at the base of the prostate it unites with the seminal duct to form the ejaculatory duct.

The **ejaculatory ducts** are the two common ducts formed at the base of the prostate by the junction of the seminal duct and the vas deferens. They are about ¾ in. in length, run forward in the substance of the prostate, and open separately in the prostatic urethra on the verumontanum at the lateral margin of the prostatic utricle.

Clinical Considerations.—The seminal vesicles are accessible to the rectal touch; hence by this route massage or "milking" of the ducts is performed. The seminal vesicles are infected from neighboring parts of the genito-urinary tract; gonorrheal vesiculitis may terminate in abscess, or tubercular infection may be secondary to tuberculosis of the testes, the infection traveling along the vas deferens.

The relations of the base of the seminal vesicles with the rectovesical fold of peritoneum explains the invasion of the peritoneum which sometimes follows gonorrheal vesiculitis, tuberculosis, and cancer.

Access to the seminal vesicles may be had through the perineal route by traversing the recto-urethral triangle. They are readily shelled out of their fibrous capsule. The intimate relation of the ejaculatory ducts with the prostate and prostatic urethra explains their loss of function in diseases of the prostate, and the strictures and obliteration of their orifices in posterior urethritis.

THE UTERUS

The **uterus** is a hollow muscular organ destined to receive the fecundated ovum, nourish it during development, and expel it at the time of parturition. It is situated in the cavity of the pelvis and suspended between the folds of the broad

ligament. It lies above and at right angles to the vagina, behind the bladder, and in front of the rectum (Fig. 258). Note, therefore, that the uterus is essentially mobile, and that it is situated between two organs which alternately distend and contract; hence, while the position of the uterus is relatively the same, it actually varies with the state of the bladder and rectum.

FIG. 258.—MESIAL SECTION OF THE FEMALE PELVIS, SHOWING THE RELATION OF THE VISCERA.

Its **form** is that of a pear flattened anteroposteriorly; the base above, the apex below and inserted into the superior wall of the vagina. At the junction of its middle and lower thirds is a constriction, the *isthmus,* which divides the uterus into two parts, the *triangular body* and the *cylindric neck* (cervix uteri). These two divisions must be kept distinctly in mind, since they differ in function and pathology.

Its **size** varies according to age and physiologic conditions.

The multiparous adult uterus is about 3 in. long, 2 in. wide at its upper part, and 1 in. in thickness. It weighs about 1½ oz. The uterus is always larger during menstruation.

The **relations of the body and the neck** vary greatly according to age. In young children the cervix is larger than the body; in the adult virgin the cervix and body are about equal; and in the multipara the body is about twice the size of the cervix.

Its Position.—The normal position of the uterus is difficult to define because the uterus is a very mobile organ, and its direction varies with the position of the individual and with the state of the bladder and rectum; therefore, the uterus has no fixed position. However, independent of the deviations

FIG. 259.—NORMAL POSITION OF THE UTERUS.
White outline, anteversion; black outline, retroversion.

which follow an empty or distended bladder, the uterus is normally maintained by its ligaments in a position of equilibrium, and this position is one of anteversion; that is, the uterus lies on the posterior surface of the bladder, its axis at nearly a right angle with the axis of the vagina (Fig. 259). Again, note that the longitudinal axis of the body and the cervix are not normally in the same straight line, the body is flexed on the cervix, forming a slight angle, open in front—anteflexion. *Hence, the normal position of the uterus is one of anteversion and slight anteflexion.* Distinctions between versions and flexions should be well-defined to comprehend their mechanical effects. Thus, in versions the body and cervix do not change their relation; the organ makes a see-saw movement; when the body is carried backward the cervix is carried forward; as the

uterus is anteverted or retroverted the cervix lies toward the rectum or toward the symphysis (see Fig. 259). In flexions the body is bent on the cervix; in anteflexion the body inclines toward the bladder; and in retroflexion the body inclines toward the rectum. It is well to note that while the uterus is normally subject to various deviations; it is when the temporary deviation becomes fixed that a displacement is established which affects both function and relation. These displacements play an important rôle in the pathology of the female pelvis, and their practical application will be further noted when the relations of the uterus to the surrounding viscera are studied.

Means of Fixation.—Although the uterus is very mobile, it is held within certain physiologic limits and maintained in position by—

(*a*) The broad ligaments, which are attached to the sides of the pelvis and suspend the uterus in the pelvic cavity like a hammock.

(*b*) The round ligaments, attached in front, maintain it in normal anteversion and oppose posterior or lateral displacements.

(*c*) The uterosacral ligaments, fixed behind to the sacrum and in front to the cervix, steady the cervix and prevent prolapsus.

In addition to the ligaments the uterus receives support from the vessels which surround it, and from the perineal floor.

When the uterus becomes pregnant the ligaments are gradually lengthened to accommodate themselves to the new conditions. After childbirth the ligaments gradually contract to re-establish the normal relations. The relaxation of the ligaments after childbirth is the frequent cause of displacements and prolapsus, and accentuates the danger of allowing women to get up too soon after labor.

Relations.—*Anteriorly*, the upper three-fourths of the uterus, above the level of the cervix, is covered by peritoneum and is in relation with the posterior surface of the bladder, from which it is separated by the uterovesical pouch of peritoneum. The lower fourth is deprived of peritoneum and is separated from the posterior surface of the bladder by a layer of connective-tissue (see Fig. 258). This intimate relation of the uterus with the bladder explains the effect of forward displacements of the uterus in producing vesical irritation (dysuria, polyuria, etc.).

Posteriorly, the uterus is more convex than the anterior surface, and is covered by peritoneum its entire length. It

corresponds to the anterior surface of the rectum, from which it is separated by a fold of peritoneum—the *cul-de-sac of Douglas.* Note in this relation that the cul-de-sac of Douglas covers also the posterior surface of the cervix and the upper posterior surface of the vagina (see Fig. 258). This relation is important, since it permits examination of uterine conditions by means of the rectal touch—a convenient method to use in examining virgins, in whom the hymen forms an impediment.

In retrodisplacements of the uterus pressure on the rectum may cause constipation, and the compression of uterine fibroids has caused intestinal obstruction.

The cul-de-sac of Douglas is the pathologic pouch of the female pelvis. The position of the ovaries and tubes suspended within this pocket, the numerous inflammatory lesions to which they are subject, and the rupture of a tubal pregnancy are the frequent causes of purulent and sanguineous collections within this pouch easily recognized by vaginal examination and often amenable to operative treatment through the posterior vaginal wall.

Laterally, the uterine borders are slightly concave and correspond to the line of attachment of the peritoneal folds forming the broad ligaments. They are traversed in their entire extent by the uterine artery and the accompanying veins.

Superiorly, the fundus of the uterus is convex and covered by peritoneum. At its two extremities, where it is continuous with the lateral border, are the angles of the uterus, to which the Fallopian tubes are attached. It is in relation with the coils of small intestine and the sigmoid flexure.

The Cervix.—The neck or cervix uteri is the lower constricted portion of the uterus; around its circumference, at the junction of its middle with its lower third, is inserted the vagina, dividing it into two segments, the supravaginal portion and the vaginal portion. Note the peculiar formation of the cervix and vaginal junction. The cervix is inserted into the upper anterior wall of the vagina, at right angles to its axis, so that the lower extremity of the cervix is in direct contact with the posterior vaginal wall (Fig. 260).

The **supravaginal portion** is in contact with the base of the bladder, from which it is separated by cellular tissue. The walls between the two cavities are not very thick, and *vesico-uterine fistula* sometimes occurs as the result of parturition. Posteriorly, it is covered by the anterior fold of Douglas' pouch, which separates it from the rectum.

On the sides it sustains a most important relation with the uterine artery and veins and the terminal portion of the ureter. *The ureter is separated from the supravaginal portion of the*

FIG. 260.—SHOWING THE RELATION OF THE CERVIX TO THE VAGINA.

cervix by a distance of $\frac{3}{4}$ *in., and is crossed in front by the uterine artery* (Fig. 261). The danger of wounding the ureter in removing the uterus or cervix is evident.

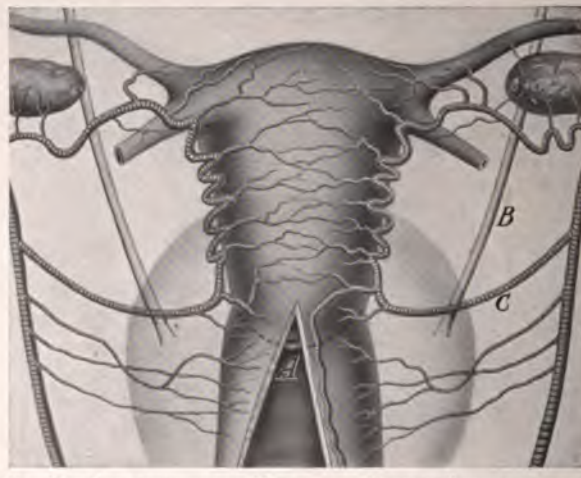

FIG. 261.—THE RELATIONS OF THE URETER AND UTERINE ARTERY TO THE CERVIX. Bladder in front represented by shadow outline. *A*, Cervix; *B*, ureter; *C*, uterine artery.

The **vaginal portion** of the cervix is the part which projects into the vagina and can be seen through the speculum and felt by vaginal examination. It is a cone-shaped body, at the extremity of which is a small aperture, the *external os*, or external mouth of the womb. In the virgin the external os is

nearly circular; in women who have borne children it is larger, irregular, and in the form of a transverse slit. The external os divides the vaginal portion of the cervix into two lips, a lower or *anterior lip*, and an upper or *posterior lip*, which is longer, owing to the higher attachment of the vaginal wall behind.

Owing to the fact that the axis of the uterus is at right angles to that of the vagina, the external os rests against the posterior

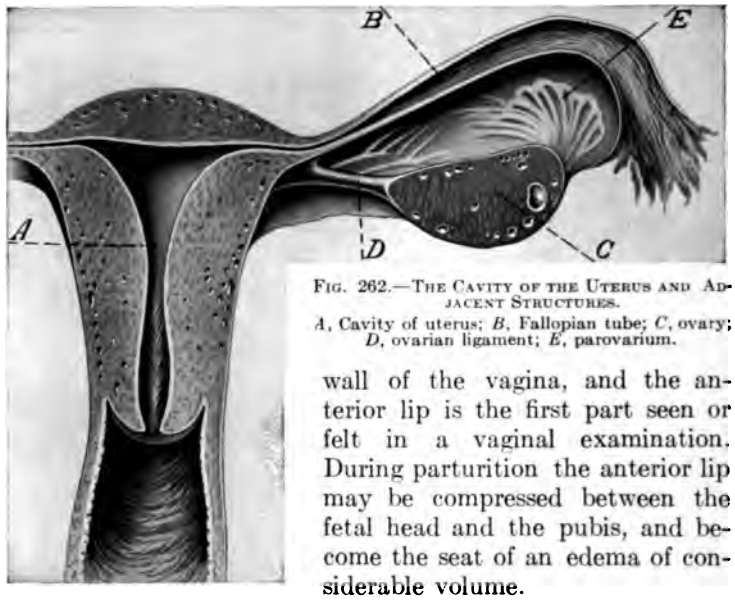

FIG. 262.—THE CAVITY OF THE UTERUS AND ADJACENT STRUCTURES.
A, Cavity of uterus; *B*, Fallopian tube; *C*, ovary; *D*, ovarian ligament; *E*, parovarium.

wall of the vagina, and the anterior lip is the first part seen or felt in a vaginal examination. During parturition the anterior lip may be compressed between the fetal head and the pubis, and become the seat of an edema of considerable volume.

The cervix is also prone to lacerations during parturition. They may be unilateral, bilateral, or stellate. They play an important rôle in the pathology of uterine inflammations and in the development of cervical cancer.

Atresia of the cervix may be congenital or cicatricial; the result of injuries, operations, or the application of caustics. Whatever the cause, retention of the menstrual fluid results, favoring the extension of uterine inflammation to the tubes and ovaries, and necessitating a dilatation of the cervical canal.

The **cavity of the uterus** averages about 2½ in. in length and may be divided into two portions:

(*a*) The *cavity of the body*, triangular in form, the base being above, the apex below. At each angle of the triangle is an orifice; superiorly, the orifices of the Fallopian tubes; inferiorly, the orifice of the *internal os* (Fig. 262).

(*b*) The *cavity of the cervix* is fusiform, with a retracted orifice at each end. The upper orifice (the internal os) opens into the cavity of the body, the lower orifice (external os) opens into the vagina. The walls of the cavity present longitudinal folds of mucous membrane from which secondary folds extend obliquely, giving it the appearance of branches of a tree; hence, the name *arbor vitæ* has been applied to it.

The Wall of the Uterus.—Omitting the peritoneal coat, which has been described elsewhere, the wall of the uterus is essentially composed of two coats, a muscular and a mucous.

The **muscular coat** is the thicker, and consists of crossed fibers of three kinds. The superficial longitudinal fibers occupy the anterior and posterior surfaces of the uterus and send prolongations to the uterine ligaments and Fallopian tubes.

The middle layer is the thickest of the three and forms an inextricable network of longitudinal and transverse fibers. Some of the fibers form sphincters at the orifices of the Fallopian tubes and at the os internum. The deep layer consists of longitudinal fibers mingled with connective-tissue and elastic fibers. The muscular tissue of the uterus forms nearly the entire thickness of the uterine wall. During gestation it undergoes hypertrophy, and by its contraction expels the fetus.

In this tissue develop the most common benign neoplasms of the uterus—*fibromyomata*. These tumors tend to assume large proportions, and may cause grave symptoms by pressure on neighboring organs or by degeneration.

The **mucous coat** lines the entire cavity of the uterus, continuous above with the mucosa of the Fallopian tubes and below with that of the vagina. The body of the uterus is lined with columnar ciliated epithelium and is intimately connected with the deep layer of the muscular coat. At the external os the character of the epithelium changes to the squamous type, which continues in the vagina. *Hence, cancer of the cervix differs in type and tendency according as it arises from the external or internal surface of the cervix; the first rarely, the second invariably, invades the body.*

Note the continuity of the uterine mucosa with the Fallopian tubes above and the vagina below—it explains the ravages of vaginal infection (gonorrheal) upon the tubes and ovaries. The uterine mucosa contains a number of tubular glands, especially abundant in the cervical canal, where they sometimes become cystic and are then called the *ovules of Naboth*.

In *endometritis* these glands become enlarged, the secretion

increases, and *leukorrhea* results. They are nearly always the starting-point in cancer of the uterus.

Vessels.—The blood supply of the uterus is derived from the *uterine* artery, a branch of the internal iliac, and the *ovarian*, from the abdominal aorta. Note in this connection the tortuous course of the uterine vessels and the remarkable vascular circle which they form (Fig. 263).

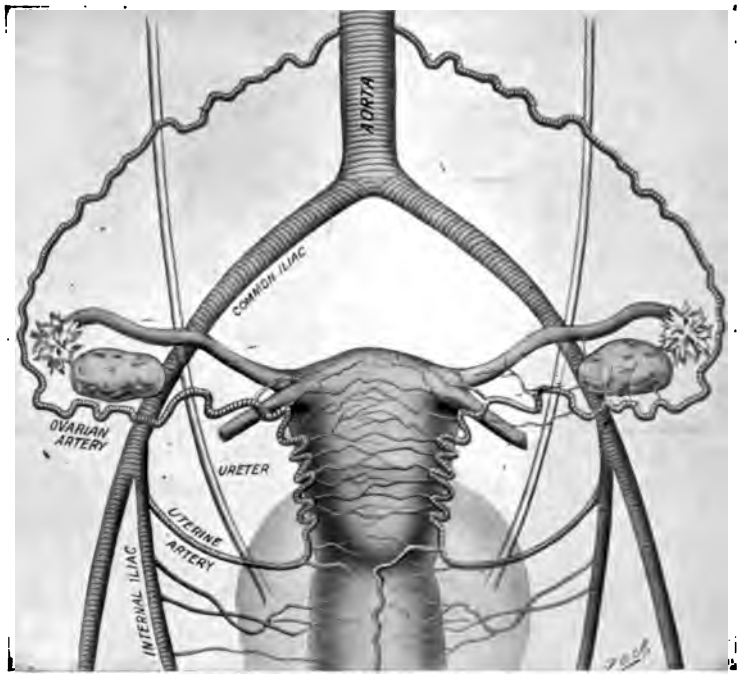

FIG. 263.—THE UTERO-OVARIAN VASCULAR CIRCLE. (After Robinson.) Shadow outline of bladder in front.

The uterine artery reaches the uterus at a point opposite the supravaginal portion of the cervix and *crosses in front of the ureter at a distance of ¾ in. from the cervix.* It then bends upward and runs close beside the body of the uterus, between the folds of the broad ligament, giving off a number of branches which supply the uterine wall, and at the angle of the uterus anastomoses with the ovarian artery. The spiral course of the uterine artery is for the evident purpose of allowing for the increased size of the uterus during pregnancy without causing tension of the vessels.

The **veins** of the uterus take their origin in the venules of the mucosa and muscularis. The branches which traverse the muscularis are by far the most important. In the pregnant uterus they undergo enormous development and form the *uterine sinuses*. When the placenta is expelled these venous

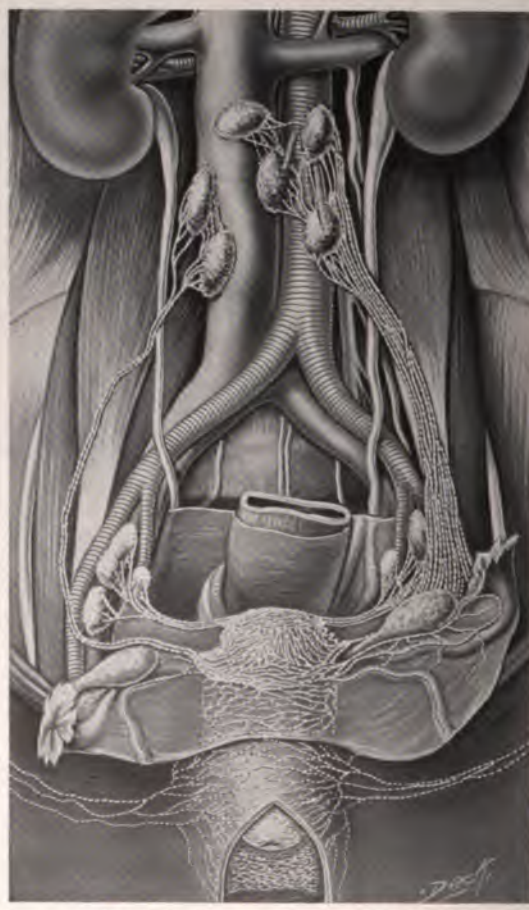

FIG. 264.—LYMPHATICS OF THE UTERUS.

sinuses are opened and hemorrhage follows. Contraction of the muscular fibers closes the bleeding vessels and, as Testut observes, plays the rôle of "living ligatures."

Observe, therefore, the importance of uterine contraction after labor, and the danger of fatal hemorrhage following uterine

inertia. The uterine veins terminate in the venous plexuses of the broad ligament and anastomose with those surrounding the base of the bladder, the vagina, and rectum; hence the effect of uterine congestion on neighboring organs, the possible wide-spread thrombophlebitis following septic infection (puerperal septicemia), the extension to the internal iliac and common iliac veins obstructing the venous return from the lower limb and causing edema of the extremity—*phlegmasia alba dolens*, or "milk-leg."

The **lymphatics** originate in the three coats of the uterine wall, but more especially in the muscularis, where they are most abundant. They terminate in collecting trunks, which are formed into three groups (Fig. 264):

(*a*) The superior group drain the body of the uterus, follow the course of the ovarian vessels, and terminate in the lumbar glands of the corresponding side.

(*b*) The middle group accompany the vessels of the round ligament and terminate either in the external iliac glands or enter the inguinal canal and terminate in the inguinal glands.

(*c*) The inferior group drain the cervix and vagina and terminate in the internal iliac and sacral glands.

Thus it will be observed that the lymphatics of the uterus follow the course of the vessels and by their anastomoses form a complete lymphatic ring about the body and cervix. The importance of the lymphatics in spreading infection and in the extension of uterine cancer is obvious.

The **nerves** of the uterus are derived from the third and fourth sacral, and sympathetic branches from the hypogastric and the renal plexuses. It will thus be seen that the innervation of the uterus is intimately connected with that of the abdominal viscera, the kidneys, and the neighboring pelvic organs, and explains the various reflexes which occur in conjunction with uterine affections in the kidneys, stomach, and intestine. Note that the cervix is poorly supplied with nerves, so that it may be manipulated without causing much pain.

Malformations of the uterus, so frequently observed, are due to the arrest of development of the *ducts of Müller*. The uterus and vagina are formed by the fusion of the lower extremities of these ducts; the upper portions of the ducts preserve their independence and form the two Fallopian tubes. If the fusion between the Müllerian ducts is incomplete, there may result a double uterus and vagina or a double uterus and

normal vagina. The effect of pregnancy in the malformed uterus is a condition of much interest.

Clinical Considerations.—The interesting phase of uterine displacements in their effect upon neighboring organs has already been described. One other displacement should be noted, because of the anatomic and mechanical factors involved, viz.:

Prolapse of the uterus, due to two mechanical causes—

(*a*) Relaxation of the uterine supports—the ligaments and the perineal floor. The equilibrium between the intra-abdominal pressure and the mechanical supports is lost, and the uterus gradually sinks to a lower level in the pelvic cavity.

(*b*) Change in the relation of the axis of the uterus with that of the vagina. Normally, they are at right angles; in this position prolapsus never occurs. The uterus must be retroverted so that the axis of the uterus and vagina are in the same straight line before the first cause can act effectually.

These predisposing conditions are most likely to exist immediately after parturition, before the parts have regained their normal tonicity or the uterus has resumed its normal position. In extreme prolapse the uterus may emerge from the vulva and form a mass between the thighs, the vaginal wall being turned completely inside out.

Tumors.—The most frequent benign tumor of the uterus is the *fibromyoma* (uterine fibroid). Its tendency to assume large proportions, compress neighboring organs, incite uterine hemorrhage, elaborate toxic products, and in some instances to undergo degeneration, render these neoplasms exceedingly dangerous if allowed to persist.

Cancer of the uterus is one of the most common forms of malignant disease. It most frequently originates in the cervix, either externally, in the squamous epithelium, or internally, in the tubular glands. It sooner or later invades the vagina, bladder, rectum, and ureters. It spreads to distant parts by the uterine lymphatics and may be carried by the blood stream to the heart and lungs. Its insidious onset is its most dangerous characteristic.

Means of Access.—The uterus may be reached for operation either by the abdominal or vaginal route. Through the vagina the uterus may be cureted, the cervix repaired or amputated, and the entire uterus extirpated. The vaginal route for complete hysterectomy is less desirable than the abdominal route, because of the evident narrow space and the incomplete

exposure of the important structures which this procedure involves. The abdominal route is especially indicated in extirpation of the uterus, because the exposure insures ample room and the important structures are in sight.

The uterus is removed by detaching it from its connections with the broad ligaments, the bladder, and vagina; most important of all to remember are the relations of the uterine and ovarian vessels and the ureters (see pages 498 and 501).

The **broad ligaments** (Fig. 265) are two folds of peritoneum which suspend the uterus from the lateral walls of the pelvic cavity and form for the uterus its *vascular pedicle.* They are quadrilateral in form and vertical in direction, and form a partition across the pelvis, which divides it into two compartments.

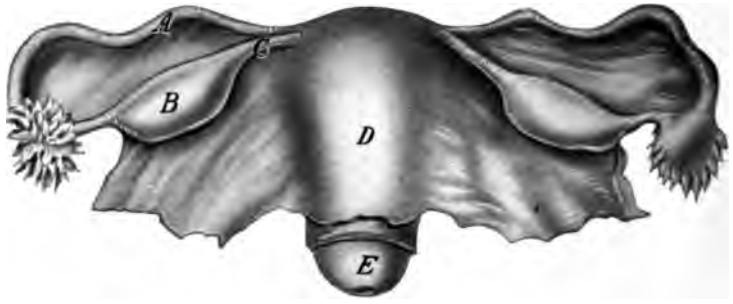

FIG. 265.—THE BROAD LIGAMENT AND CONTENTS. (POSTERIOR VIEW.)
A, Fallopian tube; *B*, ovary; *C*, ovarian ligament; *D*, uterus; *E*, cervix.

The anterior part contains the bladder, urethra, and vagina; the posterior part the rectum.

The two layers of the broad ligament separate to enclose the uterus, and are reflected from its sides to the lateral wall and floor of the pelvis, where they become continuous with the parietal peritoneum.

Contents.—Between the layers of each broad ligament are: the Fallopian tube, the ovary and its ligaments, the round ligament, the parovarium or organ of Rosenmüller, the duct of Gärtner, the hydatid of Morgagni, the uterine and ovarian vessels, nerves, and lymphatics; unstriped muscular fibers, and a variable amount of loose connective tissue, which is termed *parametrium.*

Relations.—Its anterior surface overlies the bladder and is marked by the prominent ridge of the round ligament; its posterior surface is in contact with the coils of intestine and

gives off a special ligament, the *mesovarium*, to enclose the ovary.

The *superior* or *tubal border* is entirely free and enfolds the Fallopian tube; this fold is termed the *mesosalpinx*.

The *inferior* or *rectovesical border* is attached to the floor of the pelvis and separated from the rectovesical fascia and the levator ani muscle by loose connective tissue, within which are contained the uterine vessels, nerves, and ureter.

The *internal* or *uterine border* is in relation with the sides of the uterus and upper part of the vagina. Lying between its folds is the anastomotic loop between the uterine and ovarian arteries and the uterine plexus of veins.

The *external* or *obturator border* consists of two portions, the lower attached portion is in contact with the obturator fascia, and transmits the uterine artery and round ligament; the upper free portion forms a concave, rounded margin connecting the fimbriated extremity of the Fallopian tube with the side of the pelvis. It is called the *infundibulopelvic ligament*, and transmits the ovarian vessels.

Clinical Considerations.—It will be noted that the broad ligament contains muscular fibers continuous with the superficial fibers of the uterus, which give it a certain tonicity and enable it to maintain the uterus in position. In these muscular fibers originate the *fibromyomata of the broad ligament;* when the pregnant uterus enlarges it fills the space between the two layers of these ligaments, so that for the time they are obliterated; after labor they are relaxed and feebly oppose displacements and prolapse; hence, the necessity for allowing proper time for their restitution before the patient is allowed to get up.

The *broad ligaments* contain a large number of lymphatics, which drain the uterus and vagina, and the cellular tissue is especially abundant at the base; hence, *abscess of the broad ligament* is liable to follow puerperal sepsis or septic operations on the genital organs. The relations of the broad ligament and the continuity of its cellular tissue with that of the neighboring structures explain the tendency of these abscesses to open either into the vagina, rectum, or bladder; disseminate into the ischiorectal fossa, through the great sacrosciatic foramen, into the buttock; or extend to the abdominal wall and iliac fossæ.

The **round ligaments** are two musculofibrous cords, 5 in. in length, which extend from the upper angles of the uterus, a little below the Fallopian tubes, to the vulva (Fig. 266).

They pass obliquely downward and outward toward the base of the broad ligament, thence outward and forward over the pelvic brim to the internal abdominal ring; they traverse the entire extent of the inguinal canal and after leaving the external ring expand into a number of filaments, which terminate at the base of the labia majora.

In its course through the inguinal canal it is accompanied by a diverticulum of peritoneum, the *canal of Nuck*, which corresponds to the processus vaginalis in the male. If this process remains patulous it predisposes to inguinal hernia or the formation of a cyst. The round ligament is accompanied by the *funicular artery*, a branch of the superior vesical.

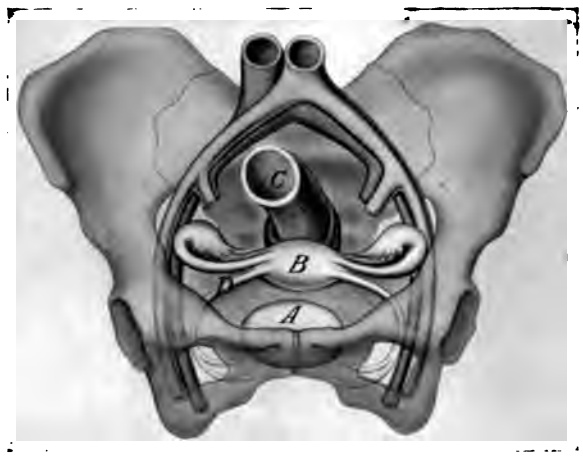

FIG. 266.—THE RELATION OF THE PELVIC VISCERA AND THE POSITION OF THE ROUND LIGAMENTS.
A, Bladder; *B*, uterus; *C*, rectum; *D*, round ligament.

Clinical Considerations.—The round ligaments are important factors in holding the uterus in its normal position of anteversion; when they become relaxed, backward displacements of the uterus may result; hence these ligaments have assumed a rôle of practical importance, because of the numerous operations which involve their shortening for the correction of backward displacements.

Means of Access.—The round ligaments may be found by opening the inguinal canal, where they may be shortened by infolding the slack (Alexander's operation); or after laparotomy they may be exposed on the anterior surface of the uterus and broad ligament.

The **uterosacral ligaments** are two flat, muscular cords which extend from the posterior surface of the neck of the uterus along the lateral surface of the rectum and are fixed to the sides of the third and fourth sacral vertebræ.

These ligaments are fixed solidly to the cervix, and so long as they are not relaxed, prolapsus is impossible, because they are important factors in maintaining the normal rectangular relation between the axis of the uterus and that of the vagina.

THE OVARY

The **ovaries** are two almond-shaped glandular organs, analogous to the testes in the male. They produce the ovules, which are fecundated by the spermatozoids, and an important internal secretion which is necessary to maintain physiologic equilibrium. These two functions must be kept in mind in studying their pathologic phenomena, since the end-results of ovarian disease or extirpation are not only sterility, but a train of nervous and mental disorders.

The ovary is a flattened ovoid 1½ in. long, 1 in. wide, and ½ in. thick. It is suspended by its anterior border from the posterior surface of the broad ligament by a fold of membrane—the *mesovarium.* Its posterior border is free and covered by its investing membrane (see Fig. 265). Its inner or uterine extremity is connected with the uterus by a round cord—the *utero-ovarian ligament*; its outer or tubal extremity is connected with the fimbriated extremity of the Fallopian tube by the ovarian fimbria—the *tubo-ovarian ligament.*

It will thus be observed that the ovary is suspended from the back of the broad ligament, and not only possesses a range of mobility itself, but is attached to neighboring structures which are also mobile; hence, the ovary follows all the movements of the uterus and broad ligaments. When relaxation of these structures occurs, prolapsus of the ovary follows, usually in the cul-de-sac of Douglas; if adhesions are established the ovary becomes permanently anchored in this position. Furthermore, the ovary may be found in the contents of an inguinal or femoral hernia, where it may atrophy from pressure or become inflamed and require removal.

Structure.—The ovary is enveloped by a membrane derived from the posterior layer of the broad ligament, which essentially *differs from peritoneum in being covered by columnar epithelium; thus, the outer membrane of the ovary is mucous, and*

not serous. Beneath the outer membrane is a thin layer formed by a condensation of the ovarian stroma covering the cortex, which contains the Graafian vesicles or ovisacs. Each month the ovum is extruded by the Graafian vesicle, engages in the Fallopian tube, and enters the uterus. Ovulation corresponds to the period of fecundity in women, and is accompanied by the phenomena of *menstruation.*

Vessels.—The **arteries** are the ovarian branches of the abdominal aorta, which enter the pelvis in a fold of the broad ligament, and thence continue to the attached border or hilum of the ovary. Note the anastomosis with the uterine artery (see Fig. 263).

The **veins** form a plexus near the ovary (*pampiniform plexus*) and empty into the ovarian vein, which in turn empties into the renal vein on the left side and into the inferior vena cava on the right. Note the analogy to the spermatic veins in the male.

The **lymphatics** of the ovary anastomose with trunks from the uterus and Fallopian tube and terminate in the lumbar glands.

The **nerves** are derived from the ovarian plexus, a continuation of the renal plexus. In the normal state the female pelvic organs are not acutely sensitive, except the ovary, which, like the testicle, possesses a sensibility especially characteristic.

The **parovarium** or **organ of Rosenmüller** is situated in the mesosalpinx, between the Fallopian tube and the ovary. It is composed of from fourteen to twenty parallel closed tubes which join at right angles a single longitudinal duct (the *duct of Gärtner* (see Fig. 262). They are homologous to the epididymis in the male.

Clinical Considerations.—The ovary may be palpated by means of a bimanual examination. With two fingers introduced into the vagina and directed toward the cul-de-sac on the side corresponding to the ovary to be explored, the abdominal wall is depressed with the free hand in the median line just above the symphysis pubis, and an effort is made to approximate the finger-tips of the two hands below the level of the pelvic brim. The ovary is felt as a rounded mass slipping between the fingers. This procedure is most successful in multiparæ, in whom the parts are relaxed and the ovaries lie at a lower level. The relations which the ovary sustains with the rectum suggest that a more satisfactory examination may be made by rectal than by vaginal palpation.

Ovarian Tumors.—The greater number of ovarian tumors

are of the cystic variety. *Ovarian cysts* develop for the most part from the Graafian follicles and may be unilocular or, more frequently, multilocular. They may acquire an enormous size, and in some instances are attached by a long pedicle, which may become twisted and produce acute symptoms.

Dermoid cysts, which are more rare and less voluminous than the true ovarian cysts, are peculiar, inasmuch as they contain sebaceous material in which are found hair, teeth, bone, and even rudimentary mammæ (Taylor).

Parovarian cysts grow much slower than ovarian cysts. They do not present a pedicle, but are enveloped on all sides by the two layers of the broad ligament (intraligamentous cysts); hence their enucleation is difficult.

Means of Access.—The extirpation of the ovary is best accomplished through an abdominal incision; the fundus of the uterus being found, the upper border of the broad ligament is traced outward, behind which is suspended the ovary, recognized by its form and consistency.

THE FALLOPIAN TUBES

The **Fallopian tubes** convey the ovum from the ovaries to the uterine cavity. They are about 4½ in. in length, situated in the upper margin of the broad ligament, and extend from the superior angles of the uterus to the ovaries (see Fig. 265). Each tube consists of an *isthmus*, the constricted inner third which passes horizontally outward from the superior angles of the uterus, and the *ampulla*, or outer dilated portion, which arches backward over the ovary and ends in a funnel-shaped *fimbriated extremity* opposite the outer pole of the ovary, with which it is connected by the ovarian fimbria or tubo-ovarian ligament. The tube is enveloped by the peritoneum of the broad ligament, which forms its mesentery—the *meso-salpinx*. At the inner extremity of the tube the orifice is 1 mm. in diameter; at its outer extremity it is from 4 to 6 mm. in diameter. Thus the diameter of the tube increases from its internal to its external extremity. Ordinarily, the fecundated ovum passes along the entire extent of the tubular canal and develops in the uterine cavity. Occasionally, however, the progress of the ovum is arrested in the tube, where it becomes fixed and develops, constituting a *tubal pregnancy*.

Structure.—The Fallopian tube is composed of three coats. The *serous coat* is derived from the peritoneal layers of the

broad ligament, which incompletely invest the tube, leaving its lower border uncovered, where the two layers diverge. Thus a rupture of the tube at its lower border would not communicate with the peritoneal cavity, but with the cellular tissue between the two layers of the broad ligament.

The *muscular coat* consists of deep circular and superficial longitudinal fibers and gives to the wall of the tube great resistance, so that it may undergo a great amount of dilatation without rupturing. The ruptures which so frequently follow tubal pregnancy are due to degenerative changes which occur in the wall of the tube.

The *mucous coat* is characterized by its longitudinal folds and possesses no glands. It is lined with ciliated epithelium, which assists the ovum in its progress toward the uterus. It is continuous on one side with the cavity of the uterus, on the other it communicates with the peritoneal cavity. *Thus, the Fallopian tube forms a direct passageway from the external genitals to the peritoneal cavity.* The importance of this anatomic continuity from a pathologic standpoint is obvious.

Vessels and Nerves.—The blood supply of the Fallopian tubes is derived from branches of the ovarian arteries which run along its lower border in the folds of the mesosalpinx. The veins communicate with the venous plexus of the broad ligament.

The *lymphatics* communicate with those of the ovary and terminate in the lumbar glands.

The *nerves* are derived from the sympathetic fibers of the pelvic plexus.

Clinical Considerations.—The pathology of the Fallopian tubes is explained by their direct communication with the external genitals and the abdominal cavity. Infection, especially gonorrheal, travels from the genitals to the tubes, and inflammation results (*salpingitis*); adhesive inflammation seals up the abdominal opening of the tube, and the products of infection collect and distend it (pus-tube). Occasionally the inflammation reaches the peritoneum, and pelvic peritonitis results. The inflammatory lesions of the tube, in producing adhesions and strictures, play an important rôle in the causation of sterility.

Tubal Pregnancy.—Normally, the ovum becomes fertilized in the tube and passes on to lodge in the uterine cavity. Occasionally it is arrested in its progress and develops in the tube, giving rise to tubal pregnancy. While the tube is able to

accommodate its growing contents up to a certain point, it is finally distended to the point of rupture, and the contents are precipitated either into the peritoneal cavity or, if the tube rupture at its lower border, between the folds of the broad ligament. Ruptured tubal pregnancy is followed by free and ofttimes fatal hemorrhage, unless checked by prompt surgical intervention. Occasionally the fertilized ovum escapes from the tube into the abdominal cavity and, becoming attached to some neighboring structure, proceeds to grow (*abdominal fetation*).

Means of Access.—The Fallopian tube may be palpated by bimanual examination, like the ovary, but the normal tube, owing to its small caliber and soft structure, cannot be recognized.

When a Fallopian tube can be palpated it is pathologic. The Fallopian tube, when distended by the products of inflammation, frequently lies adherent in the pouch of Douglas, so that its contents may be evacuated *per vaginam*, through the posterior cul-de-sac. Extirpation of the Fallopian tube is satisfactorily performed only through an abdominal incision.

THE VAGINA

The **vagina** is a musculomembranous tube, 3½ in. long, which extends from the vulva to the cervix uteri, around which it is solidly attached. It lies between the bladder and the urethra in front, and the rectum behind; the uterus above and the vulva below (see Fig. 258).

The vagina is directed obliquely upward and backward, and forms with the axis of the uterus almost a right angle. This uterovaginal angle, as before noted, is an important factor in preventing prolapse of the uterus. The diameter varies with the individual and the number of pregnancies. It is narrowest at its lower end and widest in the middle. The vagina is capable of great dilatation, especially in the puerperal state, when its limits seem to be circumscribed only by the bony walls of the cavity. In the normal state the anterior and posterior walls are contiguous.

Relations.—The *anterior wall*, in its upper half, is in contact with the bladder, in its lower half with the urethra. These relations suggest the possibility of palpating the bladder through the vaginal wall, and of entering the bladder by this route for the removal of calculus. The dangers of vesicovaginal fistula contra-indicate the latter procedure.

The vaginal and bladder wall are united by cellular tissue, so that the bladder follows the anterior vaginal wall in all its displacements (cystocele). During the course of parturition the anterior vaginal wall may be so compressed against the pubis as to subsequently slough and form a communication with the bladder—*vesicovaginal fistula*; if the opening is high it may communicate with the ureter—*ureterovaginal fistula;* if low, with the urethra, giving a *urethrovaginal fistula.*

The *posterior wall* is in immediate relation with the rectum in its lower three-fourths and by the intervention of Douglas' cul-de-sac in its upper fourth. The upper fourth of the posterior surface of the vagina is covered by peritoneum; hence, an opening in the upper fourth of the posterior vaginal wall enters the cul-de-sac of Douglas, a fact of practical importance either in directly draining collections of fluid in Douglas's pouch or in establishing drainage secondary to an operation by the abdominal route. The rectal and vaginal walls are loosely connected by cellular tissue, so that in vaginal prolapse the rectum is much less frequently involved than the bladder. It will be recalled that the anal segment of the rectum bends backward, so that the lower extremity of the vagina is separated from the anal canal by a triangular interval which constitutes the **perineal body** and is analogous to the urethrorectal triangle in the male. The rectovaginal septum, though not subjected to pressure like the anterior wall, may be torn during parturition, and a *rectovaginal fistula* result.

Laterally, the walls are in contact with the subperitoneal connective tissue, the levator ani muscle, and vaginal plexus of veins; at its lower extremity with the bulbs of the vestibule, the glands of Bartholin, and the bulbocavernosus muscle.

Superiorly, the vagina is inserted into the cervix uteri at the junction of its middle and lower thirds, so as to form an arch about the cervix known as the *fornix,* clinically divided into anterior, posterior, and lateral fornix.

Note the terminations of the ureters. From the side of the cervix they converge, running forward and inward; first beside the lateral fornix, then between the anterior vaginal wall and the base of the bladder, their vesical orifices lying about 1¼ in. below the os uteri.

Structure.—The vaginal wall is composed of three coats: mucous, muscular, and fibrocellular.

The *mucous membrane* is continuous above at the external os with the mucosa of the cervix, below with that of the vulva.

It is adherent to the underlying muscular coat, from which it is separated with difficulty. The vaginal mucosa is remarkable for the number of folds which it presents (*rugæ*). They are transverse in direction, and much more developed in the lower than the upper portion. Along the anterior and posterior walls are two longitudinal folds called the *rugous columns of the vagina*, the anterior column extending as far as the external orifice of the urethra. The epithelium lining the vagina is of the squamous variety. The vaginal mucosa possesses no glands; hence secretions from the vagina are not true glandular secretions, but are the result of exudation and epithelial desquamation (Testut). The secretions of the vagina are normally acid, but in a case of vaginitis they become neutral.

The *muscular coat* is the thickest of the three and is composed of longitudinal and circular fibers. At the lower end of the vagina the muscular fibers thicken and form a muscular ring about the outlet—the *sphincter vaginæ*.

The *fibrocellular coat* is very thin and forms a sort of sheath about the vagina.

Vessels and Nerves.—The vagina is abundantly supplied with blood by branches from the uterine, vesical, vaginal, and internal pudic arteries, all branches of the internal iliac.

The *veins* form a rich plexus on each side of the vagina (*vaginal plexus*), which communicates with the veins of the uterus, bladder, rectum, and broad ligament, finally emptying into the internal iliac vein. Large hematomata following parturition are sometimes formed, resulting from rupture of these veins during delivery.

The *lymphatics* of the vagina anastomose with those of the cervix and those of the vulva, forming the collecting trunks from the upper, middle, and lower third of the vagina, which terminate respectively in the external iliac, the internal iliac, and the lateral sacral lymph-glands.

The *nerves* are derived from the hypogastric and the internal pudic, and form about the vagina the *perivaginal plexus*.

THE FEMALE URETHRA

The **female urethra** is a musculomembranous canal about 1½ in. in length, extending from the neck of the bladder to the vulva, where it opens by an orifice—the *meatus* (see Fig. 258). It practically corresponds to the posterior urethra of the male. Its diameter is about ¼ in., but so great is its elasticity that it

may be dilated sufficiently to allow the introduction of the finger for exploration or removal of a foreign body without causing rupture or incontinence of urine.

Its direction is nearly vertical. There is, perhaps, a slight curve with the concavity forward, but it permits the introduction of a straight instrument without difficulty.

Relations.—The female urethra may be divided into two segments; an intrapelvic segment, extending from the neck of the bladder to the triangular ligament, and a vaginal segment, extending from the triangular ligament to the meatus. In front is a plexus of veins, the *plexus of Santorini;* laterally are the anterior fibers of the levator ani; behind is the anterior vaginal wall from which it is separated above, but with which it is intimately connected below. This latter relation is of practical importance, since by means of vaginal palpation the consistence and sensibility of the urethra may be appreciated. By this means the urethra may be milked and pathologic secretions expressed for examination.

The meatus is the narrowest portion of the urethral canal, situated in the median line, about 1 in. behind the clitoris. *To find the meatus* separate the labia minora and note the tubercle situated at the end of the anterior vaginal raphe; the slit-like orifice of the meatus is immediately in front of the tubercle. It must be remembered that in certain cases of uterine tumor and after prolonged labor, where the vulva is torn and swollen, the meatus is more deeply placed and difficult to locate. A complete exposure of the parts is necessary in all cases where accurate and aseptic catheterization is to be performed.

Structure.—The urethra consists of a muscular, submucous, and mucous coat.

The *muscular coat* is composed of internal longitudinal and external circular fibers. At the neck of the bladder they thicken and form a muscular ring, the internal sphincter of the bladder.

The *submucous coat* consists of loose cellular tissue in which is a network of veins. It gives to the mucosa a certain amount of laxity in its movements on the subjacent muscular coat.

The *mucous coat* presents a number of longitudinal folds lined with transitional epithelium continuous with the squamous epithelium of the bladder and the meatus. It contains a number of mucous glands and follicles.

Skene's glands are situated in the inferior wall of the urethra near the meatus, and open by two ducts to the right and left

of the median line, in the posterior segment of the meatus. They secrete mucus and may occasionally become cystic.

Clinical Considerations.—The great dilatability of the female urethra has already been alluded to, and its practical value emphasized. Because of the wide caliber and short length of the female urethra it is less frequently affected with urethritis, and is less difficult to cure than in the male. The danger of urethritis in the female lies in the fact that it presents no acute symptoms.

In **urethrocele** the mucosa is so loosely attached that it may sometimes prolapse and form a pouch behind the meatus in which urine accumulates and becomes a source of great discomfort.

Urethral caruncle is a small, vascular tumor usually situated at the inferior border of the meatus. They bleed easily, are very painful, and may give rise to secondary symptoms such as spasm of the urethra and retention of urine. They are analogous to hemorrhoidal tumors.

CHAPTER XXIII

THE MALE PERINEUM AND ITS ADNEXA

THE perineum includes the soft parts at the pelvic outlet which are situated below the pelvic diaphragm. Thus, it is a space limited by the pelvic diaphragm above, the skin below, the symphysis pubis in front; the rami of the pubis, the tuberosity of the ischium, the great sacrosciatic ligaments on the side, and the coccyx behind.

FIG. 267.—SHOWING THE LOZENGE-SHAPED SPACE.
A, The urogenital triangle in front and *B*, the rectal triangle behind.

Superficially, the perineal region is indicated by a lozenge-shaped space, the anterior angle situated at the lower border of the symphysis, the posterior angle at the coccyx, and the two lateral angles at the tuberosities of the ischium. A transverse line drawn between the two ischial tuberosities divides it into two triangular areas, the *urogenital triangle* in front and the *rectal triangle* behind (Fig. 267).

The Rectal Triangle.—The central landmark of this area is the anal orifice, on the sides of which are two large cavities

filled with fat—the *ischiorectal fossæ*, separated from each other by the rectum and prostate. They are in the form of a triangular pyramid, with the base below. *Externally*, they are bounded by the tuberosities of the ischium and the bony wall lined by the obturator internus muscle, which is covered by its aponeurosis. *Internally*, by the levator ani and sphincter ani muscles; the *base* is formed by the skin in direct contact with the fat and cellular tissue of the fossa (no intervening aponeurosis); the *apex* corresponds to the point of junction between the aponeurosis of the levator ani and obturator internus muscles, and is situated about 2 in. from the surface.

In addition to the space described above there are two important diverticula connected with the ischiorectal fossæ. The *anterior diverticulum* is represented by a small interval between the fascia of the levator ani and obturator internus muscles, which extends to a point near the superior border of the pubis. The *posterior diverticulum* is situated on either side of the coccyx, between the gluteus maximus and levator ani muscles. These prolongations are of great practical interest in ischiorectal abscess, since pus may burrow either into the anterior perineum or into the buttock.

Contents.—The *ischiorectal fossa* is filled, for the most part, with fat in which are vessels and nerves (Fig. 268). The fat of the ischiorectal fossa has been compared to that of the orbit, inasmuch as it persists even in emaciated subjects and is rapidly destroyed by suppuration, following which it is reproduced very slowly. The most important vessel of this region is the *internal pudic artery*, lying on the outer wall of the fossa with its vein and nerve in a sheath formed by the obturator fascia, *Alcock's canal*, about 1½ in. above the tuberosity of the ischium. *Therefore, in opening an ischiorectal abscess keep away from the outer wall; an incision midway between the ischial tuberosity and the anus is safe.*

The *inferior hemorrhoidal artery* crosses the middle of the fossa transversely, and is distributed to the anus. It is an artery of small caliber, and if wounded is attended by no serious hemorrhage.

The *lymphatics* accompany the vessels and anastomose with those of the anus, rectum, and perineal integument. They are important factors in the formation of ischiorectal abscess.

Ischiorectal abscess is the most frequent lesion of this region. The reasons for this are obvious. Its predominant tissue (fat) has little bacterial resistance; its vessels are not

well-supported by the surrounding tissue, which, with their dependent position, favors congestion; it is in lymphatic communication with bacterial centers—the rectum, anus, and perineal integument. Pus in the ischiorectal fossa, unless evacuated early, follows the line of least resistance and opens spontaneously, either through the skin, through the rectum, or both; in the latter case a fistulous tract remains, the internal

FIG. 268.—SECTION THROUGH THE ISCHIAL TUBEROSITIES, SHOWING (*A*) THE ISCHIORECTAL FOSSA.

opening communicating with the rectum above the sphincter and the external opening in the skin about the anal margin (*fistula in ano*). This condition is rebellious to all treatment save that of complete division of the bridge of tissue between the two openings.

The **urogenital triangle** includes the anterior portion of the perineum. Its base is formed by the transverse line extending between the tuberosities of the ischium, its sides by the

ischiopubic rami; its apex is situated at the symphysis pubis. Thus is formed an equilateral triangle, the sides of which are about 3 in. in length. The floor of this triangle is formed by the *triangular ligament*, which, like a diaphragm, closes in the front part of the pelvic outlet and transmits the urethra. Since the urethra forms the anatomic as well as the clinical center of this region, its course and relations must be well understood before considering the structures which are grouped about it.

The Male Urethra.—The urethra is a musculomembranous canal about 8 in. in length which extends from the neck of the

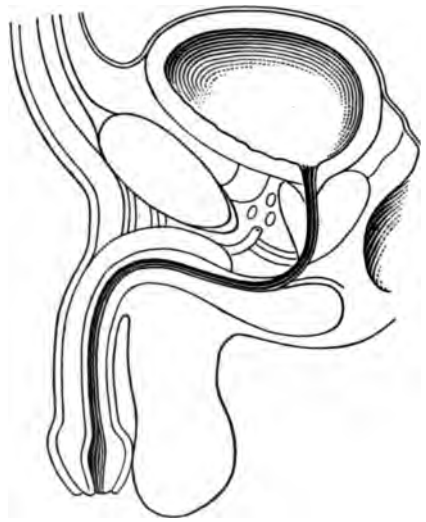

FIG. 269.—THE MALE URETHRA.
Note that in its course it describes a double curve resembling the letter S.

bladder to the meatus urinarius in the glans penis. Its function is two-fold—to convey the urine from the bladder, and the semen from the ejaculatory ducts. Like its function, its pathology is two-fold—urethral affections are complicated by affections of the urinary apparatus (cystitis, etc.) or affections of the genital apparatus (orchitis, etc.).

Its Direction.—The urethra starts at the neck of the bladder (1 in. behind the symphysis) and traverses successively the prostate, triangular ligament, and the penis. In its course it describes a double curve, resembling the letter S (Fig. 269), which may be divided into—

(*a*) An anterior curve, corresponding to the mobile portion of the urethra and formed by the penile urethra; its apex is at the point where the penis is attached to the front of the symphysis by its suspensory ligament. This curve exists only when the penis is flaccid; it disappears when the organ is erect or when it is placed in the proper position for catheterization. Hence the anterior curve in the practical work of passing sounds is a negligible quantity.

(*b*) A posterior curve, corresponding to the fixed portion of the urethra, begins at the neck of the bladder and ends in front of the pubis where the penis is fixed by its suspensory ligament. It describes a curve which embraces in its concavity the lower border of the symphysis, from which it is

FIG. 270.—VARIATIONS IN THE CALIBER OF THE MALE URETHRA.
A, Neck of bladder; *B*, prostatic portion; *C*, membranous portion; *D*, penile portion; *E*, fossa navicularis.

separated by a distance of about 1 in. As this posterior curve is not absolutely, but only relatively fixed, it may be generally stated that it corresponds to the arc of a circle, the center of which is at the lower border of the symphysis and its radius 1 in.

The importance of knowing the direction of the fixed portion of the urethra is obvious, since it is here that difficulties in passing sounds or catheters are encountered. The reason for making urethral instruments with a definite curve is founded on this anatomic fact.

Its Divisions.—The urethra is anatomically divided into the prostatic, membranous, and spongy portions. Clinically,

it is divided into the *anterior urethra,* which extends from the meatus to the triangular ligament, and the *posterior urethra,* from the triangular ligament to the neck of the bladder. This latter division is of practical importance, since the two segments differ essentially in structure, pathology, and embryologic development.

Its **caliber** normally varies and presents alternate contractions and dilatations. The contracted segments are the meatus, the middle portion of the spongy urethra, the membranous portion, and the neck. The intervening dilatations are the fossa navicularis, the bulb, and the prostatic portion (Fig. 270). According to Woolsey, the different parts should distend so as to admit the following sounds of the French scale: the meatus, No. 24; the spongy portion, Nos. 28 to 30; the bulbous portion, No. 32; the membranous portion, Nos. 26 to 27; and the prostatic portion, Nos. 30 to 32.

The different segments of the urethra are described with the regions through which they pass.

Its Structure.—The urethra is composed of a mucous, submucous, and muscular coat, the mucosa being the only structure of practical interest.

The *mucosa* of the urethra is continuous with the glans penis in front, with the bladder, ureters, and kidneys behind, and is prolonged into the ducts and glands which open into the urethra. This arrangement has great pathologic significance, since inflammations starting in the urethra may extend to the various structures with which it is in continuity.

Characteristics of the Urethra.—(*a*) Its *elasticity* is normally very great, allowing it to distend during the passage of urine and in the introduction of sounds. In rupture of the urethra the two ends retract and sometimes separate for a distance of 1 in. or over, a fact which makes catheterization not only difficult, but dangerous.

The normal elasticity of the urethra is modified or destroyed by inflammation; cicatricial tissue replaces the elastic tissue; portions of the canal first become rigid, then contracted, and finally *urethral stricture* results. Again, the mucosa becomes friable when inflamed, and is easily torn. Hence the time when sounds are most required is the time when the passage of sounds is most dangerous, because of the possibility of making a false passage through the friable membrane.

(*b*) The *large number of orifices* which open on its surface, communicating either with a gland or a single cul-de-sac.

The *glands of Littré* are a number of small glands situated in the submucous tissue, whose orifices open on the floor of the anterior urethra or in the sinuses of Morgagni. They secrete mucus for the evident purpose of lubricating the canal.

The *sinuses of Morgagni* are a number of depressions situated along the roof of the anterior urethra; the largest of these, the *lacuna magna*, is situated in the upper wall of the fossa navicularis, about ½ in. from the meatus.

Cowper's glands are two small bodies about the size of a pea, lying on either side, between the two layers of the triangular ligament, just above the bulb. Their excretory ducts, about 1 in. in length, pass obliquely forward and open on the floor of the bulbous urethra (Fig. 256). When invaded by gonorrhea they form a deep, hard, painful tumor occupying the sides of the median raphe, and are accompanied by difficulty in micturition.

Beside these are the openings of the prostatic glands and the ejaculatory ducts already described.

It must be evident from the multitude of glands and sinuses which open into the urethra that inflammation of this canal presents possibilities of complications and chronicity, the limits of which are difficult to define.

Thus a gonorrheal urethritis has far-reaching results, not merely because of the inflammation of a long narrow canal communicating with the urinary and genital organs, but because of the infection of numerous glands and crypts which open into the canal, and in which the specific infection may lie dormant for many years.

Stricture of the urethra is due to inflammation (usually gonorrheal) or to traumatism, the result of which is the formation of cicatricial tissue which slowly contracts, diminishes the caliber of the canal, and results in stricture.

Traumatic strictures are confined to one point and develop rapidly; inflammatory strictures are usually multiple and develop slowly—years after the primary infection. The latter occurs most frequently at the contracted portions of the urethra, the *point of election* being at the junction of the anterior and posterior urethra, just in front of the triangular ligament, where the bulbous joins the membranous urethra. The reason for this is found in the anatomic fact that here is a constricted portion of the urethra lying at the most dependent part of the fixed portion of the urethra, or, briefly, *a point of constriction lying in an area of defective drainage.* The

products of inflammation naturally collect at this point, remain the longest, and affect it the most profoundly.

A normal urethra is necessary to the proper expulsion of urine; when stricture is present normal micturition is impeded and sometimes retention of urine results; or the urethra behind the stricture may become distended and finally rupture, extravasation of urine occurring in the neighboring tissues.

Stricture of the urethra may be relieved by progressive dilatation; or if this be impracticable, internal or external urethrotomy may be performed.

Catheterization, or the introduction of urethral instruments, while a simple procedure, may prove difficult and even dangerous unless the manipulations of the instrument conform to the anatomic structure of the canal.

Rules.—(*a*) Select the largest-sized instrument that will pass. A large instrument is less liable to catch in the mucous folds or crypts, and the danger of a false passage is minimized.

(*b*) Draw the penis upward over the anterior abdominal wall to obliterate the prepubic curve. In this position the direction of the canal conforms to that of the sound.

(*c*) Introduce the instrument so that the *beak is directed toward the floor of the urethra*, to avoid catching the tip in the sinuses along the roof, especially the lacuna magna in the roof of the fossa navicularis.

(*d*) After the mobile portion of the urethra has been traversed sweep the handle of the instrument around so that the beak is directed toward the roof of the urethra, and at the same time depress the handle between the thighs so that the tip of the instrument will follow the posterior urethral curve. A finger in the rectum may assist the instrument in entering the membranous urethra, where obstruction is sometimes encountered.

(*e*) *It is direction, not force, that is required.* The sound's own weight is sufficient force.

(*f*) If resistance is encountered, change the direction of the instrument. *The sound must follow, not force, a passage.* The obstacles to the passing of a sound are usually met at two points: the inferior border of the symphysis (triangular ligament) or the neck of the bladder (enlarged prostate).

Contents of the Urogenital Triangle.—Apart from the skin, which is freely movable and presents a median raphe more or less prominent, the perineum is composed of alternate layers of fascia and muscle.

The *superficial fascia* consists of two layers, a superficial and deep. The former consists of loose cellular tissue continuous with the subcutaneous tissue of the neighboring regions, especially that of the scrotum, penis, and abdominal wall. It contains the superficial perineal vessels and nerves.

The *deep layer of superficial fascia* (*Colles' fascia*) is a thin aponeurosis, triangular in form, firmly attached on its sides to

FIG. 271.—CONTENTS OF THE UROGENITAL TRIANGLE.
A, Corpus cavernosus; *B*, ischiocavernosus muscle; *C*, bulb of urethra; *D*, transversus perinei muscle; *E*, ischiobulbar triangle.

the ischiopubic rami, fusing in front with the suspensory ligament and deep fascia of the penis; behind it curves up beneath the transversus perinei muscles and fuses with the lower margin of the triangular ligament. Note, therefore, that the fusion of these two fasciæ forms a compartment *closed above, below, behind, and on the sides, its only outlet being in front,* where it is in communication with the subcutaneous

tissue of the abdominal wall, the penis, and the scrotum. *Hence extravasated urine from ruptured urethra can take but one course.* It diffuses rapidly in the subcutaneous tissue of the scrotum, penis, and abdominal wall. One observer has reported a case where it extended as far as the axilla (Testut).

This compartment contains the root of the penis, the bulb of the urethra, with their muscles, vessels, nerves, and Cowper's glands (Fig. 271).

The root of the penis is formed by the crura of the *corpora cavernosa*, two elongated cones of erectile tissue which are covered by the erector penis (*ischiocavernosus*) muscle and firmly attached to the ischiopubic rami. They converge and at the pubic arch join the corpus spongiosum to form the body of the penis.

The *bulb of the urethra* is the posterior enlargement of the corpus spongiosum surrounded by the accelerator urinæ (bulbocavernosus) muscle and situated in the middle line. It is intimately connected with the superficial layer of the triangular ligament and lies about ½ in. in front of the anus.

The *transversus perinei muscles* are two narrow muscular slips which pass transversely across the base of the urogenital triangle from the tuberosity of the ischium to the "*central tendinous point of the perineum*"—a tendinous point in the median line, midway between the bulb and the anus, where four muscles meet: the external sphincter ani, the accelerator urinæ, and the two transversi perinei.

The Ischiobulbar Triangle (see Fig. 271, *E*).—It will be noted that the transversus perinei muscles form the bases of two triangles on each side of the median line, the sides of which are bounded by the bulb internally and the crura externally; the floor is formed by the triangular ligament, and the triangles are traversed from base to apex by the superficial perineal vessels and nerves.

The **triangular ligament** forms the roof of the urogenital triangle (Fig. 272). It will be recalled that an interval exists between the levator ani muscles beneath the pubic arch, and that the triangular ligament fills this space and thereby completes the pelvic diaphragm and the roof of the urogenital triangle. The triangular ligament is a strong fibrous membrane stretched transversely across the pubic arch: its lateral borders are attached to the ischiopubic rami; at its apex beneath the pubic arch is an opening for the transmission of the dorsal vein of the penis; and posteriorly its base fuses with Colles'

fascia beneath the transverse perineal muscles. About 1 in. behind the symphysis in the median line it is perforated by the urethra, and is also traversed by the pudic arteries and nerves and the ducts of Cowper's glands.

The so-called "*posterior layer of the triangular ligament*" is really a prolongation of the obturator fascia across the pubic arch. It forms, with the anterior layer, a wedge-shaped interval about ⅓ in. in depth, and slopes backward to blend with the anterior layer and Colles' fascia. Between these two layers are the membranous urethra, surrounded by the compressor urethræ muscle, Cowper's glands and their ducts, and the internal pudic vessels and nerves.

FIG. 272.—THE TRIANGULAR LIGAMENT, SHOWING OPENING FOR MEMBRANOUS URETHRA.

The *compressor urethræ* muscle lies between the two layers of the triangular ligament and surrounds the membranous urethra. It arises on either side from the ramus of the os pubis, its fibers passing above and below the urethra to form a complete muscular covering. It acts as an external sphincter of the bladder, assists in the expulsion of semen and urine, and is an active agent in maintaining erection of the penis by compressing the numerous veins which traverse it, thereby producing a condition of venous stasis.

Perineal section (external urethrotomy) is an operation frequently performed for stricture of the deep urethra or for the purpose of draining the bladder. With a grooved staff introduced into the bladder the procedure is extremely simple, since the course of the urethra is well defined throughout. The urethrorectal triangle is opened by an incision through the median raphe extending from the scrotoperineal junction to within a short distance of the anus. By cutting exactly in the median line the hemorrhage is trifling. After the perineal fascia is incised the bulb is exposed in the forward part of the wound. The membranous urethra should then be laid open just behind the bulb and the prostatic urethra and neck of the bladder dilated—*not cut*—by the introduction of a gorget or sound. When, however, it is impossible to introduce any

instrument through the urethra, perineal section without a guide must be performed—an operation of difficulty and danger unless the anatomic landmarks be well understood. After the bulb is exposed according to the method described above, a difficulty presents itself, namely, that of locating the membranous urethra, especially when permanently obstructed and often destroyed by the repeated attempts to pass an instrument. In such a case it is well to open the urethra in front of the obstruction and retract the edges of the urethral incision by means of silk sutures. An attempt is then made to pass a fine probe through the strictured urethra into the bladder, and if successful the remainder of the operation consists in simply dividing the stricture and following the guide into the bladder. If no opening can be found the surgeon must depend entirely upon the anatomic landmarks. The following suggestions may be of service:

(*a*) *Keep in the median line.*

(*b*) Identify the triangular ligament; the membranous urethra passes between its layers and makes its exit in the median line about 1 in. below the inferior border of the symphysis.

(*c*) The prostate is in front of the neck of the bladder and surrounds the first 1¼ in. of the urethra. It may be identified through the rectum.

(*d*) The neck of the bladder is about 2½ in. to 3 in. from the surface of the perineum when the patient is in the lithotomy position (Bryant).

THE PENIS

The **penis** consists of a *root*, a *body*, and an *extremity* or *glans*.

The **root** or **fixed portion of the penis** is formed by the crura of the corpora cavernosa, deeply situated in the perineum and attached to the ischiopubic rami (see page 526). The two crura and the corpus spongiosum meet beneath the pubic arch and form the body of the penis.

The **body** or **mobile portion of the penis** properly begins at the lower border of the symphysis pubis, to which it is attached by the *suspensory ligament*, and ends in an expanded extremity, the glans penis, at the apex of which is the orifice of the urethra. When the penis is relaxed the flexed and mobile portions form an angle, when the penis is erect the mobile portion continues the direction of the fixed portion (see Fig. 269).

This organ is formed by three erectile bodies, the two corpora cavernosa and the corpus spongiosum, which at their origin are separated from each other, but which unite at the lower border of the symphysis. The two *corpora cavernosa* are placed side by side like two cylinders and occupy the dorsal plane of the penis, extending from the perineum to the base of the glans (Fig. 273). The *corpus spongiosum* encloses the anterior urethra and occupies the groove on the under surface

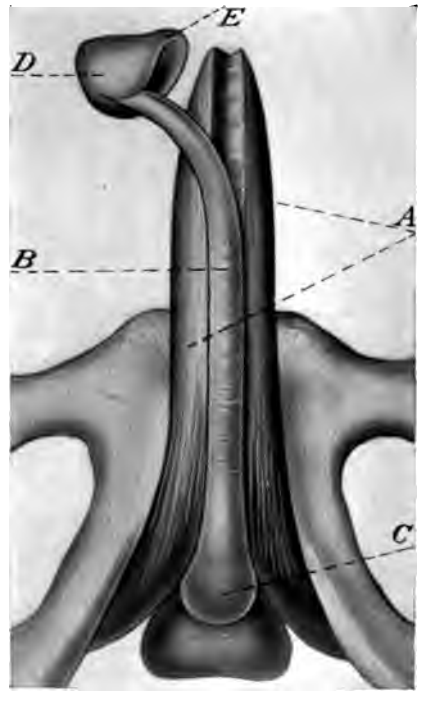

FIG. 273.—THE STRUCTURES OF THE PENIS.
A, The corpora cavernosa; *B*, the corpus spongiosum; *C*, the bulb; *D*, the glans; *E*, the corona.

of the corpora cavernosa. It begins in an expansion, the *bulb* in front of the triangular ligament, and ends in an expansion, the *glans penis*.

The **glans penis** is in the form of a flattened cone, at the apex of which is the *meatus urinarius;* at its base is a circular groove, the *cervix*, the prominent margin in front is the *corona* of the glans, which is more pronounced on the dorsal than on the ventral surface. The corona and neck contain a number

of small sebaceous glands, the *glands of Tyson*, which secrete a sebaceous material of a peculiar odor known as *smegma*. The surface of the glans is covered by a number of small papillæ endowed with special sensibility, which become prominent only when the organ is distended. The body of the penis is enveloped by integument, remarkable for its thinness and mobility, which is continuous at the root of the penis with the skin of the pubes and scrotum; at the extremity it is folded upon itself to form the *prepuce* or foreskin for the protection of the glans. The inner layer of the prepuce assumes the characteristics of mucous membrane, and after attaching itself to the neck is reflected over the glans penis and becomes continuous with the mucosa of the urethra. A triangular fold of mucous membrane, the *frenum*, connects the prepuce with the under surface of the glans. The length of the prepuce varies with the individual, from an elongation that extends below the summit of the glans to a simple fold or collar situated behind the corona and leaving the glans entirely exposed. An elongated foreskin may by mechanical obstruction or constriction cause many pathologic conditions.

Note the fact that between the prepuce and the glans is a cavity, at the base of which are a number of sebaceous glands constantly excreting smegma. The only opening of this cavity is the preputial orifice. If now the preputial orifice be so small that it cannot be retracted (*phimosis*), smegma collects within the cavity, infection follows, and inflammation results, giving rise to *balanitis* and the formation of adhesions between the prepuce and the glans. Not only this, but many reflex nervous phenomena, nocturnal incontinence, incomplete development of the glans, and liability to venereal infection may be charged to phimosis. Again, while the preputial orifice may be sufficiently large to allow the glans free exit in a state of repose, it may be necessary to forcibly retract the prepuce in a state of erection. In the latter case it may form a constricting ring about the base of the glans, interfere with the circulation, and cause an edematous swelling of the organ which imperils its vitality. This condition is known as *paraphimosis*, and demands prompt surgical intervention to prevent the glans from sloughing. All cases of phimosis should be subjected to circumcision before the sequelæ arise.

The skin is connected to the body of the penis by a layer of loose cellular tissue very rich in elastic fibers and devoid of fat. This layer gives to the skin its great mobility and is con-

tinuous with the cellular tissue of the neighboring regions. In this tissue are the superficial vessels and nerves, and it is here that extravasations of blood or urine, or edematous swellings may cause the penis to assume enormous proportions.

The *fascia penis* is the fibro-elastic sheath which forms a common investment for the erectile bodies. It is continuous behind with the superficial fascia of the perineum and above with the suspensory ligament of the penis. In front it is attached to the base of the gland and takes no part in the formation of the prepuce. Below this fascia lie the dorsal vein and artery of the penis. According to Sappey this fascia plays an important rôle in the production of erection by compressing the veins and thus bringing about a venous stasis in the corpora cavernosa.

Vessels and Nerves.—The **arteries** of the penis are supplied by the internal pudic artery, which sends branches to each of the erectile bodies and the dorsal artery to the glans.

The **veins** collect the blood from the glans and erectile bodies and for the most part empty into the *dorsal vein*, which courses beneath the fascia penis, between the two dorsal arteries. At the root of the penis it traverses the suspensory ligament and empties into the prostatic plexus.

The **lymphatics** consist of a superficial set, which drain the glans and the integument and terminate in the inguinal glands; the deep set drain the erectile bodies and probably empty into the lymphatics of the pelvis. The penile urethra is drained, for the most part, by the inguinal glands, but according to Poirier, one of the trunks passes between the recti muscles and terminates in the internal retrocrural gland.

The **nerves** are derived from the internal pudic nerve, through its superficial perineal and dorsal branches, and the hypogastric plexus of the sympathetic, which sends additional branches to the erectile tissue.

Congenital Defects.—Without detailing the process, it may be stated in a general way that the anterior and posterior urethras differ essentially in their embryologic development. The membranoprostatic urethra has its origin in connection with the internal generative organs; the spongy urethra is developed with the external genital organs. The latter is at first a groove, which is gradually converted into a canal; the fusion commencing at the bulb and advancing toward the glans. An arrest of the normal course of development gives rise to two malformations which are of special surgical interest:

(*a*) **Hypospadias,** characterized by an abnormal opening of the urethra on the under surface of the penis. It is the most frequent congenital malformation of the urethra and may vary from a small opening to a complete defect of the penoscrotal urethra; in the latter condition the penis is rudimentary and imperforate, the testicles are situated at the side of the cleft, and the urethra opens in the perineum behind the scrotum, presenting an appearance which resembles the external genitals of the female (*hypospadias vulviforme*); hence, errors in sex may be easily made at birth from a superficial examination. If the urethra opens in front of the scrotum it is known as *penoscrotal hypospadias*, if the opening is on the under surface of the glans it is a *balanic hypospadias*—by far the most frequent variety.

(*b*) **Epispadias,** characterized by an abnormal opening of the urethra on the dorsum of the penis. It is a rare deformity and often associated with congenital vesical fissures. The developmental explanation of this defect is somewhat ambiguous. According to Taylor, the erectile bodies have become reversed so that the corpus spongiosum occupies the dorsal position and hence urethral defects present on the dorsal surface. The deformity varies according as the defect involves the entire length of the penile urethra or only a part.

In *penopubic epispadias* the defect involves the entire length of the urethra and may be associated with extroversion of the bladder. In *balanic epispadias* the urethral opening is on the dorsal surface at the base of the glans, the urethral segment of the glans being represented by a dorsal groove.

Clinical Considerations.—The meatus is one of the narrowest and least distensible parts of the urethral canal. In certain aggravated cases it is necessary for the surgeon to incise the meatus (*meatotomy*) to permit proper dilatation of the urethral canal, to give free drainage in urethritis, or to relieve certain reflex phenomena, such as incontinence of urine, of which it is sometimes the cause. The abnormal position of the meatus in epispadias and hypospadias has already been alluded to under congenital defects.

The glans is frequently the site of inflammation from retained secretions (balanitis); the important rôle which the elongated foreskin plays in its production is explained in considering the prepuce. The numerous papillæ covering the glans, when subjected to prolonged irritation, hypertrophy and give rise to papillomas or *venereal warts*. The neck and corona of the penis

are favorite sites for venereal ulcerations (chancre and chancroid). Note the fact that a chancre which shows a typical induration, when situated at the base of the glans where the subcutaneous tissue is plentiful, will manifest little induration at other points on the glans, owing to the absence of subcutaneous tissue (Woolsey).

Chordee is a painful deflection of the penis which occurs during erection. It is due to an extension of inflammation from the urethra into the tissue of the corpus spongiosum whereby its elasticity is diminished, so that when erection occurs the corpora cavernosa are bent downward by the contracted spongy body, which acts like a string to a bow.

"Fracture" of the penis may occur during coitus by sudden and forcible flexion of the erectile bodies. It is followed by extensive and rapid swelling and preternatural mobility of the distal segment.

Epithelioma of the penis may originate either in the glans or the prepuce. The irritating effects of phimosis often antedate the appearance of this disease. The course of the lymphatics suggests that, since the disease is co-extensive with the inguinal lymph-glands, a radical operation must include a thorough dissection of these glands when the organ is amputated.

THE SCROTAL REGION

The scrotal region comprises the structures which envelop the testicles, the testicles themselves, and the lower portion of the spermatic cord (Fig. 274).

In studying this region recall the fact that the testicles at an early period of fetal life are contained within the abdominal cavity, lying behind the peritoneum a little below the kidney; that they subsequently migrate from the abdomen, through the inguinal canal into the scrotum; hence the structures which envelop the testicles are merely structures of the abdominal wall which have been appropriated by the testicle in its descent. From this viewpoint the seemingly complicated structural arrangement is at once simplified.

The **scrotum** is a musculocutaneous pouch containing the testicles and the lower portion of the spermatic cord. It consists of two layers, the integument and the dartos.

The *skin of the scrotum* is thin, semitransparent, and of a brownish color, containing sebaceous glands and hair-follicles. In the median line is a longitudinal raphe which marks the

line of fusion between the two genital folds and is sometimes the site of *dermoid cysts*. It is characterized by a series of transverse folds or rugæ which disappear on distention and are due to the attachment of the dartos to its deep surface. Thus the skin of the scrotum is very distensible, as seen in the enormous size attained in hydrocele; in the feeble support

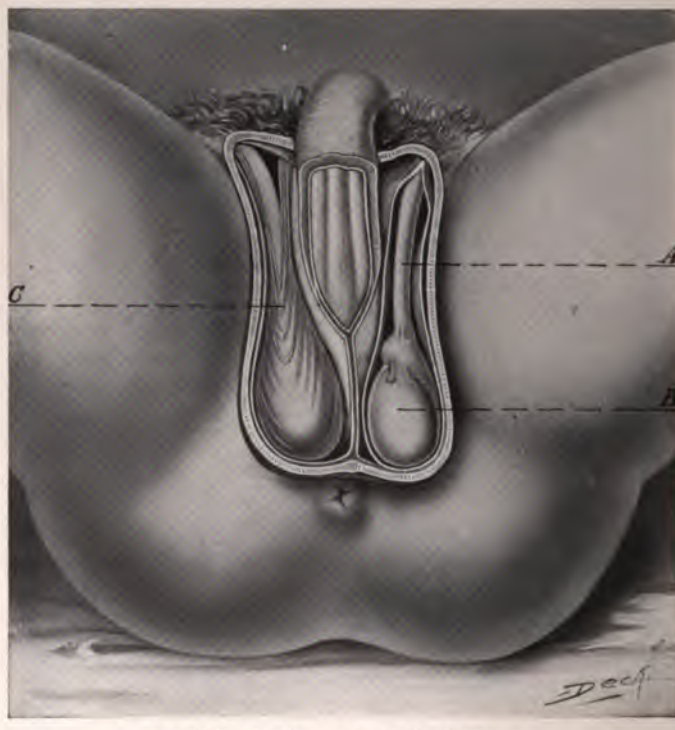

FIG. 274.—THE SCROTUM AND ITS CONTENTS.
A, Spermatic cord; *B*, testicle; *C*, cremasteric muscle.

which it offers to the veins of the cord in conditions of varicocele, and the possibility in plastic operations of borrowing large flaps from the scrotum without diminishing the capability of the bag.

The **dartos** is formed of thin muscular fibers intimately attached to the deep surface of the skin. As Tillaux observes, it is a skin-muscle which contracts under the influence of cold and venereal orgasm. It relaxes under the influence of heat

and its tonicity diminishes with age. Wounds of the scrotum have a tendency to shrivel up under the action of the dartos.

The contraction of the dartos must not be confounded with that of the cremaster, which can be produced by irritating the skin of the abdomen or the internal surface of the thighs. *The cremasteric reflex affects the testicle, not the skin of the scrotum.* While the skin of the scrotum forms a common envelop for the two testicles, the dartos forms a partition in the median line and divides the scrotum into two sacs, each of which contains the corresponding testicle and its envelopes. Thus, effusions of blood in the scrotum have a tendency to remain localized in one side.

Beneath the dartos is a quantity of loose cellular tissue entirely devoid of fat. It is limited on the sides by its attachment with the dartos to the ischiopubic rami. It is continuous with the cellular tissue of the perineum, the penis, and the abdominal wall. The presence and arrangement of this tissue explains the enormous swelling of the scrotum in cases of edema and extravasated urine or blood, and its propagation to the penis and abdominal wall.

The cellular tissue is traversed by the superficial vessels and nerves, and although the vessels are of small caliber, careful hemostasis should be observed in wounds of the scrotum to prevent the hemorrhage which sometimes follows subsequent relaxation of the dartos and the formation of large scrotal hematomas.

The **lymphatics** of the scrotum terminate in the inguinal glands. They are frequently the site of irritation from filaria or obstructive lesions producing enormous hyperplasia of the connective-tissue and resulting in *elephantiasis of the scrotum.*

Epithelioma of the scrotum usually begins as a wart or papilloma. It was formerly known as "*chimney-sweep's cancer,*" because of its prevalence among those following that occupation. It is now a rare condition. Its extension by way of the lymphatics suggests an early involvement of the inguinal glands.

Note that in addition to the two layers of the scrotum the testicle derives a covering from each of the muscles of the abdominal wall:

(*a*) The spermatic fascia from the external oblique.

(*b*) The cremasteric fascia from the internal oblique.

(*c*) The infundibuliform fascia from the transversalis.

Ordinarily, these coverings are so blended that they cannot

be recognized; only in large herniæ of long standing do they become sufficiently hypertrophied to be demonstrated.

Of these three the *cremasteric fascia* is the most important, since it holds in its meshes a number of muscular loops (*cremaster muscle*) derived from the internal oblique muscle, which forms a thin sheet enveloping the testicle and spermatic cord (see Fig. 274). When the cremaster contracts it draws the testicle up toward the inguinal ring.

The **cremasteric reflex** is the reflex contraction of this muscle which follows "tickling" of the skin of the upper and internal surface of the thigh (due to the fact that the same nerve—the genitocrural—supplies the muscle and the area of skin designated). This reflex is of great diagnostic significance in locating the lesion in certain affections of the nervous system.

The tunica vaginalis derived from the parietal peritoneum will be considered in connection with the testicle.

The **testicles** are two glandular organs, the essential function of which is to produce the spermatozoids and furnish an internal secretion which is necessary for the normal development of the individual. Note the effect of double castration in a child, in the arrest of development which ensues, and in the adult the resulting physical and psychic disturbances of a serious character.

In form the testicle is an oval with flattened sides; its size is subject to great variation, the left is usually larger than the right; in general terms it measures about 1½ in. in length, 1 in. in breadth, and 1¼ in. from behind forward.

The **epididymis** is an appendage, not a part, of the testicle. It is really the convoluted origin of the vas deferens, and surmounts the posterior superior border of the testicle "like the crest of a helmet" (Fig. 275, *A*). Its anterior expanded portion forms the head or *globus major*, which is intimately connected with the testicle by the radiating efferent ducts; its posterior and smaller extremity forms the tail or *globus minor* connected with the testicle only by connective-tissue and continuous with the vas deferens; the intermediate portion or *body* lies upon, but is separated from, the testicle by a cul-de-sac of the serous membrane termed the *digital fossa*. Occasionally the epididymis is not so intimately connected with the testicle, and the tunica vaginalis forms a distinct fold like a mesentery—the *meso-epididymis*.

Situated near the line of demarcation between the globus major and the testicle are one or two small pedunculated bodies

called the *hydatids of Morgagni.* They are fetal remains and are of importance only because they give rise to cystic tumors.

The testicles are suspended in the scrotum from the inferior extremity of the spermatic cord. The *scrotal ligament* attaches the lower border of the testicle to the bottom of the scrotum. Thus, notwithstanding its mobility within the scrotal sac, it is held in a relatively fixed position, its vertical axis being directed obliquely from above down and before back; its anterior convex border inclines forward and downward; its posterior straight border is attached to the spermatic cord and inclines backward and upward.

While this position is the rule, it is important to remember that unilateral *inversion of the testicle* may sometimes be present, seen chiefly in four varieties designated according to the position occupied by the epididymis.

(*a*) *Superior inversion,* in which the long axis of the testicle is tipped forward so that the posterior border of the testicle looks upward and the epididymis lies above in a horizontal plane (Fig. 275, *B*).

(*b*) *Anterior inversion,* in which the epididymis is attached to the anterior surface of the testicle (Fig. 275, *C*).

(*c*) *Lateral inversion,* in which the epididymis is attached to the lateral surface of the testicle (Fig. 275, *D*).

(*d*) The *loop inversion,* in which the epididymis encircles the testicle like a sling (Fig. 275, *E*) (Testut).

FIG. 275.—THE EPIDIDYMIS AND ITS RELATION TO THE TESTICLE.

A, Normal relation; *B*, superior inversion; *C*, anterior inversion; *D*, lateral inversion; *E*, the loop inversion.

The most common of these inversions is the anterior position, a fact of great surgical interest, since in cases of hydrocele the usual puncture or incision of the scrotum in front might injure the epididymis and testicle.

The **tunica vaginalis** is the serous membrane which invests the testicle and its epididymis, and lines the scrotum. Originally, it is derived from the peritoneum during the migration of the testicle from the abdomen into the scrotum; after the descent of the testicle the upper portion of the peritoneal pouch—the portion between the internal ring and upper part of the gland—becomes obliterated, and the lower portion remains as a closed serous sac which invests the testicle and lines the cavity in which it is contained.

The *visceral layer* covers the greater part of the outer surface of the testicle and epididymis; it dips in between the body of the epididymis and the outer surface of the testicle, forming the digital fossa, and is incomplete posteriorly, where the spermatic vessels and duct enter the substance of the testicle.

The *parietal layer* is reflected upon the cord for a short distance above the testicle and extends down below the level of the testicle. Between the two layers is the *cavity of the tunica vaginalis*, normally lubricated by a small amount of serous fluid, which, when secreted in excess, produces a condition of *hydrocele*.

Structure of the Testicle.—The testicle is completely invested by a dense fibrous membrane, the *tunica albuginea*, which sends radiating septa into the substance of the gland and forms the fibrous framework of the parenchyma. Between these septa is the glandular tissue containing the greatly convoluted *seminiferous tubules*, the essential structure of the gland, surrounded by very delicate cellular tissue.

It is the latter tissue which, during inflammatory changes, undergoes proliferation, crowds out the tubules, and causes *testicular atrophy*. The tubules converge to form twelve to fifteen tubes which, as the *vasa efferentia*, perforate the tunica albuginea and form the convoluted tubules of the globus major, finally terminating in a single duct, the *canal of the epididymis*.

The **spermatic cord** forms the pedicle of the testicle (Fig. 276). It commences at the upper and back part of the testicle, traverses the scrotum and the inguinal canal, and terminates at the internal abdominal ring, where its component structures are dispersed. The essential elements of the cord are the

vas deferens and the vessels and nerves of the testicle, united by loose cellular tissue and ensheathed by the infundibuliform process of the transversalis fascia, which is reinforced by the cremasteric fascia.

The **vas deferens** is the most important structure of the cord. Its long and tortuous course has already been described

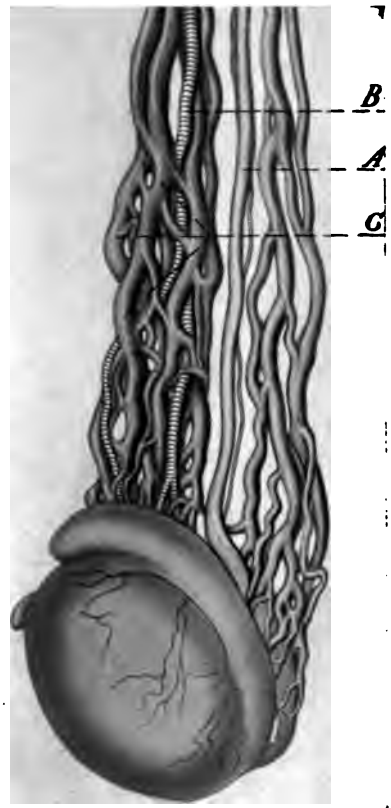

FIG. 276.—THE ELEMENTS OF THE SPERMATIC CORD.
A, The vas deferens; *B*, spermatic artery; *C*, spermatic veins.

(see page 492); only its scrotal segment will be considered here. It extends from the tail of the epididymis to the external abdominal ring and is easily distinguished from the other elements of the cord by its firm consistency. When palpated it feels like a whipcord, and on inspection it is characterized by its bluish-white color. Normally, it is smooth

and flexible, but these characteristics are distinctly modified by disease, as seen in the induration of gonorrhea and the nodular points in tuberculosis.

The vas deferens in the cord lies between two vascular groups; in front, the spermatic artery surrounded by the anterior group of veins; behind, the artery of the vas deferens, accompanied by the posterior group of veins. It is important in operations involving the cord, such as hernia and resection of varicosed veins, not to denude the vas too closely, as preservation of the artery of the vas deferens will insure the nutrition of the testicle, should the spermatic artery be sacrificed in the removal of the varicosed veins.

The **spermatic artery** is a branch of the abdominal aorta and is the largest artery of the cord. After a long course in the abdomen it reaches the internal abdominal ring, where it unites with the other elements of the cord and, pursuing a tortuous course, finally reaches the testicle, sending branches to the epididymis which anastomose with the artery of the vas, and entering the back part of the testicle supplies the substance of the gland.

Note that this artery occupies the center of a group of veins which conceal it, so that in the course of an operation it is often impossible to recognize it; hence it is frequently wounded, especially in resecting the veins for varicocele, but the vitality of the testicle is not impaired if the artery of the vas remains intact.

The **artery of the vas deferens** is a branch of the superior vesical, and accompanies the vas, forming an important anastomosis with the spermatic artery near the testicle.

The **spermatic veins** are remarkable for their number and volume. They take their origin from the testicle and epididymis, and form two groups: the anterior group in front of the vas surround the spermatic artery and form the *pampiniform plexus*, which, finally coalescing into a single trunk, empty on the right side into the inferior vena cava and on the left side into the corresponding renal vein. The posterior group behind the vas terminates in the deep epigastric vein. The veins of both groups anastomose freely between themselves and with each other; hence, in varicocele the veins of both groups are affected, but in a different degree.

It may be well to note that the frequency of varicocele on the left side is explained by the difference in the termination of the two veins: the right empties into the vena cava nearly

parallel with the course of the venous current, the left into the renal vein perpendicular to the blood current and thus forms a slight obstacle to the return flow from the left spermatic vein. This, however, is a predisposing rather than a real cause of varicocele.

The **lymphatics** of the testicle accompany the other elements of the cord and terminate in the lumbar glands.

The **nerves** of the testicle are derived from the spermatic plexus of the sympathetic, which anastomoses with the aortic, renal, and hypogastric plexuses.

Note in this connection the reflex pain felt in the testicle during an acute attack of renal calculus, and again the nausea and syncope which follow a blow on the testicle, or pain in the back associated with tumor of the testis.

Clinical Considerations.—In the migration of the testicle from the abdomen into the scrotum it is evident that it may be arrested at any point between its original site and the scrotum, or it may descend into some abnormal position.

Undescended Testicle (Cryptorchidism).—The testicle in its migration, failing to reach the scrotum, is retained either in the abdomen, the iliac fossa, or the inguinal canal; the last variety is the most frequent. Retained testicle after the age of puberty undergoes complete atrophy, so that any operation performed for the purpose of replacing the organ must be done during childhood, otherwise the result is cosmetic rather than functional. Undescended testicle is nearly always associated with inguinal hernia.

Ectopia Testis.—In this condition the testicle has deviated from its normal path and lodged in an abnormal position; thus, it may pass the inguinal canal and make its exit from the abdomen through the femoral ring and take a position in the front of the thigh near the saphenous opening, or it may pass the scrotum and finally lodge in the perineum in front of the anus.

Inversion of the testicle has already been alluded to (see page 537).

Hydrocele ordinarily refers to a collection of serous fluid in the cavity of the tunica vaginalis similar to a pleuritic, peritoneal, or joint effusion. To appreciate the varieties of hydrocele and rationally account for the same it is only necessary to recall the fact that the testicle in its descent from the abdomen into the scrotum is preceded by a pouch of peritoneum; that at birth the portion of this pouch extending from the internal ring to the upper part of the testicle is normally closed,

and the lower portion of the pouch remains as the tunica vaginalis. Under normal conditions, therefore, the collection of fluid is confined to the tunica vaginalis, and is known as *vaginal hydrocele.*

In *congenital hydrocele* there is complete patency of the peritoneal pouch, and the tunica vaginalis communicates with the peritoneal cavity. In appearance it simulates hernia.

In *infantile hydrocele* the peritoneal pouch is closed above, shutting off the general peritoneal cavity; the lower portion of the pouch and the tunica communicate, and when distended with fluid is liable to be mistaken for an inguinal hernia.

In *encysted hydrocele* of the cord the peritoneal pouch is closed above and below, the intervening portion remaining open. The practical point in hydrocele is the fact that it simulates hernia, from which it is to be differentiated, the diagnostic sign being its translucency. Again, the possible communication with the peritoneal cavity must emphasize the dangers of injecting such substances as carbolic acid and iodin to obliterate the sac, while the danger of wounding the testicle in tapping a hydrocele is apparent.

As a rule, the testicle occupies a posterior and inferior position and the sac may safely be punctured in front or above.

Varicocele denotes a varicosed condition of the veins of the spermatic cord. While it resembles varicosed veins in other regions it presents marked characteristics because of the number and tortuosity of the spermatic veins, and, in contradistinction to other varicosities, it is an affection of early adult life, when sexual vigor is greatest. The dilated and thickened veins feel like a "bag of worms," and produce a sensation of fulness or dull ache in the cord which directs the patient's attention to the condition and often causes marked psychic disturbance. Many cases of varicocele require operation for the salutary mental effect rather than the pathologic need. The cause of varicocele has received various explanations, most of which are mechanical, such as the great length and tortuosity of the spermatic veins and their imperfect valves; the greater frequency of varicocele on the left side, due to the fact that the left spermatic vein enters the renal vein at a right angle, the right vein enters the vena cava obliquely; pressure of the sigmoid on the left vein in cases of constipation; compression of the veins in the inguinal canal by the contraction of the abdominal muscles. It will be noted that all of these causes are predisposing, none are final.

It is a significant fact that varicocele always occurs after puberty (from the fourteenth to the twenty-fifth year) and diminishes with age, evidently, therefore, *an affection of puberty,* a time when a profound change is being wrought through a profound congestion of the sexual organs.

The real cause of varicocele is the pubescent congestion, associated with congenital weakness of the walls of the veins.

The **affections of the testicle and epididymis** must be differentiated by an accurate knowledge of their anatomic relations (see page 537) and the possibility of inversion of the testicle (displacement of the epididymis) be kept in mind. The testicle is easily recognized by its firm, smooth, elastic feel, and the peculiar sickening pain produced when the testicle is compressed. All of these normal characteristics are modified by disease. The epididymis, when enlarged, forms a crescentic swelling which is folded about the testicle. As a rule, syphilis and mumps affect the testicle; tuberculosis and gonorrhea, the epididymis. Tubercular affections localize in the head, gonorrhea, by preference, in the tail of the epididymis.

Tumors of the Testis.—In addition to the inflammatory enlargements the testicle is most frequently the site of *sarcoma,* especially in connection with undescended testicle. *Carcinoma* of the testicle is rare. It extends by way of its lymphatics to the lumbar glands and involvement of the inguinal glands occurs only when the scrotum is involved. The testicle is rarely the seat of *chondroma,* which shows a strong tendency to undergo sarcomatous degeneration.

CHAPTER XXIV

THE FEMALE PERINEUM AND ITS ADNEXA

THERE are many points of similarity in the male and female perineum which should be noted before considering the special points of difference. For example, in its situation, its form, and structure it is essentially the same. The *apparent difference* is seen in the external organs of generation, and yet these are really analogous, but in a reduced form. Thus, the scrotum and penis of the male are typified in the labia majora and clitoris of the female. The *real difference* consists in the perforation of the perineal structures by the vulvovaginal passage and the readjustment of the parts made necessary by this modification.

As in the male, the lozenge-shaped perineum is divided by a transverse line between the two ischial tuberosities into an anterior and posterior triangle, so in the female the same line of division is applicable. The female perineum is, therefore, divided into an anterior and posterior triangle.

The **posterior** or **vaginorectal triangle** forms the "*perineal body*" which fills the space between the lower part of the vagina and rectum. It is bounded in front by the vulvovaginal wall, behind by the anterior rectal wall, and below by the skin covering the space between the anus and vagina. It is structurally unique because of its strong connective tissue intermingled with fibers of elastic tissue and the muscles which meet at the central point of the perineum. It thus combines strength with elasticity which admirably adapts it for the remarkable stretching which it undergoes in the passage of the child's head during parturition.

The perineal body is of great surgical interest because of the lacerations which occur during labor. If its elasticity is insufficient, or if the expulsive force be suddenly applied, the structures yield, and laceration of the perineum follows. When the rupture does not involve the anus it is an *incomplete laceration of the perineum;* when the vagina and rectum communicate it is termed a *complete laceration of the perineum.* Lacerations of the perineum are grave, not alone because of

the immediate results, but because of the relaxation of the pelvic outlet, the lack of proper support for the intrapelvic organs, and its important bearing upon the pathology of prolapsus uteri.

The **anterior** or **urogenital triangle,** of which the apex is at the symphysis pubis, the base formed by the transverse line between the ischial tuberosities, and the sides by the ischiopubic rami, differs essentially on the surface from that of the male. It presents a longitudinal fissure—the vulva—on either side of which are folds of integument called labia, and into this fissure open the urinary and genital canals. If, however, the anterior perineum of the male and female be compared, they present many points in common, viz.: the floor of the space is formed by the triangular ligament, which is traversed by the urogenital canal. In the male these two canals, urethral and spermatic, are fused into one; in the female they remain separate, the urethra in front and the vagina behind. The median cleft represented by the vagina divides the bulb and the bulbocavernosi muscles into two halves, represented by the bulbi vestibuli and the sphincter vaginæ muscles, while the corpora cavernosa, the ischiocavernosi, and the transverse perinei muscles differ only in that they are reduced in size (Woolsey).

The Female External Genitals (Fig. 277).—The **vulva** is the longitudinal cleft, with its surrounding parts, which extends from the pubis to within a short distance of the anus. Above and in front of the pubis is an accumulation of fatty tissue beneath the integument which forms the *mons veneris* and becomes covered with hair at the time of puberty. The vulva is really a region which includes all the external female genitals.

The **labia majora** are two thick folds of skin, containing fat, which extend from the mons veneris backward, on each side of the vulva, and gradually diminishing in thickness, blend with the perineum about 1 in. above the anus. In front they join beneath the mons veneris and form the *anterior commissure;* behind they form with the intervening skin the *posterior commissure* or *fourchette.* Between the fourchette and the hymen is a depression—the *fossa navicularis.*

The labia majora represent the lateral halves of the scrotum and contain fat, vessels, and dartos. Their inner surface resembles mucous membrane and is provided with sebaceous and sweat-glands. The round ligaments terminate in the labia majora; hence, an inguinal hernia may present in the labia or a cyst may form in the canal of Nuck analogous to hydrocele.

The **labia minora** are two thin cutaneous folds about 1½ in. long, situated within the labia majora, extending from the clitoris, over which they unite to form the *prepuce of the clitoris*, and blending below with the inner surface of the labia majora. They contain no fat, but are composed mainly of

FIG. 277.—THE FEMALE EXTERNAL GENITALS.
A, Labia majora; *B*, anterior commissure; *C*, posterior commissure; *D*, fossa navicularis; *E*, labia minora; *F*, clitoris.

vascular tissue; on their inner surface are a number of sebaceous glands.

The size of the labia minora varies in different subjects; when they are especially redundant and project outside the vulva, it is said to be a sign of masturbation.

The **clitoris,** in form and structure, resembles the penis on a small scale. Like the penis, it consists of two corpora caver-

nosa which join to form a body about 1½ in. long, attached by a suspensory ligament to the symphysis pubis and surmounted by a glans covered by a prepuce. The glans is represented by a small rounded tubercle, situated just below the junction of the labia minora.

The **hymen** is a membranous diaphragm which incompletely closes the vaginal orifice. It varies in form, but is usually represented by a membranous ring with an opening sufficient to permit the vaginal secretions to escape. Occasionally, the membranous ring is completely closed (*imperforate hymen*), so that at the time of menstruation the secretions are retained and accumulate in the vagina, making it necessary to incise the membrane to permit their discharge. It is well to remember that the hymen may be absent or it may persist after copulation; hence, it cannot be regarded as a sign of virginity.

After the hymen has been ruptured its situation is marked by small, rounded elevations known as *carunculæ myrtiformes.*

The **vaginal bulbs (bulbus vestibuli)** are two oblong masses of erectile tissue situated on either side of the vaginal orifice. They are the homologues of the bulb of the urethra in the male, which has been split into halves by the interposition of the vaginal canal. They extend on either side of the vestibule below the sphincter vaginæ muscle, to a point below the clitoris, where they are connected by the *pars intermedia.* Rupture of the bulb may occur during parturition and give rise to the formation of a large hematoma.

The Vulvovaginal Glands (Glands of Bartholin).—These homologues of Cowper's glands are situated one on each side of the lower part of the vagina. They are about the size of a bean, and their excretory ducts, about ¾ in. long, open just oustide of the vaginal orifice near the base of the labia minora.

In cases of gonorrhea secondary infection of these glands is very frequent. They may also be the site of cysts.

PART V

THE SPINE

CHAPTER XXV

THE SPINAL COLUMN AND ITS CONTENTS

In examining the back it will be observed that there is a well-marked median furrow, bounded on either side by muscular masses, formed by the trapezius muscles in the cervical region, and by the erector spinæ muscles in the dorsal and lumbar regions. At the bottom of this groove may be felt the spines of the vertebræ. The first and most conspicuously palpable is the spine of the seventh cervical vertebra (*vertebra prominens*). This forms a convenient point from which to count the spines. In addition to this there are several important landmarks by which certain of the vertebræ may be readily identified. The third dorsal spine corresponds to the root of the spine of the scapula; the seventh dorsal spine corresponds to the inferior angle of the scapula; the fourth lumbar spine is on a level with the highest point of the iliac crest. The termination of the cord in the adult is at the lower border of the first lumbar vertebra, the dural sac opposite the body of the third sacral; in the child the points of termination are the third lumbar and third sacral, respectively. Hence, in *lumbar puncture* for diagnostic or therapeutic purposes, or as a preliminary in spinal anesthesia, *it is safe to puncture the third lumbar interspace*, which is just above a transverse line connecting the highest points of the iliac crest (see page 364).

The spine supports and connects the three important cavities of the body: the cranial, the thoracic, and the abdomino-pelvic. It is composed of a series of osseous segments, between which are interposed fibrocartilaginous disks, while all are bound firmly together by strong ligaments. There is thus formed a flexible column combining mobility and strength, the chief characteristic of which is to bend without breaking. In

addition to this it forms a canal for lodging and protecting the spinal cord, furnishing outlets at regular intervals, through which the spinal nerves emerge.

Clinically, therefore, the spine is a flexible bony tube which lodges the spinal cord.

The Intervertebral Fibrocartilage.—The fibrocartilaginous disks placed between the bodies of the vertebræ play an important part in the mechanism of the spine.

(*a*) They form a powerful means of union; so firmly are they attached that in indirect fractures of the spine the bony tissue gives way before the ligamentous.

(*b*) They form elastic cushions between the bodies of the vertebræ which act as buffers in modifying the effects of shock.

(*c*) They impart mobility to the spine without compromising its strength.

It will be noted that their peripheral portion is fibrous, their central portion pulpy and elastic; thus, they are flattened by the erect attitude and a person is actually taller in the morning than at night by ½ in. Again they are most developed where the most movement is found—observe their thickness in the cervical and lumbar regions; not only do they vary in thickness in different regions, but in different parts of the same disk. In the cervical and lumbar regions they are thicker in front, in the dorsal region, behind; thus, it will be seen that the curves of the spine are due to the difference in thickness of these bodies rather than difference in the bodies of the vertebræ themselves.

Movements of the Spine.—As Holden observes, though little movement is permitted between any two vertebræ (the atlas and axis excepted), yet the collective motion between them all is considerable. The movements of the spine are flexion, extension, lateral flexion, and a slight degree of rotation.

The greatest mobility is found in the cervical and lumbar regions, the least in the dorsal region, where it is almost *nil*. The two points of greatest mobility are above, at the junction of the cervical and dorsal segments, and below, at the junction of the dorsal and lumbar segments.

The Physiologic Curves of the Spine.—At birth the spinal column is straight, but when the child begins to sit up, the weight of the head causes the back to bend and a primitive spinal curve with the convexity backward is produced; when, however the child begins to walk, the effort to maintain equilibrium brings into play the muscles which act to produce

compensatory curves, and thus is produced the normal contour, which consists of a long curve in the dorsal region with its convexity backward, and the two compensatory curves in the cervical and lumbar regions with the convexity forward (Fig. 278). These curves vary greatly within physiologic limits and are modified by habit, occupation, and sex.

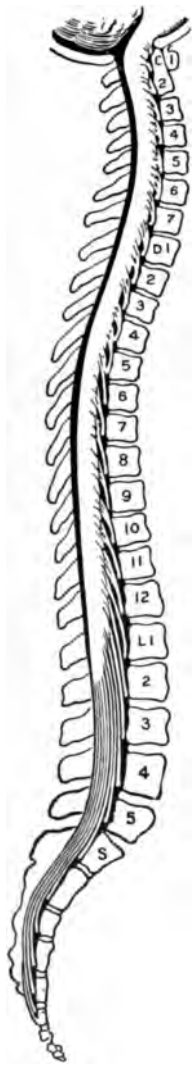

FIG. 278.—THE SPINAL COLUMN, ITS NORMAL COURSE, AND COURSE OF SPINAL CORD.

In the normal individual there may also be a slight lateral deviation from the median line in the dorsal region with the convexity to the right. This is due to the greater use of the right arm than the left. When the right arm carries the weight, the trunk is inclined to the left to maintain equilibrium. This lateral curvature is also exaggerated by habit and occupation.

Kyphosis refers to a curvature of the spine with the convexity backward. This condition may be simply the normal curve increased to an unusual degree, as seen in the round shoulders of growing children and laborers whose work compels them to assume a stooping attitude; or it may be a curve dependent upon pathologic processes, as observed in Pott's disease, infantile paralysis, rickets, etc.

Lordosis refers to a curvature of the spine with the convexity forward, most frequently seen in the lumbar region. Here, again, the condition may be simply the normal curve increased to an unusual degree, as seen in pregnant women, people with fatty abdomens, or abdominal tumors; or it may depend upon pathologic processes, as observed in hip disease, rickets, etc.

Scoliosis refers to a lateral curvature of the spine. As Bradford and Lovett observe, it should be distinctly borne in mind that lateral curvature is not a disease in any true sense of the word, but a distortion of growth.

General Characteristics of the Vertebræ.—The thirty-

three vertebræ composing the spinal column are superimposed segments which, though essentially homologous, differ in certain characteristic details.

It will be noted that certain of the vertebræ at the lower part of the column have fused together, forming separate bones, as seen in the sacrum and coccyx (the *fixed vertebræ*); the remaining vertebræ are the *true* or *movable vertebræ*. They are subdivided into groups, according to their location, as follows: seven cervical, twelve dorsal, five lumbar, five sacral, and four coccygeal.

Points in Common.—The typical vertebra consists of a bony mass in front—the *body*—and a bony ring behind—the *arch*. The superimposed bodies form the supporting column of the spine, the superimposed arches form the spinal canal which lodges the spinal cord.

Two bony bridges—the *pedicles*—connect the arch with the bodies. From the arch, posteriorly, project the *spinous processes;* laterally, the *transverse processes*. The parts of the arch between the spinous and transverse processes are the *laminæ*. Above and below the pedicles are notches which form apertures when the vertebræ are articulated and constitute the *intervertebral foramina* for the passage of the spinal nerves.

Points of Difference.—The **cervical vertebræ** are smaller than those in other segments of the spine and their distinctive characteristic is the foramen in the transverse process for the passage of the vertebral artery.

The **dorsal vertebræ** are larger than the cervical vertebræ and increase in size as they approach the lumbar region. The laminæ overlap, and the spinous processes slope obliquely downward. Their distinctive feature is the facet or half-facet on the sides of the body for the articulation with the head of the rib.

The **lumbar vertebræ** are massive in structure; their spinous processes are thick and horizontal in direction. They are distinguished by their size and the absence of the characteristic points which mark the cervical and dorsal vertebræ.

Atypical Vertebræ.—The first two cervical vertebræ, the *atlas* and *axis*, present a marked deviation from the general type. The modification of these vertebræ has for its evident aim a connection between the head and spine which combines the firmest union with the freest movement. To secure this the axis and atlas are so constructed that they not only articulate between themselves, but both are united with the occiput.

Observe how this is attained—the *atlas* or first cervical vertebra has neither a body nor spinous process. It is in the form of a ring; its body has become detached and united to the axis as its odontoid process. The *lateral masses* (the extraordinary development on the sides) present on their upper surface articular processes for the condyles of the occiput; thus a joint is formed which permits of the nodding movements of the head. On the under surface of the lateral masses are facets for articulation with the axis which permit the head to rotate.

The *axis*, or second cervical vertebra, is distinguished by the *odontoid process*, a large tooth-like process which surmounts the upper surface of the body and forms a pivot on which the atlas rotates. This process in front articulates with the atlas; behind, at its base, is a constriction which receives the *transverse ligament*, a strong band which forms with the anterior arch of the atlas an osseofibrous collar tightly embracing the neck of the odontoid process and holding it firmly in place. It is the rupture of this ligament and the subsequent dislocation, whereby the odontoid process impinges on the medulla oblongata, that produces death in cases of hanging. In high cervical caries this ligament may undergo softening and sudden death result.

From the tip of the odontoid process the *two check ligaments* pass to the inner sides of the occipital condyles. As their name suggests, they serve to limit rotation of the head.

The **spinal canal** occupies the entire length of the vertebral column and contains the spinal cord and its membranes, the cerebrospinal fluid, connective tissue, and vessels. It is bounded in front by the posterior surface of the bodies of the vertebræ, covered by the posterior common ligament; on the sides are the pedicles of the vertebræ and the intervertebral foramina, through which the spinal nerves emerge; behind, it is closed by the lamina and the *ligamenta subflava*, which are interposed between the laminæ from the axis to the sacrum. Observe that in the dorsal region the laminæ overlap and thus afford an excellent protection to that part of the cord which is most exposed to injury because of its nearness to the surface; in the cervical and lumbar region the laminæ are separated by intervals, rendering the cord more liable to injury from punctured wounds. The width of the canal is much larger than the volume of the cord; thus deviation of the spine, and even fractures and dislocations can exist without causing compression.

The width varies with the mobility of the region; in the neck and loins it is wide and triangular, in the back, where motion is limited, it is narrower and circular.

Between the walls of the spinal canal and the investing membrane of the cord is a space—the *epidural space*—filled with a mass of cellular tissue and a plexus of veins (like the cranial sinuses) which communicate with the veins of the bodies of the vertebræ (similar to the diploic veins) and in turn with the extraspinal veins. Note the analogy here to the venous circulation of the cranium.

The Spinal Cord and Its Membranes.—The spinal cord is an elongated cylindric structure contained in the spinal canal, which it occupies, but does not fill. It is about 18 in. long and extends from the atlas to the lower border of the body of the first lumbar vertebra, where it breaks up into the *cauda equina*. It is suspended in the spinal canal, but it is firmly fixed by the *ligamenta denticulata*, which pass from the cord to the inner surface of the dura. It lies nearer the anterior than the posterior surface of the canal. In the fetus the cord extends to the bottom of the sacral canal, but its growth does not keep pace with the bony canal, and at birth the cord extends to the third lumbar vertebra, and in the adult, as noted, to the first lumbar vertebra.

The cord is not of uniform diameter throughout; it presents two enlargements: a *cervical enlargement*, which extends from the third cervical to the first dorsal vertebra and corresponds with the origin of the brachial plexus, and a *lumbar enlargement*, situated opposite the last two or three dorsal vertebræ, and corresponds with the origin of the lumbar and sacral plexuses.

The **membranes of the cord** are similar to those of the brain, of which they are a continuation.

The **dura mater** is a tough, fibrous membrane which begins at the foramen magnum, to the margins of which it is firmly attached, and terminates at the base of the coccyx, where it becomes continuous with the periosteum. It thus forms a long fibrous sac which completely envelops and protects the cord. The dura is pierced laterally by the spinal nerves, ensheathing them with tubular prolongations which extend as far as the intervertebral foramina, where it blends with the periosteum.

The dura mater is attached to the cord on each side by a series of fibrous bands (the *ligamenta denticulata*) whose function is to steady and support it.

Note the points of difference in the dura mater of the cord

as compared with that of the brain. It does not form an internal periosteum for the walls of the spinal canal. It does not send in partitions to support the cord, as seen in the falx cerebri and cerebelli. It does not split to form venous sinuses. It contains no Pacchionian bodies.

The **arachnoid membrane,** like the cranial arachnoid, is in contact with the internal surface of the dura mater and is loosely connected with the pia mater by delicate connective tissue. The interval between the arachnoid and the pia is the *subarachnoid space*, containing the *cerebrospinal fluid*, which communicates with that of the brain through an opening in the floor of the fourth ventricle—the *foramen of Magendie*. As before noted, the arachnoid is the membrane of adjustment which plays the rôle of a water-bed for the brain and cord.

The intercommunication of the cerebrospinal fluid of the brain and cord is well demonstrated in the case of a *spina bifida;* pressure on the tumor causes fluctuation to be felt over the anterior fontanel; drainage of the fluid from a spina bifida affects the brain by suddenly depriving it of its support and fatal convulsions occur; in lumbar puncture the same result may follow if too large a quantity of fluid be withdrawn. The diagnostic value of an examination of this fluid in inflammatory conditions of the brain and cord is evident.

The **pia mater** of the cord differs from the pia of the brain in that it forms a thick, fibrous, rather than a thin, vascular, membrane. It is intimately attached to the cord, sending prolongations into the anterior and posterior median fissures and forming an investment for the spinal nerves. Below the second lumbar vertebra it is continued down as a slender cord (the *filum terminale*), which occupies the middle of the bundle of nerves forming the cauda equina and at the third sacral vertebra blends with the dura mater. Externally, the pia furnishes a series of important prolongations (the ligamenta denticulata) which are attached to the dura mater and serve to steady and support the cord.

Structure of the Cord (Fig. 279).—Externally, the surface of the cord shows a number of fissures or grooves, extending along its entire length. The *anterior* and *posterior fissure* incompletely divide the cord into two symmetric halves. At the sides, where the anterior and posterior roots of the spinal nerves emerge, are the *anterolateral* and *posterolateral grooves:* the former but very indistinct, the latter well-marked. On transverse section the structure of the cord is plainly shown.

It will be seen that it consists of *white nerve substance* which envelops an H-shaped central mass of *gray nerve substance* (Deaver). The gray matter is arranged in the form of two crescent-shaped masses placed in each lateral half of the cord and connected by a transverse band—the *gray commissure*. The extremities of the crescentic masses are known as the horns. The *anterior horn* is short and thick, but does not extend to the surface; it sends out numerous nerve fibers to form the anterior roots of the spinal nerves. The *posterior horn* is long and slender and extends to the posterolateral groove, where it gives origin to the posterior roots of the spinal nerves. Between the gray commissure and the bottom of the anterior fissure is an intervening strip of white substance termed the *white commissure*.

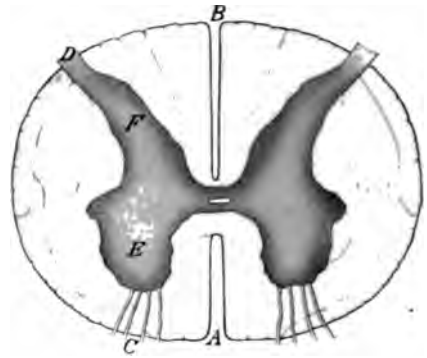

FIG. 279.—SCHEMATIC REPRESENTATION OF A TRANSVERSE SECTION OF THE SPINAL CORD.
A, Anterior fissure; *B*, posterior fissure; *C*, anterolateral groove; *D*, posterolateral groove; *E*, anterior horn; F, posterior horn.

The Conduction Paths of the Cord (Fig. 280).—In the white substance of the cord have been found certain well-defined columns or tracts, each endowed with special function. In order to understand the topography of these tracts each half of the cord is naturally divided into three areas by the anterior and posterior horns of gray matter, and these three areas subdivided as follows:

1. Posterior area	Tract of Goll. Tract of Burdach.
2. Anterior area	Direct pyramidal tract (tract of Türck).
3. Lateral area	Crossed pyramidal tract. Direct cerebellar tract. Gowers' tract.

The remaining anterolateral area is occupied by the anterolateral ground bundle.

The *postero-internal tract* (tract of Goll) consists of ascending fibers derived from the posterior roots of the nerves, which traverse the entire extent of the cord. It conveys sensory impressions from the lower extremity.

The *postero-external tract* (tract of Burdach) consists of

ascending fibers derived from the posterior roots of the nerves. It extends from the lower dorsal segment and conveys sensory impressions from the trunk and upper extremity.

The *direct pyramidal tract* (tract of Türck) consists of descending fibers which extend only as far as the first dorsal segment of the cord. The fibers do not decussate in the medulla, but cross subsequently at or near the levels of their destination. It conveys motor impulses to the upper extremity only.

The *crossed pyramidal tract* consists of descending fibers which decussate in the medulla and extend the entire length of the cord. Its fibers arise in the motor area of the cortex

FIG. 280.—THE CONDUCTION PATHS OF THE SPINAL CORD.
A, Tract of Goll; *B*, tract of Burdach; *C*, direct pyramidal tract; *D*, crossed pyramidal tract; *E*, direct cerebellar tract; *F*, anterolateral ascending tract; G, anterolateral ground bundle.

on the side opposite to that of their ultimate distribution in the spinal cord. The impulses conveyed by this tract are concerned in the voluntary control of the muscles in the lower extremity and trunk.

The *direct cerebellar tract* consists of ascending fibers which start in the column on the opposite side of the lumbosacral region. It conveys those sensory impulses to the cerebellum which have to do with the maintenance of equilibrium.

The *anterolateral ascending tract* (Gowers' tract) consists of ascending fibers which start in the upper lumbar, all of the dorsal, and all the cervical regions, and has the same function as the direct cerebellar tract, but for the trunk and arms.

The *anterolateral ground bundle* comprises the remainder of the anterolateral tract. Recent investigation shows that it contains numerous discrete tracts, some ascending and some descending, but there are many points which are not, as yet, definitely determined.

The Spinal Nerves.—Thirty-one pairs of spinal nerves arise from the spinal cord as follows: eight cervical, twelve dorsal, five lumbar, five sacral, and one coccygeal. Each nerve arises by two roots: an anterior or motor root and a posterior or sensory root, the filaments of which pass through a ganglion which lies in the intervertebral foramen.

FIG. 281.—THE FORMATION OF A SPINAL NERVE.

Just beyond the ganglion the two roots unite to form the nerve trunk (Fig. 281). Remember that the nerve trunks do not arise from the cord on a level with the foramina through which they leave the spinal canal; the majority arise from the cord at a point above their respective foramina of exit. Thus, in the cervical region the origin of the nerves is nearly on a level with their point of exit, lower down the obliquity and length of the root increases so that the roots of the lower dorsal nerves are at least a vertebra higher than the foramina through which they emerge (Holden). Since the cord terminates at the first lumbar vertebra it must be evident that the lumbar and sacral nerves run vertically downward to reach their foramina of exit. To this fact is due the formation of the bundle of nerves in the lower part of the spinal canal which constitutes the *cauda equina*, or horse-tail.

In reference to the *points of exit*, it will be recalled that there are eight cervical nerves and only seven cervical vertebræ; the first cervical nerve passes above the first vertebra; the

cervical nerves, therefore, take the name of the vertebra above which they pass out; in the other regions they are named after the vertebra below which they exit.

The points of origin of the nerve roots, with reference to the vertebræ, are important in the diagnosis of injury to the cord and to the nerves in the spinal canal. The following is, therefore, quoted from Treves:

The first cervical nerves arise from the cord opposite the interval between the atlas and occiput.

The second and third cervical nerves arise from the cord opposite the axis.

The fourth, fifth, sixth, seventh, and eighth cervical nerves arise from the cord opposite the third, fourth, fifth, sixth, and seventh vertebræ, respectively.

The first four dorsal nerves arise from the cord opposite the discs below the seventh cervical and the first, second, and third dorsal vertebræ, respectively.

The fifth and sixth dorsal nerves arise from the cord opposite the lower borders of the fourth and fifth vertebræ.

The remaining six dorsal nerves arise from the cord opposite the bodies of the sixth, seventh, eighth, ninth, tenth, and eleventh vertebræ.

The first three lumbar nerves arise from the cord opposite the twelfth dorsal vertebra.

The fourth lumbar nerve arises from the cord opposite the disc between the twelfth dorsal and first lumbar vertebræ.

The last lumbar nerve, together with the sacral and coccygeal nerves, arises from the cord opposite the first lumbar vertebra. The practical application of the above facts demonstrates that a fracture at the level of the twelfth dorsal vertebra may cause paralysis of the sacral plexus, while a lesion of the cord at the eleventh dorsal vertebra would cause paralysis of the lumbar and sacral plexuses, etc.

Clinical Considerations.—When through arrest of development the spinal canal is not completely closed, an osseous defect remains, known as *spina bifida*, found most frequently in the lumbar and sacral regions because these lamina are ossified last (Fig. 282). Through this osseous defect the contents of the spinal canal protrude, sometimes involving only the membranes (*meningocele*), or including both the cord and membranes (*myelomeningocele*). These congenital tumors occupy the exact median line and are filled with cerebrospinal fluid; hence, when the child cries the cerebral fluid is forced

into the spinal canal and the tumor becomes tense; on the other hand, when the tumor is compressed, the cerebrospinal fluid may cause cerebral irritation or even convulsions.

Traumatic Spine.—It is evident that the spine belongs to that class of joints which depend for their support upon the surrounding ligaments, and that the most frequent injury which occurs in this kind of joint is a sprain. Consider again that the spine represents not merely one joint, but multiple joints, and it is clear that an injury, which in other parts would produce a sprain of a single joint, in this region must in lesion and

FIG. 282.—SPINA BIFIDA.

symptomatology be multiplied by the number of vertebral segments involved.

The traumatic spine following railroad accidents is a condition of great clinical and medicolegal interest, since this lesion presents not merely local symptoms, but a complicated symptomatology, which clearly indicates that not only the spinal ligaments have been sprained, but that the cord itself is in some way implicated, as manifested by the anesthesia, hyperesthesia, excitability, visual disturbance, and changes of reflexes, etc., which accompany the injury.

Traumatic spine must be considered as a two-fold lesion; a sprain of the spinal ligaments associated with a concussion of the cord which, like concussion of the brain, cannot be anatomically defined; but since it presents well-defined symptoms it must be accorded a place among the organic lesions.

The jarring or shaking of the cord causes the cells to undergo some modification which we do not know.

Fractures and Dislocations of the Spine.—The multiple bony segments of which the spine is composed, and their firm, ligamentous union, indicate that fracture without dislocation of the spine, or the reverse condition, is exceedingly rare. As before stated, the chief characteristic of the spine is to bend without breaking; when, therefore, it bends to the point of breaking a double lesion results. In the cervical region a dislocation may occur without fracture, but in other regions they do not occur separately; hence, the term *fracture dislocation* is appropriately applied to this form of injury.

Fracture dislocation is the result of direct injury, as in falling across a beam or rail; or indirectly, by a heavy weight falling on the head or shoulders.

The parts of the spine where the maximum injury occurs are at the points of maximum movability, viz.: the atlo-axial, the cervicodorsal, and the dorsolumbar.

Fractures of the spine, like fractures of the skull, are important, not because of injury to its walls, but because of the injury to its contents. As a rule, the cord is compressed or it may be incompletely divided by the upper fragment being displaced forward on the lower fragment; thus, the anterior or motor portion of the cord is compressed by the sharp edge of the body of the vertebra below, and if the cord be not completely crushed motor paralysis only occurs; sensation is retained. It is necessary to clearly understand the mechanism of fracture dislocation injuries of the spine to see the reason why the removal of depressed fragments from the spine (*laminectomy*) is not analogous to the removal of depressed bone from the skull, and the consequent less encouraging results of operative treatment.

(*a*) The small size of the cord predisposes it to total destruction, not local injury, and though the depressed fragment be removed the damage is irreparable.

(*b*) The compression is not always due to an accessible fragment of bone, but to the body of the vertebra in front of the cord, which is inaccessible to the operator.

It will be recalled that the cord proper extends only as far as the lower border of the body of the first lumbar vertebra; when the injury is situated below this point, the cord escapes and the nerves of the cauda equina only are liable to be injured.

The cord may suffer compression not only from bone frag-

ments, but from the pressure of a blood-clot (hematomyelia); compression symptoms will be manifest by motor and sensory paralysis, as well as changes in the reflexes. Diagnosis of the site of injury must be based on the resultant paralyses, the topography of the cord, and the points of origin and exit of the spinal nerves.

Pott's disease or tubercular caries of the spine usually affects the bodies of the vertebræ (most frequently the dorso-lumbar junction) so that by their gradual destruction they fall forward and produce an angular projection of the spine. The anatomic factors in the construction of the spine suggest the symptoms which accompany the disease. The normal mobility of the spine is arrested and the spine is immobilized by the tension of the muscles; hence, the *symptoms of attitude.* The normal curves of the spine are affected by the gradual sinking in of the softened vertebræ; hence, the *distortion of contour;* pressure upon the spinal nerves causes characteristic *peripheral pains* in their area of distribution; note the "belly-ache" of dorsal caries. Finally, suppuration may occur and the pus, finding its way into the sheath of the psoas, present in various regions distant from its point of origin (see Psoas Abscess, page 363). It is interesting to note how the cord accommodates itself to the slowly progressive pressure, as seen in bone disease, but is itself rarely affected. On the other hand, when the disease is acute and the change in contour rapid, compression occurs and paralysis results.

The tumors of the spinal cord are similar to those found in connection with the brain. They are of practical interest in the compression symptoms which they manifest, and the possibility of diagnosing their position with the hope of surgical relief; the latter is only available when the tumor is compressing the cord from without and does not involve the cord itself.

PART VI

THE LOWER EXTREMITY

CHAPTER XXVI

SURFACE ANATOMY

THE function of the lower extremity is to support the weight of the body and provide a means of locomotion. While the upper extremity must have mobility to perform its functions, the lower extremity must have solidity. A due consideration of the function of the extremity is the guiding principle in the treatment of fractures and affections of the joints. Hence, while angular ankylosis is the most serviceable attitude in the upper extremity, the straight position is the only ankylosis of utility in the lower extremity. Again, shortening in the upper extremity is of little consequence, so long as mobility be preserved. In the lower extremity every effort should be made to preserve the normal length of the two limbs. This is of prime importance in the treatment of all fractures of the lower extremity.

Surface Markings (Figs. 283 and 284).—Palpate the *crest of the ilium*, which forms the upper boundary of this region; follow the crest to its anterior termination and demonstrate the *anterior superior spine*. At its posterior termination may be felt the *posterior superior spine*, which lies at the level of the second sacral spine and corresponds to the center of the sacro-iliac synchondrosis. Below the crest and laterally, the *great trochanter* is a prominent landmark, which in fleshy subjects is indicated by a slight depression. The *tuberosity of the ischium* forms, with its fellow, the prominent bony support in the sitting posture.

Nélaton's line is the line connecting the anterior superior spine with the tuberosity of the ischium (Fig. 285). With the parts in normal position this line touches the top of the

FIG. 283.—RELATIONS OF THE SURFACE MARKINGS TO THE BONES OF THE LOWER EXTREMITY. (ANTERIOR VIEW.)

A, Anterior superior spine; *B*, great trochanter; *C*, internal condyle; *D*, head of fibula; *E*, internal malleolus; *F*, base of fifth metatarsal bone.

FIG. 284.—RELATION OF THE SURFACE MARKINGS TO THE BONES OF THE LOWER EXTREMITY. (POSTERIOR VIEW.)

A, Posterior superior spine; *B*, tuberosity of the ischium; *C*, the gluteal fold; *D*, tendon of the biceps muscle; *E*, adductor tubercle; *F*, calf muscles; *G*, external malleolus; *H*, internal malleolus.

great trochanter. Note the importance of this line in the diagnosis of fractures of the neck of the femur and in dislocations of the hip; in the latter conditions the trochanter is above the line.

Bryant's Triangle (see Fig. 285).—The patient being in the recumbent position, drop a line vertically downward from the anterior superior spine; from the same point draw a second line to the top of the great trochanter; a third line is drawn connecting the first two, and at right angles to the vertical line. The third or test line should be compared with that of the normal side; its length is diminished on the damaged side.

FIG. 285.—*A*, *A*, NÉLATON'S LINE; *B*, BRYANT'S TRIANGLE.

The **gluteal fold** is a crease in the skin which marks the junction of the buttock with the back of the thigh. Note that the lower border of the gluteus maximus does not correspond with this fold, but lies a little above it.

Observe the **iliotibial band** of fascia lata which stretches over the great trochanter from the crest of the ilium to the outer tuberosity of the head of the tibia. The portion above the trochanter is tightly stretched, so as to firmly resist the pressure of the fingers. If the trochanter be displaced, relaxation of the iliotibial band follows—an important diagnostic point in fracture of the neck of the femur.

In the region of the groin the three most important landmarks are the anterior superior spine, the spine of the pubes,

and Poupart's ligament. The first is the point from which measurements of the lower extremity are made.

Rule.—With the patient in the recumbent position, the body in a straight line, and the limbs adducted, mark with a pencil the anterior superior spine and the lower border of the internal malleolus. With a steel tape measure the distance between the two points and compare this with the same measurement of the opposite limb. This measurement is of importance in determining the amount of shortening in injury or disease of the lower extremity. Remember, however, that even under normal conditions there is a difference of ¼ to ½ in.

The **spine of the pubis** is distinct in thin subjects, but in fleshy subjects it is hidden by the pubic fat. It can always be palpated, however, in the male by invaginating the scrotum with the index finger and passing it upward along the cord; in the female by adducting the thigh and thus bringing out the prominent tendon of the adductor longus muscle. The relation of the pubic spine to femoral and inguinal hernia is an important point in differential diagnosis.

Poupart's ligament is easily palpated, extending from the anterior superior iliac spine to the spine of the pubis. It practically corresponds to the fold of the groin—the line of junction between the abdomen and the thigh.

Scarpa's triangle is marked even in fleshy subjects by a depression below Poupart's ligament. Its boundaries are Poupart's ligament, the inner border of the sartorius, and the outer border of the adductor longus. The femoral artery passes under the midpoint of Poupart's ligament and bisects this triangle from base to apex, where its pulsations can be felt. A line drawn from the midpoint of Poupart's ligament to the tubercle of the adductor magnus on the inner condyle of the femur corresponds in its upper two-thirds to the position of the femoral artery. To the inner side of the femoral artery lies the femoral vein; to its outer side is the anterior crural nerve.

On the front of the thigh may be palpated the quadriceps extensor muscle, passing downward to form a tendon, which is attached to the patella.

On the inner side of the thigh is the adductor group of muscles, and at the back of the knee may be felt the prominent *hamstring tendons*, the inner hamstrings being formed by the tendons of the gracilis, semimembranosus, and semitendinosus, the outer hamstring by the tendon of the biceps.

The most important landmark in the region of the knee is the *patella*. Note that its upper border is attached to the quadriceps tendon, and that the *ligamentum patellæ* extends from its lower border to the *tubercle of the tibia*. When the limb is extended and relaxed, the patella can be moved to and fro over the trochlear surface of the femur; when the knee is flexed the patella is securely fixed in front of the joint. On either side of the patella is a slight groove which is obliterated by effusions into the joint.

On the inner side of the knee may be felt the *prominent inner condyle of the femur*, with its tubercle for the attachment of the adductor magnus. Below the inner condyle is the *inner tuberosity of the tibia*, and between the two may be distinguished the *interarticular line*. On the outer side is the *external condyle* of the femur, much less prominent than its fellow, and below, the corresponding tuberosity of the tibia.

The *head of the fibula* may be felt on the external aspect, nearly on a level with the tubercle of the tibia.

The *popliteal space* is a well-marked hollow behind the knee-joint, best seen when the knee is slightly flexed. The lower part of this space corresponds to the angular interval between the two heads of the gastrocnemius, the upper part to the space between the hamstring tendons.

Note the position of the *external popliteal nerve*, just behind and along the inner border of the biceps tendon; it may be palpated as it crosses the head of the fibula. Note in front of the leg the anterior border of the tibia; it forms the bony prominence termed the *shin*, and may be traced downward to the *internal malleolus*. The head of the fibula may be felt lying on the outer side, the greater part of the bone being hidden beneath the muscles on the outer side of the limb; at the lower third it becomes subcutaneous and terminates in the external malleolus.

Note the prominence of the calf formed by the gastrocnemius and soleus muscles. The outline of these muscles may be made more distinct by raising the body on the toes.

At the ankle the *three conspicuous landmarks* are the *internal* and *external malleoli* on the sides and the *tendo Achillis* behind.

Note that the external malleolus, though less prominent, extends ½ in. lower than the internal malleolus.

In front of the ankle, between the two malleoli, are numerous tendons which cover and strengthen the ankle-joint. These tendons may be brought out prominently by flexing the ankle,

and, beginning at the tibial side, each tendon may be demonstrated in the following order: the *tibialis anticus*, the *extensor proprius hallucis*, and the *extensor longus digitorum*. When the ankle is extended, the astragalus forms a distinct projection, which is most noticeable in front of the external malleolus. Behind, the tendo Achillis stands out prominently as it descends from the calf muscles to be inserted into the posterior surface of the os calcis. Between the tendo Achillis and the two malleoli are an outer groove, occupied by the tendons of the peroneus longus and peroneus brevis, and an inner groove, occupied by the deep flexor tendons and the posterior tibial vessels and nerves.

Along the outer border of the foot the *base of the fifth metatarsal bone* is the most prominent landmark.

Along the inner border of the foot may be felt the *tubercle of the scaphoid*, about 1 in. in front and slightly below the level of the internal malleolus; and, further along, the *base* and *head of the first metatarsal bone*.

The *metatarsophalangeal joints* lie 1 in. behind the webs of the toes.

CHAPTER XXVII

THE REGION OF THE HIP

THERE is much in the lower extremity which is homologous to the upper extremity. In the hip we find a correspondence to the shoulder.

Anatomically, the hip refers to the articulation of the head of the femur with the acetabulum.

Surgically, the hip comprises the joint and the soft parts surrounding it.

The **buttock** is the prominent mass of soft parts posterior to the hip. It is made up of the gluteal muscles and a large quantity of fat.

The **skin** covering the buttock is thick and coarse. It contains hair-follicles and is frequently the site of furuncles.

The **superficial fascia** is a loosely attached fascia containing a large quantity of fat. The prominence of the buttock, especially in the female, is due to the large deposition of fat, rather than the development of the glutei muscles. Over the tuber ischii the tissue is fibrofatty and brings the skin in closer relation to the bone. Because of the large amount of adipose, the buttock is the frequent site of lipomata. Large effusions of blood and pus can take place in the buttock, because of the laxity and extent of the superficial fascia.

The **deep** or **gluteal fascia** is continuous with the fascia lata of the thigh. At the anterior border of the gluteus maximus, it divides into two layers, which encase the muscle and again unite, to be attached above to the crest of the ilium and behind to the sacrum and coccyx. The superficial layer behind the gluteus maximus is thin; the deep layer in front of the gluteus maximus is more resistant and gives attachment to the gluteus medius.

This fascia is of great surgical importance, because—

(*a*) Extravasations of blood beneath the fascia are indicated by no superficial ecchymosis, and the fluctuation may confound them with abscess.

(*b*) Pus beneath the fascia may cause great pain because it is confined in an osteo-aponeurotic space, from which it may

exit by passing through the great sacrosciatic foramen into the pelvis, or burrow down the thigh. In a case reported by Treves it traveled as far as the ankle before it broke.

The **gluteus maximus** is the analogue of the deltoid. It is the largest muscle of the body and is remarkable for its thickness and the arrangement of its fasciculi.

It arises from the superior curved line of the ilium, the posterior surface of the lower part of the sacrum, the side of the coccyx, and the great sacrosciatic ligament. Its fibers are directed obliquely downward and outward. The superficial fibers pass over the great trochanter and are *inserted* into the fascia lata of the thigh, the deep fibers being inserted into the gluteal ridge of the femur. Under the lower border of the muscle can be felt the edge of the great sacrosciatic ligament.

Nerve.—The inferior gluteal.

Action.—It extends the thigh, holds the head of the femur in close approximation with the acetabulum when walking, brings the body to the erect position after stooping, and is a tensor of the fascia lata.

Beneath the gluteus maximus are two important bursæ:

The **ischial bursa** is situated over the tuberosity of the ischium, and in those whose employment requires a prolonged sitting posture it is apt to become inflamed and give rise to a bursitis which has acquired the name of "*coachman's bursitis.*"

The **trochanteric bursa** is situated between the muscle and the great trochanter. When inflamed it may give rise to symptoms simulating "hip disease," because the pain causes the thigh to be fixed in the flexed and adducted position. The differential diagnosis should be made by the absence of swelling over the joint and the ability to rotate the head of the femur without causing pain.

Caries of the great trochanter has followed suppuration of this bursa (Treves).

There is a third bursa of little interest found between the tendon of the muscle and the vastus externus.

The **fold of the buttock** is the crease in the skin which marks the line of junction between the buttock and the back of the thigh. *It does not correspond* to the lower border of the gluteus maximus, as has been erroneously stated, but is considerably above this level. The gluteus maximus, however, has much to do in *accentuating* this fold when it brings the hip

into full extension; and, *per contra*, the fold disappears when the thigh is flexed.

Hence, disappearance of this "fold" is a diagnostic sign of early hip disease, due to flexion of the hip-joint which occurs early in the disease. The fold also disappears in certain displacements of the hip.

Beneath the gluteus maximus we find the fan-shaped group of muscles, attached on one side to the pelvis, their tendons all converging, to be inserted into the great trochanter. They are the gluteus medius, pyriformis, gemellus superior, obturator internus, gemellus inferior, and quadratus femoris.

Above the pyriformis the gluteal vessels emerge; below it, the sciatic vessels.

The sacrosciatic notches are converted into foramina by the great and lesser sacrosciatic ligaments.

The **great sacrosciatic foramen** is bounded by the posterior border of the os innominatum and the great and lesser sacrosciatic ligaments.

It transmits	the pyriformis muscle, the gluteal vessels, the superior gluteal nerve	above the muscle.
	the sciatic vessels, the great sciatic nerve, the internal pudic vessels and nerves, the inferior gluteal nerve, small branches of the sacral plexus	below the muscle.

The **lesser sacrosciatic foramen** is bounded by the tuber ischii and the great and lesser sacrosciatic ligaments. It transmits the tendon of the obturator internus and the internal pudic vessels and nerves.

Through these foramina pus may burrow from the buttock to the pelvis or from the pelvis to the buttock, and make its appearance at the lower border of the gluteus maximus.

Stab wounds of the buttock may enter the pelvis through the sciatic foramina and cause fatal injuries.

Arteries and Nerves of the Buttock.—The **gluteal artery** leaves the pelvis through the great sacrosciatic foramen above the pyriformis muscle, and divides into a superficial and deep branch. The superficial branch runs between the gluteus maximus and medius muscles, the deep branch between the gluteus medius and minimus. The gluteal artery is about as large as the ulnar. In wounds of the buttock only the branches are involved, since the main trunk is within the pelvis.

Aneurysm of the gluteal artery is of traumatic origin. When small, it may be ligated and the sac excised; when large, it is necessary to ligate the internal iliac artery.

The position of the gluteal artery corresponds to the middle of the superior border of the great sacrosciatic foramen. On the surface it is indicated by the junction of the inner and middle thirds of a line drawn from the posterior superior iliac spine to the tip of the great trochanter (Fig. 286).

The **sciatic artery** leaves the great sacrosciatic foramen below the pyriformis muscle in company with the internal pudic artery and the great sacrosciatic nerve. It supplies

FIG. 286.—RELATIONS OF THE PYRIFORMIS MUSCLE TO THE VESSELS OF THE BUTTOCK. *A*, Gluteal artery; *B*, sciatic artery; *C*, internal pudic artery.

a branch to the great sacrosciatic nerve, the *comes nervi ischiadici*, and is the principal factor in forming a collateral circulation with the branches of the femoral after ligation of the external iliac artery. The sciatic artery is sometimes the site of traumatic aneurysm. The vessel lies in a space midway between the great trochanter and the tuber ischii (see Fig. 286). The great sciatic nerve lies above it and is the chief guide to the artery.

The **internal pudic artery** is peculiar in that it leaves the pelvis through the great sacrosciatic foramen, winds about the spine of the ischium, and re-enters the pelvis through the lesser sacrosciatic foramen. It may be reached through the same incision which is used in ligating the sciatic.

The **infragluteal triangle** lies just below the lower border of the gluteus maximus, which forms its base; the long head of the biceps bounds it internally and the great sciatic nerve externally (Fig. 287).

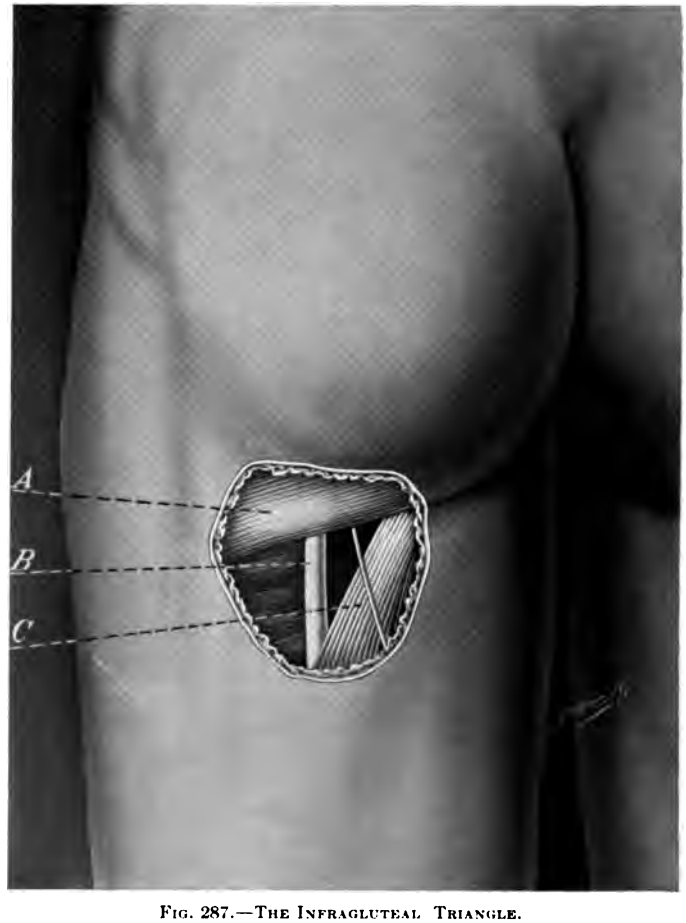

FIG. 287.—THE INFRAGLUTEAL TRIANGLE.
A, The gluteus maximus; *B*, the great sacrosciatic nerve; *C*, the biceps.

The **great sciatic nerve** is derived from the sacral plexus, and makes its exit from the pelvis through the great sacrosciatic foramen resting on the ischiatic spine, against which it may be compressed. It passes out below the pyriformis and under cover of the gluteus maximus. It lies between the tuber ischii

and the great trochanter, and is crossed obliquely by the long head of the biceps.

Sciatica is a painful affection of the sciatic nerve, which may be due to causes extrinsic or intrinsic. Among the extrinsic causes are pelvic tumors, aneurysms of the branches of the internal iliac, vesical calculi, feces in the rectum, or exostoses at the sacrosciatic foramen. Intrinsically, it may be due to chronic inflammatory changes of the connective tissue in and about the nerve. Neuralgia of this nerve has sometimes been relieved by stretching it. Two methods may be employed:

1. *Dry stretching*, accomplished by flexing the foot to a right angle, extending the leg on the thigh, and then forcibly flexing the thigh on the abdomen. This method is uncertain.

2. *Wet stretching* consists in cutting down on the nerve, isolating it, hooking it up with the finger, and subjecting it to steady traction for three minutes. This is accomplished through a 5-in. incision down the back of the thigh, extending from the gluteal fold at a point midway between the tuber ischii and the great trochanter. After passing through the skin, superficial fascia, and fascia lata, the sides of the infragluteal triangle will be recognized and the nerve isolated.

The **lymphatics of the buttock** consist of a superficial set, which empty into the inguinal glands, and a deep set, which go to the glands about the internal iliac.

The **groin,** as a region, is limited above by Poupart's ligament, externally by a line from the anterior superior spine to the great trochanter, and below by a transverse line, extending from the fold of the buttock across the anterior surface of the thigh. It practically corresponds to Scarpa's space.

The **fold of the groin** is the line of junction between the abdomen and the thigh.

The groin is covered by fine mobile skin which contains hair follicles and sebaceous glands. *In incising abscess of the groin the incision should be made perpendicular and not parallel to the fold of the groin*, for the reason that incisions parallel to the fold of the groin have a tendency to close; vertical incisions have a tendency to keep open, and, therefore, provide better drainage with less incision.

Burns of the groin may leave a contracting cicatrix, which may cause permanent flexion of the thigh; hence, the necessity of complete extension after these injuries.

Wounds of the groin are very dangerous, because they may penetrate (*a*) the abdomen and (*b*) the great vessels of the thigh.

The **superficial fascia** consists of two layers: the superficial layer, which is continuous above with the superficial fascia of the abdomen, and the deep layer, which is very thin and adherent to the fascia lata a little below Poupart's ligament.

FIG. 288.—THE LYMPHATICS OF THE GROIN.

Between these two layers of superficial fascia we find the superficial vessels, nerves, and lymphatics.

The Lymphatics of the Groin (Fig. 288).—Like the axilla, the groin is one of the principal glandular centers, and the lymphatics play an important rôle in the pathology of this region.

The *superficial lymphatic glands*, ten to twenty in number, are situated between the two layers of the superficial fascia. They consist of (*a*) a horizontal group lying along Poupart's ligament and (*b*) a vertical group along the saphenous vein. The horizontal group receives the lymphatics from the abdominal wall, the scrotum, perineum, anus, prepuce of penis, clitoris, and buttock. The vertical group receives the lymphatics from the skin of the lower extremity. The superficial glands send vessels to the deep inguinal glands.

The *deep lymphatic glands* lie beneath the deep fascia. There are two or three of them, and they are placed internal to the femoral vein. The superior gland of this group (*Rosenmüller's gland*) lies in the crural canal and projects into the pelvic cavity. Because of its situation in the crural ring, it may, when inflamed, simulate a strangulated hernia (Poirier). The deep inguinal glands receive the lymphatics from the glands of the penis or clitoris and from the superficial inguinal glands. They send branches to the iliopelvic glands.

Bubo of the groin is always symptomatic of a neighboring lesion, since the lymph-glands do not enlarge spontaneously. Thus, in chancre or malignant disease of the prepuce, penis, or of the labia majora, and in cancer of the scrotum and infections of the lower extremity, the inguinal glands are involved secondarily, and suppuration and destruction of the glands often follow.

The **fascia lata,** or deep fascia, completely envelops the thigh and binds the muscles in a fibrous cuff. It is attached to the crest of the ilium, Poupart's ligament, the rami of the pubes and ischium, the great sacrosciatic ligament, and the sacrum and coccyx. Externally, it is remarkably strong and gives attachment to the tensor vaginæ femoris.

The **saphenous opening** is an aperture in the fascia lata at the upper and inner part of the thigh. It is situated about 1 in. below the inner end of Poupart's ligament, transmits the internal saphenous vein, and forms the external ring of femoral hernia.

The arrangement of the fascia lata in the formation of the saphenous opening is interesting, and explains the peculiar pointing of deep-seated abscesses and the course of femoral hernia.

The outer side of the saphenous opening is formed by the iliac portion of the fascia lata, which is attached to the crest of the ilium and to the length of Poupart's ligament. From

the spine of the pubis it is reflected downward and outward over the sheath of the femoral vessels, forming a sickle-shaped margin (the falciform process) or external boundary of the saphenous opening. The inner side of the saphenous opening is formed by the pubic portion of the fascia lata, which is a continuation of the iliac portion, but on a *lower plane,* since it passes behind the sheath of the femoral vessels and is continuous with the sheath of the psoas and iliacus muscles. Thus, the fascia lata forming the saphenous opening is arranged in two planes, continuous below, and separated by the thickness of the femoral vessels above, so as to permit the internal saphenous vein to empty without interruption into the femoral vein in any position of the thigh.

The saphenous opening is covered by the *cribriform fascia,* so-called because of the number of perforations made by the blood-vessels and lymphatics. Femoral hernia ultimately finds its way through the saphenous opening, pushing the cribriform fascia in front of it; it then curls around the falciform process and over Poupart's ligament. The position of the thigh has much to do with the tension of the fascia lata. When the thigh is extended, the fascia lata in the groin is tense and the falciform process sharp; when the thigh is flexed and rotated inward the process slackens; hence, the value of the latter position in attempting to reduce a femoral hernia. The margin of the saphenous opening may form one of the seats of stricture in femoral hernia.

There are four muscles in this region which are of special importance: the sartorius, adductor longus, psoas, and pectineus. They form two triangles, a superficial and deep.

Scarpa's triangle is formed by Poupart's ligament as its base, the sartorius muscle externally, and the adductor longus internally. The femoral vessels bisect it from base to apex. It contains the femoral vein, femoral artery, and anterior crural nerve, arranged from within out: vein, artery, nerve (Fig. 289). The deep triangle within Scarpa's triangle is formed by Poupart's ligament, the psoas muscle externally, and the pectineus internally. The femoral vessels extend from base to apex, and occupy the bottom of the groove formed by the two muscles.

Because of the many lesions of the adductor longus muscle, causing flexion and permanent adduction of the thigh, Tillaux has compared it to the sternomastoid muscle.

During horseback riding the adductor longus is specially

employed in gripping the saddle; consequently it is frequently sprained and some of its fibers may be ruptured.

Riders' bone is an ossification of the upper tendon of the adductor longus due to sprain or rupture of the tendon from its pelvic attachment.

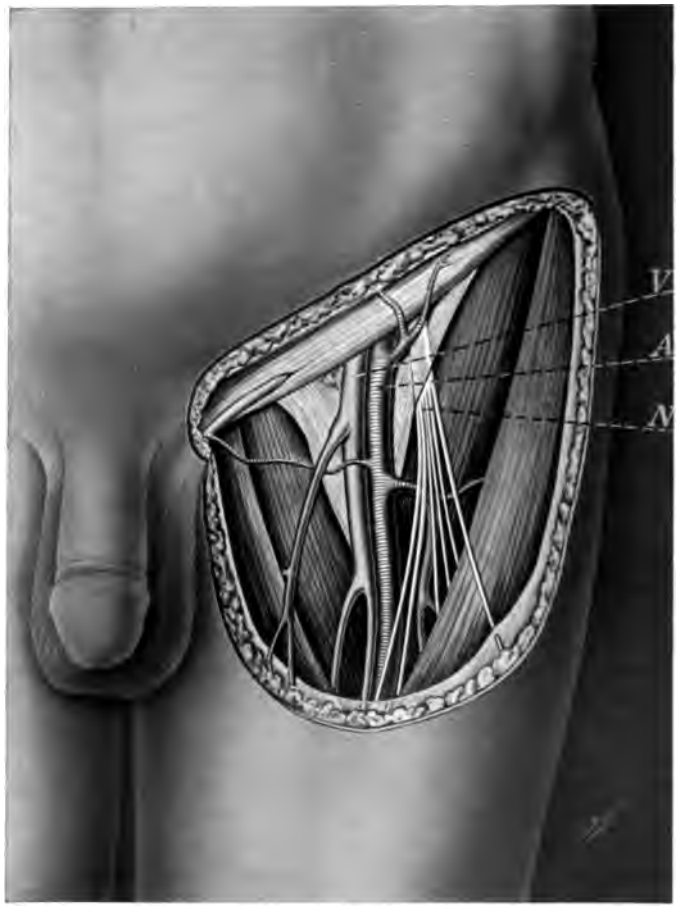

FIG. 289.—SCARPA'S TRIANGLE.
Note the relation of the (*V*) vein, (*A*) artery, and (*N*) nerve.

The **femoral vessels** bisect Scarpa's triangle from base to apex. They are not deeply placed. The pulsations of the artery can be distinctly felt even in the stoutest subject.

The **femoral artery** is the continuation of the external iliac

from beneath the center of Poupart's ligament. Its direction is obliquely downward and inward, and is represented by a line drawn from the middle of Poupart's ligament to the adductor tubercle on the internal condyle of the femur. Immediately below its origin the artery rests directly on the iliopectineal eminence, which forms an excellent point for compressing the artery; hence, the *point of election* for applying digital pressure to the artery is immediately below Poupart's ligament. *In applying digital pressure to the artery always place the fingers parallel to the axis of the vessels*, to avoid, as far as possible, compression of the vein, which is apt to be followed by phlebitis.

Digital compression of the femoral is not merely an emergency procedure in cases of hemorrhage, but it is constantly employed in amputations and other operations of the lower extremity. Nearly all of the collateral branches are given off in the region of Scarpa's triangle, the most important of which is the—

Profunda femoris, which is nearly as large as the superficial femoral. It arises from the back part of the femoral artery, about 2 in. below Poupart's ligament, and passes outward, then winds downward and inward to the adductor magnus, and finally anastomoses with branches of the popliteal artery.

This artery is the chief nutrient vessel of the thigh, and plays an important rôle in the establishment of collateral circulation after ligation of the external iliac and superficial femoral arteries.

Ligation of the femoral in Scarpa's triangle may be required for wounds or aneurysm. Ligation of the femoral above the origin of the profunda is not a safe procedure, because of the number of branches connected with it and the frequent high origin of the profunda, which might interfere with the formation of a perfect clot and give rise to secondary hemorrhage. Ligation of the external iliac is to be preferred to that of the common femoral. The most favorable site for the ligation of the femoral is at the apex of Scarpa's triangle. The incision for ligature is made over the line of the artery, the limb being slightly flexed and everted. The skin, superficial fascia, and fascia lata are divided and the sartorius muscle exposed. The muscle is drawn outward and the sheath of the vessels recognized. The sheath is opened on the side nearest the sartorius, to avoid injuring the vein. The ligature is passed from within out, close to the artery, to avoid the vein which lies behind, and slightly to the inner side of the artery.

The **femoral vein** accompanies the femoral artery in the upper two-thirds of its course. Its relation to the artery is the reverse of that of the sartorius muscle, viz.: at Poupart's ligament it lies to the inner side, at the apex of Scarpa's space it passes behind, and, lower down, it is to the outer side of the artery.

Wounds of the femoral vein are exceedingly dangerous. If very small, a lateral ligature may be applied, otherwise it is necessary to ligate above and below the wound.

Phlebitis of the femoral vein is a frequent sequela of *digital compression of the artery*, or the application of an Esmarch bandage. It also follows labor, typhoid fever, and inflammatory processes of the abdomen and pelvis. There seems to be a curious predilection for the vein of the left side, even when the inflammatory focus is on the right, as in appendicitis. Various explanations of this phenomenon have been offered, the main anatomic reason being the slower venous current on the left side due to a less direct communication with the inferior vena cava. No satisfactory cause, however, has yet been assigned.

Psoas abscess generally originates in tubercular caries of the dorsal or lumbar vertebræ. This abscess is characterized by the number of places and distance from the original focus at which it may point (Fig. 290). The pus may burrow along the sheath of the psoas, pass under Poupart's ligament, and form a swelling in Scarpa's triangle to the outer side of the femoral vessels (most common variety); or if the pus burrow through the sheath of the psoas, it may gravitate to the iliac fossa; or it may pass into the pelvis and beneath the pelvic fascia find its way through the great sacrosciatic foramen to the gluteal region; or through the obturator fascia to the ischiorectal fossa and be mistaken for fistula in ano. It may, by working behind the psoas, enter the sheath of the quadratus lumborum and point in the loin (lumbar abscess). It may point above Poupart's ligament near the anterior superior spinous process of the ilium; it may pass down to the thigh, the knee, and even to the side of the tendo Achillis, as in a case reported by Erichsen. *Thus it will be observed that lumbar, gluteal, ischiorectal, and iliac abscesses, and obscure abscesses of the lower extremity may have their origin in spinal caries.*

The Psoas Bursa.—Between the tendon of the psoas muscle and the capsule of the hip-joint is a bursa which frequently

communicates with the joint. When the bursa is inflamed and distended with fluid it forms a tumor on the front of the thigh which makes diagnosis difficult. It simulates, in many respects, hip disease. Inflammation of the bursa may extend to the joint and *vice versa*.

Tumors of the Groin.—Instances of supernumerary mammary glands located in the groin have been reported, and Treves cites a case of a female with a breast so placed, who

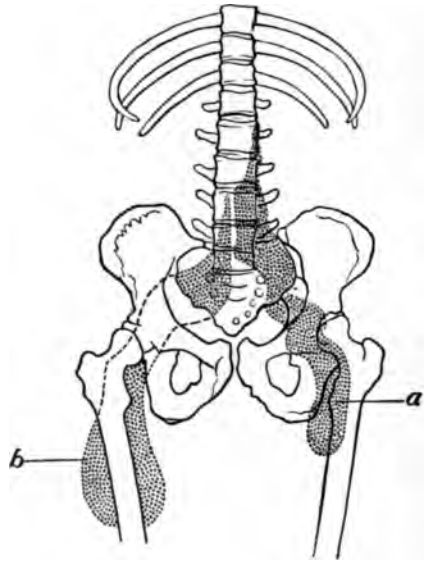

FIG. 290.—SHOWING THE COURSE OF A SPINAL ABSCESS. (After Testut.)
a, Abscess following the course of the psoas muscle and pointing below the groin; *b*, abscess passing through the great sacrosciatic foramen and pointing on the back of the thigh.

suckled her child from this part. By far the majority of tumors or glandular swellings in this region are connected with the lymphatic glands. Since the inguinal glands receive the lymphatics from the genitals and lower extremity, many of the glandular swellings are of a septic or syphilitic origin. Tubercular lymphadenitis is seldom found in the inguinal glands. Sarcoma is rather frequent and carcinoma is usually secondary to carcinoma of the penis, scrotum, and vulva.

Lipomata are frequently found in the region of Scarpa's triangle, and cases are reported where the tumor has changed its position from the groin to a point lower down on the thigh. The tumor always travels in the direction of gravity.

The **obturator** or **adductor region** consists of the soft parts about the obturator or thyroid foramen. Its boundaries are the pubic arch and perineum, the hip-joint, the horizontal ramus of the pubis, and the tuberosity of the ischium. The muscles which surround this region are the gracilis, the adductor longus, adductor brevis, and pectineus. The obturator externus is attached to the external surface of the obturator membrane and the obturator internus to the internal surface of the obturator membrane.

The **obturator** or **thyroid foramen** is a large aperture between the ischium and os pubis. In the male it is large

FIG. 291.—THE OBTURATOR CANAL.
A, Obturator vessels and nerve; *B*, obturator externus muscle; *C*, adductor magnus muscle.

and oval, in the female it is smaller and triangular. This foramen is covered in by the *obturator membrane*, which consists of two layers, an anterior and posterior. These two layers are joined below, but separated to the extent of ½ in. as they approach the pubic arch and convert the *obturator groove* of the pubic bone into the *obturator canal* (Fig. 291). Between the two layers of membrane is some cellular tissue. The obturator canal is traversed by the obturator vessels and nerve. Through this canal pus may pass from the pelvis to the thigh and *vice versa*.

The **obturator artery,** arising from the internal iliac, is

directed forward below the brim of the pelvis to the upper part of the obturator foramen and makes its exit through the obturator canal, dividing into internal and external branches which encircle the obturator membrane beneath the obturator externus muscle.

Anomalies.—In one out of three cases the obturator artery arises from the deep epigastric, and in one in seventy-two cases by two roots from both vessels. When it arises from the deep epigastric, its course in reaching the obturator canal may be on the outer side of the femoral ring (37 in 101 cases, Quain), or it may curve inward along the free margin of Gimbernat's ligament (10 in 101 cases, Quain); thus, it may almost encircle the neck of a hernial sac (Fig. 292).

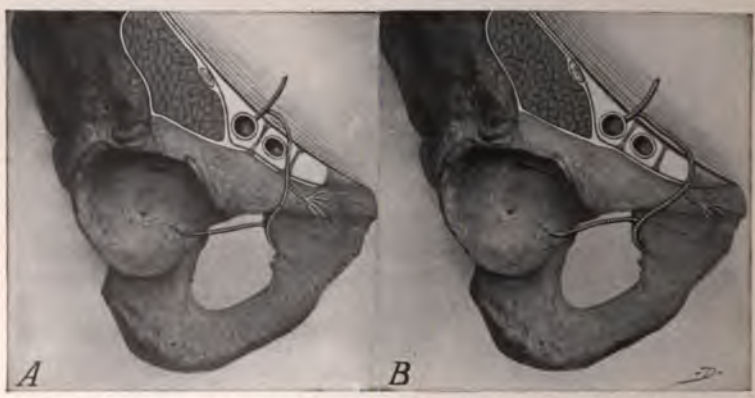

FIG. 292.—VARIATIONS IN THE ORIGIN AND COURSE OF THE OBTURATOR ARTERY. *A*, The obturator artery, external to the femoral ring; *B*, the obturator artery, internal to the femoral ring.

The **obturator nerve** passes through the obturator canal above the artery, and divides into branches which supply the obturator externus, the three adductors, the gracilis, the hip, and knee-joints. *It is due to the two-fold articular distribution of this nerve that pain in hip-joint disease is often referred to the knee.*

The **obturator gland** is a small inconstant gland at the internal orifice of the obturator canal. Cruveilhier believes that this gland is often enlarged in internal inflammations.

Obturator Hernia.—The hernial protrusion engages in the obturator canal and lies to the outer side of the adductor longus, beneath the pectineus, and to the inner side and behind the femoral vessels. These hernias are very rare and more

frequent in the female. Tillaux believes that they are most liable to occur in fat subjects who become rapidly thin. It must be remembered that these hernias are very small and the overlying muscles are thick; consequently, there is no evidence of a protrusion on the surface, and their presence cannot be more than suspected.

The symptoms present are sharp pain at the border of the obturator foramen, internal to the femoral artery. The pain is reflected along the course of the obturator nerve. Acute intestinal obstruction follows if the sac contains intestine. In all cases of acute bowel obstruction obturator hernia must be remembered as one of the possible causes.

In suspected cases the obturator foramen may be examined, per vaginam, or, in the male, per rectum. Cases are reported where the hernia has been reduced by this manipulation. In operating for obturator hernia the best route is through a vertical incision internal to the femoral vessels. The adductor longus is separated from the pectineus and the pectineus is drawn outward. To relieve strangulation the incision should be upward and inward to avoid the obturator vessels.

The **hip-joint** is deeply situated beneath a thick layer of muscles. Hence it is difficult to palpate, not easily accessible, and *grave lesions may exist where only functional symptoms are appreciable.*

It is a ball-and-socket joint, formed by the cup-shaped cavity of the acetabulum and the head of the femur. It is a joint of considerable strength, which it derives from the bony conformation of its articular surfaces and the strong ligaments which surround it.

The *bottom of the acetabulum* is very thin, even transparent, and seems as though it might be easily broken by a blow on the great trochanter. The head of the femur, however, does not come in contact with this thin portion of the acetabulum. It is supported entirely by the strong rim of the acetabulum, which bears the brunt of blows transmitted through the head. Through the nonarticular portion of the acetabulum abscesses of the pelvis may make their way into the hip-joint, and likewise abscess of the hip-joint may get into the pelvis.

On the lower border of the acetabulum is a deep notch (the cotyloid notch) which is converted into a foramen by the cotyloid ligament. Through this foramen pass the vessels and nerves which supply the hip-joint.

The **cotyloid ligament** is a fibrocartilaginous rim attached

to the margin of the acetabulum. It deepens the articular cavity, bridges over the notch, and fits the head of the femur "like an air-tight collar," enabling atmospheric pressure to act in keeping the articular surfaces in contact.

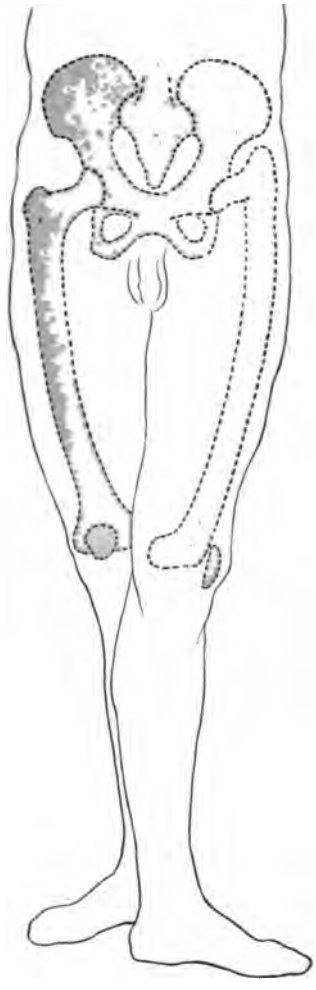

Fig. 293.—Coxa Vara.

The *superior extremity of the femur* consists of the head, the neck, and the great and lesser trochanters.

The **head** is round and forms three-quarters of a sphere. It is covered with cartilage, thicker in the center than at the circumference; near the summit and a little below the center is a depression for the attachment of the ligamentum teres.

The **neck** is like an elongated pedicle supporting the head. It is directed obliquely from above down and from within out. The narrowest part is at the junction of the head, the broadest where it is connected with the shaft. The neck forms with the shaft an angle of about 130° in the adult. This angle is said to diminish in old age, but there is not sufficient evidence to support this statement.

Coxa Vara. — During adolescence the neck sometimes undergoes softening and bends downward, and may reach an angle of 60°. This causes shortening of the limb (Fig. 293). The neck is often twisted, presenting either an anterior or posterior curve, in which case there will be either inward or outward rotation of the limb. This condition is probably due to a localized osteomalacia.

The **great trochanter** is a large quadrilateral eminence at the superior and external extremity of the diaphysis. It projects behind the posterior surface of the neck and is about

¾ in. lower than the head. At the base of its internal surface is the digital fossa, which gives insertion to the tendon of the obturator externus muscle.

The **lesser trochanter** is a conical projection on the internal surface of the femur at the base of the neck. Its summit gives insertion to the psoas muscle.

Ligaments of the Hip-joint.—The *ligamentum teres* is attached to the depression in the head of the femur, a little below its center, and to the bottom of the acetabulum (the non-articular portion); as a ligament it has little influence. Its function is to carry the vessels which nourish the head of the femur, and to act as a buffer against the force of blows transmitted through the great trochanter.

The *capsular ligament* is a strong ligamentous cuff attached to the circumference of the acetabulum and the neck of the femur. It is much thicker, less lax, more resistant than the capsule of the shoulder, and holds the articular surfaces in close apposition.

In front it is separated from the tendon of the psoas by a synovial bursa which sometimes communicates with the joint by a circular aperture and is the source of inflammatory processes. In front the capsule covers the whole anterior surface of the neck and is attached to the anterior intertrochanteric line, above it is attached to the base of the neck, and behind to the neck of the bone, ½ in. above the posterior intertrochanteric line. Hence it will be observed from this attachment of the capsule that division of fractures of the neck of the femur into intra- and extracapsular is not exact, for a fracture of the neck might at the same time be both intra- and extracapsular.

The *iliofemoral* or Y-*ligament of Bigelow*, is an accessory band of fibers which extends obliquely across the front of the joint. It descends like an inverted Y, the stem being attached to the anterior inferior iliac spine and the two branches to the upper and lower ends of the anterior intertrochanteric line (Fig. 294).

This ligament plays an important rôle in strengthening the anterior part of the capsule and preventing forward dislocations.

Fracture of the Neck of the Femur.—The former classification of intra and extracapsular fractures is now obsolete, because it is not exact and often misleading. The classification based on the clinical evidence is the only rational one, viz.: (*a*) fracture at the base of the neck; (*b*) fracture of the neck.

Why should we attempt to distinguish between these two forms? Because the essential point in the prognosis is the degree of vitality and the power of repair of the upper fragment. This depends upon the preservation of the blood supply, and the blood supply is more liable to be defective the nearer the injury approaches the head.

FIG. 294.—THE ILIOFEMORAL OR Y-LIGAMENT OF BIGELOW.

In fractures at the base of the neck the vessels are not extensively injured, impaction is usually present and the prognosis is good. In fracture of the neck the periosteum may be entirely severed and the only source of blood supply be through the ligamentum teres; the prognosis is, therefore, bad.

Fractures at the base of the neck (Fig. 295) usually occur before old age. They are caused by a fall upon the great trochanter. The compact tissue of the neck is driven into the spongy tissue of the trochanter and an impacted fracture results. It is after such a fracture that the patient frequently gets up and walks and is suddenly disabled again when the impaction is broken up. The two distinctive features of this fracture, in addition to the other symptoms, are widening of the trochanter and its backward displacement, due to fixed external rotation.

Fractures at the neck of the femur (Fig. 296) is essentially a lesion of old age, the predisposing cause being senile changes in the bone, which rarefies and becomes a mere eggshell of compact tissue and breaks on the least provocation. It is caused by a slight fall on the feet or great trochanter. It may even be due to muscular action, since this fracture has occurred

FIG. 295.—FRACTURE AT THE BASE OF THE NECK OF THE FEMUR.

in bed. The head of the femur is completely detached from the neck and rests in the acetabulum. Impaction never occurs.

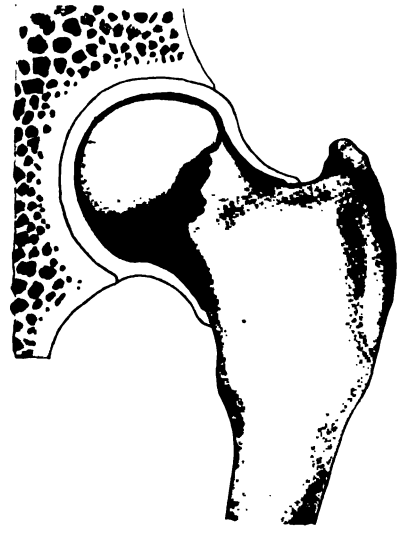

FIG. 296.—FRACTURE OF THE NECK OF THE FEMUR.

The symptoms of this fracture are at the beginning deceptive and may be mistaken for contusion of the hip. The dictum

of Hodgson may well be kept in mind, that *inability of an elderly person to use the limb after a fall upon the hip should be deemed evidence of probable fracture of the neck of the femur.*

Tillaux believes that when a patient following a traumatism of the hip cannot lift the heel from the level of the bed there is strong presumption that a fracture is present. He has never seen a contusion of the hip preclude this movement.

Symptoms common to the two varieties are:

Eversion or outward rotation of the limb	In fracture of neck it is due to the weight of the limb. In fracture of base it is due to impaction of the posterior portion of the neck. If the anterior portion of the neck is impacted, inversion will be present.
Shortening	In fracture of neck it is due to overriding, slight at first; after three or four days it increases. This is pathognomonic. In fracture at base it is due to alteration of the angle and shortening remains the same.
Elevation of Trochanter above Nélaton's line..	In fracture of neck it is marked. In fracture at base it is slight.

Allis has called attention to the effect which displacement of the trochanter produces, viz.: relaxation of the iliotibial band of fascia above the trochanter. This is easily demonstrated by comparing the two sides.

Dislocation of the Hip.—The hip-joint is one of great strength, due to its bony conformation, the connecting ligaments, and the surrounding muscles. The capsule is strong and thick; it is reinforced in front by the iliofemoral or Y-ligament. Luxations of the head of the femur are produced by great violence, and are consequently rare. To produce a dislocation of the hip a certain amount of flexion of the limb is indispensable. It is always caused by a movement of flexion combined with a movement of rotation.

Dislocation while the limb is in extension is impossible. Usually they occur when the patient is in the attitude of squatting or in falling down. Whatever position the dislocated head may ultimately assume, the primary displacement is downward and inward, the head subsequently takes a position which is determined by the degree of flexion or extension, and of outward or inward rotation of the thigh at the moment of luxation (DaCosta).

Dislocations of the hip are of two classes:

I. *Backward.*

II. *Forward*, that is, either anterior or posterior to a vertical

line drawn through the acetabulum. These may be subdivided into four varieties, depending upon the final location of the head after it has left the acetabulum. The classification is as follows:

I. *Backward* (Fig. 297).—(*a*) Ischiatic: The head rests upon the ischium at a level with the spine, behind and below the acetabulum.

(*b*) Dorsum ilii: The head rests upon the ilium, behind and above the acetabulum.

II. *Forward* (Fig. 298).—(*a*) Obturator: The head rests on the obturator foramen, in front and below the acetabulum.

(*b*) Pubic: The head rests upon the pubis in front and above the acetabulum.

Backward dislocation of the hip is the most common, because in dislocations of the hip there are three conditions present:

(*a*) Rupture of the capsule.

(*b*) Rupture of the cotyloid ligament.

(*c*) Rupture of the ligamentum teres. The Y-ligament remains untorn.

The thinnest and weakest point of the capsule is posterior; the weakest part of the cotyloid ligament is posterior; the shallowest part of the acetabulum is below. So the head of the bone is more prone to break through between these points.

FIG. 297.—BACKWARD DISLOCATION OF THE HIP.
A, Ischiatic; *B*, dorsum ilii.

The *head in backward dislocation* rests either upon the dor-

sum ilii (the most common of all the varieties) or in front of the spine of the ischium.

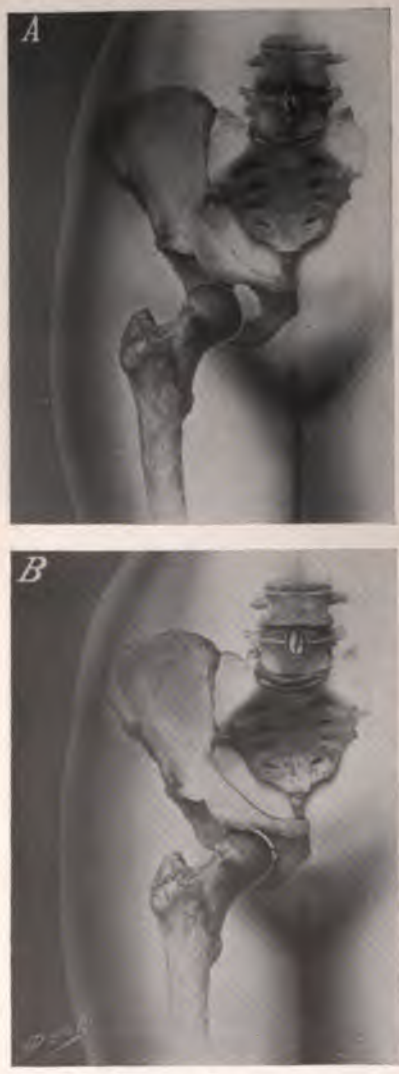

FIG. 298.—FORWARD DISLOCATION OF THE HIP.
A, Obturator; *B*, pubic.

The obturator internus muscle has an important relation to these dislocations. In ischiatic dislocation the head escapes under the obturator internus. In the dorsum ilii variety the head escapes above this muscle and cannot descend because of the collar which this muscle forms.

The symptoms are preternatural immobility, rotation of the limb inward; shorting, more pronounced in the dorsum ilii than the ischiatic. The tip of the great trochanter lies above Nélaton's line.

The *head in forward dislocations* rests either at the obturator foramen or on the pubic bone. The symptoms are preternatural immobility, rotation of the limb outward, and displacement of the trochanter inward. In the pubic variety the limb is shortened. In the obturator variety the limb appears to be elongated. This is largely due to a compensatory tilting of the pelvis.

Reduction of Dislocation of the Hip.—The chief obstacle to reduction is the untorn Y-ligament; at the same time it is the chief aid to the surgeon in accomplishing reduction, acting as a fulcrum to the shaft of the bone. Its tension prevents the head from going back into its socket;

hence, the first movement is to relax the Y-ligament by means of flexion. The manipulations for reducing these dislocations are as follows:

1. *Flex the leg on the thigh and the thigh on the abdomen.* This relaxes the Y-ligament and brings the head to the edge of the socket.

2. *Circumduct the limb in the opposite direction to which the foot is pointing, i. e.,* in backward dislocations, circumduct out; in forward dislocations, circumduct in. This brings the head to the rent in the capsule.

3. *Extend* the limb to bring the head into the acetabulum.

In making these manipulations it is well to remember that the internal condyle points in the same direction as the head.

Congenital dislocation of the hip is due to lack of development of the acetabulum and to the flat head and short neck of the femur. If reduction be made there is nothing to hold it from slipping out. After a time the muscles become shortened and a permanent dislocation is established.

The method of Lorenz consists in manipulating the limb until the muscles are stretched and the head brought opposite the acetabulum by forced extension and abduction. The limb is retained in position for several weeks by a plaster cast.

Tubercular hip disease is the most frequent of all hip diseases. It is essentially a disease of childhood. It begins as a tubercular osteomyelitis in the head of the bone or the acetabulum, and extends until it involves all the structures of the joint. There are many features in this disease which are of anatomic interest.

1. In the initial stage *pain is referred to the knee,* because of the distribution of the obturator nerve, supplying both the hip and knee-joints. The irritation of the nerve at the hip is expressed in pain at the knee. As soon as the synovia becomes infected and there is effusion into the joint the thigh is—

2. *Flexed, abducted,* and slightly *rotated outward.* This position produces the greatest laxity of the capsule, giving more room for the fluid, and is consequently the posture of greatest ease.

3. *Flattening of the buttock* and *loss of the gluteal fold* is not due in the initial stage to atrophy of the muscles, but to flexion of the hip dependent upon the attitude of the thigh, as explained above. Later, atrophy of the gluteal muscles may accentuate this symptom.

4. *Apparent lengthening* is not due to the effusion in the joint, but to tilting of the pelvis to overcome the shortening produced

by flexion and abduction, and thus restore the function of the affected side by bringing the foot to the ground.

5. If a patient be laid on his back and the affected limb extended and brought into line with its fellow, two conditions will be noticed: (*a*) The pelvis is tilted downward on the affected side (apparent lengthening), and (*b*) the lumbar spine is arched forward (lordosis), forming the compensatory curve which permits the fixed and flexed thigh to assume the extended position.

6. After the disease has progressed sufficiently to produce caries of the head, softening and relaxation of the ligaments, the limb, while still flexed, reverses its former attitude and becomes *adducted* and *rotated inward*.

Various explanations of this position have been offered. None are satisfactory. The most rational explanation of this change of attitude is based on the fact that the obturator nerve supplies both the hip and the adductor muscles. The first position which the limb assumes is the posture of greatest ease. After a time the ligaments soften and relax, and the original posture is not so necessary for comfort. At the same time, irritation of the obturator nerve is producing a reflex irritation in the adductor muscles which causes them to contract and the limb finally reaches the position of the second stage—adduction and rotation inward.

7. *Apparent Shortening.*—With the change in position of the limb to adduction, the pelvis tilts up on the affected side, just as it tilted down with the limb in abduction, in order to restore the parallelism of the limbs.

8. *Actual shortening* occurs in the third stage of the disease, when the tissues have become disintegrated and the head of the femur is either dislocated upward or the head of the bone is actually absorbed.

CHAPTER XXVIII

THE THIGH

THE **thigh** is that portion of the lower limb that extends between the region of the hip and the upper border of the synovial cul-de-sac of the knee-joint, two fingers' breadth above the patella. It corresponds to the middle part of the femur.

The thigh is the shape of a truncated cone with the base above. In men the surface is irregular from the muscular reliefs; in women it is nearly round. The thigh is directed obliquely downward and inward, more pronounced in the female because of the width of the pelvis.

The skin is thick and coarse externally, but internally it is thin and fine. It is loosely attached to the subjacent tissue, and very mobile, so that the cuff flap is easily obtained in circular amputations of the thigh. The subcutaneous tissue varies in different subjects. In the female it is very abundant. The nerves which supply the skin are imbedded in this tissue.

The **fascia lata** envelops the thigh like a fibrous cuff, binding the muscles closely together. It is thickest externally, where it forms the strong iliotibial band, and thinnest at its inner and upper aspect. In case of a rent of the fascia lata the subjacent muscle may protrude, forming a hernia of the muscle.

From the fascia are given off two prolongations or intermuscular septa. The outer extends from the insertion of the gluteus maximus to the outer condyle, and separates the vastus externus from the short head of the biceps. The inner separates the vastus internus from the adductors and pectineus.

We may divide the muscles of the thigh into those which are attached to the femur and those which are free. *Because of this arrangement the muscles contract unevenly after circular amputation.* The attached muscles are the adductors, the vasti, and the crureus. The free muscles are the sartorius, rectus, biceps, semimembranosus, semitendinosus, and gracilis.

The **femoral artery** begins at the middle of Poupart's ligament and terminates at the lower border of Hunter's canal.

Its direction is represented by a line drawn from the middle of Poupart's ligament to the posterior surface of the internal condyle of the femur.

Surgically, the femoral artery may be divided into two parts, corresponding to the points at which it may be ligated.

FIG. 299.—HUNTER'S CANAL AND CONTENTS.

1. Superior—from Poupart's ligament to the apex of Scarpa's triangle.

2. Inferior — Hunter's canal from the apex of Scarpa's triangle to the femoral opening in the adductor magnus.

Hunter's canal is a three-sided fibromuscular space occupying the middle third of the thigh and contains the femoral artery, femoral vein, and the long saphenous nerve.

It is roofed in by the sartorius muscle and a fibrous expansion which extends from the vastus internus across the femoral vessels to the adductors. On the outer side it is bounded by the vastus internus; the adductors longus and magnus constitute the inner boundary. The vein and artery are enclosed in their own sheath; the vein lying behind and on the outer side of the artery is often adherent to it, so that separation is sometimes difficult. The nerve lies at first on the outer side and then in front of the artery (Fig. 299).

The important relation of the femoral vein and artery is easily remembered by recalling the relation of the sartorius muscle, and remembering that the relation of the vein is just the reverse. Thus, at the base of Scarpa's triangle the muscle is

on the outer side and the vein is to the inner side. At the apex of the triangle the muscle is directly over the artery, the vein is directly behind it; in Hunter's canal the sartorius is above and to the inner side, the vein is beneath and to the outer side (relation of the letter X).

Ligation of the artery in Hunter's canal is usually performed for popliteal aneurysm. An incision is made over the line of the artery in the middle of the thigh. The skin and fascia having been divided, the sartorius muscle is recognized by the direction of its fibers and drawn inward. The aponeurotic roof of the canal extending from the adductors to the vastus internus, having been exposed, is divided and the sheath of the vessels recognized and opened. The vein lies to the outer side of the artery and the ligature is passed from without inward.

Anomalies of the Femoral Artery.—The artery has been found dividing into two trunks below the origin of the profunda, and uniting again at the lower border of Hunter's canal, to form a single popliteal artery. The artery has been found in the back of the thigh, making its exit from the pelvis through the great sacrosciatic foramen and accompanying the great sciatic nerve to the popliteal space, where it assumed its normal course (DaCosta).

The **great sacrosciatic nerve** at the back of the thigh is situated between the adductor magnus in front and the biceps behind; at the lower third of the thigh (the popliteal space) it divides into the internal and external popliteal nerves.

It is the cause of *stump neuralgia* after amputation, when it has not been pulled down and sufficiently excised.

The *superficial lymphatics* occupy the internal surface and empty into the superficial glands of the groin.

The *deep lymphatics* accompany the vessels and empty into the glands which occupy the crural canal.

Fracture of the Femur.—The shaft of the femur may be broken at any point, but is most common at the middle third of the bone (Fig. 300). The fracture is usually oblique, although in children it is frequently transverse and subperiosteal, a condition which, while favorable for treatment, may lead to errors in diagnosis because of lack of deformity and absence of crepitation. The obliquity of these fractures in the adult gives rise to considerable displacement and it is often a serious difficulty to prevent shortening. The lower fragment is usually drawn up behind the upper by the hamstrings. The lower

extremity of the upper fragment is tilted forward by the pressure of the lower fragment and by the aid of the psoas muscle. There results an angular deformity which cannot always be completely reduced, even with extension, and under the best treatment it is exceptional to get a result without some degree of shortening. It is well to remember in this connection that normal limbs are not always of equal length, and if, after a fracture of the femur, the shortening is not more than an inch, the result should be considered good.

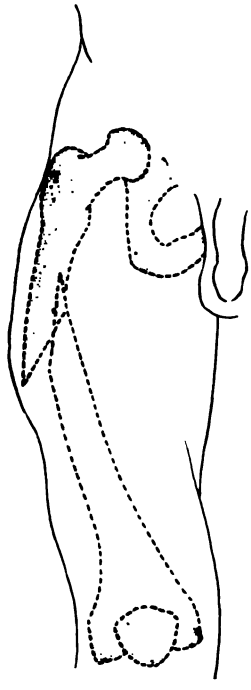

FIG. 300.—THE ANGULAR DEFORMITY IN FRACTURE OF THE SHAFT OF THE FEMUR.

The femur is frequently the site of *osteomyelitis of adolescence.* Its frequency here is undoubtedly due to exposure to injury, which is often the exciting cause of the disease. Early drainage of the bone is the important consideration, and the point of election for opening the abscess is on the anterior and external surface, where there are no important vessels or nerves. Necrosis of the femur frequently follows osteomyelitis, especially when the treatment of the acute process has been delayed. Sometimes the sequestrum occupies the entire diaphysis, in which case it is necessary to amputate the limb.

Sarcoma is frequently found in the femur, originating either in the periosteum or in the medullary cavity. If it appears in the upper portion of the thigh, it is inoperable; if in the lower portion, it may be treated by amputation at the hip.

CHAPTER XXIX

THE REGION OF THE KNEE

THE region of the knee comprises the articulation and the soft parts surrounding it. It extends above, to the upper border of the synovial cul-de-sac—two fingers' breadth above the patella; below, to the tuberosity of the tibia. Anteriorly, the median line is occupied by the patella; on each side is a well-marked depression which disappears when there is fluid in the joint; above is a slight depression which corresponds to the superior synovial cul-de-sac which becomes prominent in case of intra-articular effusion; below, is a large flat tendon, the ligamentum patellæ, which becomes prominent when the leg is extended, and is attached below to the tuberosity of the tibia.

Laterally, we note the prominence of the condyles, especially the inner condyle, which forms the rounded eminence so conspicuous on this part of the joint. Below this is the inner tuberosity of the tibia, and between the condyle and the latter process can be palpated the interarticular line; on the inner condyle can be felt the adductor tubercle. The head of the fibula forms a prominence on the outer side and on a level with the tubercle of the tibia. Most of these surface markings about the knee-joint increase with extension, diminish with flexion, and disappear in effusion in the joint.

The skin in front is thick, becoming thinner toward the sides. It is loosely attached and glides easily over the subjacent structures. This is a means of protection to the joint, since the gliding skin tends to direct violence away from the articulation. It also permits loose cartilages to be located and removed and the joint so entered that the skin incision does not correspond to the opening into the capsule, an excellent precaution against the entrance of infection.

The deep fascia of the knee-joint is a continuation of that of the thigh. It completely envelops the knee-joint, forms a sheath for the quadriceps tendon, passes in front of the patella without adhering to it, is inserted below into the internal and external tuberosities of the tibia and the head of the fibula, and continues below with the aponeurosis of the leg.

The **prepatellar bursa** is situated in front of the periosteum of the patella and behind the deep fascia. In people whose occupations require a kneeling posture, such as scrubwomen and certain mechanics, an inflammatory process may be set up in this bursa which results in enlargement, distention with serous fluid, or sometimes pus. This condition is known as *prepatellar bursitis* or "*housemaid's knee.*" Housemaid's knee and synovitis of the joint will not be confounded if it is remembered that in the former the fluid is above the patella, while in synovitis the patella is above the fluid. There is also a small bursa between the ligamentum patellæ and the tubercle of the tibia. When inflamed it is very painful because of the rigidity of the surrounding structures. It may sometimes communicate with the joint, and cases are reported where incision of the bursa has led to suppuration of the articulation (Treves).

The Circumpatellar Anastomosis.—Around the patella and about the contiguous end of the femur and tibia is formed a rich anastomotic circle. This anastomosis is formed by the two internal and two external articular branches of the popliteal, the anastomotica magna, the descending branch of the circumflex, and the recurrent branch of the anterior tibial. The anastomoses of these vessels form two arches. The superficial arch runs between the skin and fascia about the patella. The deep arch lies on the surface of the lower end of the femur and upper end of the tibia, supplying branches to the contiguous bones and numerous offsets into the joint. Through this anastomosis the collateral circulation is established after ligature of the popliteal artery.

The **nerves of the knee-joint** are derived from the obturator, the anterior crural, and internal and external popliteal.

Pain about the knee is not only symptomatic of disease in the knee, but, owing to the nerve supply, it is frequently *an indication of disease far removed from the knee, but sharing the same nerve supply.* Such conditions as disease of the cord in the neighborhood of the third and fourth lumbar vertebræ, pressure on the trunk of the anterior crural, obturator, or sciatic, and disease of the hip-joint may be manifested by pain in the knee.

The **popliteal space** in the lower extremity may be compared to the bend of the elbow in the upper extremity. It contains large vascular and nerve trunks which supply the leg. Wounds in this region, while rare, are very dangerous, since they may involve the artery, vein, or nerve. This space

is a lozenge-shaped depression situated behind the knee, the depression being caused by the hollow which lies behind the two condyles of the femur. The boundaries *above* are the biceps externally, the tendons of the semitendinosus and semimembranosus and gracilis internally, *below* the two heads

FIG. 301.—THE POPLITEAL SPACE.; RELATION OF STRUCTURES SEEN FROM BEHIND. *A*, Artery; *V*, vein; *N*, nerve.

of the gastrocnemius (Fig. 301). The floor is formed by the lower part of the posterior surface of the femur, the posterior ligament of the joint, and the popliteus muscle. The roof is covered in by the fascia lata. The skin covering the space is thin and smooth. When destroyed by a burn, a contracting

cicatrix may result which permanently flexes the knee. The transverse fold formed by the flexion of the leg on the thigh does not correspond to the interarticular line; it is a little above.

The subcutaneous tissue in the median line is traversed by the external saphenous vein; it pierces the fascia lata at the middle of the space and empties into the popliteal vein. The fascia lata is a prolongation of the aponeurosis of the thigh and is continuous below with the fascia of the leg. It is very dense and restrains the growth of tumors and the progress of abscesses toward the surface. The unyielding character of the fascia masks the presence of pus and extensive destructive changes may go on before it is discovered. The pus is practically contained in a fibro-osseous tube from which it may escape above into the thigh or below into the leg. Early incision and free drainage should be provided before extensive infiltration occurs, or amputation may be necessary.

The **hamstring muscles** are frequently the site of contractures in diseases of the knee-joint when it is not immobilized in extension. The leg is flexed by degrees on the thigh and the tibia drawn slowly backward until a partial backward luxation results. This condition is frequently observed in tubercular knee.

The **biceps** arises from the tuberosity of the ischium and the outer lip of the linea aspera; it is inserted into the outer side of the head of the fibula. *The tendon of this muscle forms the outer hamstring.*

Its *action* is to flex the leg and rotate it slightly outward. Its *nerve* is the great sciatic.

It is very frequently the cause of permanent flexion and causes a formidable resistance to extension of the leg. If the muscle cannot be stretched under anesthesia, it is necessary to do a tenotomy of the biceps tendon.

In performing this operation remember that *the external popliteal nerve hugs the inner border of the biceps tendon and that in a subcutaneous tenotomy it is liable to be severed and paralysis of the external muscles of the leg result.* To avoid this accident it is much wiser to do an open operation.

The **semitendinosus** is remarkable for the length of its tendon. It arises from the tuberosity of the ischium and is inserted by a long tendon into the upper and inner surface of the tibia, from which it is separated by a bursa. Its *action* is to flex the leg and rotate it slightly inward. Its *nerve* is the great sciatic. This muscle is often the subject of contractures

in tubercular knee, but tenotomy of the tendon presents no difficulties.

The **semimembranosus** is attached to the tuberosity of the ischium and inserted into the inner and back part of the tibia. It flexes the leg and rotates it slightly inward. Its nerve is the great sciatic. It does not participate in contractures to the extent of the other flexors. It is associated with a large bursa, which separates it from the internal head of the gastrocnemius and will be described separately.

The two preceding muscles with the gracilis form the inner hamstrings. The semitendinosus, the gracilis, and the sartorius pass over the internal condyle of the femur, from behind forward, in the order named. They are separated from the internal lateral ligament of the knee by a bursa, the *bursa anserina,* which sometimes becomes inflamed and is the site of serous effusion. It will be noted that the hamstring muscles are all supplied by the great sciatic nerve. This nerve also supplies the knee-joint, and may explain the contractures of these muscles in disease of the joint. The two heads of the gastrocnemius form the lower borders of the popliteal space. The external head is covered by the biceps, the internal head by the semimembranosus. Between the internal head and the fibrous capsule of the joint is a *bursa* which sometimes communicates with the joint by means of an opening in the capsule.

The **popliteus muscle** occupies the bottom of the popliteal space. It arises from the outer side of the external condyle of the femur and the posterior ligament of the knee-joint, passes obliquely downward and inward, and is inserted into the posterior surface of the shaft of the tibia above the oblique line. A *bursa* is placed between the condyle and the muscle. The tendon of the muscle is covered by the external lateral ligament of the joint and it grooves the external semilunar cartilage, being enclosed in a prolongation of synovial membrane of the joint.

The **bursæ of the popliteal space** are numerous, and play an important rôle in the diagnosis of cystic tumors of this region. The most important of these is the constant and well-developed bursa between the tendon of the semimembranosus and the internal head of the gastrocnemius. It is nearly always the site of cysts of the popliteal space. It is well in differentiating these cysts to remember that they are usually situated in the lower part of the popliteal space toward the inner side and away from the median line.

The *contents of the popliteal space* are the popliteal artery and vein, the internal and external popliteal nerves, and the lymphatic glands.

The **popliteal artery** begins at the opening of the adductor magnus and ends at the lower border of the popliteus muscle. The artery enters the top of the space in company with the vein. It lies successively on the posterior surface of the femur, the posterior ligament of the joint, and the popliteus muscle. From the posterior surface of the femur it is separated by a considerable space, which is filled with cellular tissue; from the head of the tibia it is separated only by the posterior lig-

FIG. 302.—RELATION OF POPLITEAL VESSELS AND NERVE, SEEN IN TRANSVERSE SECTION. *A*, Artery, *V*, vein; *N*, nerve.

ament of the joint. *Hence, in resection of the condyle of the femur the artery is not so much in danger as in resecting the head of the tibia;* here the popliteal vessels must be pushed away and the head removed by sawing from behind forward.

In the backward luxation of tubercular knee the artery is progressively adjusted to this condition, but in reducing the luxation there is danger of rupturing the vessel. This applies with equal force to traumatic dislocations of the knee backward.

Relations.—The popliteal vein is behind the artery, and sometimes the relationship is so intimate from adherence of their coats that ligation is rendered difficult. Behind the vein is the internal popliteal nerve. Thus, the relation of the

structures from before backward are artery, vein, nerve (Fig. 302).

Ligation of the popliteal artery is seldom performed except for wounds. In case of aneurysm the superficial femoral is tied. *Two causes render the ligation difficult: the external depth of the vessel and the intimate adhesions which connect it with the vein.* The simplest ligation is made in the upper part of its course by approaching it from the inner side. With the knee flexed and abducted a 3-in. incision is made parallel to and immediately behind the tendon of the adductor magnus, in the gap which can be felt with the fingers in front of the semimembranosus and gracilis. After the superficial and deep fascia have been incised, the tendon of the adductor magnus is drawn forward and the hamstring tendons backward. By working toward the back of the femur the pulsations of the artery will be felt. The vein lies behind and somewhat to its outer side. In passing the ligature the close relationship between the artery and vein must be kept in mind. The objection to an incision on the back of the limb for this ligation is the fact that the vein and the nerve lie on top of the artery and there is great difficulty in separating them.

Popliteal Aneurysm.—*The popliteal artery is more frequently the seat of aneurysm than any other artery of the body, with the exception of the thoracic aorta.* This is probably due to its location, which constantly subjects it, in walking, to alternate distention and relaxation. Forcible and sudden extension of the limb would undoubtedly throw an extra strain upon its coats, and while in the normal vessel no damage might result, yet, if the coats were diseased, they would, under such circumstances, rupture. The relations of the artery to the vein and nerve explain the edema of the leg from pressure on the vein and the pain from pressure on the nerve which follow in the wake of popliteal aneurysm. These factors also contribute to the production of gangrene. When the leg is forcibly flexed on the thigh, pulsations in the sac cease, and this attitude has been utilized as one of the procedures in curing popliteal aneurysm. Ligation of the superficial femoral, however, will give more exact results.

The **popliteal vein** lies immediately behind the artery to which it is intimately connected. Because of the thickness of its walls, its adherence to the artery, and its tendency to gape open after section, Tillaux says that it differs from all other veins. This hypertrophy of its walls is undoubtedly due to its

adaptation to function—alternate flexion and extension—caused by the movements of the limb.

At the upper part of the space it receives the *external saphenous vein*, which pierces the aponeurosis. This vein is much less frequently varicosed than the internal saphenous, because of the support it receives from the deep fascia.

The **internal popliteal nerve** is really a continuation of the sciatic. It is the larger of the two divisions and lies behind the popliteal vein. At the lower border of the popliteus it becomes the posterior tibial nerve.

The **external popliteal nerve,** about half the size of the internal popliteal, descends obliquely along the outer side of the popliteal space, across the external head of the gastrocnemius, accompanies the biceps tendon, and winds around the neck of the fibula, between the peroneus longus and the bone, dividing into the anterior tibial and musculocutaneous nerves. The danger of wounding this nerve in dividing the biceps tendon has already been mentioned. The same applies in resecting the head of the fibula. This nerve can be compressed as it winds around the neck of the fibula and is *one of the painful points in sciatic neuralgia.*

The **popliteal lymphatics** are four or five in number, lodged in the loose connective tissue in the depths of the space. These glands may enlarge and form an abscess from infection of the foot, and also become the seat of neoplasms which are difficult to diagnose, especially when they lie in the median line.

Synovial cysts of the popliteal space may follow—

(*a*) Chronic distention of the knee-joint, the internal pressure causing the synovial membrane to protrude through the weak spots in the capsule (Sutton). *These are the articular synovial cysts.* They occupy the median line and are soft and easily reduced when the leg is flexed.

(*b*) They may be due to bursæ which lie beneath the adjacent tendons and, becoming enlarged, communicate with the synovial cavity of the joint. They are most frequently associated with the semimembranosus bursa, and occupy the sides, especially the internal side. They are hard, resistant, and nonreducible.

The **knee-joint** is the most extensive and the most complicated articulation in the human body. It is a huge joint, depending for its strength not upon the bony conformation of the articular surfaces, but upon the powerful ligaments, the muscles, and fascia which surround it. The bones forming

the knee-joint are the femur, tibia, and patella. The lower end of the femur consists of two large eminences, the internal and external condyles. In front they merge together and

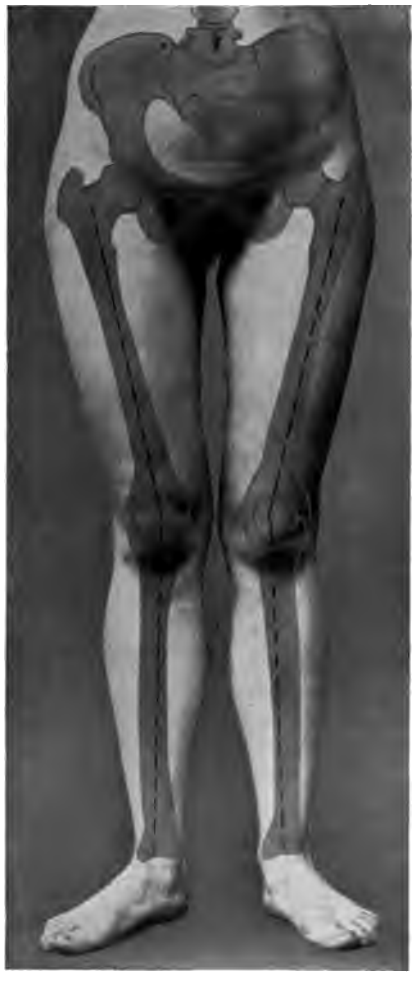

FIG. 303.—SHOWING THE OBTUSE ANGLE FORMED BY THE AXES OF THE FEMUR AND TIBIA.

form the trochlear surface, on which the posterior surface of the patella glides in flexion and extension of the leg. Behind, the condyles are separated by a large notch, the *intercondyloid notch,* to the sides of which the crucial ligaments are attached.

The internal condyle is narrower and longer than the external condyle. They are not on the same level, the internal being lower than the external. The articular surface of the tibia, however, is perfectly horizontal; hence, in the articulation between the femur and tibia it is necessary for the femur to meet the tibia at an angle in order that the two unequal condyles may rest on a horizontal plane. Thus, the axis of the femur and the axis of the tibia do not form a straight line, but a line broken at the level of the knee by an obtuse angle open externally (Fig. 303). This diminishes the pressure which would be produced if the bones were perfectly vertical.

The knee, therefore, naturally inclines inward. When this angle becomes exaggerated to the extent of a deformity, it produces a condition known as genu valgum or "knock-knee." Tillaux asserts that this is due not to feeble ligaments or to muscular contraction, but to a disproportionate development of the two condyles. The trouble is in the ossification of the femur, physiologic activity being greater in the internal condyle than in the external condyle. In estimating the degree of knock-knee the patient should be lying down, with the limbs fully extended and the two knees in contact. The amount of separation between the two internal malleoli measures the amount of deformity. The deviation is corrected when the two internal malleoli can be put together and the knees touch.

Genu valgum is treated by apparatus, suitable only for children before the fourteenth year; by forcible correction, by detaching the epiphysis, and by osteotomy for deformities of a pronounced type. Macewen's supracondyloid osteotomy is usually performed. It consists of a partial division of the shaft of the femur above the internal condyle, the operation being completed by forcible fracture. The limb is immobilized in the corrected position by a plaster splint.

Genu varum is the opposite of knock-knee. The knee bows out. It is caused by inequality in the development of the condyles of the femur and is almost exclusively found in children. In the milder forms it may be corrected by apparatus, but in the severe cases osteotomy is required.

Sarcoma sometimes develops in the condyles of the femur. It is more liable to occur during adolescence, and *in the early stages is with difficulty differentiated from tubercular knee.*

The head of the tibia is surmounted by an articular surface presenting two shallow cavities, separated by an osseous ridge—the spine of the tibia. These shallow cavities are deepened by

the *semilunar cartilages* (Fig. 304), two fibrocartilages, crescentic in form, placed on top of the articular surface of the tibia to deepen the cavities which receive the condyles of the femur. The outer margin is thick and tapers down to the inner edge, which is thin and sharp. The upper surfaces are concave for articulation with the condyles, their lower surfaces are flat and rest upon the head of the tibia (Gray). The semilunar cartilages are solidly fixed to the tibia and follow it in its various displacements.

The **patella** is a sesamoid bone developed in the tendon of the quadriceps extensor. It is covered posteriorly by cartilage and articulates with the anterior surface of the femur. It is a flat bone, triangular in shape, with the base above and the apex below. When the limb is extended the patella is movable,

FIG. 304.—THE SUPERIOR ARTICULAR SURFACE OF THE TIBIA, SHOWING (*A*, *A*,) THE SEMILUNAR CARTILAGES.

when it is flexed the tendon is taut and the patella is firmly held in the trochlear groove, acting as a protection to the articulation. A horizontal line passing around the knee at the apex of the patella corresponds to the interarticular line (Tillaux).

Cases of congenital absence of the patella are reported, but they are rare.

The **ligamentum patellæ** was originally a continuation of the quadriceps tendon. After complete ossification of the patella it becomes a distinct ligament. It is attached to the apex of the patella and inserted into the tubercle of the tibia supplying the place of an anterior ligament. The direction of the quadriceps tendon is that of the thigh, while the direction of the ligamentum patellæ is that of the leg; hence, there is

a similar obtuse angle formed at the patella as exists between the bones. In contraction of the quadriceps muscle this angle tends to correct itself and the patella is carried externally. The patella is prevented from frequent dislocation outward by the *lateral patellar ligaments,* which are prolongations of the fascia, and pass from the edges of the patella to the tibia and head of the fibula.

Fracture of the patella is almost always the result of muscular action. The patient stumbles, and in an effort to

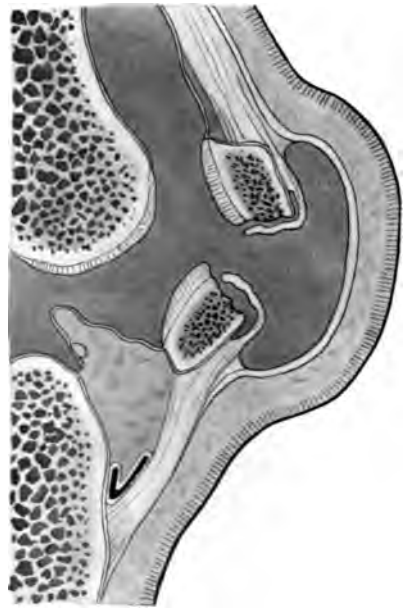

FIG. 305.—FRACTURE OF THE PATELLA BY MUSCULAR ACTION. Note the interposition of fibrous tissue between the fragments.

save himself from falling the patella is broken. Clearly there is no direct blow to the patella in such a case, but the quadriceps muscle is brought into sudden and violent contraction while the knee is partially flexed, a great strain is brought to bear on the patella as it pivots against the trochlear surface of the femur, and, as a result, it is broken just as a stick is broken over the knee.

These *fractures are always transverse,* somewhere between the apex and base. The lower fragment remains in place, the upper fragment is drawn up by the quadriceps muscle, and

considerable separation results, which is later increased by effusion into the joint. As the separation of the fragments takes place, the fascia on top of the patella is stretched, thinned out, finally torn; and falls in between the fragments, forming an interposition of fibrous tissue which is the cause of two important phenomena (Fig. 305):

(*a*) *It prevents bony union, unless removed.*

(*b*) *It prevents crepitus.*

In the treatment of fractures of the patella (caused by muscular action) *all forms of treatment except open operation must result in fibrous union, because of the fibrous curtain which has dropped between the two fragments.* Only open operation, removal of the fibrous curtain, and coaptation of the fragments can result in bony union.

Fracture of the patella occasionally occurs by direct violence—a direct blow or fall on the patella. In these cases the bone is comminuted, there is little or no separation of the fragments, no interposition of fibrous tissue between the fragments, crepitus is distinct, and open operation is not necessary to obtain good union. *It is a good rule in every case of obscure injury to the knee to exclude fracture of the patella before searching further.*

Dislocation of the patella is generally outward and is specially apt to occur in knock-kneed subjects. It is due to muscular contraction. The femur and leg normally form an angle at the knee, but the quadriceps contracts in a straight line; hence the tendency is to throw the patella outward. Occasionally the patella is dislocated on its edge. The internal or external lateral edge of the patella lies in the median depression between the condyles. While muscular action is undoubtedly the cause, no rational explanation has yet been advanced.

Occasionally *rupture of the ligamentum patellæ* occurs from violent contraction of the quadriceps. The ligament may be torn from its insertion in the tubercle of the tibia, at the patella, or at the middle. Suture of the tendon should be done. *Without treatment, function of the limb is seriously interfered with.*

The **posterior ligament** is a fibrous band attached above to the intercondyloid notch and below to the posterior margin of the head of the tibia. It is perforated by a number of apertures which give exit to the vessels and nerves of the joint.

The **lateral ligaments** are so attached that they are nearer

the posterior surface and thus check overextension. They are tense in extension and relaxed in flexion.

The **crucial ligaments** are two powerful interosseous ligaments, occupying the interior of the joint and situated nearer the posterior portion. They are so named because they cross each other like the letter X. These ligaments prevent displacements of the articular surfaces in an anteroposterior direction and especially check inward rotation of the leg. In tubercular knee these ligaments are altered or destroyed, so that latera movement and rotation of the leg is possible even when extended.

Internal derangement of the knee-joint is a form of disability which is characterized by sudden acute pain, "locking" of the knee in the flexed position, and loss of power in the limb. The most common causes of this condition are:

(*a*) Loose cartilages in the joint.

(*b*) Displacements of the semilunar cartilages.

Injuries to the semilunar cartilages are usually the result of a sudden twisting movement of the body, the internal semilunar cartilage being more frequently displaced than the external. This may possibly be explained by the fact that in movements of the body which cause rotation at the knee more weight is thrown upon the inner condyle than the outer. When a cartilage has once been displaced, it is apt to recur, and when the dislocation becomes habitual it may be necessary to remove the offending cartilage. *Removal of one of the cartilages does not interfere with the function of the joint.*

The *synovial membrane of the knee* is the largest and most extensive of all the articulations. It lines the capsule and structures within. It forms a short cul-de-sac between the quadriceps extensor and the femur, extending about 1 in. above the upper margin of the patella. To the top of the cul-de-sac is attached the *subcrureus muscle*, which pulls the serous membrane up in movements of extension and thus prevents it from being pinched. At its apex the synovial cul-de-sac communicates with the *suprapatellar bursa*, which lies between the quadriceps and the lower end of the femur. This bursa extends 2½ in. above the upper border of the patella when the limb is extended (Fig. 306). The suprapatellar bursa may exist independently, but this is the exception. Hence penetrating wounds entering 2½ in. above the patella practically open the knee-joint. On the sides the synovial membrane extends below the vasti muscles for about 3 in. It sends a prolongation to the tendon

of the popliteus muscle which sometimes communicates with the superior tibiofibular articulation. There are certain folds of synovial membrane which contain fat and serve as padding to fill up the spaces; among these are the *ligamentum mucosum,* which extends from below the patella to the intercondyloid notch, and the *ligamenta alaria,* extending from the sides of the ligamentum mucosum, between the patella and femur.

FIG. 306.—*A*, THE SUPRAPATELLAR BURSA; *B*, PREPATELLAR BURSA; *C*, LIGAMENTUM MUCOSUM; *D*, DEEP INFRAPATELLAR BURSA.

Synovitis.—*Inflammation of the synovial membrane is the principal pathologic process in diseases of the knee-joint.* Its chief characteristic is the serous effusion which takes place in the joint cavity, giving rise to pain, distention, flexion of the knee, and ankylosis.

Pain is severe only in acute processes where the effusion is rapid and the tension on the capsule is extreme. In chronic synovitis there is little pain, since the distention is gradual and the tissues, by degrees, adapt themselves to the new conditions.

Distention is marked by a bulging above the patella under the quadriceps, and on the sides of the patella and its ligament. The patella is carried forward from the trochlear surface and

"floats" on top of the fluid. Pressure backward on the patella, when the upper part of the joint is circumscribed by the flat of the hand, thumb, and fingers, accentuates the bulging, which is made to appear even when there is a small quantity of fluid.

Flexion of the knee to about 125° is the position the joint assumes when it is chronically distended with fluid, because—

(*a*) It is the position of maximum capacity of the joint.

(*b*) It relaxes the maximum number of ligaments—the posterior, crucial, and lateral ligaments.

(*c*) It may be caused by reflex irritation of the flexors, which, because of their advantageous attachment, are enabled to overcome the extensors and flex the joint.

Ankylosis.—The joint at first is maintained in the flexed position by the contracted muscles (false ankylosis); after a time it becomes fixed in this position by fibrous or bony consolidation (true ankylosis). *In all diseases of the knee-joint the limb should be immobilized in full extension, so that the function of the limb may be preserved, even if ankylosis occur.*

The synovial membrane of the knee is remarkable for the number of fringes which originate from its internal surface. These fringe-like processes enlarge, become cartilaginous, and are detached, giving rise to "floating bodies" which are carried to various parts of the joint, and in walking may be interposed between the articular surfaces, giving rise to sudden pain and disability. These loose cartilages should be removed when they become troublesome.

Tillaux has observed that traumatism of the knee with effusion is frequently accompanied by a great amount of atrophy of the quadriceps extensor. After the knee is apparently cured and the patient allowed to walk the effusion returns. When the patient is again put to bed, and upon disappearance of the effusion gets up to walk, the same thing recurs. The cause of this repetition of the effusion is muscular atrophy, which can be cured only by exercise and massage of the quadriceps muscle.

Fractures about the knee-joint which require special mention are—

(*a*) *Supracondyloid fracture of the femur* usually occurs at a point where the compact tissue of the shaft joins the cancellous tissue of the lower end, 1 or 2 in. above the base of the condyles. The deformity is quite characteristic, the lower fragment being tilted backward by the action of the gastrocnemius muscle; hence, treatment of the fracture in the extended

position is unsatisfactory. It is necessary to flex the leg to relax the gastrocnemius muscle, and if this is not sufficient, tenotomize the tendo Achillis and immobilize the limb upon a double inclined plane.

(*b*) *Separation of the lower epiphysis of the femur.* Recall the fact that the lower epiphysis joins the shaft in the twenty-first year, that it includes all of the articular surface of the lower end of the femur, with the attachments of the gastrocnemius muscle. This accident is due to great violence, and in a large number of cases has been produced by catching the leg in the spokes of a revolving wheel. The displacement of the epiphysis is usually forward. Sometimes the injury is compounded by the upper fragment protruding backward through the skin. Injury to the popliteal vessels has resulted in aneurysm and gangrene of the leg. The obstacle to reduction is usually the traction and tension of the muscles of the thigh which pull the head of the tibia against the upper fragment. If reduction cannot be accomplished by traction and manipulation it will be necessary to use the operative method and expose the fracture by incision. After reduction the leg should be immobilized in a flexed position to prevent recurrence. Whether shortening will occur after this injury it is impossible to prognosticate.

Dislocations of the Knee.—Although the bony conformation of the knee-joint is such as would seem to predispose it to dislocation, the ligaments and muscles which surround it are so strong that dislocation of the knee is rare. The displacement may be forward, backward, or lateral. As a rule, the crucial ligaments are ruptured and one or both lateral ligaments torn. The knee is more frequently dislocated forward, the patella and its ligament being a protection against backward displacement.

The popliteal artery is often severely injured in forward dislocations by the backward pressure of the femur, and gangrene of the limb has sometimes followed. Reduction of these displacements is not attended with any difficulty.

Excision of the Knee-joint.—In performing this operation three anatomic points of practical value should be remembered:

(*a*) The inner condyle is lower than the outer; hence, *in sawing the femur the obliquity of the joint surface should be preserved, to avoid a subsequent knock-knee or bow-leg.* Treves' rule is to apply the saw parallel to the articular surface and perpendicular to the shaft.

(*b*) The line of the femoral epiphysis is represented by a horizontal line drawn across the bone at the level of the tubercle for the adductor magnus. The line of the upper tibial epiphysis is indicated by a horizontal line just below the tuberosities, so as to include the attachment of the semimembranosus and the facet for the fibula. In front it slants down on each side to meet just below the tubercle (Woolsey). *In young subjects avoid the epiphyseal lines, or the subsequent growth of the bone may be interfered with.*

(*c*) The popliteal artery is in danger of being wounded. There is *some* interval between the artery and the posterior surface of the femur, but *only the posterior ligament intervenes between the artery and the upper level of the tibia.* Hence there is more danger of wounding the artery when sawing across the tibia than when removing the head of the femur.

(*d*) Ankylosis in the extended position is the result to be desired.

The lower end of the femur and the head of the tibia are favorite sites for the development of sarcoma.

CHAPTER XXX

THE LEG

THE **leg** is that portion of the lower extremity situated between the knee and the ankle. Its limit above is a horizontal line passing through the tuberosity of the tibia; below, the base of the malleoli. It is round and represents a truncated cone with the base above, a fact which presents certain difficulties in forming a cuff flap in amputation of the leg by the circular method.

The **skin** is more adherent at its under surface than that of the thigh, and it must be dissected rather than rolled back. The skin lies in direct contact with the crest of the tibia (the shin), which, because of its exposed position, is a frequent site of contusions characterized by their chronicity. A contusion which in another part of the body would be of little moment will at this point frequently form an ulcer which results in loss of substance and sometimes involvement of the periosteum and bone. These ulcers cicatrize slowly unless the limb is given complete rest.

The skin of the leg is predisposed to varicose ulcers, which usually occupy the inferior half. These ulcers are noted for their brownish cicatrix; they are shallow, sometimes adherent to the bone, and easily reopened if not protected.

In the subcutaneous cellular tissue are situated the internal and external saphenous veins and some nerve filaments.

The aponeurosis forms an incomplete cuff about the leg, the interval corresponding to the subcutaneous portion of the tibia. It is attached to the outer and inner tuberosities of the tibia, the head of the fibula, the anterior and inner borders of the tibia, and below, to the two malleoli. It is continuous above with the fascia of the thigh and below with that of the foot. The incomplete cuff is formed by the aponeurosis leaving the anterior border of the crest of the tibia, encircling the leg, and attaching itself to the internal border of the bone; thus, the subcutaneous portion of the tibia is deprived of aponeurosis.

From the under surface of the aponeurosis two intermuscular

septa are reflected inward and attached to the borders of the fibula, forming a compartment which contains the long and short peronei muscles.

The *interosseous ligament* extends between the external border of the tibia and the antero-internal border of the fibula.

The **muscles** in the anterior portion of the leg are subject to energetic contraction and compression against the deep fascia which binds them in place. If the fascia be torn, hernia of the muscle will follow. The muscles are thick above and terminate in tendons below, which are arranged in the following order from within out: (1) tibialis anticus; (2) extensor proprius hallucis; (3) extensor longus digitorum; and (4) peroneus tertius. The superficial muscles on the back of the leg are the gastrocnemius and soleus, forming the "calf of the leg," characterized by their thick bellies, which gradually disappear in a common tendon—the *tendo Achillis*—inserted into the posterior part of the os calcis. In front of these muscles is the deep transverse fascia which separates them from the deep muscles—the tibialis posticus, flexor longus digitorum, and the flexor longus hallucis. The outer portion of the leg is the peroneal region. The upper part corresponds to the peroneus longus, the lower part to the peroneus brevis.

The **vessels of the leg** consist of three large arterial trunks: the anterior and posterior tibials, and the peroneal. The popliteal artery bifurcates at the lower border of the popliteus muscle into anterior and posterior tibials. It is at the point of bifurcation of the popliteal artery that emboli are most prone to lodge and thus cut off the circulation in the leg and cause gangrene.

The main arteries of the leg are in close relation to the bones; the anterior and posterior tibials with the tibia, and the peroneus with the fibula. Hence in certain oblique fractures of the leg the sharp fragments of bone may injure the vessels.

The **anterior tibial artery,** one of the terminal branches of the popliteal, traverses the superior part of the interosseous space and appears in the anterior tibial region. It is deeply placed between the tibialis anticus and the extensor longus digitorum. It rests on the interosseous ligament, accompanied by its venæ comites, and the anterior tibial nerve which lies to its outer side. At the middle of the intermalleolar space it passes beneath the anterior annular ligament and continues as the *dorsalis pedis artery.*

The **posterior tibial artery** lies behind the tibialis posticus

and in front of the soleus. It passes down the back of the leg and terminates behind the internal malleolus, where it divides into internal and external plantar arteries. It is accompanied by its venæ comites and the posterior tibial nerve which lies to the outer side.

The **peroneal artery** is the smallest of the three arteries of the leg. It branches from the posterior tibial, 1 in. below the border of the popliteus. It passes down the back of the leg, along the inner border of the fibula, between the tibialis posticus and the flexor longus hallucis to the outer side of the os calcis, where it gives off its terminal branch, the external calcanean.

The formal ligation of the arteries of the leg is a dissecting-room exercise of little practical value. In case of hemorrhage the wound is enlarged and the two ends of the vessel ligated. In case of aneurysm the method of Antyllus is applicable—ligation of the arterial trunk above and below the sac, and extirpation of the latter.

The **veins of the leg** are important because of their predisposition to varices. The superficial veins occupy the subcuticular cellular tissue. The deep veins are situated between the muscular layers, and the two systems are connected by communicating branches. Some authors have held that deep varices always precede superficial varices, and that this accounts for the many failures in the operative relief of varicose veins. Tillaux states that the deep veins can undoubtedly be affected with varices, but the superficial group, especially those belonging to the internal saphenous vein, are most frequently affected, and affected singly.

Varicose Veins (Fig. 307).—Trendelenburg has shown that there are three steps in the pathology of varicose veins. The vein distends, little by little, the walls thicken, the valves become effaced, and the vein is transformed into a rigid tube, firm to the touch and remaining open when cut. In this condition the blood in the vein is subjected to pressure from the entire column of blood situated above; hence the venous blood not only finds it difficult to return to the center, but is forced back to the peripheral capillaries, which thin out and give rise to insidious hemorrhages. The blood stasis gives rise to trophic changes, the principle of which is manifest in varicose ulcer.

The vein most frequently affected is the *internal saphenous*, which begins in an arch on the dorsum of the foot and passes up in front of the internal malleolus and along the inner side of

the leg to the inner and back part of the knee and up the inner side of the thigh between the two layers of superficial fascia, passing through the saphenous opening to terminate in the femoral vein.

The treatment of varicose veins of the leg aims to diminish or abolish the blood-pressure. This is accomplished, indirectly, by compression with bandages, elastic stockings, etc.; directly, by resection of the vein.

FIG. 307.—VARICOSE VEINS OF THE LEG.

The **bones of the leg** are the tibia and fibula, united by the interosseous ligament. The tibia forms the main support and transmits the weight of the body to the foot. It is largest at its extremities and smallest at the junction of its lower and middle thirds. It may be compared to two elongated cones joined at their apices, which correspond to the junction of the lower and middle thirds. Here the bone is least resistant and fracture most frequently occurs.

The fibula is a slender bone of about the same proportion throughout. It reinforces the tibia, provides for muscular

attachments, and forms with the tibia an important mortise for the ankle-joint.

Fractures of the Bones of the Leg.—The narrowest portion of the tibia is at the junction of the middle and lower thirds of the shaft; hence it is the weakest spot and the point of frequent fracture. As a rule, both bones are broken together, the fibula at a little higher level than the tibia. When separate bones are broken it is usually the fibula.

Because of the subcutaneous situation of the bones of the leg compound fracture is more frequent here than in any other part of the extremities. It is a common occurrence in oblique fractures to have the sharp fragment puncture the skin without extensive laceration. In applying a splint after reduction the proximity of the bone to the skin demands special attention to the padding in order to avoid pressure necrosis of the skin and subsequent conversion of a simple into a compound lesion by ill-fitting splints.

Fractures of the leg by direct violence exhibit only those features common to fractures in general. Fractures of the leg by indirect violence may present many points of anatomic interest. Tillaux asserts that these indirect fractures may be caused by (*a*) flexion, as when a man standing on a ladder falls backward and catches his foot between the steps of the ladder, in which case his trunk plays the part of a lever, and there results an indirect fracture by flexion. Such fractures are transverse, both bones being broken on the same level. They present little tendency to displacement, the skin is never involved, consolidation is rapid, and the result satisfactory. They may be be caused by (*b*) torsion, as when a man standing upright suddenly turns his body, while the leg is immobile, a fracture is sometimes produced which is complicated and difficult to treat. The point of election is the lower third of the leg, the fibula being broken at a higher level. The fragments are broken obliquely from behind forward, causing them to easily glide over each other; the sharp ends may compound the lesion by puncturing the skin. The lower end of the upper fragment produces a prominence beneath the skin if it does not puncture, and there is some angular deformity caused by the lower fragment being drawn up by the muscles of the calf. These fractures present difficulties in reduction and retention. Reduction under anesthesia, by extension and counterextension, and retention by a plaster splint are the most satisfactory methods of treatment. In oblique fractures of the leg it is usual to get

some shortening. In reducing fractures of the leg it is well to remember that the inner edge of the patella, the internal malleolus, and the inner side of the great toe should be in the same vertical plane.

The tibia is frequently the site of *acute osteomyelitis*, usually preceded by contusion. It produces grave constitutional symptoms, which have been mistaken for typhoid. Early intervention is essential to save the life of the patient and prevent the production of sequestra which may extend the length of the bone.

Bone abscess more frequently attacks the extremities of the tibia than any other bone of the body. It is usually of tubercular origin (Brodie's abscess).

The tibia is subject to rachitic curvature occurring in the lower third of the bone and usually producing a curvature outward.

Syphilitic affections of the tibia are rather common, manifesting themselves in the form of chronic osteitis and periostitis. The typical nodes on the shaft of the tibia are due to periosteal thickening.

Sarcoma of the tibia is not rare. It occurs more frequently in the upper than in the lower end and its course is not so rapid as in the femur (Sutton).

CHAPTER XXXI

THE ANKLE AND FOOT

THE **ankle** refers to the articulation between the leg and the foot and the soft parts surrounding it, composed exclusively of tendons. Surgically, the region of the ankle extends two fingers'-breadths above and below the malleoli. The region is noted for its many prominences and depressions. In front are seen the extensor tendons of the toes; behind, the tendo Achillis; and on the sides the internal and external malleoli. On each side of the tendo Achillis is a deep depression. These depressions are obliterated in sprains, synovitis, and effusion in the joint. The skin is in immediate contact with the bone, and care must be used in the application of bandages that they do not produce pressure necrosis or gangrene.

The subcutaneous tissue is not thick except on the sides of the tendo Achillis. Over the malleoli it is very thin and devoid of adipose tissue. It contains the internal saphenous vein in front of the internal malleolus, and the external saphenous vein behind the external malleolus. The deep fascia is continuous above with that of the leg, below with that of the foot. It is firmly fixed to the sides of the malleoli and blends with the periosteum. At the ankle the fascia thickens and forms three distinct bands which serve to keep the tendons in contact with the bone, as follows:

The **anterior annular ligament** consists of two parts: a superior or transverse portion, and an inferior or Y-shaped portion, connected by an intervening layer of fascia. The upper transverse band stretches across from the tibia to the fibula. It contains a synovial sheath for the tendon of the tibialis anticus; the other tendons, vessels, and nerves pass beneath it. The lower Y-shaped band is attached externally to the upper surface of the os calcis; as it passes in front of the joint the two limbs of the Y diverge, the upper being attached to the internal malleolus, the lower being fused with the plantar fascia. This ligament forms distinct compartments for the tendons which pass beneath.

The **external annular ligament** extends from the extremity of the external malleolus to the outer surface of the os calcis and bridges over the peronei tendons which pass beneath in a common synovial sheath.

The **internal annular ligament** extends from the internal malleolus to the internal margin of the os calcis. It forms four canals lined with synovial membrane for the tendons which pass beneath.

In the *anterior region of the ankle* are four tendons, from within out, the tibialis anticus, the extensor proprius hallucis, the extensor longus digitorum, and the peroneus tertius. In addition there are the anterior tibial artery, vein, and nerve. The tendons are held in place by the anterior annular ligament. Beneath this ligament are three partitions lined with synovial membrane. The external is occupied by the extensor longus

FIG. 308.—VARIETIES OF CLUB-FOOT.
A, Talipes calcaneus; *B*, talipes varus; *C*, talipes valgus; *D*, talipes equinus.

digitorum, and the peroneus tertius, the middle by the extensor proprius hallucis, and the internal by the tibialis anticus. Sometimes the tendon of the tibialis anticus passes over the annular ligament, in which case it forms a prominent relief on the dorsal surface of the foot. If the muscles be affected with contraction, there may be produced a condition of *talipes calcaneus* (Fig. 308, *A*)—characterized by extreme flexion of the foot, so that it rests on the ground only by its heel. If, in addition, the foot is turned inward by the action of the tibialis anticus, it is a *talipes varus* (Fig. 308, *B*). If the foot is turned outward by the lateral peronei, it is a *talipes valgus* (Fig. 308, *C*). Talipes calcaneus is much rarer than *talipes equinus* (Fig. 308, *D*) (where patients walk on the toes). To correct this condition it may be necessary to section the tendons.

The artery in front of the ankle is the *anterior tibial*, which occupies the middle of the intermalleolar space lying between

the tendons of the extensor propius hallucis and the extensor longus digitorum. At the bend of the ankle it becomes the *dorsalis pedis artery*, and at the lower level of the annular ligament it furnishes the internal and external malleolar branches. The anterior tibial nerve accompanies the artery lying to its outer side.

The posterior region of the ankle consists of the tendo Achillis, and the retrocalcaneal bursa.

The **tendo Achillis** is a large flat tendon, common to the gastrocnemius and soleus muscles, inserted into the posterior surface of the os calcis. It extends the foot on the leg. In walking it raises the heel from the ground.

Rupture of the tendo Achillis has occurred from sudden contraction of the "calf muscles." It gives way, not at the point where it is attached to the bone, but about 1½ in. above its insertion. In treating this condition it is not usually necessary to suture the tendon, since the ends of the tendo Achillis may reunite by immediate fibrous tissue, over an interval of 2 in. It will be necessary, however, to immobilize the foot in extension and the leg in flexion. The tendo Achillis plays an important part in the production of *club-foot*. When it is contracted it holds the foot in permanent extension so that the toes come in contact with the ground—*talipes equinus* (Fig. 308, *D*). Tillaux has called attention to the fact that sometimes the tendo Achillis is congenitally too short to permit full flexion of the foot. The foot can only be flexed to a right angle. In the early years the walk is nearly normal, because the extensor longus digitorum compensates, to a certain extent, for the short tendo Achillis; however, the toes are pulled, little by little, on the metatarsals, especially the great toe, and a veritable subluxation occurs. The extensor longus digitorum becomes fatigued and unable to overcome the resistance of the tendo Achillis, and the patient walks more and more on the front of the foot. At the same time there is a deviation inward and a condition of *talipes equinovarus* is produced, the patient walking on the outer side of the foot with the heel drawn up. To remedy this condition it is necessary to cut the tendo Achillis, and sometimes the tibialis anticus and plantar fascia; in fact, every structure should be divided which prevents the foot from assuming the normal position.

Tenotomy of the Tendo Achillis.—The tendon may be divided subcutaneously about 1 in. above its insertion. Care should be exercised not to wound the posterior tibial vessels and

nerve, which lie on the inner side of the tendon and are separated by a sufficient interval to insure their safety. The foot is flexed so as to make the tendon stand out. The knife is introduced flat on the inner side, between the skin and tendon, and the cut made carefully from without in. The tendon can be felt to give way as the ends separate.

If section of the tendo Achillis is not sufficient to restore the foot to its normal position, the cause should be discovered and the constricting tissues divided. Sometimes the plantar fascia is the cause of the foot rolling in. In such a case the fascia should be stretched and divided at its most prominent point. If the operation is done in the early years, section of the soft parts may be sufficient to restore the foot to its normal position; if done late it may be necessary to resect some of the tarsal bones.

The **retrocalcaneal bursa** lies between the tendo Achillis and the posterior surface of the os calcis. In those who do much walking it may become inflamed, giving rise to a bursitis, which produces a swelling on the sides of the tendon.

The *internal region of the ankle* is limited by the internal malleolus in front and the tendo Achillis behind, and bridged over by the internal annular ligament. Thus there is formed an osteofibrous canal through which pass all the important structures which go to the sole of the foot. They are, in order, from within out: the tendons of the tibialis posticus and flexor longus digitorum, the posterior tibial artery with its venæ comites, the posterior tibial nerve, and the tendon of the flexor longus hallucis (Fig. 309). The tendons of the muscles are contained in special sheaths lined with synovial membrane, which sometimes becomes inflamed, giving rise to synovitis with effusion. It is frequently tubercular in origin and may ultimately infect the tibiotarsal articulation and cause grave results.

The **posterior tibial artery** occupies the middle of the space between the posterior border of the internal malleolus and the tendo Achillis. It is accompanied by its venæ comites and lies between the tendons of the flexor longus digitorum and the flexor longus hallucis. The posterior tibial nerve lies behind the artery, which at the lower level of the space it divides into internal and external plantar arteries.

The *external region of the ankle* contains the tendons of the peroneus longus and brevis, and the peroneal artery. The tendons pass behind the external malleolus in a common sheath invested by a common synovial membrane. In their inferior

attachment the brevis goes to the metatarsal bone of the little toe, the longus crosses the sole of the foot obliquely, and is attached to the metatarsal bone of the big toe. It is, therefore, an important agent in maintaining the transverse arch of the foot.

The tendon of the peroneus longus is frequently dislocated by the rupture of its tendon sheath. It may be

FIG. 309.—STRUCTURES BEHIND THE INTERNAL MALLEOLUS.
A, Tendon of tibialis posticus; *B*, tendon of flexor longus digitorum; *C*, posterior tibial artery; *D*, posterior tibial nerve; *E*, tendon of flexor longus hallucis.

necessary to anchor it by suturing the sheath or chiseling a groove for it behind the malleolus.

The synovial membrane of the peronei tendons is subject to inflammation. Tubercular synovitis sometimes develops and extends to the tibiotarsal joint. It is a curious fact, observed by Tillaux, that tubercular synovitis develops much more frequently in the tendons which are alongside of the malleoli than those which pass in front of the ankle.

The **tibiotarsal joint** is formed by the upper convex surface of the astragalus being mortised between the two malleoli. The tibia forms the greater part of the mortise and the external malleolus descends about 1 cm. lower than the internal. The anterior and posterior ligaments are unimportant. The *internal lateral* or *deltoid ligament* consists of a thick, flat, triangular fascia attached above to the inner malleolus and below to the scaphoid, the sustentaculum tali, and the inner side of the astragalus. This ligament is so thick and strong, that in sudden strains it is the malleolus that is detached rather than the ligament itself (see Pott's fracture).

The *external lateral ligament* consists of three distinct fasciculi, sometimes described as separate ligaments. They are attached above to the outer malleolus, the anterior and posterior bands go to the astragalus, the middle band passes downward to the os calcis.

The joint is lined with synovial membrane. Fluid within the joint is discovered with difficulty because of the tendons which surround it.

Tubercular osteo-arthritis is not rare, occurs most frequently in adults, and follows injury. As the disease progresses, the question of resection or amputation will arise. An excellent rule to follow in operations about the ankle is:

Resection in traumatism and amputation in disease. In tubercular invasion of the tarsus resection is impractical because the process involves neighboring articulations; there is no certainty that all the diseased tissue has been removed; it is difficult to preserve a useful foot; there is usually a long course of suppuration following resection, which is a menace both to the cure and the patient.

In amputation the disease is removed at once and convalescence is rapid.

In amputation at the ankle it is important to preserve the skin of the heel with its vessels, so that the patient may have a satisfactory surface for contact with the ground. In the study of injuries about the ankle-joint there are several points of anatomic interest which contribute to their proper appreciation.

(*a*) There normally exists no lateral movement in the tibiotarsal joint.

(*b*) When lateral movement is present it points to fracture of the malleoli or injury or disease of the ligaments.

(*c*) Lateral movement in the tibiotarsal joint following traumatism is an indication of fracture of the malleoli.

Pott's fracture is a fracture involving the fibula and ankle-joint, and presenting a symptom-complex of great anatomic interest (Fig. 310). This injury is caused by a twist or forcible eversion of the foot, and presents the following characteristics:

FIG. 310.—POTT'S FRACTURE.

1. As the foot is everted, the first structure to feel the strain is the internal lateral ligament. This ligament, it will be remembered, is thick and strong, and instead of rupturing, it tears off the internal malleolus.

2. As the strain continues, the external malleolus is forced

outward, and the bone yields at its weakest point, viz.: the shaft of the fibula just above the malleolus.

There are, therefore, two actual fractures:

(*a*) The internal malleolus.

(*b*) The fibula, at a point from 1 to 3 in. above the malleolus.

There result from this injury *five characteristics which constitute the symptom-complex:*

1. Outward displacement of the foot.
2. Prominence of the internal malleolus.
3. Depression over the fibula, 1 to 3 in. above the malleolus.
4. Widening of the joint.
5. Backward displacement which produces shortening of the foot and lengthening of the heel.

Stimson asserts that there are *three points of tenderness,* which are constant and characteristic:

(*a*) At the internal malleolus.

(*b*) Over the fibula at the site of fracture.

(*c*) In front of the inferior tibiofibular ligament at its point of rupture.

In the reduction of this fracture great care should be exercised to press the foot forward and inward and retain it in this position. If this precaution is not observed, the injury may result in great subsequent disability to the patient, since in outward or backward displacement of the foot the weight of the body is brought far to the inner side and a strain is placed upon the internal lateral ligament which causes pain and fatigue.

The foot in many respects is analogous to the hand. It differs by forming a right angle with the leg, so as to furnish a broad base of support for the weight of the body. When the foot ceases to occupy a horizontal plane, walking becomes diffiult or impossible. Hence in the treatment of surgical affections of the feet the aim should be to maintain the foot at a right angle to the leg; for what mobility is to the hand, solidity is to the foot. The skin on the dorsal surface is thin and mobile, and less sensitive than the plantar. It is easily excoriated and becomes callous under pressure. The subcutaneous tissue is loose and abundant, and contains the superficial vessels and nerves. It is easily infiltrated, and becomes rapidly edematous under certain conditions.

The *veins* are numerous and form arches, from which the internal and external saphenous take their origin. They may be the site of varicosities in those affected with varicose veins.

The aponeurosis is continuous above with that of the

leg, and beneath it are found the tendons already noted in front of the ankle: the tendon of the tibialis anticus, passing to its insertion in the base of the metatarsal bone of the great toe and the contiguous surface of the internal cuneiform; that of the extensor proprius hallucis to the base of the last phalanx of the great toe, and the tendons of the extensor longus digitorum to each of the four outer toes.

The **dorsalis pedis artery** is a continuation of the anterior tibial at the bend of the ankle. It terminates at the first intermetatarsal space, where it gives off a communicating branch, which anastomoses with the external plantar and forms the plantar arch. It lies external to the tendon of the extensor proprius hallucis, which is a guide to the artery. The anterior tibial nerve is to the outer side.

The **lymphatics** on the dorsal surface form a rich network, which communicates with the trunks accompanying the internal saphenous vein.

The **plantar surface** of the foot is normally concave and does not rest on the ground at all points, the concavity being especially well-marked at its internal border. Furthermore, at the plantar surface are three principal points of support for the weight of the body: (*a*) the heel, (*b*) the head of the first metatarsal, and (*c*) the head of the fifth metatarsal. These three points constitute the pillars of the *pedal arch.* When the pedal arch is broken down so that the plantar surface of the foot rests at all points on the ground, there results a condition of *flat-foot,* which gives rise to pain and disability, the bony anatomy of which will be discussed later.

The *plantar skin* is very sensitive and very thick, especially at the pillars of the arch. In people who walk much it is the site of callosities. Beneath these callosities there sometimes develop mucous bursæ which inflame and suppurate and form fistulæ, penetrating a sufficient depth to affect the bone or even extending to the dorsal surface, and giving rise to a peculiar affection—*perforating ulcer of the foot,* characterized by an ulceration on the sole of the foot which makes its way through the fascia, muscles, tendons, and the metatarsal spaces to the dorsal surface. Many causes have been assigned in considering the pathology of this affection, such as circulatory changes due to atheroma or trophic disturbance. Tillaux believes that it is previously caused by a malformation of the foot, congenital or acquired, which causes unequal pressure on the arch and brings about the formation of mucous bursæ, which suppurate and

form fistulous tracts. He believes that many of these cases get well with complete and prolonged rest, and that amputation should not be considered until rest has been well tried.

The *plantar subcutaneous tissue* is dense and resembles that of the scalp and palm. It is characterized by fibrous septa between which are pellets of fat. It does not retract when cut and the bleeding points are difficult to clamp and ligate. When foreign bodies, such as needles or glass, penetrate the sole of the foot they are very difficult to extract, although previously located by the *x*-ray, because of the density of the tissue, which does not permit the edges of the wound to separate, and its tendency to bleed. Much larger incisions than the size of the foreign body would warrant must be made in order to obtain satisfactory exposure.

The **plantar fascia** is the densest fascia of the body and extends from the os calcis to the roots of the toes and from the internal to the external borders. It is triangular, with the apex behind and the base in front, and is divided into a central and two lateral portions. The *central portion* is the most important and strongest of the three. It is narrow behind and attached to the inner tubercle of the os calcis. Near the heads of the metatarsal bones it divides into five processes, one for each toe. Like the cord of a bow it suspends the longitudinal arch of the foot from the os calcis to the metatarsal heads, and is an important factor in preventing the arch from sinking and producing flat-foot. When it is contracted, as in equinovarus, the arch is exaggerated and the foot flexed and rolled in. In such conditions the deformity is corrected by section of the plantar fascia. The *outer portion* of the plantar fascia extends from the os calcis to the base of the fifth metatarsal. It is continuous with the central portion and the dorsal fascia. The *inner portion* is attached behind to the internal annular ligament and is continuous with the central portion and dorsal fascia. At the lateral borders of the central portion are given off two intermuscular septa, which separate the middle from the internal and external plantar groups of muscles, and divide the plantar region into three compartments. The internal lateral compartment corresponds to the thenar eminence and contains the muscles of the big toe; the external compartment corresponds to the hypothenar eminence and contains the muscles of the little toe. The central compartment contains the most important structures. In addition to the common flexors of the toes it contains the plantar vessels and nerves.

The Plantar Arteries (Fig. 311).—The *external plantar artery* is really a continuation of the posterior tibial. It courses from its origin obliquely across the plantar surface to the base of the fifth metatarsal bone, turns obliquely inward and reaches the posterior extremity of the first intermetatarsal space, where it anastomoses with the communicating branch of the dorsalis pedis and forms the *plantar arch* (Fig. 312). This anastomosis brings the anterior tibial artery into communication with the posterior tibial artery. It will be observed that the plantar arch differs from the palmar arch in the fact that the former is a vertical anastomosis, while the latter is a horizontal one.

The *internal plantar artery* is smaller than the external. It is like a collateral branch and at its termination furnishes an artery to the great toe.

From the convexity of the plantar arch are given off five branches which form the collateral branches of the toes, and in addition the perforating branches which traverse the interosseous spaces.

The *lymphatics* of the sole of the foot are very numerous. Most of them go to the glands of the groin; a few pass to the glands of the popliteal space.

FIG. 311.—THE PLANTAR ARTERIES.
A, The external plantar artery; *B*, the internal plantar artery.

The **bones of the foot** are composed of the tarsals and metatarsals. The tarsal bones are seven in number, arranged in two rows, the astragalus and os calcis behind, the scaphoid, cuboid, and three cuneiform in front. These bones are so arranged that they form two arches, one transverse, the other anteroposterior. The astragalus forms the keystone of the

arch, not because of its shape, but because the tibia resting directly upon the astragalus throws the entire weight of the body upon it, and the astragalus transmits it behind to the os calcis, and in front to the scaphoid and cuneiform bones. This arrangement of the bones of the foot in an arch gives it great elasticity, decomposes the sudden shocks to which the foot is

FIG. 312.—THE PLANTAR ARCH.
Note that it is formed by the external plantar artery anastomosing with a branch of the dorsalis pedis.

frequently subjected, and provides a concavity which lodges the vessels and nerves and protects them from pressure in the vertical position (Fig. 313).

Flat-foot occurs in people whose occupation compels them to be on their feet a great deal, and is the result of a flattening out of the longitudinal arch (Fig. 314). As already stated,

FIG. 313.—THE BONES OF THE FOOT FORMING THE PEDAL ARCH.

the sole of the foot does not normally rest on the ground at all points. The points of contact are the three pillars of the arch, the os calcis, the head of the fifth metatarsal, and the head of the first metatarsal bones. These three points are all abundantly covered by cellular tissue to protect them from pressure. When from too constant strain the ligaments are

overstretched, they finally relax, the arch breaks down, and the entire plantar surface comes in contact with the ground, bringing pressure upon points that are not adapted to withstand it, throwing the joint surfaces out of line and giving rise to a condition which produces pain and fatigue when the patient walks. The pain of flat-foot is due to overstretching of the ligaments and ceases when the patient is in repose. The changes in the appearance of the foot are very marked. The concavity on the inner side of the foot is obliterated, and the foot is lengthened and broadened. In severe cases the patient walks on the inner side of the foot. The yielding of the calcaneoscaphoid, the long and short plantar ligaments, the plantar fascia, and the tendons of the anterior and posterior

FIG. 314.—FLAT-FOOT.

tibials and peroneus longus result in the foot becoming abducted and everted.

The treatment of flat-foot consists in rest and the wearing of a steel plate inside the shoe to support the arch.

Morton's metatarsalgia is characterized by pain localized in the head of the fourth metatarsal bone. It begins when the shoe is put on and disappears in repose. It is caused by pinching of a nerve between the fourth and fifth metatarsals and is usually associated with flat-foot. It may be necessary, in severe cases, to resect the head of the fourth metatarsal bone.

The **mediotarsal joint** (articulation of Chopart) is composed of two articulations, one formed by the articulation of the os calcis with the cuboid, the other by the articulation of the astragalus with the scaphoid. This joint is the site of most

of the partial movements of the tarsus and consists of a sort of rotation and circumduction. It is through this joint that Chopart's amputation is performed (Fig. 315).

The **tarsometatarsal joint** (articulation of Lisfranc) is formed by the cuboid and the three cuneiform bones articulating with the posterior extremities of the five metatarsal bones. The interarticular line is irregular, the second metatarsal bone, as it articulates with the middle cuneiform, being deeply wedged in between the internal and external cuneiform, forming one of the principal difficulties in Lisfranc's amputation, which is made through this articulation (see Fig. 315).

The landmarks of the joint are the posterior extremity of the fifth metatarsal bone, which is the most prominent point on the external border of the foot and always appreciable to the

FIG. 315.—THE TARSAL AND METATARSAL DISARTICULATIONS.
A, Chopart's disarticulation; *B*, Lisfranc's disarticulation.

touch. On the internal border the point is 3 cm. in front of the tubercle of the scaphoid, which is easily found.

Fractures and Dislocations at the Ankle.—The ankle is an articulation of great strength, because of its bony conformation and the many ligaments and tendons which surround it. The astragalus is mortised between the two malleoli above, the os calcis below and behind, and the scaphoid in front. These injuries are usually caused by indirect violence, the principal factor being forced movements of the foot.

The ultimate lesion depends upon the intensity and direction with which the force acts upon the foot. In slight injuries a sprain results; the ligaments being overstretched or ruptured. In severer types the ligament does not give way, but pulls off one of the malleoli, the result being a combination of sprain and fracture. In other cases the ligaments are ruptured, the ankle dislocated, and the tibia or fibula fractured as typified in a Pott's fracture (see pages 627 and 628). *Hence the ankle-*

joint, more than all others, is subject to complex lesions following injury.

The *lateral dislocations* are always associated with fracture of the tibia or fibula. The result of an outward dislocation is shown in a Pott's fracture. Inward dislocation is extremely rare because the direction of the dislocating force is opposed by the natural direction of the foot which is toward abduction rather than adduction. Usually the external malleolus is torn off. It is worth noting that the deformity associated with this injury is so slight that it is apt to be mistaken for a sprain.

The *anteroposterior dislocations* are not so common as the lateral variety. They are usually produced by severe violence when the foot is fixed in overextension or flexion, and are associated with extensive laceration of the ligaments and fracture of one or both malleoli. Forward luxation is extremely rare and some authors believe that it is never complete.

Dislocation of the astragalus is produced by violent pressure, as in a fall from a great height. The astragalus being expelled "as a kernel is pressed between the fingers."

The bone lies on the dorsum of the foot, producing a prominence beneath the skin, which it sometimes ruptures, or by pressure causes it to become gangrenous. If there be no wound present, an effort may be made to reduce it, although this is rarely possible. Prompt extirpation is then the only recourse. The results of operation are usually excellent.

The os calcis is the most frequently fractured of the tarsal bones. The injury is usually caused by a fall upon the heel; rarely, it is caused by muscular action through the tendo Achillis. These fractures are usually comminuted, the symptoms are obscure, the swelling is considerable, crepitus is frequently absent, and diagnosis often difficult. Stimson suggests that the deformity of the heel is best recognized when compared with its fellow from behind, while the patient is kneeling.

Fracture of the astragalus alone may occur by a fall upon the feet, but is usually associated with fracture of the os calcis or with dislocation of the ankle and fracture of the fibula. Fracture of the astragalus without displacement may frequently be mistaken for sprain of the ankle.

Disease of the Tarsus.—The tarsal bones are spongy in character and separated by synovial cavities; hence they are liable to be the focus of inflammatory changes after slight traumatism and the synovial cavities tend to diffuse the disease

among the adjoining bones. *Tubercular disease is by far the most common chronic inflammation in this region.* It usually begins as an osteomyelitis of the astragalus and spreads to the neighboring bones. It is insidious in its onset and may not be diagnosed until fistulous tracts have made their way to the dorsal surface and extensive destruction occurred. The value of excision in diseased conditions of the tarsus is debatable, because of the difficulty of being certain that all the diseased tissue is removed, and a useful foot preserved. Many surgeons advocate amputation as more certain and satisfactory.

Amputations of the Foot.—In considering the subject of amputations of the foot the surgeon can have no better rule for his guidance than that "the patient should be given the stump best adapted to the most useful artificial limb." This is the prime consideration, and in the attainment of this result the following rules are indispensable.

(*a*) Form the flap from the sole of the foot. The thick skin and the abundant subcutaneous tissue make an excellent cushion for withstanding pressure.

(*b*) Place the cicatrix so that it will not be subjected to undue pressure, toward the side, and not at the end of the stump.

(*c*) Preserve the muscular balance so that there will be no subsequent deviation of the stump by secondary muscular retraction.

(*d*) Sever the nerves high enough, so that their ends will not be incorporated in the cicatrix and produce stump neuroma.

There are many classical amputations of the foot, and the following are discussed because of their anatomic interest, the details of the technic being purposely omitted.

Lisfranc's amputation is a disarticulation of the metatarsotarsal joint with a short dorsal and long plantar flap (see Fig. 315); as already noted, this interarticular line is very irregular. In making the disarticulation the principal difficulty is the head of the second metatarsal bone which is wedged in between the internal and external cuneiforms. The interarticular line on the external border is just behind the tuberosity of the fifth metatarsal, a prominence which is easily felt; on the internal border it is 1½ in. in front of the tuberosity of the scaphoid. While the insertion of the tibialis anticus into the base of the first metatarsal is destroyed, its insertion into the internal cuneiform remains, and the muscular balance is thus preserved.

Chopart's amputation disarticulates through the mediotarsal joint, having previously provided a short dorsal and a long plantar flap (see Fig. 315). The interarticular line is located by drawing a line across the dorsum of the foot, beginning just behind the tubercle of the scaphoid and terminating about 1 in. behind the tuberosity of the fifth metatarsal. This operation is not to be commended because of the retraction of the tendo Achillis, which causes the stump to deviate and the patient to walk on the cicatrix. Even tenotomy of the tendo Achillis does not always obviate this tendency.

Syme's amputation consists in the removal of the entire foot and the projecting ends of the malleoli. The flap is formed from the heel, from which the os calcis has been shelled. The vitality of the flap depends upon the preservation of the internal calcaneal branches of the posterior tibial and the external calcaneal branches of the peroneal. This is best conserved by hugging the os calcis when the dissection is being made. *This is the most practical amputation of the foot, and provides one of the most serviceable stumps.*

Pirogoff's amputation is an osteoplastic modification of Syme's. The posterior portion of the os calcis is left in the heel flap and its sawed surface is placed in contact with that of the tibia.

The objection to this method is the tendency of the fragment to become displaced by the retraction of the muscles of the calf and the tendency of the fragment to necrose or fail to unite.

The **toes** are in many respects analogous to the fingers, as, for example, in the number of phalanges, the arrangement of the soft parts, and the attachments of the flexor and extensor tendons. The short flexors of the toes correspond to the flexor sublimis digitorum, the four tendons dividing into two slips at the bases of the first phalanges to allow the passage of the corresponding flexor longus digitorum, and being inserted into the sides of the second phalanges, about its middle.

The long flexors correspond to the profundus digitorum. The tendons are inserted into the bases of the last phalanges of the four lesser toes, each tendon passing through a slit in the flexor brevis digitorum.

The extensor longus digitorum divides into four tendons, which pass across the dorsum of the foot and are inserted into the second and third phalanges of the four lesser toes. Each of the three inner tendons is joined opposite the metatarsophalangeal articulation by a tendon from the extensor brevis

digitorum. All the tendons receive fibrous expansions from the lumbricales and interossei.

Deviations of the Toes.—Sometimes the toes are *hyperextended* on the *metatarsals*, which would naturally be considered due to a contraction of the extensor tendons. Tillaux claims that it is due to a tendo Achillis too short to permit complete

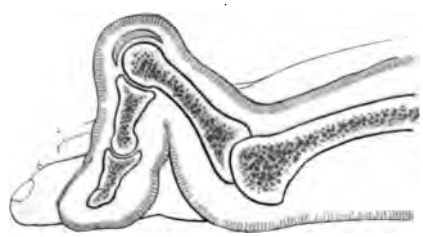

FIG. 316.—HAMMER-TOE.

flexion of the foot on the leg. The patient, to counterbalance the resistance of the tendo Achillis, brings in play the action of the flexors of the foot, which are the extensors of the toes, enabling the heel in this way to touch the ground. This gradually brings about hyperextension of the toes and a resulting subluxation on the metatarsals.

FIG. 317.—HALLUX VALGUS.

Hammer-toe (Fig. 316).—In this deviation the third phalanx is completely flexed on the second and directed downward so that the toe touches the ground at its free extremity. The second toe is the one most frequently affected. It is caused by wearing too short shoes. Pressure of the shoe often causes

a callosity, which inflames and suppurates. It may be necessary to resect or amputate to effect a cure.

Hallux valgus is a deviation of the great toe externally (Fig. 317). At times it overlaps and forms a right angle with the adjacent toes. Associated with this deformity is the development of an exostosis at the internal portion of the head of the first metatarsal bone, and the production of a bursa (bunion which may inflame and suppurate). The tendon of the extensor proprius hallucis retracts and assists in maintaining the deformity. The treatment consists in removing the exostosis.

The toes are frequently the site of gangrene due to atheroma, diabetes, frost-bite, etc. They are, however, less frequently the site of infections than the fingers.

Dislocation of the great toe on the metatarsal bone resembles a similar dislocation of the thumb, because of the difficulties which may present in effecting reduction.

Nerve Supply of Lower Extremity.—The cutaneous nerve supply of the lower extremity is shown in Figs. 318 and 319. The muscles on the front of the thigh are supplied by the anterior crural nerve; the muscles on the back of the thigh and the muscles of the leg and foot are supplied by the great sciatic nerve. Paralyses of the lower extremity are usually due to some lesion of the cord rather than a paralysis of an individual nerve.

The **anterior crural nerve** may be involved in fracture of the pelvis, fractures and dislocations of the femur, tumors growing in the pelvis, and stab wounds of the groin. The paralysis is manifest by inability of the patient to flex the hip or to extend the knee on the thigh. There is loss of sensation in the skin covering the front and inner side of the thigh, the inner side of the leg, and foot.

The **obturator nerve** is seldom paralyzed alone, usually in association with the anterior crural. When this nerve is paralyzed the adductor muscles are involved and the patient is unable to press his knees together, or pass one leg over the other. There is loss of sensation in the skin over the upper and inner side of the thigh. The most interesting phenomenon connected with this nerve is the peripheral expression of pain in the knee from irritation by pressure on its trunk. Thus, in hip-joint disease, in sacro-iliac disease, in cancer of the sigmoid flexure, and in obturator hernia pain is complained of in the knee.

FIG. 318.—CUTANEOUS NERVE-SUPPLY OF THE LOWER EXTREMITY. (ANTERIOR VIEW.)

A, Genitocrural; *B*, ilio-inguinal; *C*, external cutaneous; *D*, middle cutaneous; *E*, internal cutaneous; *F*, lateral cutaneous of peroneal; *G*, internal saphenous; *H*, external saphenous; *I*, musculocutaneous; *J*, external plantar; *K*, internal plantar; *L*, anterior tibial.

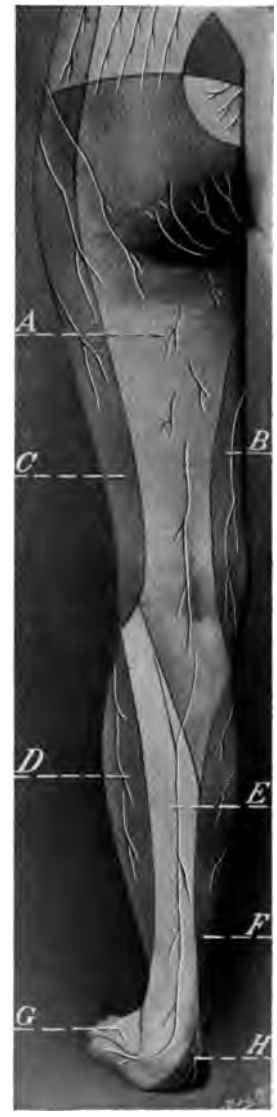

FIG. 319.—CUTANEOUS NERVE-SUPPLY OF THE LOWER EXTREMITY. (POSTERIOR VIEW.)

A, Small sciatic; *B*, internal cutaneous; *C*, external cutaneous; *D*, lateral cutaneous; *E*, internal saphenous; *F*, external saphenous; *G*, musculocutaneous; *H*, internal calcaneus.

The Great Sciatic Nerve.—When paralyzed there is loss of power in the muscles on the back of the thigh, in all the muscles below the knee, and loss of sensation in the skin of the leg and foot, except on the inner side. Irritation of this nerve produces sciatica. It may be caused by pelvic tumors, stone in the bladder when large, accumulation of feces in the rectum, and tumors growing from the margin of the great sacrosciatic foramen.

BIBLIOGRAPHY

Allport: History of the Mastoid Operation, Jour. Am. Med. Association, July 14, 1906.

Bardeleben: Applied Anatomy.

Bristow: The Use of Air to Dilate the Bladder and Suprapubic Cystotomy. "Annals of Surgery," vol. xvii., 1893.

Brödel: The Intrinsic Blood-vessels of the Kidney and Their Significance in Nephrotomy. "Johns Hopkins Hosp. Bull.," January, 1901.

Bryant: Operative Surgery.

Butler: Diagnostics of Internal Medicine.

Dawbarn: Starvation Treatment of Certain Malignant Growths.

Deaver: Enlargement of the Prostate, Its Diagnosis and Treatment.

Deaver: Surgical Anatomy.

Eisendrath: Clinical Anatomy.

Fowler: A Treatise on Surgery.

Gerdes: Zur operativen Behandlung des muscularen Schiefhalses. "Zentralblatt für Chirurgie," February 9, 1907.

Gerrish: Text Book of Anatomy.

Gordon, O. A.: Transactions of the Brooklyn Surgical Society, March, 1907.

Gray: Anatomy, Descriptive and Surgical (New American Edition).

Herczel, E.: Ueber eine bisher unbekante Ursache des Fiebers nach Milzextirpation. "Wiener klin. Wochenschrift," vol. v., 1907.

Hodenpyl: The Anatomy and Physiology of the Faucial Tonsil with reference to the Absorption of Infectious Material. "American Journal of the Med. Sciences," 1891.

Holden: Manual of Dissection of the Human Body.

Huntington: Anatomy of the Peritoneum and Abdomen.

Joessel and Waldeyer: Lehrbuch der Topographisch-Chirurgischen Anatomie.

Jonnesco: Résection totale et bilatérale du sympathique et cervical dans le traitment du goitre exophthalmique et de l'epilepsie. "Compt. rend. Cong. internationale de Méd.," 1899.

Keen, W. W. : Text-book of Nervous Diseases, by American Authors.

Kocher: Operative Surgery.

Macewen: Pyogenic Diseases of the Brain and Spinal Cord.

Merkel: Handbuch der Topographischen Anatomie.

Monks: Intestinal Localization. "Annals of Surgery," October, 1903.
Morris: Human Anatomy.
Morris: Surgical Diseases of the Kidney and Ureter.
Mumford: Surgical Aspects of Digestive Disorders.
Moynihan: Abdominal Operations.
Owen: A Manual of Anatomy for Senior Students.
Poirier and Charpy: Traité d'Anatomie Humaine.
Poirier, Cuneo, and Delamere: The Lymphatics.
Quain: Elements of Anatomy.
Robson: Gall-bladder and Bile-ducts.
Robson and Moynihan: Diseases of the Pancreas.
Rolleston: Diseases of the Liver, Gall-bladder, and Bile-ducts.
Sappey: Traité d'Anatomie.
Schultze and Stewart: Atlas of Topographic and Applied Anatomy.
Scudder: The Treatment of Fractures.
Senn: The Pathology and Surgical Treatment of Tumors.
Sobotta and McMurrich: Atlas of Human Anatomy.
Stimson: Fractures and Dislocations.
Sutton: Tumours, Innocent and Malignant.
Taylor: A Treatise on Applied Anatomy.
Testut: Traité d'Anatomie Humaine.
Tillaux: Traité d'Anatomie Topographique.
Treves: Applied Anatomy.
Van Gehuchten: Anatomie du Système Nerveux de l'Homme.
Whiting: The Modern Mastoid Operation.
Windle: Surface Anatomy.
Woolsey: Applied Surgical Anatomy.
Wright and Preston: Surgical Anatomy.
Zuckerkandl: Atlas der Topographischen Anatomie

INDEX

ABDOMEN, 331, 333, 336
anterior wall of, 337
boat-shaped, 336
boundaries of, 336
clinical significance of superficial fascia, 337
congenital defects of, 344
female, 336
in fleshy people, 336
in young children, 336
linea alba of, 332
albicantes of, 335
transversæ of, 333
lymphatic ganglia of, 449
muscles of, 337
posterior wall of, 362
skin of, 337
superficial fascia of, 337
surface anatomy of, 331, 333
topographic anatomy of, 333
Abdominal brain, 460
cavity (see abdomen), 367
long axis of, 367
fetation, 512
joint, 368
muscles, 337, 365
aponeurosis of, 337
conjoint tendon of, 340
disposition of, 337
protection to the viscera, 338
policeman, 371
rings, external, 332, 339, 348
internal, 332, 341, 348
route for kidney operations, 451
salivary gland, 435
tonsil, 402
wall, abscesses in, 345
anterior, 337
arteries of, 342
clinical significance of nerve supply to, 344
congenital hernia through, 344
injuries of, 344
lymphatics of, 343
nerves of, 343
posterior, 362
veins of, 343
Abducent, or sixth cranial nerve, 38, 97, 99, 101, 103
Abscess of abdominal wall, 345
axillary, 265
of breast, 218
gluteal, 579
iliac, 579
ischiorectal, 518, 579
of liver, 223, 423
lumbar, 579
mediastinal, 208
perinephritic, 451
postorbital, 98
prevesical, 483
prostatic, 490
Abscess, psoas, 363, 579
retro-esophageal, 232
retropharyngeal, 194, 197, 232
of spine, tubercular, 364
submaxillary, 153
subphrenic, 419
Accelerator urinæ muscle, 526
Accessory mammary lymphatics, 216
palatine nerves, 140
pancreas, 438
renal artery, 447
sinuses of nose, 118
thyroids, 191
Accommodation of eye, 106
Acetabulum, 583
Achillis tendon, 566, 616, 621, 638
Acne rosacea, 112
Acquired umbilical hernia, 346
Acromial epiphysis, 247
Acromion process, 233, 240, 247, 252
Acromioclavicular articulation, 148
Acromiothoracic artery, 176
Acute abdomen, 212, 344
dilatation of stomach, 386
glaucoma, 104
Adam's apple, 23, 177, 179
Addison's disease, 457
Adductor brevis muscle, 581
longus muscle, 576, 581
magnus, 565, 594
pollicis muscle, 328
region, 581
tubercle of femur, 597
Adenoid growths in pharynx, 145, 146
Adrenalin, 456
Adrenals, 456, See *Suprarenal Glands.*
Air embolism, 165, 172, 173
Alcock's canal, 518
Alexander's operation, 507
periosteum, 128
Alveolar arch, 124
Alveoli, abscess of, 124
arches of, 124
of the teeth, 121
Amnesia, 54
Ampulla of rectum, 470
stone in, 431
variations in form of, 428
of Vater, 437
Amputations, Chopart's, 637
Lisfranc's, 634, 636
Pirogoff's, 637
Syme's, 637
Anal canal, 472, 474
association with neck of bladder, 472
nerves of, 474
relations of, 472
sensitiveness of, 474
sphincters of, 472
valves of, 473
Anal valves or valves of Morgagni, 473
Anastomosis, circumpatellar, 598

Anastomotica magna of elbow, 280
of knee, 598
Anatomic snuff-box, 237, 307, 308
Anesthesia paralysis, 277
Aneurysm of abdominal aorta, 458
cirsoid, of temporal artery, 28
of gluteal artery, 571
popliteal, 602
of thoracic aorta, 231
Angina Ludovici, 151, 153
Angle, carrying, 287, 288, 299
of knee, 606
sacrovertebral, 462, 463
of scapula, 222, 233
Angular artery, 71
vein, 47, 101
Angulus Ludovici, 204
Ankle, 621
amputation of, 626
dislocation of, 634
fascia of, 621
fractures of, 634
ligaments of, 621, 622, 626
regions of, 622, 624
resection of, 626
tendons in, 622
tubercular arthritis of, 626
Annular ligaments of ankle, 621
of wrist, 317
stricture of the rectum, 476
Antecubital fossa, 236, 284
Anteflexion of the uterus, 495
Anterior annular ligament of ankle, 621
of wrist, 317
cerebral artery, 51, 52, 163
fossa, 36, 95
cervical triangle, 150
ciliary artery, 104, 105
vein, 106
circumflex artery, 252
commissure of vulva, 544
communicating artery, 52
crural nerve, 357, 362, 639
ethmoidal foramen, 103
fontanel, 18
fossa of skull, 36
contents of, 36
fractures of, 36
interosseous artery of forearm, 299
mediastinum, 226
nares, 113
palatine canal, 141
foramen, 137
thoracic nerves, 272
tibial artery, 616
true ligament of the bladder, 468
urethra, 521
Anterolateral ascending tract of spinal cord, 556
ground bundle of spinal cord, 557
Anteroposterior diameter of pelvis, 462
Anteversion of the uterus, 495
Anthelix, 19, 59
fossa of, 59
Antitragus, 20, 60
Antrum of Highmore, 21, 85, 121
boundaries of, 120
infections of, 121
of mastoid, 65
method of opening into, 122
mucous membrane of, 121
orifice of, 121
tumors of, 122
Antyllus, method of ligation in aneurysm of arteries of leg, 617
Anuria, 378
Anus, artificial, 477. See also *Anal Canal, etc.*
fissure of, 476
Anus, imperforate, 477
Aorta, 220
abdominal, 457
aneurysm of, 458
bifurcation of, 457
ligation of, 458
relations of, 457
thoracic, 230
aneurysm of arch of, 231
descending, 231
divisions of, and their relations, 230
origin of, 230
orifice, 229
Aortic plexus, 457
Aphasia, 54
causes of, 54
Aponeurosis, brachial, 278
of external oblique muscle, 239
of foot, 629
orbital, 97, 98
palatal, 139
temporal, 97
Apparatus, lacrimal, 109
Appendices epiploicæ, 409, 410
Appendicostomy, 408
Appendicular artery, 403
Appendiculo-ovarian artery, 403
ligament, 403
Appendix, 401
blood supply of, 404
clinical considerations of, 407
female, 403
location of, 333, 402
lymphatics of, 402, 404
nerves of, 405
presence in hernia, 405
variations in, and position of, 406
veins of, 404
Aqueduct of Sylvius, 50
Aqueductus Fallopii, 64
Aqueous chamber of eye, 106
Arachnoid membrane of brain, 38, 40, 49
of spinal cord, 554
Arbor vitæ of cervix uteri, 500
Arch or arches, alveolar, 124, 125, 137
costal, 331
crural, 357
palmar, 239, 317, 319, 320
deep, 239, 318, 322, 323
superficial, 239, 319
pedal, 629
plantar, 631
pubic, 463
zygomatic, 92
Arcus senilis, 105
Area or areas, auditory, 53, 54
fracture, of skull, 33
general sensory, 53, 54
motor, 53
of smell, 53, 54
speech, 53
of spinal cord, 556
taste, 54
visual, 53, 54
Argyll-Robertson pupil, 106
Arm, the, 278
collateral circulation in, after ligation of brachial artery, 283
compartments of, 278
extent of, 278
intermuscular septa of, 278
nerves of, 278, 280
skin of, 278
surgical considerations of, 281
vascular sheath of, 279
vessels of, 279
Arnold's nerve, 61
Arteria centralis retinæ, 101

Artery or arteries of abdominal wall, 342
accessory renal, 447
acromiothoracic, 176
anastomotica magna of brachial, 280
of femoral, 598
angular, 71
appendicular, 403
appendiculo-ovarian, 403
articular, of knee, 142
ascending palatine, 142
pharyngeal, 142, 164
auricular, 61
posterior, 28, 164
axillary, 235
basilar, 52
brachial, 276, 278, 279, 280, 283, 286
of brain, 51
bronchial, 224
carotid, common, 24, 155, 158, 160, 161, 162
external, 80, 144, 160, 163
internal, 51, 63, 80, 101, 143, 160, 163
left, 244
celiac axis, 383
cerebral, anterior, 51, 52, 163
of cerebral hemorrhage, 52
middle, 51, 54, 163
posterior, 52
cervical, deep, 175
ciliary, anterior, 104
long, 101
short, 101
circle of Willis, 51, 52
circumflex, of arm, 240, 252, 283
iliac, deep, 342
comes nervi ischiadici, 571
mediani, 300
communicating, anterior, 52
posterior, 52
coronary, of lip, inferior, 125
superior, 125
cricothyroid, 180
cystic, 426
dorsalis linguæ, 142
pedis, 616, 623, 629
scapulæ, 176, 246, 249
epigastric, deep, 342, 582
facial, 20, 71, 151, 153
femoral, common, 577, 593
profunda, 578
superficial, 578
frontal, 27
funicular, 507
gastric, 383
gastro-epiploic, 383
gluteal, 570
hemorrhoidal, inferior, 474, 518
middle, 474, 489
superior, 474
hepatic, 372
hypogastric, 345
iliac, circumflex, 342
external, 577
inferior profunda, of brachial, 280, 283
innominate, 155, 244
intercostal, 211, 214, 342
superior, 163, 175, 211
interosseous, of forearm, 299
of knee-joint, 598
lacrimal, 101
laryngeal, inferior, 182
superior, 182
lenticulostriate, 52
lingual, 133, 137, 153, 154, 164, 165
of lips, 125
long thoracic, 214
mammary, internal, 211, 214, 228, 342
maxillary, external. See *Facial.*

Artery, maxillary, internal, 63, 80, 89, 92
meningeal, anterior, 41
middle, 41
posterior, 41
mesenteric, 373
nasopalatine, 138
obturator, 360, 581
occipital, 27, 163, 164
ophthalmic, 99, 101
ovarian, 501, 509, 511
palatine, anterior, 138
posterior, 137, 138
palmar arch, 239, 317, 319, 320
deep, 239, 322
superficial, 239, 320
palpebral, 101
of penis, 531
peroneal, 617
plantar, external, 631
internal, 631
popliteal, 602, 616
profunda cervicis, 163
inferior, of arm, 280
superior, of arm, 280
femoris, 578
pudic, internal, 489, 514, 518
pulmonary, 223, 224
pyloric, 383
radial, 238, 297, 305, 306, 307
ranine, 134
renal, 447
accessory, 447
of scalp, 27
scapular, posterior, 176, 248
sciatic, 571
spermatic, 540
splenic, 372, 434
subclavian, 24, 156, 171, 173, 175
submental, 151
subscapular, 249, 283
superficialis volæ, 306
supra-orbital, 19, 27
suprascapular, 175
temporal, 19, 27, 61, 163
anterior, 27
posterior, 27
superficial, 80
thyroid, axis, 171
gland, 188
inferior, 159, 160, 163, 175, 189
superior, 163, 164, 165, 182, 189
thyroidea ima, 185, 189
tibial, anterior, 616
posterior, 616, 624
transversalis colli, 175, 248
ulnar, 238, 298, 306
uterine, 501
vaginal, 514
of vas deferens, 540
vasa brevia, 372
vertebral, 38, 51
vesical, 483
inferior, 483, 489
middle, 483
superior, 483

Articulation or articulations. See also *Joints.*
acromioclavicular, 148
carpometacarpal, 315, 324
chondrosternal, 219
Chopart's, 633
of elbow, 287
inferior radio-ulnar, 308, 309
of Lisfranc, 634
mediocarpal, 308, 310
tarsal, 633
metacarpophalangeal, 320, 321, 324
radiocarpal, 305, 308, 309
sternoclavicular, 158, 173

Articulation, temporomaxillary, 87
tibiotarsal, 626
Artificial anus, 477
Aryteno-epiglottidean folds, 181
Arytenoid cartilage, 180, 181
Ascending colon, 411
palatine artery, 142
pharyngeal artery, 142, 164
Ascites, 343, 371
Asphyxia, 182
Astragalus, 632
dislocation of, 635
fracture of, 635
Atlas, 551
lateral masses of, 552
relation to pharynx, 146
Atresia of cervix, 499
Atypical vertebræ, 551
Auditory area, 53, 54
meatus, external, 19, 60
internal, 38
nerve, 38
Auerbach's plexus, 385, 386
Auricle of ear, 19, 59
defects and malpositions of, 59
Auriculotemporal nerve, 30, 63, 80, 93
resection of, 30
Avulsion of upper extremity, 245
Axilla, 234, 264
boundaries of, 234, 264
contents of, 266
incision into, 265
skin of, 265
suspensory ligament of, 243, 265
Axillary arch, 267, 268
artery, 266
compression of, 267
course of, 235, 266
ligation of, 244, 267
origin of, 266
relations of, 267
fascia, 235, 265
folds, 219, 433
lymph-glands, 215, 216, 268, 269
surgical considerations of, 269
space, 234
vein, 218, 244
Axis, celiac, 383
pelvic, 464
thyroid, 171
vertebral, 551
odontoid process of, 552
relation to pharynx, 146
Azygos uvulæ, 140

Balanic epispadias, 532
hypospadias, 532
Balanitis, 530
Banti's disease, 435
Barrel-shaped chest, 207
Bartholin, glands of, 547
Base-line, Reid's, 56
Basilar artery, 52
meningitis, 49
Basilic vein, 236, 281
Basin, pelvic, 461
Bassini's operation for hernia, 356
Bell, nerve of, 272
Bell's palsy, 72
Bezoldt, mastoiditis of, 68
Biceps muscle of arm, 233, 235, 248, 250, 278, 279
tendon of, in elbow, 286
of thigh, 600
Bichat, fatty ball of, 85
Bicipital bursa, 286
fascia, 284, 286
groove, 233, 250, 251, 278
Bicuspid teeth, 21, 128
Bicycle accident, 86
Bigelow, Y-ligament of, 585
Bile-tract. See *Gall-tract, etc.*
Blackheads, 112
Bladder, 478, 485
access to, 485
anterior, true ligament of, 468
avenues of infection to, 485
base of, 480
capacity of, 478
clinical considerations of, 484
exstrophy of, 344
extroversion of, 484, 532
fasciculated, 485
female, 483
fundus of, 482
lateral true ligament of, 468
location of, 478
lymphatics of, 483
malposition of, 485
nerves of, 483
neck of, 480
pathologic triangle of, 482, 485
peritoneal covering of, 479
points of difference between male and female, 484
relations of, 478
sensitiveness of mucosa, 483
structure of, 481
vessels of, 483
wounds of, 484
Blandin, glands of, 133
Blepharitis, 108
Blind fistula, 475
Bone or bones, astragalus, 631, 632
atlas, 551
carpus, 308, 310
clavicle, 233, 240, 241
coccyx, 461
cranial, 33, 34
cuboid, 631, 633
cuneiform, of foot, 631, 632
of hand, 310
diploe of, 34
epiteric, 33
ethmoid, 36, 96, 114
femur, 566, 583, 585, 595, 605
fibula, 618
of foot, 631
frontal, 33, 55, 96, 97
humerus, 233, 250, 252, 261, 262, 263, 281, 284, 293
hyoid, 22, 163, 176, 177
iliac, 331, 332, 562
intermaxillary, 127, 141
ischium, 463, 562
lacrimal, 96, 110
of leg, 618
fractures of, 619
general considerations of, 618
malar, 96, 97
maxillary, inferior, 86
superior, 96, 97, 110, 120
metacarpal, 323, 324
metatarsal, 632
nasal, 21, 112
navicular. See *Scaphoid.*
occipital, 33
os calcis, 631, 632
innominata, 461
magnum, 310, 315
planum, 96
palatal, 96
parietal, 33
patella, 607
pelvic, 461
phalangeal, of foot, 637
of hand, 327, 328

Bone, pisiform, 238, 317
pubis, 464, 465
radius, 237, 300, 302, 308, 309
ribs, 204, 209, 210
riders, 577
sacrum, 461, 464
scaphoid, of foot, 631, 632
of wrist, 309, 310
scapula, 207, 209, 223, 245, 247
semilunar, 309
sphenoid, 33, 97
sternum, 207, 208, 209
tarsus, 632
temporal, 33, 163
thigh. See *Femur.*
tibia, 618
trapezium, 315
turbinated, 114
inferior, 110, 114, 115
middle, 114, 115
superior, 114, 115
ulna, 237, 300, 302, 309
unciform, 317
vertebral, cervical, 158, 167, 171, 549, 551
dorsal, 548, 551
lumbar, 364, 548, 551
vomer, 114
Wormian, 33
Boyer, bursa of, 177
Brachial aponeurosis, 278
artery, 276, 278, 279, 286
anomalies of, 280, 283
bifurcation of, 280, 283, 297
compression of, 282
course of, 279
ligation of, 282
relations of, 279, 280
venæ comites of, 279
plexus, 156, 171, 269, 276
branches of, 271, 272
cords of, 24, 270, 271
formation of, 270, 271
surgical considerations of, 277
Brachialis anticus muscle, 278, 279
Brachiocephalic vein, 198
Brain, 40, 53
areas of, 53, 54
arteries of, 51
clinical considerations of, 57
compression of, 57
concussion of, 57
contusion of, 57
membranes of, 40
relations to skull, 57
sinuses of, 44
water bag of, 50
wound of, 57
Branchial cleft, 145
cysts, 203
fistula, 203
Breast. See also *Mammary Gland.*
abscess of, 218
areola of, 213
areolar lymphatics of, 215, 216
cancer of, 217, 218
cutaneous lymphatics of, 215
glandular lymphatics of, 215
incision into, 219
infection and routes for, 218
neoplasms of, 216, 217
pigeon, 208
reflected pain from, 215, 217
removal of, 218
sebaceous glands of, 213
subcutaneous tubercle of, 216
Bregma, 18
Bristow's method of inflation of bladder, 480
Broad ligament of uterus, 505
abscess of, 506
borders of, 506
clinical considerations of, 506
contents of, 505
mesosalpinx of, 506
mesovarium of, 506
relations of, 505
Broca's region, 53
Brödel's white line, 448
Brodie's abscess of tibia, 620
Bronchial artery, 224
glands, 231
Bronchocele, 190
Brunner's glands, 394
Bryant's triangle, 564
Bubo, 351, 575
Bubonocele, 351, 354
Buccal cavity, 93, 125
nerve, 84
Buccinator muscle, 84
Buck teeth, 146
Bulbocavernosus muscle, 526
Bulbs, vaginal, 547
Burdach, tract of, 556
Bursa, or bursæ, anserina, 601
bicipital, 286
ischial, 569
mucous, of foot, 629
olecranon, 289
omental, 370
palmar, 320
of popliteal space, 601
prepatellar, 598
psoas, 579
retrocalcanean, 624
subdeltoid, 250
submammary, 214
subscapular, 245
supra-acromial, 249
suprapatellar, 610
trochanteric, 569
thyrohyoid, or bursa of Boyer, 177
Buttocks, 568
arteries of, 570
fascia of, 568
fold of, 569
lipoma of, 568
lymphatics of, 573
nerves of, 570
skin of, 568

Calcaneoscaphoid ligament, 633
Calcarine fissure, 54
Calf, 616
muscles, 616
Callosities of foot, 628, 629
of hand, 317
Canal, Alcock's, 518
anal, 472, 474
anterior palatine, 141
carotid, 51
crural, 359
dental, 93
Fallopian, 67
Hunter's, 594
inguinal, 348
lacrimal, 110
of Nuck, 348, 507, 544
obturator, 581
posterior palatine, 137
of Schlemm, 106
of Wirsung, 437
Canine teeth, 128
Canthi of the eyelids, 107
Capsular ligament of hip-joint, 585
of shoulder, 245, 250
of temporomaxillary articulation, 88

Capsule of kidney, 443
of parotid, 79
of prostate, 468
of Tenon, 95, 97
function of, 95, 98
structure of, 95
Caput succedaneum, 32
Carbuncle, 148
Cardiac end of stomach, 381
Cardiorrhaphy, 230
Carotid artery, common, 24, 155, 158, 160
aneurysm of, 161
anomalies of, 162
bulb of, 161
collateral circulation after ligation of, 162
compression of, 160
course of, 158
ligations of, 161
anatomic considerations in, 162
origin of, 158
relations of, 158, 159, 160
satellite muscle of, 158
surface landmarks of, 162
external, 80, 144, 160, 163
internal, 63, 80, 101, 143, 160, 163
Carotid canal, 51
ganglion, 166
region, 155
sheath, 158, 162
contents of, 158, 162
triangles, inferior, 150, 155
superior, 150, 155
tubercle (or tubercle of Chassaignac), 23, 160, 162
Carpal bones, 308, 309, 310
fracture of, 314
Carpometacarpal joint, 315
Carrying angle, 287, 288, 294
Cartilages, arytenoid, 180, 181
cricoid, 23, 160, 162, 177
fibro-, intervertebral, 549
ensiform, 204, 331
of nose, lateral, 112
septal, 114
of Santorini, 181
semilunar, of knee, 607
thyroid, 23, 163, 177
Caruncle, urethral, 516
Caruncula lacrimalis, 108
Carunculæ myrtiformes, 547
Cataract, 106
Catheterization, 524
Cauda equina, 553, 557
Caudate nucleus, 52
Cave of Meckel, 77
Cavernous plexus, 103
sinus, 37, 44, 48, 101, 163
arteriovenous aneurysm, with internal carotid, 37
contents of, 37, 48
infections of, 49
thrombosis of, 48
surgical considerations of, 48, 49
Cavity or cavities, abdominal, 367
buccal, 93, 125
cranial. See *Cranium.*
glenoid, 88, 251, 252, 254
nasal, 113
orbital, 95
pelvic. See *Pelvis.*
peritoneal. See *Abdominal.*
lesser, 370
sigmoid, 287
thoracic, 219
tympanic, 62, 63
Cecum, 397
abnormal location of, 399
clinical considerations of, 401
Cecum, foreign bodies in, 401
mesentery of, 377
peritoneal covering of, 398
types of, 399
Celiac axis, 383
Cephalic vein, 236
Cerebellum, 38
Cerebral arteries, anterior, 52
middle, 163
posterior, 52
Cerebrospinal fluid, 40, 49, 554
composition of, 50
flowing from nose, 37
functions of, 50
outlets of, 50
surgical considerations of, 50, 51
Ceruminous glands of ear, 61
Cervical adenitis, 153
enlargement of spinal cord, 553
fascia, deep, 196
neuralgia, 30
plexus, 169
quadrilateral, 150
sympathetic, 166
effects of resection of, 168
ganglia of, 166
resection of, 191
surgical considerations of, 167, 168
vertebra, 158, 167, 171
Cervicofacial division of facial nerve, 81
Cervix of penis, 529
of uterus, 494, 497
arbor vitæ of, 500
atresia of, 499
cancer of, 500, 504
cavity of, 500
external os of, 498
internal os of, 499
lips of, 499
supravaginal portion of, 497
vaginal portion of, 498
Charcot's artery of cerebral hemorrhage, 52
Chassaignac, tubercle of, 23, 160, 162
Check ligament of cervical vertebræ, 552
of eye, 98
Cheeks, lipomas of, 85
neuralgia in, 84
pus in, 85
Chest, 207. See also *Thorax.*
barrel-shaped, 207
diameter of, 207
circumference of, 207
flat, 207
retracted, 207
Choked disk, 102
Cholecystenterostomy, 432
Choledochotomy, 432
Chondrosternal articulation, 219
Chopart's amputation, 637
articulation, 633
Chorda tympani, 63, 93, 134
Chordee, 533
Choroid membrane, 105, 106
disposition of, 105
function of, 105
melanosarcoma of, 105
vessels, 101
Chyle cysts, 374
Cicatricial stricture of rectum, 476
Ciliary arteries, 101, 104
body, 105
ganglion, 102
muscle, 102, 103, 105
veins, 106
Circle of Willis, 51, 52, 163
Circular sinus, 44
Circumflex artery, 246, 283
iliac, 342
nerve, 246, 250, 255, 257, 273

Circumpatellar anastomosis, 598
Circumvallate papillæ, 22, 132
Cirsoid aneurysm of ophthalmic artery, 101
of temporal artery, 28
Clavicle, 233, 240, 241
articulations of, 241
dislocations of, 241
excision of, 244
fracture of, 242, 253
neoplasms of, 244
Clavicular region, 240
Clavipectoral fascia, 243, 265
Claw-hand, 276, 300, 323
Cleft palate, 140, 141, 142
sternum, 209
Clinoid processes, 43
Clitoris, 546
ligaments of, 547
prepuce of, 546
structure of, 546
Club-foot, 622
Coachman's bursitis, 569
Coccyx, 461
Cold in the head, 117
Colic, salivary, 153
Colic impression on liver, 417
Collar incision of Kocher, 191
Colles' fascia, 525
fracture, 309, 310
anatomic factors in, 311
complex of, 310, 311, 312
reduction of, 313
or triangular ligament of abdomen, 339
Colon, 335, 409
blood supply of, 411
capacity of, 410
characteristics of its coats, 409, 410
differential landmarks in, 410
divisions of, 409
mesentery of, 377
surgical considerations of, 414
Colostomy, anatomic points in, 415
Columns of Morgagni, 473
Comes nervi ischiadici artery, 571
mediani artery, 300
Commissures of spinal cord, 555
of vulva, 544
Common bile-duct, 372, 389, 437
course and divisions of, 427
relations of, 389
stones in, 430
carotid artery. See under *Carotid Artery*.
ligaments of spinal column, 552
Communication between intra- and extra-cranial circulation, 44
Communis extensor tendons of hand, 327
Complete or scrotal hernia, 351, 354, 356
Compound palmar ganglion, 322
Compressor urethræ muscle, 527
Concha, 19, 60
Conduction paths of spinal cord, 556
Condyles of femur, 566
of humerus, 235, 284
of jaw, 20, 88, 89
Congenital defects of abdomen, 344
of penis, 531
dislocation of hip, 591
hernia through abdominal wall, 344
umbilical, 346
hydrocele, 542
Conjoint tendon of abdominal muscles, 34
Conjugate diameters of pelvis, 462
Conjunctiva, 108
divisions of, 108
inflammation of, 109
vessels of, 101
Conoid ligament, 241
Constrictor muscles of pharynx, 146
Contraction, Dupuytren's, 319
ischemic, of Volkmann, 302
Convolutions of the brain, 53
hippocampal, 54
Coracoclavicular ligament, 241
brachialis muscle, 235, 248, 250, 279
Coracoid process, 234, 248, 252, 279
Cord or cords of brachial plexus, 271
spermatic, 348, 538
spinal, 552
umbilical, 345
vocal, 181
Cornea, 100, 103, 104
inflammation of, 105
nutrition of, 105
Corneal opacities, 105
Corona of penis, 529
Coronal suture, 55
Coronary arteries of the face, 71, 125
ligaments of liver, 419
Coronoid process of inferior maxillary bone, 31
of ulna, 291
Corpora cavernosa, 526, 528, 529
Corpus spongiosum, 529
Coryza, 117
Costal arches, 331
groove, 210
Costo-acromial ligament, 252
Costoclavicular ligament, 241
Costocoracoid membrane, 243, 244
vertebral groove, 224
Cotyloid ligament, 583
notch, 583
Cowper's glands, 523
Coxa vara, 584
Cranial bones, 33, 39
fracture of, 35, 36, 37
peculiarities of nutrition, 34
structure of, 34
sutures of, 33
tumors of, 33
syphilis of, 39
tuberculosis of, 39
union of, 33
cavity, 40
contents of, 40
Craniocerebral topography, 52, 53
Craniotabes, 39
Cranium, 33, 34
base of, 36
vault of, 33
Cremasteric fascia, 340, 536
muscle, 340, 536
reflex, 535, 536
Crepitus, muffled, 293
Crest of ilium, 562
of os pubis, 462
Cretinism, 187
Cribriform fascia of thigh, 576
plate of ethmoid, 36
Crico-arytenoideus posticus muscles, 180
Cricoid cartilage, 23, 160, 162, 177
Cricothyroid artery, 180
membrane, 23, 177, 179
Crile, method of ligation of common carotid artery, 162
Crista galli, 103
Crossed pyramidal tract of spinal cord, 550
Crucial ligaments, 610
Crural arch, 357
canal, 359
nerve, 357, 362, 565, 639
Crureus muscle, 593
Crutch paralysis, 277
Cryptorchidism, 541
Cuboid bone of foot, 631, 633
Cul-de-sac of Douglas, 471, 492, 497

Cuneate lobe of brain, 54
Cuneiform bone of foot, 631, 632
of wrist, 309
Cystalgia, 474
Cystic artery, 426
duct, 430
angulation of, 424
stone in, 430
Cystocele, 513
vaginal, 485
Cyst or cysts, branchial, 203
of canal of Nuck, 544
chylous or mesenteric, 374
of hand, 329
hydatid of liver, 424
intraligamentous, 510
of jaw, 129
lacteal, 214
of liver, 223
Meibomian, 108
of ovary, 510
pancreatic, 439
parovarian, 510
salivary, 153
synovial, of popliteal space, 604
of testes, 537
of urachus, 346

Dacryocystitis, 110
Dangerous area of eye, 105
of scalp, 26
Dartos, 534
action of, 534
Darwin, tubercle of, 60
Deadly mesenteric line, 393
Deep cervical artery, 175
fascia, 196
lymphatics, 134
circumflex iliac artery, 342
epigastric artery, 342
course of, 342
injury to, 342
relations of, 342
facial vein, 71
fascia of knee-joint, 597
gluteal fascia, 568
palmar arch, 239, 318, 322, 323
fascia, 318, 319
temporal nerve, 93
Deltoid or internal lateral ligament of ankle, 626
muscle, 250, 253
atrophy of, 250
lipoma of, 264
paralysis of, 234, 255
region, 149
Dental canal, 93
foramen, 93, 74
guide to, 94
Dentition, 128
Dermoid cysts of ovary, 510
of scrotum, 534
Descendens noni nerve, 160, 162
Descending colon, 413
Diameters of the pelvis, 462
Diaphragm, 219
central tendon of, 219
crura of, 220
extent of, 219
functions of, 219
layers of, 219
lymphatics of, 378
nerves of, 220
openings through, 220
pelvic, 465
rupture of, 220
vault of, 219
wounds of, 220, 22

Digastric muscle, 150, 151, 164, 165
Digital fossa, 536
Diploe, 34
infectious processes in, 29
Diploic veins of scalp, 29
Diplopia, 38
Direct cerebellar tract of spinal cord,
inguinal hernia, 354
pyramidal tract of spinal cord, 556
Disease, Addison's, 457
Banti's, 435
Graves' (or exophthalmic goiter), 18
of hip-joint, 364
Hodgkin's, 143, 202
Paget's, of the nipple, 213
tubercular, of spine (Pott's), 212, 3
561
Dislocation or dislocations of ankle, 63
of astragalus, 635
congenital, of hip, 591
of elbow, 290
of great toe, 639
of hip, 588, 589
of jaw, 90
of knee, 613
of patella, 609
radiocarpal, 310
of shoulder-joint, 252
of spine, 560
subacromial, 253
subclavicular, 253
subcoracoid, 253
subglenoid, 247, 253, 254
subspinous, 253
of wrist, 310
Diverticula of ischiorectal fossa, 518
Diverticulum, Meckel's, 346
Dorsal vein of penis, 531
vertebra, 551
Dorsalis linguæ artery, 142
pedis artery, 616, 623, 629
scapular artery, 176, 246, 249
Dorsum ilii dislocation of femur, 589
Double harelip, 142
vision, 38
Douglas, cul-de-sac of, 471, 492, 497
semilunar fold of, 340
Duct or ducts, bile-, common, 372, 3
437
cystic, 420
ejaculatory, 493
of Gärtner, 505, 509
hepatic, 426
lactiferous, 214, 218
of Müller, 503
nasal, 110
pancreatic, 389, 430, 437
prostatic, 489
of Rivinus, 131
of Santorini, 437
seminal, 491
Stenson's, 20, 81, 85, 125
sublingual, 131
thoracic, 173, 220, 244
thyroglossal, 132
vitello-intestinal, 345
Wharton's, 131, 152
of Wirsung, 437
Ductus arteriosus, 230
Duodenal impression of liver, 417
Duodenocholedochotomy, 432
Duodenojejunal flexure, 387, 390
fossa (or fossa of Treitz), 387, 390
Duodenum, 389
characteristics of, 389
clinical considerations of, 390
perforating ulcer of, 391
relations of, 389
traumatic rupture of, 390

Dupuytren's contraction, 319
Dura mater of brain, 34, 40
of spinal cord, 553
Dysphagia, 161, 190, 231
Dyspnea, 161, 182, 190, 231
Dysuria, 490, 496

EAR, 59, 60, 61, 62
auricle of, 19, 59
external, 59
anatomic considerations of, 59, 60
clinical considerations of, 62
extent of, 60
middle, 64, 67, 89
anatomic considerations of, 63
clinical considerations of, 67
facial paralysis due to suppuration in, 67
ossicles of, 63
Ectopia testis, 541
Ectropion, 108
Ejaculatory ducts, 493
access to, 493
clinical considerations of, 493
orifices of, 489
Elbow. See also *Elbow-joint.*
arterial circle of, 286
bend of, 286
bony points of, 235, 236, 284
dimple of, 288
grooves of, 284
miner's, 289
muscular eminences of, 284
synovitis of, 284
venous M of, 284
Elbow-joint. See also *Elbow.*
ankylosis of, 287
dislocations of, 290
reduction of, 292
varieties of, 291
fractures in vicinity of, 292
interarticular line of, 287
ligaments of, 287
resection of, 289
separation of epiphysis in, 293
surgical considerations of, 289
Elephantiasis of scrotum, 535
Embolism, air, 165, 172, 173
pulmonary, 224
Eminence, hypothenar, 238, 239, 317
thenar, 238, 239, 316
Eminentia articularis, 88, 90
Emissary veins of skull, 29
Emphysema, pulmonary, 225
subcutaneous, of nose, 112
of thoracic wall, 225
Emphysematous or barrel-shaped chest, 207, 210
Empyema, 210, 222
Encysted hernia, 352
hydrocele, 542
Ensiform cartilage, 204, 331
Enterectomy, 396
Enterotomy, 396
Enteroptosis, 338, 412
Entropion, 108
Epidemic parotitis (mumps), 80
Epididymis, 536
gonorrheal and tubercular affections of, 543
Epididymitis, 536
Epidural hemorrhage, 41
causes of, 42
symptoms of, 42
space of spinal cord, 553
Epigastric artery, 342
region, 333
Epigastrium, 212
Epiglottis, 22, 145, 181
detached, 178
functions of, 181
Epilepsy, focal, 41
Epiphysis of femur, 613
of humerus, 261
of radius, 309
separation in shoulder, 261
of lower femoral, 613
of ulna, 309
Epiplocele, 370
Epiplopexy, 371
Epispadias, 532
Epistaxis (nose-bleed), 117
Epulis, 127
Erb's paralysis, 277
Erectile body of nasal mucous membrane, 117
of penis, 529
of vagina, 547
Erector penis, 526
spinæ muscles, 334, 366
Esophagotomy, 194, 196
Esophagus, 23, 159, 193, 220
extent of, 193
lymphatics of, 195
opening in diaphragm, 220
points of constriction in, 194
relations of, 194
stricture of, 195, 196
Estlander's operation for empyema, 210
Ethmoid bone, 36, 96, 122
cribriform plate of, 36
perpendicular plate of, 114
Ethmoidal cells, 96, 122
inflammation of, 96, 122
outlets of, 122
foramen, anterior, 103, 122
posterior, 122
Eustachian tube, 64, 145, 146, 147
anatomic considerations of, 64
infections in, 64
inflation of, 64
method of Politzer, 64
of Valsalva, 64
opening in pharynx, 145
Excision of rectum, 477
Exophthalmic goiter, 168, 187, 190
Exophthalmos, pulsating, 37
Exstrophy of the bladder, 344
Extensor brevis pollicis, 307
communis digitorum, 307
indicis, 307
longus digitorum, 567
pollicis, 307
minimi digiti, 307
muscles of forearm, 297
of leg, 616
ossis metacarpi pollicis, 307
proprius hallucis, 567
quadriceps, 565
External abdominal ring, 322, 339, 348
angular process, 18
annular ligament of ankle, 622
anterior thoracic nerve, 272
articular artery of knee, 598
auditory meatus, 17, 19, 60
calcaneal artery, 617
carotid artery, 80, 93, 144, 160, 163, 164
anatomic considerations of, 164
differentiation from internal, 163
ligation of, 93, 164
relation to parotid gland, 164
condyle of femur, 566
of humerus, 235
cutaneous nerve of abdomen, 357
of thigh, 362
ear, 59
genitals, female, 544

External genitals, male, 528, 533, 536, 539
hemorrhoids, 276
iliac artery, 577
glands, 503
intermuscular septum of arm, 278
jugular vein, 149, 155, 168, 171, 173
lateral ligament of jaw, 89
ligament of knee, 609
oblique muscle, 338, 339
occipital protuberance, 17
os of cervix uteri, 498
plantar artery, 631
popliteal nerve, 566, 604
pterygoid muscle, 90, 92, 93
rectus muscle, 99
saphenous vein, 604, 615
sphincter of rectum, 472
strabismus, 38, 102
Extroversion of the bladder, 484, 532
Eye. See also *Orbit*.
accommodation of, 106
aqueous chamber of, 106
check ligaments of, 98
dangerous area of, 105
enucleation of, 97, 107
muscles of, 99
Eye-ball, 95, 100, 104. See also *Eye*.
coats of, 104, 105
pain in, 104
Eye-lashes, 108
Eye-lid, 95, 107
affections of, 97
functions of, 107
glands of, 108
layers of, 108
nerves of, 108
structure of, 107

FACE, areas supplied by the trifacial nerve, 76
blood supply of, 70, 71
clinical considerations of, 71, 72
epithelioma of, 70
location of foramina on, 74
lymphatics of, 78
muscles of, 70
nerves of, 72
skin of, 70
Facial artery, 29, 151, 153, 164
muscles, 70
divisions of, 70
functions of, 70
nerve, 26, 72, 81, 147
course and divisions of, 72
paralysis of, 38, 64, 66, 72
relation to parotid gland, 81
neuralgia, 168
paralysis (or Bell's palsy), 72
process of parotid gland, 79
vein, 71, 126, 151, 153, 166
danger of infections in, 71
phlebitis of, 71
Falciform or suspensory ligament of liver, 370
process of fascia lata, 576
Fallopian canal, 64
caries of, 67
tubes, 510
access to, 512
ampulla of, 510
coats of, 511
clinical considerations of, 511
extirpation of, 512
fimbriated extremity of, 510
functions of, 510
inflammation of, 511
isthmus of, 510
lymphatics of, 511
Fallopian tubes, nerves of, 511
orifices of, 510, 511
structure of, 510
vessels of, 511
Falx cerebelli, 43
cerebri, 42
Farabeuf's triangle, 166
Fascia, axillary, 265
bicipital, 284, 286
cervical, deep, 196
clavipectoral, 243, 265
Colles', 525
cremaster, 340, 536
cribriform, 576
deep palmar, 318, 319
gluteal, 568
iliac, 362
infundibular, 341
intercolumnar, 349
ischiorectal, 468
of knee-joint, 597
lata, 575, 593
muscular hernia through, 593
lumbar, 366
obturator, 468
palmar, 318, 319
pectoral, 214
pelvic, 467
penis, 531
plantar, 630
prevertebral, 158
rectovesical, 468
superficial palmar, 317
of scalp, 25
temporal, 31
transversalis, 341, 348
Fatty ball of Bichat, 85
capsule of kidney, 443
Fauces, 139
isthmus of, 145
pillars of, 21, 139, 140
Felon or whitlow, 325
Female genitals, external, 544
pelvis. See *Pelvis*.
perineum, 544
points of difference and similarity to male, 544
triangles of, 544, 545
Femoral artery, 565, 577, 593
anomalies of, 595
collateral circulation of, 571
digital compression of, 578
divisions of, 594
ligation of, in Hunter's canal, 595
in Scarpa's triangle, 578
hernia, 359
coverings of, 360
herniotomy for radical cure of, 361
for strangulation of, 360
mechanism of taxis in, 360
ring, 358
relations of, 359
sheath, 358, 359
vein, 579
phlebitis of, 579
wounds of, 579
Femur, articulation with hip, 583
condyles of, 566
fracture of base of, 586
of neck, 585, 586
of shaft, 595
interarticular line of, 566
intercondyloid notch of, 605
necrosis of, 596
osteomyelitis of, 596
sarcoma of, 596
trochanters of, 584, 585
Fenestra ovalis, 63
Fetation, abdominal, 512

Fibula, 618
fracture of, 619
head of, 566
malleolus of, 566
Fifth cervical vertebra, 171
cranial nerve, 37, 76, 97, 101
metatarsal bone, 567
Filum terminale, 554
Fingers, 324
amputations of, 328
bones of, 327
dislocations of, 328
dorsal surface of, 326
extensor tendons in, 327
flexor tendons in, 326
ligaments of, 328
skin of, 325
Fissure or fissures of anus, 476
calcarine, 54
of Glaser, 88
longitudinal, 17, 55
parieto-occipital, 57
pterygomaxillary, 92
of Rolando, 53, 54, 56
of Santorini, 62
sphenoidal, 77, 93, 97, 100
sphenomaxillary, 92, 97
of spinal cord, 554
of Sylvius, 37, 51, 55, 163
Fistula, anal, 475, 519
blind, 475
branchial, 203
gastric, 381
horseshoe, 475
in ano, 475, 519
of parotid gland, 82
rectovaginal, 513
rectovesical, 481
salivary, 82
ureterovaginal, 513
urethrovaginal, 513
vesico-uterine, 484, 497
vesicovaginal, 484, 513
Fixed vertebra, 551
Flat chest, 207
foot, 629, 632
structures involved in, 632
Flexor brevis digitorum, 637
carpi radialis, 306
ulnaris, 298, 299
longus digitorum, 637
hallucis, 616
muscles of forearm, 297
of leg, 616
of thigh, 600
profundus digitorum, 300
sublimis digitorum, 299
Flexure, duodenojejunal, 387
hepatic, 409
sigmoid, 409
splenic, 409
Floating bodies in knee-joint, 612
kidney, 444
Focal epilepsy, 41
Fold or folds, aryteno-epiglottic, 181
of axilla, 433
of buttock, 569
glosso-epiglottidean, 181
of groin, 573
semilunar, of Douglass, 340
Fontana, spaces of, 106
Fontanels, 18
Foot, 628
amputations of, 636
aponeurosis of, 629
bones of, 631
callosities of, 628, 629
club-, 622
flat-, 629, 632
Foot, lymphatics of, 629, 631
perforating ulcer of, 629
skin and subcutaneous tissue of, 628
veins of, 625
Foramen or foramina, cecum of dura mater, 44
of tongue, 132
dental, 93, 94
ethmoidal, 103, 122
infra-orbital, 74, 75
jugular, 39
of Key, 50
magnum, 38
of Magendie, 50, 554
mental, 20, 74, 76, 87, 93, 94
of Munro, 50
obturator, 581
optic, 99, 101
ovale, 78
palatine, 137
of Retzius, 50
rotundum, 77, 78
sacrosciatic, 570
sphenopalatine, 93
spinosum, 78
sternal, 208
supra-orbital, 74, 103
of Winslow, 370, 372
of hernia through, 377
Forearm, 297
bones of, 300
fracture of, 302
extent of, 297
muscles of, 297, 302
Fornices of vagina, 513
Fossa or fossæ, antecubital, 236, 284
of anthelix, 59
cerebral, anterior, 36, 95
middle, 37
posterior, 38
cranial. See *Cerebral.*
digital, 536
duodenojejunal, 387
glenoid, of temporal bone, 88, 89
of helix, 59
ileocecal, 406
ileocolic, 406
iliac, 362
infraclavicular, 243
infraspinous, 245
ischiorectal, 518
nasal, 44, 95
navicularis, 544
pericecal, 405
peritoneal, 349
pterygomaxillary, 92
renal, 443
of Rosenmüller, 145
scapular, 245
of skull. See *Cerebral.*
sphenomaxillary, 93, 97
subcecal, 406
subclavian, 234
subscapular, 245
supraclavicular, 169
suprascapular, 171, 245
temporal, 19, 31, 93, 95, 97
zygomatic, 90, 97
Fourchette, 544
Fourth cranial nerve or trochlear, 37, 97, 100, 101
lumbar vertebra, 390
sacral nerve, 474
Fowler, method of treatment in peritonitis, 378
Fracture or fractures, of acromion process, 247
of anatomic neck of humerus, 261
of ankle, 635

Fracture, area of skull, 33
of astragalus, 635
of forearm, 302
of clavicle, 242, 253
Colles', 309, 310
of condyles of humerus, 292, 293
dislocations, 560
of elbow, 292
of femur, 585, 586, 595
of fibula, 619
into frontal sinus, 119
of metacarpal bones, 324
of olecranon process, 295
of patella, 608
of pelvis, 465
of penis, 533
of phalanges of hand, 328
Pott's, 310, 627
of ribs, 210
of scaphoid, 314
of scapula, 247
of shaft of femur, 595
of humerus, 281
of spine, 560
of superior maxilla, 85
supracondyloid, of femur, 612
of surgical neck of humerus, 294
Frenum of penis, 530
of tongue, 22, 130
Frontal artery, 27
bone, 33, 96, 97, 110
external angular process of, 55
internal angular process of, 96
sinuses in, 18, 97
lobes, 36
nerve, 103
sinus, 18, 118
fracture into, 119
glands of, 119
inflammation of, 120
larvæ in, 119
mucous membrane of, 119
outlet of, 119
pus in, 120
relation to sphenoidal, 119
Frontonasal process, 141
Funicular artery, 507
hernia, 352

Galactocele, 214
Gall-bladder, 424
abnormal position of, 428
blood supply of, 426
fundus of, 424
mesenteric covering of, 424
nerves of, 426
relations of, 426
stones in, 430
surface markings of, 334
Gall-stones, 430
tract, 424
clinical considerations of, 429
operations for relief of obstructions in, 431
Ganglion or ganglia, carotid, 166
cervical sympathetic, 166
ciliary, 102
compound palmar, 322
Gasserian, 74, 77
Meckel's, 97
ophthalmic, 103
otic, 80
thyroid, 166
vertebral, 166
of wrist, 314
Gärtner, duct of, 505, 509
Gasserian ganglion, 37, 74, 77
branches of, 37, 77
Gasserian ganglion, location of, 37, 77
removal of, 37, 78
Gastrectomy, 387, 388
Gastric arteries, 383
coronary chain group of glands, 384
dilatation, 385
fistula, 381
glands, 385
impression on liver, 417
triangle, 379, 385, 386
ulcer, 387
Gastrocnemius muscle, 616
Gastro-enterostomy, 383, 386, 387
anatomic considerations in, 387
posterior, 387
Gastro-epiploic arteries, 383
Gastrohepatic or lesser omentum, 377
Gastrophrenic ligament, 381
Gastrosplenic omentum, 372
Gastrostomy, 386
Gastrotomy, 386
Gemellus inferior muscle, 570
superior muscle, 570
General sensory area, 53, 54
function of, 54, 55
location of, 54
Genioglossus muscle, 129, 130, 132, 15
Geniohyoid muscle, 132
Genitals, external female, 544
male, 528, 533, 536, 539
Genitocrural nerve, 349
Genu valgum, 606
varum, 606
Gerdes, method of resection of scal anticus in wry-neck, 156
Gerlach, tubular tonsil of, 145
valve of, 402
Gerota's capsule (perineal fascia), 443
Gimbernat's ligament, 339, 359, 360
Glabella, 17, 55
Gladiolus, 204, 223
Gland or glands, abdominal salivary,
axillary, 216, 269
of Bartholin, 547
of Blandin, 133
bronchial, 231
Brunner's, 394
ceruminous, 61
Cowper's, 523
of v. Ebner, 133
gastric coronary chain group of lyn atic, 384
iliac external, 503
inguinal, 503, 574, 575
intrinsic lingual, 133
labial, 125
lacrimal, 103, 109
of Lieberkühn, 394
of Littré, 523
lymphatic. See under *Lymphatics, Individual Regions or Organs.*
mammary, 204, 213
internal, 216
supernumerary, 580
Meibomian, 108
mesenteric, 374
molar, 85
of neck, 200
cancerous, 201
sarcomatous, 202
tuberculous, 201
of Nuhn, 133
obturator, 585
parathyroid, 191
parotid, 163
peritracheal, 231
peritracheobronchial, 231
posterior mediastinal, 231
prostate, 486, 489

Gland, retrocarotid, 160
retrosternal, 218
of Rosenmüller, 575
salivary, 79, 131, 151
serous, of tongue, 133
Skene's, 515
subclavian, 216, 217
sublingual, 22, 131
submaxillary, 126, 151
submental, 126
supra-epitrochlear, 286
suprarenal, 456
thymus, 224
thyroid, 159
of Tyson, 530
vulvovaginal, 547
of Weber, 133
Glans clitoris, 547
penis, 529
Glaser, fissure of, 88
Glaucoma, 104, 106, 168
Glenoid cavity, 251, 252, 254
fossa, 88, 89
ligament of fingers, 327
Globus major, 536
minor, 536
Glossitis, 129
Glosso-epiglottidean folds, 181
Glossopharyngeal nerve, 39, 134, 143, 147
Glottis, 181
edema of, 181
Gluteal abscess, 579
artery, 570
aneurysm of, 571
fascia, 568
fold, 564
nerve, inferior, 569
Gluteus maximus muscle, 568, 569
medius muscle, 570
minimus muscle, 570
Goiter, 190
exophthalmic, 187
Goll, tract of, 556
Gower, tract of, 556
Graafian vesicles or ovisacs, 509
Gracilis muscle, 581
Graves' disease, 187
Great auricular nerve, 169
occipital nerve, 30
omentum, 370
as a cause of intestinal obstruction, 371
function of, 371
in hernia, 370, 371
palatine nerve, 137
palmar bursa, 320
sacrosciatic foramen, 570
ligament, 569
nerve, 572, 595, 641
notches, 463
trochanter, 562, 584
caries of, 584
Groin, 573
bubo of, 575
fascia of, 574
fold of, 573
lymphatics of, 574
tumors of, 580
wounds of, 573
Groove or grooves, bicipital, 233, 250, 251, 278
costal, 210
costovertebral, 224
musculospiral, 281
nasogenial, 112
nasolabial, 112
obturator, 581
of spinal cord, 554
Gum-boil, 127
Gums, 127
general considerations of, 127

HALLE'S point, 454
Hallux valgus, 639
Halsted, method of breast amputation, 269
Hammer-toe, 638
Hamstring muscles, 600
tendons, 565
Hamular process, 142
Hand, 305, 316
cysts of, 329
dorsal surface of, 323
handle of, 291
hollow of, 316, 317, 319
tumors of, 329
Hard palate, 21, 141
Hare-lip, 126, 127, 141
double, 126, 142
Hasner, valve of, 110
Hauptganglion of Küttner, 136
Head, surface anatomy of, 17
Heart, 278
apex beat of, 206
displaced, in pleurisy, 222
exposure of, 230
relation to chest wall, 228
valves of, and their location, 229
wounds of, 228, 229, 230
Heister, valves of, 432
Helix, 59
fossa of, 59
Hematuria as a symptom of bladder affections, 483
Hemorrhage, contrecoup, 42
epidural, 41, 42
subconjunctival, 108
Hemorrhoidal arteries, 474, 489, 518
plexus of veins, 474
veins, 476
Hemorrhoids, 474, 475
external, 476
internal, 475
Hepatic artery, 372, 427
duct, 426
stone in, 430
flexure, 409
vein, 420
Hernia, acquired, 352
complete or scrotal, 351, 354, 356
congenital, 351, 352, 356
encysted, 352
femoral, 359
funicular, 352
incomplete, 353
infantile, 352
inguinal, 350
lumbar, 365
oblique inguinal, 351, 354
obturator, 582
perineal, 471
retroperitoneal, 390
scrotal, 354, 356
sigmoid, 414
strangulated, 355
umbilical, 346
Herniotomy, 355
Herpes zoster (shingles), 211
Heschel, transverse gyri of, 54
Hesselbach's triangle, 343, 354
Hiccup, 230, 231
Highmore, antrum of, 21, 85
Hilton's law, 252
method of incision into axilla, 265
water-bed, 49
white line, 472

Hip. See also *Hip-joint.*
disease, 364
tubercular, 591
dislocation of, 588
congenital, 591
reduction of, 590
symptoms of, 590
varieties of, 589
Hip-joint, 568, 583
capsule of, 585
ligaments of, 585
structure of, 583
Hoarseness, 161, 182, 183, 190
Hodgkin's disease, 143, 202
Horseshoe fistula, 475
kidney, 450
Housemaid's knee, 598
Houston's valves, 473
Humerus, 233, 252
anatomic neck, fracture of, 261, 263
condyles of, 284, 293
dislocations of, 253
head of, 234
separation of epiphysis, 262, 263
shaft of, 281
fracture of, 281
non-union in, 281
surgical neck, fracture of, 262, 263
tuberosities of, 233, 250
Hunter's canal, 594
Hutchinson's teeth, 129
Hyaloid membrane, 106
Hydatid of Morgagni, 537
Hydrocele, 538, 541
congenital, 542
encysted, 542
infantile, 542
vaginal, 542
Hydrocephalus internus, 51
Hydronephrosis, 453
intermittent, 453
Hydrothorax, 222
Hymen, 547
imperforate, 547
Hyoglossus muscle, 129, 151, 153, 154
Hyoid bone, 22, 163, 176, 177
fracture of, 176, 177
Hyperchlorhydria, 385
Hypertrophied prostate, 487
Hypochondriac region, 333
Hypogastric arteries, 345
plexus, 474, 503
region, 333
Hypoglossal nerve, 134, 151, 153, 154, 163, 166
Hypospadias, 532
balanic, 532
penoscrotal, 532
vulviforme, 532
Hypothenar eminence, 238, 239, 317

Iliac abscess, 579
artery, external, 177
fascia, 362
fossæ, 362
region, 333
Iliacus muscle, 363
Ileocecal fossa, 406
appendix in, 406
valve, 389
Ileocolic artery, 404
fossa, 406
Ilium, 391
Iliofemoral or Y-ligament of Bigelow, 585
Iliohypogastric nerve, 343
Ilio-inguinal nerve, 349
Iliopectineal eminence, 578
line, 462
Iliopsoas muscle, 357, 363
Iliotibial band, 564
Ilium, crest of, 331
spines of, 382, 562
Imperforate anus, 477
hymen, 547
Incisive papilla, 137
Incisor teeth, 127, 128
Incisura intertragica, 20, 60
pancreatis, 437
Incomplete hernia, 353
Incus, 63
Indicis extensor, 307
Infantile hydrocele, 542
umbilical hernia, 346
Inferior carotid triangle, 150
cervical sympathetic ganglion, 166
coronary artery, 125
dental artery, 89, 93
nerve, 89, 93
course of, 93
exposure of, 94
neuralgia of, 93
resection for, 93
gluteal nerve, 569
hemorrhoidal artery, 474, 518
vein, 474
labial artery, 125
laryngeal artery, 182
nerve, 183
lingualis muscle, 133
longitudinal sinus, 42
maxillary bone, 86
coronoid process of, 31
fractures of, 86
structure of, 86
branch of fifth nerve, 74, 77
nerve, 37, 92
mesenteric artery, 411
oblique muscle of eye, 99, 100
petrosal sinus, 44, 46
profunda artery, 280, 283
radio-ulnar joint, 308, 309
rectus muscle of eye, 99, 100
thyroid artery, 159, 160, 175, 189
vein, 185
turbinated bone, 110
vesical artery, 483, 489
Infraclavicular fossa, 243
Infragluteal hyoid muscles, 162
region, 176
orbital foramen, 74, 75
nerve, 76, 86, 108
involved in fracture of the superior maxilla, 86
neuralgia of, 86, 122
notch, 20
spinous fossa, 245
muscle, 251
triangle, 572
trochlear nerve, 108
Infundibuliform fascia, 341
Infundibulopelvic ligament, 506
Infundibulum of nose, 115
Inguinal canal, 348
relations of, 348
colostomy, 415
glands, 503, 574, 575
hernia, 350
acquired, 352
causes of, 351
complete, 351
congenital, 351, 352
coverings of, 354
direct, 354
encysted, 352
funicular, 352
infantile, 352
oblique, 351, 354

Inguinal hernia, radical cure of, 356
region, 347
Inguinofemoral region, 356
Inion, 17
Innominate artery, 244
bifurcation of, 155
vein, 165
Interarticular line of elbow-joint, 287
of femur, 566
Interclavicular notch, 208
Intercolumnar fascia, 349
Intercondyloid notch of femur, 605
Intercostal arteries, 211, 214, 342
injury in thoracentesis, 211
muscles, 120
neuralgia, 210
nerves, 210, 211, 214
diagnostic importance in reflected pain, 211
distribution of, 212
spaces, 204, 210
Intercostohumeral nerve, 211
Intermaxillary bone, 127, 141
Intermuscular septa of arm, 278
Internal abdominal ring, 332, 341, 348
annular ligament of ankle, 622
anterior thoracic nerve, 272
carotid artery, 51, 63, 80, 101, 143, 160 163
course of, 163
origin of, 163
relations of, 164
condyle of femur, 566
of humerus, 235
cutaneous nerves, 273, 280
hemorrhoids, 475
hydrocephalus, 51
jugular chain of lymphatics, 134
vein, 71, 158, 159, 165, 166, 244
anatomic and surgical considerations of, 165
laryngeal nerve, 134
lateral ligament of ankle, 626
of jaw, 89
malleolus, 566
mammary artery, 211, 214, 228, 342
anastomosis of, 211
ligation of, 211
glands, 216
maxillary artery, 63, 89, 92
vein, 92
oblique muscle, 339, 349
plantar artery, 631
popliteal nerve, 604
pterygoid muscle, 83, 94
pudic artery, 489, 514, 518, 571
rectus muscle of eye, 99, 100
saphenous vein, 617
sphincter of rectum, 472
strabismus, 38
Interphalangeal joints, 239
Interosseous arteries of forearm, 299
ligament of forearm, 297, 300
of leg, 616
muscles of hand, 276, 323
Interscapulothoracic amputation, 249
Intersigmoid fossa, 414
Intestinal anastomosis, 379
localization, 374
considerations in, 375
loops, 375, 376
determination of direction and position, 376, 377
obstruction, 436
caused by rent in omentum, 371
paralysis, 378
Intestine. See also *Intestinal, etc.*
large. See *Colon.*
small, 389
Intersutural membrane, 27, 33
Intervertebral fibrocartilages, 549
Intervesical pouch, 484
Intraligamentous cysts in female pelvis, 510
Intra-ocular pressure, 104
tension, 105, 106
Intravesicular triangle, 480, 492
Intussusception, 400
Iris, 102, 103, 105
Ischemic contraction of Volkmann, 302
Ischial bursa, 569
Ischiatic dislocation of the hip, 589
Ischiocavernosus muscle, 526
Ischiorectal abscess, 518, 579
fascia, 468
fossa, 518
contents of, 518
diverticula of, 518
Island of Reil, 55
Isthmus of thyroid gland, 184, 187
of uterus, 494

Jaw, condyle of, 20, 88, 89
coronoid process of lower, 125
cyst of, 129
dislocation of lower, 90
external lateral ligament of, 89
fixation of, 91
fracture of, 86, 87
internal lateral ligament of, 89
necrosis of, 92
ramus of, 92
tumors of lower, 92
Jejuno-ileum, 391
Joint or joints. See also *Articulations.*
abdominal, 368
acromioclavicular, 148
ankle, 621
carpometacarpal, 315
elbow, 287
hip, 583
interphalangeal, 239
knee, 604
mediocarpal, 310
mediotarsal, 633
metacarpophalangeal, 239
metatarsophalangeal, 567
radio-ulnar, 308, 310
sacro-iliac, 464
shoulder, 240
tarsometarsal, 634
temporomaxillary, 90
Jones' position, 294
Jonnesco, removal of cervical sympathetic, 168
Jugular foramen, 39
vein, anterior, 160
external, 149, 155, 168, 171, 173
internal, 71, 158, 159, 166, 244
thrombophlebitis of, 165
posterior, 168

Keratitis, 105
Key, foramen of, 50
Kidneys, 335, 439
abnormalities of, 449
capsule of, 443
clinical considerations of, 450
fetal, 450
fixation of, 442
floating, 444
hilum of, 440
horseshoe, 450
investments of, 442, 443
location of, 439, 440, 441
lymphatics of, 449

Kidney, movable, 444
nerves of, 449
pedicle of, 440
relation of twelfth rib to, 442
relations of, 445
rupture of, 451
size of, 440
supernumerary, 450
surface anatomy of, 441
Knee, 597. See also *Knee-joint.*
fascia of, 597
pain in region of, 598
skin of, 597
Knee-joint, 604
ankylosis of, 612
dislocations of, 613
excision of, 613
fracture about region of, 612
internal derangement of, 610
ligaments of, 607, 609, 610
loose cartilage of, 610
nerves of, 598
surface markings of, 597
synovial cul-de-sac of, 610
membrane, 610, 612
affections of, 611
Knock-knee, 606
Knuckles, 238
Kocher collar incision for thyroidectomy, 191
method of reduction in shoulder dislocations, 260
Küttner, hauptganglion of, 136
Kyphosis, 559

Labia majora, 545
minora, 546
Labial glands, 125
Lacrimal apparatus, 109
surgical considerations of, 111
arteries, 101
bone, 96, 110
canals, 110
caruncle, 108, 110
duct, 86
gland, 103, 109
location of, 109
structure of, 109
surgical considerations of, 111
nerve, 103, 108
sac, 86, 100, 110
Lacteal cyst, 214
Lacteals, 373
Lactiferous ducts, 214, 218
Lacuna magna, 523
Lambda, 18
Lambdoidal suture, 18
Large intestine. See also *Colon.*
malignant stricture of, 414
obstructions in, 414
Laryngeal lymphatics, 182
nerves, 182, 183
vessels, 182
Laryngotomy, 183
Laryngotracheal tube, 176, 177
Larynx, 144, 145, 159, 178
anatomy of, 179, 181
excision of, 183
inflammations of, 182
interior divisions of, 181
surgery of, 183
Lateral sinuses, 20, 39, 44, 47, 165
course of, 20, 46
divisions of, 46
location of, 46
relation to mastoid antrum, 47, 48
septic thrombosis of, 47
surgical considerations of, 47
Lateral sinuses, tributaries of, 46
true ligament of bladder, 468
ventricles of the brain, 58
where to trephine for, 58
Latissimus dorsi muscle, 205
Lead-poisoning, blue gum line of, 127
Leeching, point for application on cranium, 47
Left recurrent laryngeal nerve, 174
Leg, 615
aponeurosis of, 615
bones of, 618
fractures of, 619
muscles of, 616
skin of, 615
varices of, 617
varicose ulcers of, 615
veins of, 617
vessels of, 616
Lens, 105, 106
capsule of, 106
function of, 106
Lenticular nucleus, 52
Lenticulostriate artery, 52
Lesser internal cutaneous nerve, 273
omentum, 377
peritoneal cavity, 370, 377
sacrosciatic foramen, 570
trochanter, 585
Leukoplakia lingualis, 135
Leukorrhea, 501
Levator ani muscle, 466, 467
palati muscle, 140, 147
palpebræ superioris muscle, 99
paralysis of, 102
Lieberkühn's glands, 394
Ligament or ligaments, annular, of ankle, 621, 622
annular, of wrist, 307
appendiculo-ovarian or ligament of Clado, 403
of Bigelow, 585
of bladder, 468
broad, of uterus, 496, 505
calcaneoscaphoid, 633
capsular, of hip, 585
of jaw, 88
of shoulder, 245, 250
check, of eye, 98
of spine, 552
of Clado, 403
Colles', 339
conoid, 241
coracoclavicular, 241
coronary, of liver, 419
costo-acromial, 252
costoclavicular, 241
cotyloid, 583
crucial, 610
deltoid, of ankle, 626
of elbow, 287
falciform or suspensory, of liver, 419
of fingers, 327
formed by peritoneum, 370
gastrophrenic, 381
Gimbernat's, 339, 359, 360
glenoid, 327
great sacrosciatic, 569
of hip, 585
infundibulopelvic, 506
interosseous, of forearm, 300
of leg, 616
of jaw, external, 89
internal, 89
of knee, 607, 609, 610
orbicular, of elbow, 287
of mouth, 104
phrenocolic, 434
phrenosplenic, 434

Ligament, plantar, 633
pterygomaxillary, 94
Poupart's, 331, 337, 339, 565
carpal, 314
radio-ulnar, 309
round, of uterus, 496
scrotal, 537
of shoulder-joint, 251
sphenomaxillary, 89
of spinal column, 552
sternoclavicular, 241
stylomaxillary, 89
suspensory, of axilla, 243
of liver, 370, 418, 419
of penis, 528
teres, 585
transverse metacarpal, 318
trapezoid, 241
triangular, of abdominal wall, 339
of pelvis, 520, 526
tubo-ovarian, 508
utero-ovarian, 508
uterosacral, 496, 508
Y-, 585
of Zinn, 99
Ligamenta alaria, 611
denticulata, 553
subflava, 552
Ligamentum mucosum, 611
patella, 566, 607
rupture of, 609
teres, 585
Line or lines, Brödel's white, 448
Hilton's white, 472
iliopectineal, 562
interarticular, of elbow-joint, 287
of femur, 566
Nélaton's, 562
Reid's base-, 56
white, of forearm, 299
of pelvis, 466, 468
Linea alba of abdomen, 332
of neck, 185, 197, 198
Lineæ albicantes, 336
semilunaris, 332
transversa, 333, 340
Lingual artery, 153, 154, 164, 165
exposure of, 154
ligation of, 137
nerve, 94, 134, 154
resection of, in cancer of the tongue, 94
tonsil, 132
triangle, 153
vein, 151, 153
Lingula, 94
Lips of cervix, 499
of mouth, 125
affections of, 125
arteries of, 125
commissures of, 125
hare-, 126, 127
lymphatics of, 126
nerves of, 126
skin of, 125
veins of, 126
Lisfranc's amputation, 636
articulation, 634
tubercle, 171, 175
Littré, glands of, 523
Liver, 416
abscess of, 223
additional supports of, 419
blood supply of, 419
cirrhosis of, 421
clinical considerations of, 422
cysts of, 223
fissures of, 417
hydatid cyst of, 424
impressions on under surface of, 417
Liver, influences acting on position of, 418
ligaments of, 418
location of, 416
lymphatics of, 422
nerves of, 422
surface markings of, 417
vascular pedicle of, 419
wounds of, 422
Living ligatures, 502
Lobe or lobes, cuneate, 54
of ear, 60
frontal, 36
Riedel's, 424
temporal, 37, 54
Lobule of ear, 20
Lockjaw, 83
Longitudinal fissure, 17
sinus, superior, 44
Long plantar ligament, 633
thoracic artery, 214
nerve, 272
Lordosis, 364, 550
Loreta's operation, 386
Lower extremity, 562
Ludwig's angina, 151, 153
Lumbago, 366
Lumbar abscess, 579
colostomy, 415
enlargement of the spinal cord, 553
fascia, 366
hernia, 365
muscles, 365
nephrectomy, 442
plexus, 343
puncture, 364, 548
region, 333, 364
operations in, 367
veins, 448
vertebra, fourth, 390
Lumbricales muscles, 276
Lungs, 223
divisions of, 223
emphysema of, 225
landmarks of, 223
lymphatics of, 224
nerves of, 224
root of, 223
vessels of, 224
wounds of, 223, 225
Lupus, site of, on nose, 112
Luschka's tonsil, 145
Lymphatic gland or glands. See also under *Special Organs*.
accessory mammary, 215
axillary, 215, 216
of bladder, 483
of breast, 215, 216
bronchial, 231
of buttock, 573
of cheek, 78
of diaphragm, 378
of esophagus, 195
of eyelids, 78
of face, 78
gastric, 384
of groin, 574
inguinal, 503, 574, 575
of kidneys, 449
mammary, 215, 216
mediastinal, 231
of neck, 200
of ovaries, 509
of pancreas, 438
parotid, 82
pharyngeal, 147
of popliteal space, 604
of prostate, 490
of rectum, 475
retrosternal, 216

Lymphatic gland of scalp, 30
of scrotum, 535
of stomach, 384
subclavian, 216
submaxillary, 152
of testicles, 541
thyroid gland, 190
of tongue, 134, 135, 136
of uterus, 503
of vagina, 514
ring of Waldeyer, 146

MACEWEN'S guide to the mastoid antrum, 66
suprameatal triangle, 66
Macroglossia, 135
Magendie, foramen of, 50
Main en griffe (claw-hand), 276, 323
Malar bone, 96, 97
Male perineum and its adnexa, 517
Malformations of uterus, 503
Malgaigne's dictum, 86
Malignant stricture of the rectum, 476
Malleoli, 566
Malleus, 63
Malpositions of bladder, 485
Mammary gland, 204, 212. See also *Breast.*
accessory lymphatics of, 215
arteries of, 214
capsule of, 213
carcinoma of, 213, 217, 218
lipomata of, 216
lymphatics of, 215, 216
nipple of, 213
structure of, 213, 214
supernumerary, 212
region, 212
Manubrium, 204, 223
Masseter muscle, 71, 83, 92
Mastication, muscles of, 91, 92
Mastoid, antrum, 37, 65
Macewen's guide to, 66
surgical considerations of, 68, 69
cells, 65
trephining of, 48
disease, 67
process, 17, 65
Mastoiditis, 67
of Bezoldt, 68
Mastosquamosal suture, 68
Maxilla, inferior, 86
superior, 95, 96, 97, 110, 120
Maxillary artery, external. See *Facial.*
internal, 63
nerve, inferior, 74
superior, 74
sinus, 95, 96, 121
McBurney's point, 333
Mentotomy, 532
Meatus, external auditory, 17, 59, 60
anatomic considerations of, 60
blood supply of, 61
clinical considerations of, 62
glands of, 61
nerve supply of, 61
relation to mastoid cells and parotid gland, 61
urinarius, of male urethra, 529
Meckel's cave, 77
diverticulum, 346
ganglion, 97
space, 78
Median basilic vein, 236, 284
cephalic vein, 236, 284
nerve, 274, 278, 280, 297, 306
distribution to the fingers, 274
paralysis of, 274, 300
Mediastinal abscess, 208, 232
space, 219, 221
Mediastinum, 225
anterior, 226
contents of, 226
divisions of, 226
lymphatics of, 231
posterior, 226
tumors of, 232
Mediocarpal articulation, 308, 310
Mediotarsal joint, 633
Meibomian cyst, 108
glands, 108
Meissner's plexus, 385
Membrana tympani, 60, 61
attachments of, 62
blood supply of, 63
injuries to, 63
paracentesis of, 63
perforation of, 63
Membrane or membranes of brain, 40
costocoracoid, 244
cricothyroid, 23, 177
hyaloid, 106
interosseous, of forearm, 297
intersutural, 27, 33
obturator, 581
Schrapnell's, 63
of spinal cord, 553
thyrohyoid, 177, 179
trochlear, 100
Membranous urethra, 527
Meninges. See *Membranes of Brain or Spinal Cord.*
Meningocele, 558
Menstruation, 509
Mental foramen, 21, 74, 76, 87, 93, 94
nerve, 21, 76
symphysis, 86
vessels, 21
Mercurial poisoning, 127
Mesenteric cysts, 374
glands, 374
nerves, 373
plexus, 373
vessels, 373, 375, 376, 377
Mesentery, 370, 372
as a factor in hernia, 374
of cecum, 377
of colon, 377
extent of, 373
functions of, 374
hernia in, 374
of rectum, 377
Meso-appendix, 402
intestinal strangulation through, 403
structures of, 403
Mesocolon, 412
Meso-epididymis, 536
Mesonephron, 444
Mesosalpinx, 506, 510
Mesovarium, 506
Metacarpal bones, 323
dislocation of, 324
fracture of, 324
Metacarpophalangeal joint, 239, 320, 321, 324
Metatarsal bones, 632
Metatarsalgia of Morton, 633
Metatarsophalangeal joint, 567
Method of Antyllus, leg, 617. See also under *Individual Names.*
Bristow's, 480
Crile's, 162
Fowler's, 378
Halsted's, 269
Hilton's, 266
Kocher's, 260
Monks', 375

Method, Politzer's, 64
Stimson's, 260
Valsalva's, 64
Microcephalus, 33
Middle cerebral artery, 51, 54, 163
ear, 64, 67, 89
fossa of skull, 37
contents of, 37
fractures of, 37
hemorrhoidal artery, 474, 489
vein, 476
lobe of prostate, 489
meatus of nose, 115, 116
meningeal artery, 41, 42
affections of, 41
course of, 41
divisions of, 42
orbital branch of, 97
thyroid vein, 160
turbinated bone, 114, 115, 116
vesical artery, 483
Milk-leg, 503
Miner's elbow, 289
Mitral orifice, 229
Molar glands, 85
teeth, 128
Monks' method of intestinal localization, 375
Mons veneris, 544
Montgomery, tubercles of, 213, 218
Morgagni, columns of, 473
hydatid of, 505, 537
sinuses of, 147, 523
valves of, 473
Morton's metatarsalgia, 633
Motor area, 53
oculi nerve, 38, 101, 102
injuries to and effects of, 38, 102
Mouth, 124
cavity of, 125
cul-de-sac of, 124
divisions of, 124
floor of, 150
vestibule of, 124, 125
Movable kidney, 444
vertebræ, 551
Mucous coat or membrane. See under *Individual Structures.*
Müller, ducts of, 503
Mumps, 80
Munro, foramen of, 50
Muscle or muscles of abdomen, 337
accelerator urinæ, 526
adductor brevis, 581
longus, 576, 581
azygos uvulæ, 140
biceps, of arm, 233, 235, 248, 278, 279
of thigh, 600
brachialis anticus, 278, 279
buccinator, 84
bulbocavernosus, 526
ciliary, 102, 103, 105
compressor urethræ, 527
constrictor, of pharynx, 146, 147
coracobrachialis, 235, 248, 250
cremaster, 340, 536
crico-arytenoideus posticus, 180
crureus, 593
dartos, 534
deltoid, 250, 253
digastric, 151, 164, 165
erector penis, 526
spinæ, 334, 366
extensor brevis pollicis, 237, 307
communis digitorum, 307
indicis, 307
longus digitorum, of foot, 567
pollicis, 237
minimi digiti, 307
Muscle, extensor, ossis metacarpi pollicis, 307
proprius hallucis, 567
facial, 70
flexor carpi radialis, 306
ulnaris, 298, 299
profundus digitorum, 300
sublimis digitorum, 299
gastrocnemius, 616
gemellus inferior, 570
superior, 570
genioglossus, 129, 130, 132, 155
geniohyoid, 132
gluteus maximus, 568
minimus, 570
gracilis, 581
hamstring, 600
hyoglossus, 129, 151, 153, 154
iliacus, 363
iliocapsularis, 363
iliopsoas, 357, 363
infrahyoid, 162
infraspinatus, 251
internal pterygoid, 83
interossei, 323
of iris, 102
ischiocavernosus, 526
latissimus dorsi, 205
of leg, 616
levator ani, 466
palati, 140, 147
palpebræ, 99
lingual, inferior, 133
superior, 133
transverse, 133
lumbar, 365
lumbricales, 276
masseter, 20, 71, 83, 92
of mastication, 91, 92
mylohyoid, 132, 150, 151, 155
oblique, external, of abdomen, 338, 349
inferior, 99, 100
internal, 339, 349
superior, 97
obturator externus, 581
internus, 465, 570
occipitofrontalis, 19, 26
omohyoid, 150, 162, 168, 169, 170, 171
orbicularis oris, 125
palpebrarum, 99, 110
of orbit, 99
palatoglossi, 139, 140
palatopharyngeal, 140
palmar interossei, 323
palmaris longus, 306
pectineus, 576, 581
pectoralis major, 205, 217, 234
minor, 248
peroneus brevis, 616
longus, 616
tertius, 616
platysma myoides, 149
popliteus, 601
prevertebral, 158
pronator quadratus, 299
radii teres, 284
prostatic muscle, 486
psoas magnus, 363, 443, 576
pterygoid, external, 90, 92, 93
internal, 94
pyramidalis, 341
pyriformis, 466, 570
quadratus femoris, 570
lumborum, 366, 443
recti of eye, 99
rectus abdominis, 332, 340
sartorius, 576
scalenus anticus, 156, 171, 173, 175
semimembranosus, 601

Muscle, semitendinosus, 600
serratus magnus, 205
shoulder-strap, 251
sphincter ani, 472
vaginæ, 545
sternohyoid, 160, 177
sternomastoid, 23, 150, 155, 156, 158, 160, 162, 168, 169, 175
sternothyroid, 160, 177
styloglossus, 129
stylohyoid, 164
subclavius, 243, 244
subcrureus, 610
subscapular, 245
supinator longus, 276, 281, 297, 298
supraspinatus, 245, 251
tensor palati, 140
tympani, 64
teres major, 246
minor, 245, 246, 251
of thigh, 593
tibialis anticus, 567, 616
of tongue, 133
transversalis abdominis, 340
transversus perinei, 526
trapezius, 150, 156, 168
triceps, 278, 280
vastus externus, 593
internus, 593
of visual accommodation, 102
Muscular coat. See under *Individual Organs.*
Musculocutaneous nerve, 274, 278, 279
Musculospiral groove, 281
nerve, 276, 281, 297
paralysis of, 276, 281
Myelomeningocele, 558
Mylohyoid muscle, 132, 150, 151, 155
Myxedema, 186

Naboth, ovules of, 500
Nails, 327
Nares, anterior, 113
posterior, 113
Nasal bones, 21, 112
fractures of, 112
cavity, 112
floor of, 114
meati of, 115, 116
meningocele in, 114
relations of, 113
roof of, 114
duct, 110
fossæ, 44, 95
lymphatics of, 118
nerve, 103
polypi, 117
septum, 114, 137
Nasogenial groove, 112
Nasolabial groove, 112
Nasopalatine artery, 138
Nasopharynx, 145
Navicularis, fossa, 544
Neck, 148, 168
contents of, 148
contour of, 148
dangerous area of, 199
glands of, 201
linea alba of, 185, 197
lymphatics of, 200, 201
regions of, 149
skin of, 148
surface anatomy of, 17
topographic division of, 148
triangles of, 150
Nélaton's line, 562
Nephrectomy, lumbar, 442
Nephrolithotomy, 451
Nephropexy, 445, 451
Nephrotomy, 451
Nerve or nerves, abducent or sixth cranial, 37, 38, 97, 101, 103
accessory palatine, 140
Arnold's, 61
auditory, 38
auriculotemporal, 30, 63, 80, 93
of Bell, 272
buccal, 84
cardiac, 249
cavernous plexus, 103
cervicofacial, 81
chorda tympani, 93, 134
circumflex, 245, 246, 250, 255, 257, 273
crural, anterior, 357, 362, 639
cutaneous, of abdomen, external, 357, 362
internal lesser, 273, 280
deep temporal, 93
dental, inferior, 93, 94
descendens noni, 160, 162
eighth cranial. See *Auditory.*
eleventh cranial. See *Spinal Accessory.*
of face, 72, 74
facial, 26, 38, 72, 81, 147
fifth cranial, 37, 97, 101
fourth cranial, 37, 97, 100, 101
frontal, 103
genitocrural, 349
glossopharyngeal, 134, 143, 147
gluteal, 570
great auricular, 169
occipital, 30
palatine, 137
sacrosciatic, 572, 595, 641
hypoglossal, 134, 151, 153, 154, 163, 167
hypo-inguinal, 349
inframaxillary, 37
infra-orbital, 76, 86, 108
infratrochlear, 108
intercostal, 214
intercostohumeral, 211
interosseous, posterior, 276
lacrimal, 103, 108
laryngeal, inferior, 183
internal, 134
recurrent, 159, 174, 183, 189, 244
superior, 182
lingual, 93, 94, 134, 154
long thoracic, 272
of lower extremity, 639
maxillary, inferior, 92
superior, 37, 74, 97
median, 274, 278, 280, 297, 300, 306
mental, 21, 76
mesenteric plexus, superior, 373, 405, 459
motor oculi or third cranial, 37, 38, 97, 101, 102
musculocutaneous, 274, 278, 279
musculospiral, 276, 281, 297
nasal, 103
obturator, 582, 639
occipital, small, 169
olfactory, 116
ophthalmic, 37, 74, 77, 103
optic, 98, 101
of orbit, 101, 103
palatine, posterior, 140
phrenic, 156, 170, 171, 220, 244
plexus, aortic, 457
brachial, 156
cavernous, 103
cervical, 169
lumbar, 343
mesenteric, superior, 373, 405, 459
ovarian, 509
pelvic, 483

Nerve, plexus, perivaginal, 514
pharyngeal, 143
renal, 509
sacral, 474
solar, 385, 459
spermatic, 541
pneumogastric, 39, 61, 147, 158, 159, 170, 195, 220, 244
popliteal, 604
posterior auricular, 26
radial, 276, 298
recurrent laryngeal, 159, 174, 183, 189, 244
sacral, fourth, 474, 503
third, 503
of scalp, 29
sciatic, 572, 641
second cervical, 156
cranial. See *Optic.*
seventh cranial. See *Facial.*
sixth cranial. See *Abducent.*
spinal accessory, 38, 168
subscapular, 245, 272, 273
superior maxillary, 37, 97
supra-acromial, 169
supraclavicular, 169, 170
supra-orbital, 19, 30, 76, 103, 108
suprascapular, 245, 272
supratrochlear, 30, 37, 103, 108
temporofacial, 81
third cranial, 37
thoracic, anterior, 272
internal, 272
transverse cervical, 169
trifacial, 38, 76, 147
trochlear, 38, 103
ulnar, 280, 281, 284, 299, 300
of Wrisberg, 273
Nevi, 72
Nipple, 204, 213
affections of, 213
lactiferous ducts in, 214
location of, 213
retracted, 217
skin of, 213
Nose. See *Nasal Bones, Cavity, etc.*
Notch, cotyloid, 583
infra-orbital, 20
interclavicular, 208
intercondyloid, of femur, 605
of Rivini, 63
sacrosciatic, 463
suprascapular, 248
suprasternal, 204
Nuck, canal of, 507, 544, 548
Nuhn, glands of, 133

Oblique diameter of pelvis, 462
Obturator artery, 581
anomalous, in femoral hernia, 360
canal, 581
dislocation of hip, 589, 590
externus muscle, 581
fascia, 468
foramen (or thyroid), 581
gland, 582
groove, 581
hernia, 582
internus muscle, 465, 570
membrane, 581
nerve, 582, 639
region, 581
Occipital artery, 27, 163, 164
bone, 33
external protuberance of, 17
internal protuberance of, 44
superior curved line of, 155
fossa, 58
Occipital sinus, 44
triangle, 150, 168
Occipitofrontalis aponeurosis, 26
muscle, 19, 26
Odontoid process, 552
Odontoma, 92
Olecranon bursa, 289
process, 235, 284, 288
fracture of, 295
Olfactory bulbs, 36
nerve, 116
Omental bursa, 370
Omentum, 370
function of, 370, 371
gastrosplenic, 372
greater, 370, 377
in hernia, 370
lesser, 377
Omohyoid muscle, 150, 160, 168, 169, 171
Opening, aortic, in diaphragm, 220
esophageal, in diaphragm, 220
of inferior vena cava, in diaphragm, 220
saphenous, 359, 575
Operation, Alexander's, 507
Bassini's, 356
Estlander's, 210
Loretta's, 386
Ophthalmic artery, 99, 101
aneurysm of, 101
ganglion, 103
nerve, 37, 77, 101, 103
vein, 48, 71, 97, 99, 101
Optic disc, 104
foramen, 99, 101
nerve, 98, 101
compression of, 107
constrictions of, 102
course of, 101
strangulation of, 102
Orbicularis oris muscle, 125
palpebrarum muscle, 99, 110
ligament of elbow, 287
of jaw, 104
muscle, 104
Orbit, 95, 96. See also *Orbital Cavity.*
aponeurosis of, 98
cysts of, 107
muscles of, 99
nerves of, 101, 103
relation to cranial fossæ, 95
Orbital aponeurosis, 97, 98, 99
cavity, 95
abscess and cellulitis of, 97, 98
cirsoid aneurysm in, 101
compartments of, 97, 99
contents of, 99
foreign bodies in, 95, 96, 107
injuries to, 95
relations of, 95
tumors in, 96, 97, 107
walls of, 95, 96
emphysema, 97
fat, 97, 98
wasting of, 104
muscles, 99, 100
plates of ethmoid, 96
Organ of Rosenmüller, 509
Orifice or orifices, aortic, 229
cardiac, of stomach, 379
mitral, 229
pulmonary, 229
pyloric, 379, 382
tricuspid, 229
urethral. See *Meatus Urinarius.*
Os calcis, 631
fractures of, 635
external, of cervix, 498
internal, of cervix, 499
hyoides, 129

Os innominatum. See *Pelvic.*
magnum, 315
planum, 96
Ossicles of ear, 63
Otic ganglion, 80
Ovale, foramen, 78
Ovarian arteries, 501, 510, 511
cysts, 510
plexus, 509
vein, 509
Ovary, 508
access to, 590
clinical considerations of, 509
cysts of, 510
functions of, 508
in hernia, 508
lymphatics of, 509
nerves of, 509
structure of, 508
tumors of, 509
vessels of, 509
Ovulation, 509
Ovules of Naboth, 500

Pacchionian bodies, 41, 50
Paget's disease of the nipple, 213
Palatal aponeurosis, 139
bone, 96
cleft, 140
Palate, 137
arteries of, 138
cleft, 140
development of, 140, 141
hard, 21, 137
mucous membrane of, 137
perforations of, 138
soft, 21, 139, 141
affections of, 141
muscles of, 140
vault of, 137
vessels of, 138, 140
Palatine rugæ, 138
Palatoglossi muscles, 139, 140
Palatopharyngei muscles, 139, 140
Palm, 316
arches of, 317
fascia of, 318, 319, 322
flexor tendons in, 320
furrows of, 316
hemorrhage from, 281
infections of, 319, 322
radial transverse fold of, 239
regions of, 316
skin of, 317
ulnar transverse fold of, 239
Palmar arches, 239, 317, 319, 320
deep, 239, 322
superficial, 239, 320
bursa, 320
fascia, 318, 319
deep, 318, 322
superficial, 317
folds, 238, 239
ganglion, compound, 322
interossei muscles, 323
Palmaris longus muscle, 306
Palpebral arteries, 101
Palsy, Bell's, 72
Pampiniform plexus, 509, 540
Pancreas, 435
accessory, 438
body of, 437
carcinoma of head, 431, 437
cysts of, 439
ducts of, 437
head of, 436
location of, 436
lymphatics of, 438
Pancreas, modes of access to, 438
movable, 439
neck of, 437
relations of, 436, 437, 438
surgical considerations of, 438, 439
tumors of, 439
vessels of, 438
Pancreatic duct, 430, 437
Pancreaticoduodenal vessels, 436
Pancreatitis, 439
Papilla of Vater, 390
Papillæ of tongue, 132
Parametrium, 505
Paraphimosis, 530
Parathyroid glands, 191, 192
Parietal bones, 33
eminence, 18
Parieto-occipital fissure, 57
Paronychia (felon), 325
Parotid gland, 79, 163
accessory, 79
capsule of, 79
facial process of, 79
fistula of, 82
incisions into, 82
infections of, 80
relation to facial nerve, 81
tumors of, 82
lymph-glands, 82
region, 78
boundaries of, 78
contents of, 79
danger of wounds in, 79, 82
nerves of, 80, 81
vessels of, 80
Parotitis epidemic, acute, 80
Parovarian cysts, 510
Parovarium, or organ of Rosenmüller, 5
Patella, 566, 607
dislocations of, 609
fracture of, 608
ligaments of, 566
Pathologic pouch of female pelvis. 8
Cul-de-sac of Douglass.
triangle of bladder, 482
Pectineus muscle, 576, 581
Pectoral fascia, 214
region, 149
Pectoralis major muscle, 205, 217, 234
minor muscle, 248
Pedal arch, 629
Pelvic basin, 461
bones in composition of, 461
axis, 464
brim, 462
cellular tissue, 468, 469
cellulitis, 469
deformities, 465
diaphragm, 465
fascia, 467
inlet, 462
outlet, 463
plexus of nerves, 483
viscera, 469
Pelvis, 461. See also *Pelvic Basin, etc.*
brim of, 462
diameters of, 462
false, 461
female, 461
fractures of, 465
inlet of, 462
male, 461
outlet of, 463
position of, 463
triangular ligament of, 526
true, 461
white line of, 466
Penis, 528
arteries of, 531

Penis, body of, 528
bulb of, 529
cervix of, 529
clinical considerations of, 532
congenital defects of, 531
corona, 529
dorsal vein of, 530
epispadias of, 532
epithelioma of, 533
erectile body of, 528
fascia of, 531
fracture of, 533
frenum of, 530
glans, 529
hypospadias of, 532
lymphatics of, 531
meatus urinarius of, 529
nerves of, 531
organs in formation, 528
prepuce of, 530
root of, 528
skin of, 530
suspensory ligament of, 528
veins of, 531
Penopubic epispadias, 532
Penoscrotal hypospadias, 532
Pericardium, 219, 226
paracentesis of, 228
relations of, 227
Pericecal fossæ, 405
Pericranium, 27, 34
Perineal body, 513, 544
hernia, 471
route for access to bladder, 486
to prostate, 491
section, 527
difficulties in, 528
Perinephritic abscess, 451
Perineum, central tendinous point of, 526
female, 544
lacerations of, 544
male, 517
Perirenal fascia, 443
Peritoneal fossæ, 349
glue, 379
ligaments, 377
vessels, 377, 378
Peritoneum, 348, 368, 378
absorption from, 378
adhesions in, 378, 379
clinical considerations of, 378
folds of, 369
investment to viscera, 367, 369
lesser cavity of, 377
ligaments of, 378
lymphatics of, 378
nerves of, 378
plastic exudate in, 379
Peritonsillitis or quinsy throat, 144
Peritracheal glands, 231
Peritracheobronchial glands, 231
Perivaginal plexus of nerves, 514
Permanent wry-neck, 156
Peroneal artery, 617
muscles, 616
Peronei muscles, 616
Pes anserinus, 81
Petit, triangle of, 335, 365
Petrosal sinus, 48
inferior, 44, 46
superior, 44, 46, 65
Peyer's patches, 394
Phalanges of foot, 637
of hand, 327
fractures of, 328
Pharyngeal artery, ascending, 142, 147, 164
orifice of Eustachian tube, 145
plexus of nerves, 143
of veins, 143
Pharyngeal tonsil, 145
Pharynx, 124, 144
blood supply of, 147
constrictor muscles of, 146
extent of, 144, 145
laryngeal portion of, 146
lymphatics of, 147
muscles of, 146
Phimosis, 530
Phlebotomy, 284, 285
Phlegmasia alba dolens, 503
Phosphorus necrosis of lower jaw, 92
Photophobia, 103
Phrenic nerve, 156, 170, 171, 220, 244
plexus, 220
Phrenocolic costal sinus. See *Pleural Sinus.*
ligament, 434
splenic ligament, 434
Pia mater of brain, 40, 51
of spinal cord, 554
Pigeon breast, 208
Pillars of the fauces, 21, 139, 140
Piles, 474, 475
Pinna, 19, 59
Pirogoff's amputation, 637
Pisiform bone, 238, 317
Plantar arch, 631
arteries, 631
anastomosis of, 631
fascia, 630
surface, 629
Platysma myoides muscle, 149, 159
Pleura, 220
cul-de-sac of, 227, 228, 230
dome of, 174
inflammation of, 222
neoplasms of, 223
puncture of, 174
Pleural sinus, 221
Pleurisy, 212, 222
dry, 222
with effusion, 222
Plexus, aortic, 457
Auerbach's, 385, 386
brachial, 156, 171, 269, 276, 277
cavernous, 103
cervical, 169
hemorrhoidal, of veins, 474
hypogastric, 474, 503
lumbar, 343
Meissner's, 385
mesenteric, 373
ovarian, 509
pampiniform, 509, 540
pelvic, 483
perivaginal, 514
of pharyngeal veins, 143
phrenic, 220
prostatic, of veins, 487
pterygoid, 71
renal, 509
sacral, 474
of Santorini, 487, 515
solar, 378
spermatic, 541
subareolar, of Sappey, 216
superior mesenteric, 405, 459
of tonsillar veins, 143
of vaginal veins, 514
venous, of external jugular, 172
Pneumogastric nerve, 147, 158, 159, 170, 174, 195, 220, 244
distribution, in abdomen, 385, 460
injury to, in fractures of the skull, 39
in neck, 158, 174, 195
in thorax, 224
Pneumonia of children, referred pain in, 212

Pneumothorax, 222, 225
Point, McBurney's, 333
Halle's, 454
Robson's, 334
Politzer method of inflation of Eustachian tube, 64
Pomum Adami, 177
Popliteal aneurysm, 603
artery, 602
aneurysm of, 603
bifurcation of, 616
injury in resection of knee, 614
ligation of, 603
relations of, 602
lymphatics, 604
nerves, 566, 604
space, 566, 598
boundaries of, 599
bursæ of, 601
contents of, 598
skin of, 599
synovial cysts of, 604
wounds of, 598
vein, 603
Popliteus muscle, 601
Portal system, 420
anastomosis in, 371, 421
vein, 372
accessory, 421
formation of, 434
Posterior abdominal wall, 362
annular ligament of wrist, 307
auricular artery, 27, 39, 61, 164
vein, 61
cerebral artery, 52
communicating artery, 52
ethmoidal cells, 122
fontanel, 18
fossa of the skull, 38
contents of, 38
fracture of, 39
interosseous artery of forearm, 299
nerve of forearm, 276
mediastinal glands, 231
mediastinum, 226
nares, 113
palatine artery, 137, 138, 142
canal, 137
nerve, 140
scapular artery, 176, 248
synechia of iris, 105
tibial artery, 616, 624
triangle of neck, 150
Postero-external tract of the spinal cord, 556
Postero-internal tract of the spinal cord, 556
Postnasal adenoids, 145, 208
orbital abscess, 98
spinal sclerosis, 106
Pott's disease, 212, 363, 561
referred pain in, 212
fracture, 310, 627
characteristics of, 627
points of tenderness in, 628
reduction of, 628
symptoms of, 628
Pouch, intervesical, 484
rectovesical, 471
Poupart's ligament, 331, 332, 339, 565
Precardial region, 228
Prepatellar anastomosis, 598
bursa, 598
bursitis, 598
Prepuce of clitoris, 546
of penis, 530
affections of, 530
Pretracheal layer of deep cervical fascia, 198
Prevertebral fascia, 158
layer of deep cervical fascia, 198
muscles, 158
Prevesical abscess, 483
space or space of Retzius, 478, 479,
Principes cervices artery, 163
Process or processes, acromion, 233, 2
247, 252
clinoid, 43
coracoid, 234
coronoid, of inferior maxilla, 31
of ulna, 291
facial, of parotid gland, 79
falciform, 576
frontonasal, 141
hamular, 142
mastoid, 17, 65
odontoid, 552
of spinal column, 551
styloid, of radius, 309
zygomatic, of temporal bone, 19
Processus vaginalis, 348
Profunda cervicis artery, 163
femoris artery, 578
Prolapse of rectum, 472
of uterus, 504
Pronation of forearm, 302
Pronator muscles of forearm, 297
quadratus muscle, 299
radii teres, 284
Prostate, 486
access to, 491
apex of, 488
arteries of, 489
base of, 488
capsule of, 468, 487
clinical considerations of, 490
hypertrophied, 487, 490
lobes of, 489
lymphatics of, 490
nerves of, 490
relations of, 487
structure of, 489
Prostatic abscess, 490
bladder, 491
ducts, 489
infections of, 490
orifices of, 489
muscle, 486
plexus of veins, 487
sinus, 489
urethra, 488, 490
utricle, 489
Protoptosis, 97
Protuberance, occipital, external, 17
internal, 44
Psoas abscess, 363, 579
bursa, 579
muscle, 363, 443, 576
Psoitis, 363
Pterygoid muscle, 71
region, 31
venous plexus, 93
Pterygomaxillary fissure, 92
fossa, 92
boundaries of, 92
contents of, 92
wounds in, 93
ligament, 94
Ptosis of eyelid, 102
Pubic arch, 463
artery, internal, 489, 571
bone, 464, 465
crest of, 462
dislocation of the hip, 589
spine, 332, 565
Pulmonary artery, 223, 224
embolism, 224
orifice of heart, 229

Pulmonary vein, 223
Pulsating exophthalmos, 37
Puncta lacrimalia, 110
Pupils, 105
  Argyll-Robertson, 106
  contraction of, 105
  dilatation of, 105, 161, 190
  sphincter muscles of, 105
Pus-tube, 511
Pylorectomy, 382, 387
Pyloric arteries, 383
  orifice, 379, 382
  valve, 382, 389
Pyloroplasty, 388
Pylorus, 334, 381
  isolation of, 383
  obstruction of, 385
  relations of, 382
  resection of, 382
  situation of, 334
  stenosis of, 382, 386
Pyorrhea alveolaris, 128
Pyothorax, 222
Pyramidalis muscle, 341
Pyramid of Lalouette, 188
Pyriformis muscle, 466, 570

QUADRANGULAR space of shoulder, 246
Quadriceps extensor, 565
  femoris muscle, 570
  lumborum muscle, 366, 443

RACHITIC rosary, 208
Radial artery, 238, 297, 306, 307
    bifurcation of, 298
    injury to, 298
    ligation of, 298
  nerve, 276, 298
    distribution to the fingers, 276
    transverse fold of palm, 239
  vein, 238, 284, 305, 307
Radiocarpal articulation, 305, 308, 309
  dislocation, 310
  ligaments, 314
Radio-ulnar articulation, 310
  ligament, 309
Radius, 237, 300, 302
  dislocations of, 292
  epiphysis of, 309
  fractures of, 296, 304
  inferior extremity of, 308
  styloid process of, 309
Ranine arteries, 134
  veins, 22, 131
Ranula, 132
Receptaculum chyli, 373
Rectal ampulla, 470
  examination, 471
  glands, 473
  route in access to the bladder, 481
  triangle, 517
    boundaries of, 518
    contents of, 518
Recti muscles of the eye, 99
Recto-urethral triangle, 472, 488
Rectovaginal fistula, 513
  pouch, 471
Rectovesical fascia, 468
  fistula, 481
  pouch, 471
Rectum, 469
  clinical considerations of, 475
  excision of, 477
  external sphincter of, 472
  extraperitoneal relations of, 471
  foreign bodies in, 470
  internal sphincter of, 472
Rectum, lymphatics of, 475
  mesentery of, 377
  nerves of, 474
  pelvic portion of, 469
  peritoneal reflections over, 470
  prolapsus of, 472
  stricture of, 476
  structure of, 472
  vessels of, 474
Rectus, lineæ transversæ of, 333, 340
  muscle of abdomen, 332, 340
Recurrent laryngeal nerve, 159, 174, 183, 189, 244
  radial artery, 283
Reflex, abdominal, 343, 344
  cremasteric, 535, 536
  testicular, 535
Region or regions, adductor (or obturator), 581
  of arm, 278
  of brain, 53, 54. See *Areas*.
  of Broca, 53
  carotid, 155
  deltoid, 149
  epigastric, 333
  of hip, 568
  hypogastric, 333
  iliac, 333
  infrahyoid, 176
  inguinal, 347
  inguinofemoral (or femoral), 353
  lumbar, 333, 364
  mammary, 213
  mastoid, 47, 65
  maxillary, 31
  of neck, 149
  obturator, 581
  parotid, 78
  pectoral, 149
  precardial, 228
  pterygoid, 31
  scapular, 245
  silent, of the brain, 55
  sternomastoid, 155
  sublingual, 132
  submaxillary, 150, 153
  suprahyoid, 132
  umbilical, 333, 345
Reid's base-line, 56
Reil, island of, 55
Renal arteries, 447
  calculus, 449
  fossa, 443
  impression on surface of liver, 417
  plexus, 509
  tumors, 451
  veins, 448
Retina, 01, 105, 106
  functions of 106
Retracted chest, 207
  nipple, 217
Retrocalcanean bursa, 624
Retrocarotid gland, 160
Retro-esophageal abscess, 232
Retroperitoneal hernia, 390
Retropharyngeal abscess, 147, 194, 199, 232
Retrorectal space, 471
Retrosternal glands, 218
Retzius, foramen of, 50
  space of, 478, 479
Rhinoplasty, 27, 113
Ribs, 209
  affections of, 209
  first, 172, 173, 204
  false, 209
  floating, 209
  fracture of, 210
  number of, 209
  resection of, 210

Ribs, seventh cervical, 209
supernumerary, 209
true, 209
twelfth, 367, 442
Riders' bone, 577
Ridge, temporal, 19
Riedel's lobe, 424
Rigg's disease, or pyorrhea alveolaris, 128
Ring or rings, external abdominal, 332, 339, 348
femoral, 358
internal abdominal, 332, 341, 348
tracheal, 183
Rivini, notch of, 63
Rivinus, ducts of, 131
Robson's point, 334
Rolando, fissure of, 53, 54
Rosenmüller, fossa of, 145
gland of, 575
organ of, 505
Round ligament of uterus, 496, 506
access to, 507
clinical considerations of, 507
course and location of, 506
Run-around, 327

Sac, lacrimal, 86, 100, 110
Sacral nerve, fourth, 474, 503
third, 503
plexus, 474
Sacrocoxalgia, 464
Sacro-iliac joint, 464
synchondrosis, 562
Sacrosciatic foramina, 570
ligaments, 570
nerve, 572, 595, 641
notches, 463
Sacrovertebral angle, 462, 463
Sacrum, 461, 477
Saddle-nose, 113
Sagittal suture, 18
Salivary calculi, 153
colic, 153
cysts, 153
fistula, 82
glands, 79, 151, 153
Salpingitis, 511
Santorini, cartilage of, 181
duct of, 437
fissures of, 62
plexus of, 487, 515
Saphenous opening, 359, 575
vein, external, 604, 615
internal, 617
Sappey, subareolar plexus of, 216
Sartorius muscle, 576
Scalenus anticus muscle, 156, 171, 173, 175
Scalp, 25, 26, 27, 28, 29, 31, 32
arteries of, 27
aneurysms of, 28
peculiarities of, 28
collections of blood and pus in, 31
dangerous area of, 26
dermoid cysts in, 32
extent of, 25
hemorrhage of, 28
layers of, 25
lymphatics of, 30
nerves of, 29
peculiarities of vessels of, 26
sebaceous cysts in, 32
skin of, 25
subaponeurotic layer of, 26
superficial fascia of, 25
tumors of, 32
veins of, 29
wounds of, 29
Scalping, 26
Scaphoid bone of foot, 567, 632
of wrist, 238, 309, 314
Scapula, anatomic neck of, 247
angle of, 207, 223
fractures of, 247, 248
fossæ of, 245
inferior angle of, 207, 209, 247
spine of, 247
surgical neck of, 247
winged, 246
Scapular region, 245
arteries of, 248
Scapulohumeral region, 249
Scarpa's triangle, 565, 576
Schlemm, canal of, 106
Schrapnell's membrane, 63
Sciatica, 573
Sciatic artery, 571
nerve, 572
neuralgia, 604
Sclera, 104
pain due to tension of, 104
weakest point of, 104
wounds of, 104
Scoliosis, 550
Scrotal hernia, 354
ligament, 537
region, 533
structures in, 533
Scrotum, 533
dermoid cysts of, 534
edema of, 535
elephantiasis of, 535
epithelioma of, 535
layers of, 533, 535
lymphatics of, 535
skin of, 533
wounds of, 535
Sella turcica, 37, 48
Semilunar bone of wrist, 309
cartilage of knee, 607
fold of Douglass, 340
Semimembranosus muscle, 601
Seminal ducts, 491
vesicles, 491, 492
Semitendinosus muscle, 600
Septum crurale, 359
nasal, 21
Sequestration dermoids, 329
Serous glands of tongue, 133
Serratus magnus muscle, 205, 247
Sesamoid bones, 327
Seventh cervical vertebra, 548
Sheath, carotid, 162
femoral, 358, 359
of rectus muscle, 340
Shin, 566, 615
Shingles, 211
Shock, 460
Short ciliary arteries, 101
Shoulder or shoulder-joint, 240, 250
anatomic considerations of, 240
capsular ligament of, 245
dislocations of, 252
anatomic considerations in reduction, 259
anesthesia in reduction of, 259
characteristic features of, 253, 254
classification of, 253
methods of reduction, 259, 260, 261
obstacles to reduction of, 259
excision of, 263
ligaments of, 251
lymphatics of, 249
strap muscles of, 251
synovitis of, 252
tumors of, 249, 264
Sigmoid cavity, 287

Sigmoid flexure, 409
groove, 68
hernia, 414
sinus, 46, 66
Silent region of the brain, 55
Sinus or sinuses, cavernous, 37, 44, 71, 101, 163
circular, 44
ethmoid, 122
frontal, 18, 97, 118
lateral, 39, 44, 165
longitudinal, inferior, 42, 44
superior, 17, 41, 42, 44
maxillary, 95, 96, 121
of Morgagni, 147, 553
occipital, 44
petrosal, 48
inferior, 44, 46
superior, 44, 46, 65
pleural, 221
prostatic, 489
sigmoid, 46, 66
of skull, 43
sphenoidal, 123
straight, 42, 44
transverse, 44
uterine, 502
Sixth cervical vertebra, 145, 160, 167, 171
cranial or abducent nerve, 37, 48, 97, 99, 101
Skene's glands, 518
Skull, 35, 40, 55
fossæ of, 36, 37, 38, 39
fracture area of, 33
fractures of, 35, 36
trephining of, 57
vault of, fracture of, 35
necrosis of, 35
Small intestine, 389
blood-vessels of, 395
diameters and divisions of, 389
length of, 389
localization of, 374, 375, 376
lymphatics of, 395
solitary glands of, 394
strangulation of, 396
structure of, 393
surgical considerations of, 395
occipital nerve, 169
Smegma, 530
Smell and taste area, 53, 54
Socia parotidis, 79
Soft palate, 139, 141
Solar plexus, 385, 459
Space or spaces, axillary, 234
epidural, of skull, 41
of spine, 553
of Fontana, 106
intercostal, 204, 210
Meckel's 78
mediastinal, 219, 221
popliteal, 598
prevesical or space of Retzius, 478, 479, 483
quadrangular, of shoulder, 246
retrorectal, 471
subarachnoid, of brain, 49
of spinal cord, 554
thyro-epiglottidean, 177
triangular, of shoulder, 246
Spasmodic wry-neck, 156, 168
Speech area, 53
Spermatic artery, 540
cord, 348, 538
plexus, 541
veins, 540
Sphenoid bone, 33, 96, 97
clinoid processes of, 43
spine of, 89
Sphenoid bone, sinus, 123
wings of, 37
Sphenoidal fissure, 77, 93, 97, 101
contents of, 97
sinus, 123
Sphenomaxillary fissure, 92, 93, 97
fossa, 93, 97
ligament, 89
palatine foramen, 93
Spina bifida, 554
Spinal accessory nerve, 38, 155, 168
surgical anastomosis with facial, 74
anesthesia, 364, 548
canal, 552
clinical considerations of, 558
contents of, 552
column. See *Spine.*
cord, 553
arachnoid membrane of, 554
areas of, 556
cervical enlargement of, 553
concussion of, 560
conduction paths in, 556
dura mater of, 553
fissures of, 554
grooves of, 554
horns of, 555
injury to, 560
lumbar enlargement of, 553
membranes of, 553
pia mater of, 554
structure of, 554
nerves, 557
number, 557
origin, 558
Spine, 548
characteristics of, 548
dislocations of, 560
fracture of, 560
kyphosis of, 550
ligaments of, 552
lordosis of, 550
movements of, 549
nasal, 21
physiologic curves of, 549
processes of, 551
of pubis, 565
scoliosis of, 550
of sphenoid, 89
of Spix, 94
traumatic, 559
tuberculosis of, 364, 561
Spinosum, foramen, 78
Spix, spine of, 94
Spleen, 432
blood-vessels of, 434
clinical considerations of, 434
enlargement of, in cirrhosis of liver, 421
hilum of, 433
infarctions of, 434
ligaments of, 434
relations of, 433
situation of, 432
surface markings of, 433
wandering, 434
wounds of, 435
Splenectomy, 434, 435
Splenic artery, 372, 434
flexure of colon, 409, 434
vein, 434
Splenopexy, 434
Squamous sutures, 33
Stapes, 63
Stenson's duct, 20, 81, 85, 125
Sternal foramen, 208
notch, 204
Sternoclavicular joint, 158, 173
ligaments, 241

Sternohyoid muscle, 160, 177
Sternomastoid muscle, 23, 150, 156, 158, 160, 162, 168, 169, 175
action of, 155
nerve supply of, 155
relations of, 155
region, 155
Sternothyroid muscle, 160, 177
Sternum, 204, 208
affections of, 208, 209
articular surfaces of, 208
cavities of, 208
cleft, 209
fracture of, 209
trephining of, 209
Stimson's method of reduction in shoulder dislocations, 260
points of tenderness in Pott's fracture, 628
Stomach, 379
acute dilatation of, 386
cardiac end of, 379
location and stricture of, 381
clinical considerations of, 385
curvatures of, 381, 383
distention of, 381, 385
fixation of, 380
fundus of, 372
location of, 379
lymphatics of, 384
nerve supply to pit of, 344
nerves of, 385
operations on, 386
orifices of, 379
pyloric end of, 381
relations of, 379
Strabismus, external, 38, 102
internal, 38
Straight sinus, 42, 44
Strawberry tongue, 133
Stricture. See under *Individual Organs.*
Stump neuralgia, 595
Stye, 108
Styloglossus muscle, 129
Stylohyoid muscle, 164
Styloid process of radius, 309
Stylomaxillary ligament, 89
Subacromial dislocation of humerus, 253, 258
Subaponeurosis of scalp, 26
Subarachnoid space of brain, 49
of spinal cord, 554
Subareolar plexus of Sappey, 216
Subclavian arteries, 24, 155, 171, 173
anatomic guides to ligation of, 175
branches of, 175
collateral circulation after ligature of, 175
compression of, 175, 176
course of, 173
divisions of, 173
ligation of, 175
relations of, 173, 174
surgical considerations of, 175, 176
fossa, 234
glands, 216, 217
triangle, 159, 169
vein, 165, 170, 171, 172, 173
Subclavicular dislocation of humerus, 253, 256
Subclavius muscle, 243, 244
Subconjunctival hemorrhage, 108
ecchymosis, 37
Subcoracoid dislocation of humerus, 253, 256
Subcostal angle, 207
Subcrureus muscle, 610
Subcutaneous emphysema, 225
Subdeltoid bursa, 250
Subglenoid dislocations of humerus, 24 253, 254
Sublingual ducts, 131
glands, 22, 131
region, 132
Submammary bursa, 214
Submaxillary abscess, 153
calculi, 153
cellulitis, 153
gland, 151
extirpation of, 152
tumors of, 153
lymphatics, 126, 152
region, 150, 153
triangle, 150, 151
Submental artery, 151
lymphatics, 121, 134
Submucous or Meissner's plexus, 385
Subparotid gland, 82
Subphrenic abscess, 419
space, 419
Subscapular artery, 176, 249, 283
bursa, 245
fossa, 245
muscle, 245
nerve, 245, 273
Subspinous dislocation of humerus, 25 258
Sucking pad, 85
Suicidal wounds of neck, 178
Superficial cardiac triangle, 228
palmar arch, 239, 319
fascia, 317
temporal artery, 80
veins of scalp, 29
Superficialis volæ artery, 320
Superior carotid triangle, 150
cervical sympathetic ganglion, 166
coronary artery of mouth, 125
hemorrhoidal artery, 437
vein, 474
intercostal artery, 163, 175, 211
laryngeal artery, 182
nerve, 182
paralysis of, 178
lingualis muscle, 133
longitudinal sinus, 17, 41, 42, 44
course of, 17, 45
surgical relations of, 45
maxillary bones, 85, 96, 137
bony connections of, 86
excision of, 86
fractures of, 85
nasal process of, 110
outer wall of, 21
periosteum of, 86
structure of, 85
branch of fifth nerve, 77
nerve, 37, 74, 97
orbital branch of, 37, 76
region, 85
meatus of nose, 115
mesenteric artery, 373
plexus, 373, 405, 459
vein, 373
oblique muscle of eye, 97, 99, 100
petrosal sinus, 44, 46, 65
profunda artery, 276, 280, 283
rectus muscle, 99
thyroid artery, 163, 164, 165
vein, 160
turbinated bone, 114, 115
vesical artery, 483
Supernumerary kidneys, 450
mammary glands, 580
ribs, 209
Supination of forearm, 302
Supinator longus muscle, 276, 281, 28 297, 298

Supra-acromial bursa, 249
fossa, 169
nerve, 169
Supraclavicular nerves, 169, 170
triangle, 168, 189, 171
Supracondyloid fracture of femur, 612
Supra-epitrochlear gland, 286
Suprahyoid region of neck, 132
Suprameatal triangle, 48, 66
Supra-orbital artery, 19, 27
foramen, 74, 103
margin, 18
nerve, 19, 30, 37, 76, 103, 108
neuralgia, 30
notch, 18
ridges, 18
Suprapatellar bursa, 610
Suprapubic route of access to the bladder, 485
Suprarenal glands, 456
attachments of, 457
function of, 456
nerves of, 457
vessels of, 457
impression on liver, 417
Suprascapular artery, 175, 176, 252
nerve, 245, 272
notch, 248
Supraspinatus muscle, 245, 251
Supraspinous fossa, 171, 245
Suprasternal notch, 204
Supratrochlear nerve, 30, 103, 108
Surface anatomy of abdomen, 331
of head, 17, 18, 19, 20
of lower extremity, 562
of mouth, 20, 21, 22
of neck, 22, 23, 24
of pelvis, 332
of spine, 548
of thorax, 204, 205, 206
of upper extremity, 233, 235, 236, 237, 238, 239
Suspensory ligament of axilla, 243
of liver, 370
of penis, 528
Suture, coronal, 18, 55
lambdoidal, 18
mastosquamosal, 68
sagittal, 18
squamous, 33
Sylvian aqueduct, 50
fissure, 37, 51, 163
operculum, 53
Sympathetic cervical ganglia, 166, 167, 168
Symphyseotomy, 465
Symphysis pubis, 331, 464
Syme's amputation, 637
Syphilitic stricture of rectum, 476

TACTILE corpuscles of the fingers, 325
Talipes calcaneus, 622
equinus, 622, 623
equinovarus, 623
valgus, 622
varus, 622
Tarsal bones, 631, 632
diseases of, 635
Tarsometatarsal articulation, 634
Taste area, 54
buds, 132
Teeth, 128
bicuspid, 21, 128
buck, 146
canine, 128
fixation of, 128
Hutchinson's, 129
incisor, 127, 128
Teeth, molar, 128
re-implantation of, 128
temporary, 128
transplantation of, 128
varieties of, 128
wisdom, 129
Tegmen antri, 65
tympani, 37
Temporal aponeurosis, 97
artery, 19, 27, 61
cirsoid aneurysm of, 28
pulsations of, 163
bone, 33, 163
fascia, 31
fossa, 19, 31, 93, 95, 97
lobes, 37, 54
muscle, 19
ridge, 19
Temporary teeth, 128
Temporofacial division of the facial nerve, 81
Temporomaxillary articulation, 87, 90
ankylosis of, 91
arthritis of, 91
capsular ligament of, 88
external lateral ligament of, 89
structures in formation of, 90
vein, 80
Tendo Achillis, 566, 567, 616, 621, 638
rupture of, 623
tenotomy of, 623
oculi, 110
Tenon, capsule of, 95, 97, 98
Tensor palati muscles, 140
tympani muscles, 64
Tentorium cerebelli, 42, 46
contents of, 43
Teres major muscle, 246
minor muscle, 245, 246, 251
Testicles, 536
clinical considerations of, 541
coverings of, 348
cysts of, 537
ectopia of, 541
factors in descent of, 348
functions of, 536
inversion of, 536
lymphatics of, 541
nerves of, 541
structure of, 538
tumors of, 543
undescended, 541
Tetany, 191
Thenar eminences, 238, 239, 316
Thigh, 593
bone. See *Femur*.
extent of, 593
fascia lata of, 593
intermuscular septa of, 593
muscles of, 593
skin of, 593
Third cervical vertebra, 171
dorsal vertebra, 548
or motor oculi nerve, 37, 97, 99, 100, 101
sacral nerve, 503
Thoracentesis, 222
Thoracic cavity, 219
compartments of, 219
duct, 173, 220, 244
nerves, 272
Thorax, 207
boundaries of, 207
contents of, 207
diameters of, 207
elasticity of, 207
emphysema of, 225
penetrating wounds of, 207
surface anatomy of, 204

Thumb, 321, 324
amputation of, 321
dislocation of proximal phalanx, **328**
thenar eminence of, 316
Thymus gland, 224, 231, 232
Thyro-epiglottic space, 177
Thyroglossal duct, 132
Thyrohyoid bursa, 177
membrane, 177, 179
Thyroid artery, inferior, 159, **160**, **163**, 189
superior, 163, 182, 189
cartilage, 23, 163, 177
fracture of, 179
foramen, 581
ganglion, 166
gland, 159, 186
accessory, 191
anatomy of, 187
capsule of, 188
clinical considerations **of, 192**
extirpation of, 190
isthmus of, 184, 187
lymphatics of, 190
middle lobe of, 188
phenomena of enlargement of, 190
relations of, 188
vein, inferior, 185
middle, 160
superior, 160
Thyroidea ima artery, 185
Thyroidectomy, 190
Thyrotomy, 183
Tibia, 618
affections of, 620
crest of, 566, 615
fractures of, 619
tuberosity of, 566
tumors of, 620
Tibialis anticus muscle, 567, **616**
Tibiotarsal articulation, **626**
Toes, 637
deviations of, 638
dislocation of great, 639
hammer-, 638
tendons in, 637
Tongue, 124
abscess of, 129
behavior of during anesthesia, 130
cancer of, 94, 134
diagnostic value of, 133
excision of, 130, 136
functions of, 129
lymphatics of, 133
mucous membrane of, 132
muscles of, 129, 130, **133**
nerves of, 134
pain in, 134
papillæ of, 132
tumors of, 137
ulcerations of, 135
vessels of, 133
Tongue-tie, 131
Tonsillar arteries, 142, 143
plexus of veins, 143
Tonsillotomy, 143
Tonsils, 22, 142
abscess of, 143
blood supply of, 142
of Gerlach, 145
hemorrhage from, 143, **144**
hypertrophy of, 143
lingual, 132
Luschka's, 145
lymphatics of, 143
neoplasms of, 144
nerves of, 143
pharyngeal, 145, 146
Tophi, 60
Topography, abdominal, **333**
craniocerebral, 52, 53
Torcular Herophili, 17, 44
Torticollis (wry-neck), 156
congenital, 156
spasmodic, 156
Trachea, 23, 159, 204
anatomic considerations **of, 183, 185**
foreign bodies in, 186
relations of, 184
Tracheotomy, 23, 180, 185
Tracts of spinal cord, 556
Tragus, 20, 60
Transversalis colli artery, **175, 248**
fascia, 341, 348
muscle, 430
Transverse aorta, 230
cervical nerve, 169
colon, 411
in enteroptosis, 412
diameter of pelvis, 462
gyri of Heschl, 54
ligament of atlas, 552
lingual muscle, 133
mesocolon, 412
sinus, 44
Transversus perinei muscles, **526**
Trapezium bone, 315
Trapezius muscle, 150, 156, **168**
Traumatic spine, 559
Treitz, fossa of, 387, 390
Treves on pronation and supinat
302
rule in excision of the knee-joint, 6
Triangle or triangles, **Bryant's, 564**
carotid, inferior, **150**
superior, 150
cervical, 150
Farabeuf's, 166
gastric, 379, 385
Hesselbach's, 343, **354**
infragluteal, 572
intravesicular, 480, **492**
ischiobulbar, 526
lingual, 153
Macewen's, **66**
of neck, 150
occipital, 150, **168**
pathologic, of bladder, **482, 485**
of Petit, 335, 365
rectal, 517
recto-urethral, 472, 488
Scarpa's, 565, 576
subclavian, 150, 169
submaxillary, 150, 151
superficial cardiac, 228
supraclavicular, 168, **169, 171**
suprameatal, 66
urogenital, 517, 525
vaginorectal, 544
Triangular fibrocartilage **of wrist, 309**
ligament of abdominal **wall, 339**
layers of, 527
of pelvis, 520, 526
perforations of, 527
space of shoulder, 246
Triceps muscle, 278, 280
tendon in elbow, 289
Tricuspid orifice, 229
Trifacial nerve, 38, 147
neuralgia, 76
Trigger finger, 326
Trigone, 482
points for infection of, 482
Trismus, **83**
Trochanteric bursa, **569**
Trochanters, 562, 584
Trochlear membrane, **100**
nerve, 38, 101, 103

Tube or tubes, Eustachian, 64, 145, 146, 147
Fallopian, 510
laryngotracheal, 176, 177
pus, 511
Tubercle or tubercles of Chassaignac or carotid, 160, 162
of Darwin, 60
of Lisfranc, 171, 175
of Montgomery, 213, 218
of scaphoid bone of foot, 567
of wrist, 238
Tubo-ovarian ligament, 508
Tubular tonsil of Gerlach, 145
Tunica albuginea, 538
vaginalis, 348, 538
Tumors. See under *Individual Organs.*
Turbinated bones, 114
Türck, column of, 553
Twelfth rib, 367
relation to kidneys, 442
Tympanum, 63, 68
clinical considerations of, 67
membrane of, 62
ossicles of, 63
Tyson, glands of, 530

Ulna, 237, 300, 302, 309
dislocations of, 314
epiphysis of, 309
fractures of, 304
sigmoid cavity of, 287
Ulnar artery, 288, 298, 306
course of, 298, 306
ligation of, 299
position in the wrist, 306
nerve, 274, 280, 281, 284, 299, 300
distribution to the fingers, 275
paralysis of, 275
transverse fold of palm, 239
vein, 238, 284
Umbilical cord, 345
hernia, 346, 347
region, 333, 345
vein, 345
Umbilicus, 332, 345
Umbo, 63
Unciform bone, 317
Undescended testicle, 541
Urachus, 345
cysts of, 346
Uranoplasty, 142
Ureters, 452
clinical considerations, 455
constrictions of, 453
course of, 452
relations of, 453, 454
terminal ends of, 513
Ureterovaginal fistula, 513
Urethra, bulbous, 526
of female, 514
clinical considerations of, 516
direction of, 515
elasticity of, 515
meatus of, 514, 515
mucous coat of, 515
muscular coat of, 515
relations of, 515
structure of, 515
submucous coat of, 515
of male, 520
anterior, 521
bulb of, 526
caliber of, 521
characteristics of, 522
dilatation of, 484, 485
direction of, 520
divisions of, 521
function of, 520
Urethra of male, glands of, 522
length of, 520
membranous portion, 523, 527
mucosa of, 522
posterior, 521
prostatic, 489, 490
stricture of, 522, 523
structure of, 522
Urethral caruncle, 516
Urethrocele, 516
Urethrotomy, 527
Urethrovaginal fistula, 513
Urine, extravasation of 337, 526
Urogenital triangle of female, 545
of male, 517, 519, 525
structures in, 524, 545
Uterine artery, 501
plexus of veins, 506
sinuses, 502
Utero-ovarian ligament, 508
Uterosacral ligament, 496, 508
Uterus, 493
access to, 504
anteflexion and anteversion of, 495
body of, 494
cancer of, 504
cavity of, 499
clinical considerations of, 504
fixation of, 496
form of, 494
functions of, 493
isthmus of, 494
ligaments of, 496, 505
location of, 493
lymphatics of, 503
malformations of, 503
mucous coat of, 500
muscular coat of, 500
neck of, 494
nerves of, 503
peritoneal coat of, 500
position of, 495
pregnant, 502
prolapse, 504
relations of, 496
size of, 495
tumors of, 504
vascular pedicle of, 505
vessels of, 501
Utricle of prostate, 489
Uvula, 21, 139
elongation of, 139

Vagina, 512
erectile body of, 547
fibrocellular coat of, 514
fornices of, 513
mucous membrane of, 513
muscular coat of, 514
nerves of, 514
relations of, 512
rugæ of, 514
rugous column, 514
secretions of, 514
structure of, 513
vessels of, 514
Vaginal artery, 514
bulbs, 547
cystocele, 485
hydrocele, 542
plexus, 514
Vaginorectal triangle, 544
Valsalva method of inflating the Eustachian tube, 64
Valve or valves, anal, or valves of Morgagni, 473
of Gerlach, 402
of Hassner, 110

Valves of heart, 229
of Heister, 432
of Houston, 473
ileocecal, 389
pyloric, 382, 389
Valvulæ conniventes, 394
Varices of leg, 617
Varicocele, 542
frequency on left side, 542
time of occurrence, 543
Vas deferens, 492, 539
ampulla of, 493
artery of, 540
clinical considerations of, 493
course of, 493
in the cord, 493
scrotal segment, 539
Vasa brevia of splenic artery, 372
Vastus externus, 593
internus, 593
Vater, ampulla of, 431, 437
papilla of, 390
v. Ebner, glands of, 133
Vein or veins of abdominal wall, 343
angular, of face, 47, 101
axillary, 218, 244
basilic, 236, 281
cava, inferior, 220
cephalic, 236, 244
ciliary, anterior, 106
diploic, 29
dorsal, of penis, 531
emissary, of skull, 29
facial, 71, 126, 151, 153, 166
deep, 71
femoral, 579
of foot, 628
hemorrhoidal, 476
plexus, 474
hepatic, 420
innominate, 165
jugular, anterior, 160
external, 149, 155, 157, 168, 171, 173
internal, 71, 158, 165, 166, 244
posterior, 168
lingual, 151, 153
mastoid, 47
maxillary, internal, 92
median basilic, 236, 286
cephalic, 236, 284
mesenteric, superior, 373
ophthalmic, 48, 71, 97, 99, 101
pampiniform plexus, 509, 540
plexus of Santorini, 487, 515
popliteal, 603
portal, 372, 434
accessory, 421
prostatic plexus, 487
pulmonary, 223
radial, 238, 284, 305, 307
ranine, 131
renal, 448
saphenous, external, 604, 615
internal, 617
of scalp, 29
diploic, 29
emissary, 29
superficial, 29
spermatic, 540
splenic, 434
subclavian, 165, 171, 172, 173
thyroid, inferior, 185
middle, 160
superior, 160
ulnar, 238, 284
umbilical, 345
vaginal plexus, 514
vena azygos major, 220
Venereal warts, 532
Venous M of arm, 284
plexus of neck, 172
Ventricles of brain, 58
heart, 58
Vermiform appendix. See *Appendix*.
Vertebræ, 550
arch of, 551
atypical, 551
body of, 551
cervical, 158, 167, 171, 549, 551
dorsal, 551
fixed, 551
general characteristics of, 550
laminæ of, 551
lumbar, 551
movable, 551
points in common and difference, 551
prominens, 548
seventh cervical, 548
sixth cervical, 160, 167, 171
spinous processes of, 551
third dorsal, 548
transverse processes of, 551
Vertebral arteries, 38, 51
ganglion, 168
Verumontanum, 489
Vesical arteries, 483, 489
trigone, 482
Vesicles, seminal, 491, 492
Vesico-uterine fistula, 484, 497
Vesicovaginal fistula, 484, 513
Visceroptosis, 338
Visual area, 53, 54
Vitello-intestinal ducts, 345
Vitreous body, 106
Vocal cords, 181
false and true, 181
Volkmann, ischemic contraction of, 302
Volvulus, 414, 415
Vomer bone, 114
Vulva, 545
Vulvovaginal glands or glands of Bartholi 547
wall, 544

Waldeyer, lymphatic ring of, 146
Wandering spleen, 434
Washerwoman's sprain, 308
Water-bed of the brain, 49, 50
Weber, glands of, 133
Wen, 32
Wharton's duct, 131, 152
buccal orifice of, 22, 131
course of, 131
White line, Brödel's, 448
of forearm, 229
Hilton's, 472
of pelvis, 466, 468
Whitlow, 325
Willis, circle of, 51, 163
Window of eyeball, 104
Winged scapula, 246
Winslow, foramen of, 370, 37
hernia through, 377
Wirsung, canal of, 437
duct of, 437
Wisdom teeth, 129
Wormian bones, 33
Wrisberg, nerve of, 273
Wrist, 305
annular ligaments of, 317
bones of, 307, 308
dislocation of, 310
drop, 277, 281
excision of, 315
extent of, 305
ganglion of, 314
interarticular line of, 310

Wrist, landmarks of, 305
osteofibrous grooves of, 307
posterior annular ligament of, 307
tuberculosis of, 314
wounds of, 306
Wry-neck, 156. See *Torticollis.*

XIPHOID cartilage. See *Ensiform.*

Y-LIGAMENT of Bigelow, 585

ZINN, ligament of, 99
zone of, 106
Zygoma, 19, 89
Zygomatic arch, 92
fossa, 90, 97
process of temporal bone, 19

LANE MEDICAL LIBRARY

To avoid fine, this book should be returned on or before the date last stamped below.

NOV 14 1968

E 531 Campbell, W.F. 50162
C18 A text-book of surgical
1908 anatomy.

NAME	DATE DUE
M. Fulle, Dr Amza	NOV 14 1968